

OXFORD Medical Publications

OXFORD

LOOSE-LEAF

SURGERY

OXFORD
LOOSE-LEAF
SURGERY

BY VARIOUS AUTHORS

BASED ON BURGHARD'S OPERATIVE SURGERY. REVISED AND SUPPLEMENTED UNDER THE EDITORSHIP OF

ALLEN B. KANAVEL, A.B., M.D., F.A.C.S.
PROFESSOR OF SURGERY, NORTHWESTERN UNIVERSITY MEDICAL SCHOOL;
ATTENDING SURGEON, WESLEY MEMORIAL HOSPITAL, CHICAGO

IN FIVE VOLUMES
OVER 1800 ILLUSTRATIONS

VOL. V

NEW YORK
OXFORD UNIVERSITY PRESS
AMERICAN BRANCH, 35 WEST 32ND ST.

WC
100
O98
v.5, 1921

COPYRIGHT, 1918
COPYRIGHT, 1921
BY
OXFORD UNIVERSITY PRESS
AMERICAN BRANCH

PRINTED IN U. S. A.

PREFACE

The necessity for an extensive revision of this volume within so short a time of its original publication recalls to mind the statement of Paré in the dedication of his *Surgery,* written in 1575, "I have striven so hard to attain my end (the perfection of surgery) that the ancients have nought wherein to excel us, save the discovery of first principles; and posterity will not be able to surpass us, be it said without malice or offense, save by some additions, such as are easily made, to things already discovered."

The constant perusal of contributions from our best clinics makes every student realize how rapid are the changes that are continually taking place, and how difficult it is to maintain a comprehensive grasp of present day surgery. The present revision of this volume by eminent surgeons embodies the advances that have been made during the past few years in the field of gynaecology and of operative obstetrics, in radium therapy, and in the immediate and reconstructive treatment of injuries due to gunshot wounds.

That America shares with Great Britain an important heritage from McDowell and Sims is evidenced by the contributions from American and English gynæcological clinics. A description of technique in this highly developed branch of surgery, including the technique of peritonization, as well as that of specific operative procedures, necessarily entails an extensive presentation; at the same time the principles upon which it has been developed have not been neglected.

Our knowledge of the results of radium treatment has increased rapidly during the past few years. At present, the experimental phase is giving place to a period in which principles of application are being established. The considerable space which has been assigned to this subject has been utilized by the author to present practical and detailed suggestions concerning the application of radium in those conditions in which it has been found to be of value.

Sufficient time has elapsed to enable us to apply to civil practice the lessons learned in the Great War. The Oxford *Surgery* has been fortunate in securing, as contributors to the section devoted to the treatment of gunshot wounds, surgeons who took a prominent part in the actual care of war wounded, and who were able, by reason of their experience in civil surgery, to clarify and systematize the observations of their war experience, and draw from them lessons that are of uni-

versal application. Methods of localizing foreign bodies have been simplified and standardized. The treatment of penetrating wounds of the head has been perfected by the adaptation of principles whose soundness has been established in other fields of surgery, to injuries of the cranium and brain. Plastic operations on the face and jaws have been devised, and perfected to such an extent that one may say we have entered upon a new epoch in this branch of surgery. Surgery of the chest has been put upon a more rational basis. The opportunity for treating large numbers of patients with abdominal wounds has brought about the development of a more perfect technique, and, of more importance, of a more enlightened surgical attitude toward the treatment of this type of injuries. The application of the principles of primary excision and suture to the treatment of wounds of the soft parts, and of the bones and joints, marks a definite step forward in surgical methods.

The thanks of the Oxford *Surgery* are due the contributors for the thoroughness with which their work has been done, and for the excellent manner in which it is presented.

ALLEN B. KANAVEL

CONTRIBUTORS TO VOLUME V

HENRY RUSSELL ANDREWS, M.D., B.S., F.R.C.P.

Obstetric Physician to the London Hospital, London.

The General Preparation of Patients for Gynæcological Operations

CHANNING W. BARRETT, M.D., F.A.C.S.

Professor of Gynæcology, University of Illinois College of Medicine; Attending Gynæcologist, Cook County Hospital, Chicago Policlinic and Hospital, Henrotin Memorial, and West Side Hospitals, Chicago.

The Operative Treatment of Genital Fistulæ

W. BLAIR BELL, M.D., B.S.

Gynæcological Surgeon with charge of Out-Patients, Royal Infirmary, Liverpool.

Operations upon the Uterine Tubes

VILRAY PAPIN BLAIR, A.M., M.D., F.A.C.S.

Associate in Surgery, Washington University Medical School, St. Louis; Professor of Oral Surgery, Washington University, Dental Department; Visiting Surgeon, St. Luke's Hospital; Assistant Surgeon, Barnes and St. Louis Children's Hospitals, St. Louis.

Wounds of the Face and Jaw

SIR JOHN BLAND-SUTTON, F.R.C.S., Lieutenant-Colonel, R.A.M.C.(T.)

Surgeon to the Middlesex Hospital, London.

The After-Treatment, Risks and Sequelæ of Abdominal Gynæcological Operations

Operations for Non-Malignant Affections of the Uterus. Operations for Diseases of the Ovary.

VICTOR BONNEY, M.S., F.R.C.S.

Assistant Gynæcological Surgeon to the Middlesex Hospital; Surgeon, Chelsea Hospital for Women, London.

Operations for Malignant Disease of the Uterus and Cervix

JAMES T. CASE, M.D., F.A.C.S.

Professor of Roentgenology; Northwestern University Medical School; Surgeon, Battle Creek Sanitarium; formerly Senior Consultant in Roentgenology for the American Expeditionary Forces; Battle Creek, Michigan.

The Localization and Extraction of Foreign Bodies under X-Ray Control

CAREY CULBERTSON, M.D., F.A.C.S.

Assistant Professor of Obstetrics and Gynæcology, Rush Medical College, Associate Attending Obstetrician and Gynæcologist, Presbyterian Hospital; Attending Gynæcologist, Cook County Hospital, Chicago.

Operations upon the Vulva and Vagina

ARTHUR H. CURTIS, B.Sc., M.D., F.A.C.S.

Clinical Professor of Gynæcology, Northwestern University Medical School; Attending Gynæcologist, St. Luke's Hospital, Chicago.

The Operative Treatment of Retrodisplacements

JOSEPH B. DeLEE, A.M., M.D., F.A.C.S.

Professor of Obstetrics, Northwestern University Medical School; Obstetrician to the Chicago Lying-In Hospital and Dispensary, and to Mercy Hospital, Chicago.

Obstetrical Operations

PALMER FINDLEY, B.Sc., M.D., F.A.C.S.

Omaha, Nebraska.

The Surgical Treatment of Puerperal Infections

GILBERT HORRAX, M.D.

Assistant in Surgery, Harvard University; Associate in Neurological Surgery, Peter Bent Brigham Hospital, Boston.

The Surgery of Gunshot Wounds of the Skull and Brain

SUMNER L. KOCH, M.A., M.D.

Instructor in Surgery, Northwestern University Medical School; Adjunct Attending Surgeon, Wesley Memorial Hospital, Chicago.

Gunshot Wounds of the Joints

BURTON J. LEE, Ph.B., M.D., F.A.C.S.

Clinical Professor of Surgery, Cornell University Medical College; Associate Surgeon, New York Hospital, New York.

Gunshot Wounds of the Abdomen

FRANK W. LYNCH, A.B., M.D., F.A.C.S.

Professor of Obstetrics and Gynæcology, University of California Medical School; Obstetrician and Gynæcologist, University of California Hospital, San Francisco.

Peritonization

R. D. MAXWELL, F.R.C.S.

Assistant Obstetric Physician to the London Hospital; Physician to Queen Charlotte's Lying-In Hospital, London.

Operations for Ectopic Gestation

DUNLAP PEARCE PENHALLOW, B.Sc., M.D.

Major, Medical Corps, U. S. Army; Chief Surgeon, American Women's War Hospital, Paignton, England; Boston.

Wounds of the Long Bones

REUBEN PETERSON, A.B., M.D., F.A.C.S.

Professor of Obstetrics and Gynæcology, University of Michigan Medical School; Obstetrician and Gynæcologist-in-Chief, University Hospital, Ann Arbor, Michigan.

Operations for Inversion of the Uterus

EUGENE H. POOL, A.B., M.D., F.A.C.S.

Clinical Professor of Surgery, College of Physicians and Surgeons, Columbia University; Attending Surgeon, New York Hospital; Consulting Surgeon, French and New York Orthopædic Hospitals, New York.

The Early Treatment of Gunshot Wounds

FRANK EDWARD SIMPSON, A.B., M.D.

Clinical Professor of Dermatology, Northwestern University Medical School; Professor of Dermatology, Chicago Policlinic; Attending Dermatologist, Mercy, Wesley Memorial, Alexian Brothers, and Henrotin Memorial Hospitals, Chicago.

Radium Therapy

THOMAS J. WATKINS, M.D., F.A.C.S.

Professor of Gynæcology, Northwestern University Medical School; Attending Gynæcologist, St. Luke's Hospital, Chicago.

The Operative Treatment of Cystocele, Uterine Prolapse, and Lacerations of the Perineum

J. L. YATES, Ph.B., B.Sc., M.D., F.A.C.S.

Chief of Surgical Staff, Milwaukee's County Hospital; Attending Surgeon, Milwaukee Children's and Columbia Hospitals, Milwaukee, Wisconsin.

War Wounds of the Thorax

CONTENTS

SECTION I

THE GENERAL PREPARATION OF PATIENTS FOR GYNÆCOLOGICAL OPERATIONS

By HENRY RUSSELL ANDREWS, M.D., B.S.(Lond.), F.R.C.P.
Obstetric Physician to the London Hospital

CHAPTER I

THE GENERAL PREPARATION OF PATIENTS

PAGES

Preparation of the Patient for Gynæcological Operations, 3; for Abdominal Operations, 5; for Vaginal Operations, 6; for Special Operations, 7 3–8

SECTION II

THE AFTER-TREATMENT, RISKS, AND SEQUELÆ OF ABDOMINAL GYNÆCOLOGICAL OPERATIONS

By SIR JOHN BLAND-SUTTON, F.R.C.S., Lieutenant-Colonel R.A.M.C.(T.)
Surgeon to the Middlesex Hospital

CHAPTER I

THE AFTER-TREATMENT OF ABDOMINAL OPERATIONS... 11–12

CHAPTER II

COMPLICATIONS OF ABDOMINAL GYNÆCOLOGICAL OPERATIONS

Metrostaxis, 13. Bed-sores, 13. Postanæsthetic Paralysis, 13. Giving Way of the Wound, 14. Hæmorrhage, 15. Intrapelvic Hæmorrhage, 16. Pneumonia, 17. Parotitis, 17. Postoperative Thrombosis, 19. Embolism of the Pulmonary Artery after Hysterectomy, 22. Foreign Bodies Left in the Abdomen, 25. Tetanus, 28. Injury to the Intestines, 29. Intestinal Obstruction, 31. Perforating Ulcer of the Stomach and Small Intestine, 32. Injuries to the Bladder, 32. Injuries to the Ureter, 32. The Fate of Ligatures, 36. Postopera-

PAGES

tive Kraurosis, 38. The Cicatrix, 38. Cancer of the Cicatrix, 39. Acidosis and Postoperative Vomiting, 39. Dilatation of the Stomach, 40. Blood Transfusion, 40..... 13–40

SECTION III

OPERATIONS UPON THE VULVA AND VAGINA

By CAREY CULBERTSON, M.D., F.A.C.S.

Assistant Professor of Obstetrics and Gynæcology, Rush Medical College; Associate Attending Obstetrician and Gynæcologist, Presbyterian Hospital; Attending Gynæcologist, Cook County Hospital, Chicago

CHAPTER I

SURGERY OF THE VULVA AND VAGINA

Intravaginal Operations upon the Uterus, 43. Dilatation of the Cervix and Exploration of the Uterus, 43. Extirpation of Uterine Polyps, 45. Amputation of the Cervix Uteri, 46. Stenosis or Atresia of the Cervix, 54. Colpocœliotomy, 55. Posterior Colpotomy, 58. Posterior Colpocœliotomy, 59. Operations upon the Bladder and Urethra, 60. Vaginal Cystotomy, 60. Extirpation of Urethral Caruncle, 61. Prolapse of the Urethra, 61. Operations upon the Vulva, 62. Excision of the Vulva, 62. Circumcision, 67. Clitoridectomy, 67. Discission of the Hymen, 68. Enlargement of the Vaginal Introitus, 69. Extirpation of Benign Tumors and Cysts of the Vulva, 69. Extirpation of the Vulvovaginal Gland, 71. Hydrocele of the Labia Majora, 72. Extirpation of Varicose Veins, 72. Operations upon the Vagina, 72. Atresia of the Vagina, 72. Extirpation of Benign Tumors of the Vagina, 76..... 43–76

SECTION IV

THE OPERATIVE TREATMENT OF GENITAL FISTULÆ

By CHANNING W. BARRETT, M.D., F.A.C.S.

Professor of Gynæcology, University of Illinois College of Medicine; Attending Gynæcologist, Cook County Hospital, Chicago Policlinic and Hospital, Henrotin Memorial and West Side Hospitals, Chicago

CHAPTER I

THE OPERATIVE TREATMENT OF GENITAL FISTULÆ

Vesicovaginal Fistula, 79. Cervicovaginal Fistula, 90. Ureterovaginal Fistula, 90. Rectovaginal Fistula, 92. Enterovaginal and Enterovesical Fistula, 97..... 79–98

SECTION V

OPERATIONS FOR NON-MALIGNANT AFFECTIONS OF THE UTERUS

By SIR JOHN BLAND-SUTTON, F.R.C.S., Lieutenant-Colonel R.A.M.C.(T.)
Surgeon to the Middlesex Hospital

CHAPTER I

HYSTERECTOMY

PAGES

Indications, 101. Vaginal Hysterectomy, 102. Subtotal Hysterectomy, 106. Total Hysterectomy, 109. Total Hysterectomy with Preliminary Ligature of the Hypogastric Arteries, 110. Impaction of Fibroids, 111. Axial Rotation, 113. Cervical Fibroids, 115. Operations for Removal of Fibroids from the Broad Ligament, 117. The Flora of the Uterus in Relation to Hysterectomy, 120. Visceral Complication Associated with Fibroids in Relation to Hysterectomy, 122. Pelvic Complications, 124. Fibroids and Pregnancy, 125. Fibroids and Cancer of the Colon, 125. Cancer of the Breast and Fibroids, 126. Sarcoma of the Tibia and Fibula, 127. The Risks of Abdominal Hysterectomy for Fibroids, 127..... 101–130

CHAPTER II

ABDOMINAL MYOMECTOMY

Abdominal Myomectomy and Enucleation for Fibroids, 131..... 131–135

CHAPTER III

THE RELATIVE VALUE OF TOTAL AND SUBTOTAL HYSTERECTOMY

Cancer of the Body of the Uterus and Fibroids, 138. Sarcoma, 139. Cancer of the Uterus after Bilateral Ovariotomy, 140. Adenomyoma of the Uterus, 140. The Fate and Value of Belated Ovaries, 144..... 136–146

SECTION VI

OPERATIONS FOR MALIGNANT DISEASE OF THE UTERUS AND CERVIX

By VICTOR BONNEY, M.S.(Lond.), F.R.C.S.
Assistant Gynæcological Surgeon, Middlesex Hospital; Surgeon, Chelsea Hospital for Women

CHAPTER I

OPERATIONS FOR CARCINOMA OF THE CERVIX UTERI

Radical Extirpation by the Abdominal Route (Wertheim's Operation), 150. Technique of the Operation, 151. Ultimate Results of the

PAGES

Operation, 163. Causes of Death and Complications of the Operation, 164. Radical Extirpation by the Vaginal Route (Schauta's Operation), 167..... 149–172

CHAPTER II

TREATMENT OF CARCINOMA OF THE BODY OF THE UTERUS AND OF CHORIO-EPITHELIOMA

Palliative Operations, 173. Chorio-Epithelioma, 173..... 173–174

SECTION VII

PERITONIZATION

By FRANK W. LYNCH, A.B., M.D., F.A.C.S.
Professor of Obstetrics and Gynæcology, University of California Medical School; Obstetrician and Gynæcologist, University of California Hospital, San Francisco

CHAPTER I

PERITONIZATION

Definition, 177. Formation of Adhesions, 177. Adhesions Resulting from Infection, 179. Adhesions Resulting from Chemical Trauma, 179. Adhesions Following Mechanical Trauma, 179. Prevention of Adhesions, 182. Infolding Raw Surfaces by Sutures, 185. Cauterization, 194. Omental Grafts, 196. The Use of Other Abdominal Structures as Flaps, 198. Chemical Methods for Preventing Adhesions, 202..... 177–204

SECTION VIII

OPERATIONS FOR DISEASES OF THE OVARY

By SIR JOHN BLAND-SUTTON, F.R.C.S., Lieutenant-Colonel, R.A.M.C.(T.)
Surgeon to the Middlesex Hospital

CHAPTER I

OVARIOTOMY

The Operation, 207. Suture of the Abdominal Incision, 212. Suppurating Ovarian Cysts, 212. Typhoid Infection of an Ovarian Cyst, 213. Axial Rotation of Ovarian Cysts, 213. Cyst-Adenoma, 214. Ovarian Dermoids, 215. Ovarian Fibroids, 216. Sarcoma of the Ovary, 216. Papillomatous Cyst, 217. Carcinoma of the Ovary, 219. Cysts of the Broad Ligament, 220. Incomplete Ovariotomy, 221. Anomalous Ovariotomy, 221. Hysterectomy after Bilateral Ovariotomy, 222. Repeated Ovariotomy, 222. Pregnancy after Bilateral Ovariotomy, 222. Ovariotomy at the Extremes of Life, 222. Ovariotomy in Old Age, 223. Mortality, 224..... 207–225

CHAPTER II

OÖPHORECTOMY

PAGES

Operation, 227. Bacteriology of the Uterine Tube in Relation to Operations, 230. Abdominal Hysterectomy after Bilateral Oöphorectomy and Ovariotomy, 231. Mortality, 232. Operation for Primary Cancer of the Uterine Tube, 232. Chorio-Epithelioma of the Tube and Ovary, 235 226–235

SECTION IX

OPERATIONS UPON THE UTERINE TUBES

By W. BLAIR BELL, M.D., B.S.(Lond.)
Gynæcological Surgeon, with charge of Out-patients, Royal Infirmary, Liverpool

CHAPTER I

GENERAL CONSIDERATIONS CONCERNING OPERATIONS ON THE UTERINE TUBES

General Indications and Points in Technique, 239. Method of Access, 239. Preliminary Operative Details, 239 239–241

CHAPTER II

CONSERVATIVE OPERATIONS

Dilatation of the Uterine Tubes, 242. Salpingostomy, 242. Fixation of the Uterine Tubes, 244 242–246

CHAPTER III

ERADICATIVE OPERATIONS

Salpingectomy by Simple Ligature, 247. Salpingectomy by Excision, 248. Acrohystero-Salpingectomy, 249. Hystero-Salpingectomy, 251. Dangers and Difficulties of Operations on the Uterine Tubes, 252 247–253

SECTION X

OPERATIONS FOR ECTOPIC GESTATION

By R. D. MAXWELL, F.R.C.S.
Assistant Obstetric Physician to the London Hospital; Physician to Queen Charlotte's Lying-In Hospital

CHAPTER I

OPERATIONS FOR ECTOPIC GESTATION

Operation for Early Rupture of the Gravid Tube, 257. Operations when Grave Symptoms Ensue between the Third and Fourth Months, 260. Operations in the Later Months of Pregnancy, 263. Tubal Abortion, 264 257–268

SECTION XI

THE OPERATIVE TREATMENT OF UTERINE DISPLACEMENTS

THE OPERATIVE TREATMENT OF CYSTOCELE, UTERINE PROLAPSE, AND LACERATIONS OF THE PERINEUM

By THOMAS J. WATKINS, M.D., F.A.C.S.
Professor of Gynæcology, Northwestern University Medical School; Attending Gynæcologist, St. Luke's Hospital, Chicago

THE OPERATIVE TREATMENT OF RETRODISPLACEMENTS

By ARTHUR H. CURTIS, B.Sc., M.D., F.A.C.S.
Clinical Professor of Gynæcology, Northwestern University Medical School; Attending Gynæcologist, St. Luke's Hospital, Chicago

OPERATIONS FOR INVERSION OF THE UTERUS

By REUBEN PETERSON, A.B., M.D., F.A.C.S.
Professor of Obstetrics and Gynæcology, University of Michigan Medical School; Obstetrician and Gynæcologist-in-Chief, University Hospital, Ann Arbor

CHAPTER I

THE OPERATIVE TREATMENT OF CYSTOCELE, UTERINE PROLAPSE, AND LACERATIONS OF THE PERINEUM

PAGES

Cystocele, 271. Urethrocele, 272. Transposition Operation, 273. Vaginal Fixation of the Round Ligaments, 283. Advancement Operation, 283. Amputation of the Cervix Uteri, 285. Excision of Part of the Body of the Uterus, 286. Vaginal Hysterectomy, 287. After-Treatment, 288. Perineorrhaphy for Relaxed Pelvic Floor, 292. Perineorrhaphy for Complete Laceration of the Perineum, 298. Perineorrhaphy for High Rectocele, 308. Rectovaginal Fistula, 311.. 271–311

CHAPTER II

THE OPERATIVE TREATMENT OF RETRODISPLACEMENTS

Indications for Operation, 312. Extraperitoneal Operations, 313. The Alexander-Adams Operation, 313. Vaginal Suspension by the Round Ligaments, 313. Intra-Abdominal Operations, 315. Amputation of the Fundus, 316. Webster-Baldy Operation, 316. Advancement of the Bladder Peritoneum upon the Fundus, 316. Gilliam Operation, 322. Postoperative Care, 322..... 312–322

CHAPTER III

OPERATIONS FOR INVERSION OF THE UTERUS

Types of Operation, 323. Anterior Colpohysterotomy (Spinelli's Operation), 324..... 323–330

SECTION XII

OBSTETRICAL OPERATIONS

By JOSEPH B. DE LEE, A.M., M.D., F.A.C.S.
Professor of Obstetrics, Northwestern University Medical School; Obstetrician to the Chicago Lying-In Hospital and Dispensary, and to Mercy Hospital, Chicago

CHAPTER I

OBSTETRICAL OPERATIONS

PAGES

Vaginal Cæsarean Section, 333. Indications for Operation, 333. Conditions, 333. Anæsthesia, 334. The Operation, 355. Dangers, 342. Pubiotomy, 342. Conditions, 344. Technicque of Operation, 345. Complications, 349. Lacerations, 349. After-Treatment, 350. Classic Cæsarean Section, 350. Complications, 354. The Placenta, 355. Hæmorrhage, 356. Infection, 356. Uterine Drainage, 356. After-Treatment, 357. Porro Cæsarean Section, 358. Indications for Operation, 358. Technique, 358. Sterilization with Section, 362. Methods, 365. Suprasymphyseal Cervical Cæsarean Section, 366. Special Anatomy, 369. Technique of Operation, 370. Indications for Operation, 373. Indications for Cæsarean Section, 381. Selection of Method of Operation, 382..... 333–383

SECTION XIII

THE SURGICAL TREATMENT OF PUERPERAL INFECTIONS

By PALMER FINDLEY, B.Sc., M.D., F.A.C.S.
Omaha, Nebraska

CHAPTER I

THE SURGICAL TREATMENT OF PUERPERAL INFECTIONS

General Considerations, 387. Operations for Puerperal Sepsis, 389. Curettage, 389. Hysterectomy, 393. Drainage of Pelvic Abscess, 393. Pyæmia, 395. Surgical Treatment of Pyæmia, 397. Contra-Indications to Operative Interference, 397. Technique of Operation, 398..... 387–398

SECTION XIV

RADIUM THERAPY

By FRANK EDWARD SIMPSON, A.B., M.D.
Clinical Professor of Dermatology, Northwestern University Medical School; Professor of Dermatology, Chicago Policlinic; Attending Dermatologist, Mercy and Wesley Memorial Hospitals, Chicago

CHAPTER I

RADIUM THERAPY

Introduction, 401. Radium Emanation and Radio-Active Deposit, 401. Radio-Activity, 402. Apparatus for Applying Radium, 404. Appa-

PAGES

ratus Containing Radium Salts, 405. Apparatus Containing Radium Emanation, 407. Apparatus for Using the Active Deposit, 409. Absorption and Filtration of Rays, 409. Secondary Radiations, 410. Screens, 410. Distance Filtration, 411. Methods of Application, 412. Length of Exposure, 413. The Reaction, 414. Dosage, 415. Radium in General Surgery, 417. Malignant Tumors, 417. Epithelioma of the Skin, 418. Leukoplakia, 420. Cancer of the Lingual, Buccal, and Pharyngeal Mucous Membranes, 420. Carcinoma of the Breast, 422. Carcinoma of the Prostate, 423. Carcinoma of the Bladder, 423. Carcinoma of the Œsophagus, 424. Carcinoma of the Stomach and Intestines, 425. Carcinoma of the Rectum, 425. Sarcomata, 426. Tuberculous Lymphadenitis, 428. Radium in Gynæcology, 429. Fibromyoma of the Uterus, 429. Carcinoma of the Cervix Uteri, 430. Radium in Dermatology, 432. Malignant Tumors, 434. Benign Tumors, 434. Nævus Pigmentosus, 437. Chronic Infections, 438. Inflammatory and Granulomatous Infiltrations of Uncertain Nature, 439. Hypertrophic Diseases of the Skin, 440. Neuroses, 440. Disorders of the Appendages of the Skin, 440. Radium in Ophthalmology, 441. Radium in Otology and Laryngology, 442. Radium in Diseases of the Ductless Glands, 443. Leukæmia, 443. Hodgkin's Disease (Lymphadenoma), 444. Exophthalmic Goiter, 444. Radium in Internal Medicine, 444. Injuries Due to Radium, 446..... 399–448

SECTION XV

LOCALIZATION AND EXTRACTION OF FOREIGN BODIES UNDER X-RAY CONTROL

By JAMES T. CASE, M.D., F.A.C.S.

Professor of Roentgenology, Northwestern University Medical School; Surgeon, Battle Creek Sanitarium; formerly Senior Consultant in Roentgenology for the American Expeditionary Forces

CHAPTER I

THE LOCALIZATION AND EXTRACTION OF FOREIGN BODIES UNDER X-RAY CONTROL

Introduction, 451. Apparatus Required, 453. Centering the Tube, 454. Marking the Skin, 455. The Technique of Localization, 457. Anatomical Localization, 457. Rotation of the Part, 460. Nearest Point Method, 462. Parallax Method, 463. Orthodiagraphic Method, 466. Method of Right-Angled Planes, 467. The Multiple Diameters Method, 467. The Single Shift Triangulation Method, 470. Double Shift Fixed-Angle Method, 471. Harpoon Method, 475. Extraction of Foreign Bodies under X-ray Guidance, 477. The Open Screen in the Darkened Room, 480. The Bonnet Method, 484..... 451–488

SECTION XVI

WOUNDS OF THE BONES AND JOINTS

GUNSHOT WOUNDS OF THE JOINTS

By SUMNER L. KOCH, M.A., M.D.
Instructor in Surgery, Northwestern University Medical School; Adjunct Attending Surgeon, Wesley Memorial Hospital, Chicago

WOUNDS OF THE LONG BONES

By DUNLAP PEARCE PENHALLOW, A.B., M.D.
Major, Medical Corps, U. S. Army; Chief Surgeon, American Women's War Hospital, Paignton, England; Boston

CHAPTER I

GUNSHOT WOUNDS OF THE JOINTS

PAGES

Types of Injury, 491. Nonpenetrating Injuries, 492. Penetrating Injuries, 494. Perforating Injuries, 496. Injuries of Individual Joints, 496. The Shoulder-Joint, 496. The Elbow-Joint, 497. Injuries of the Wrist and Hand, 497. The Hip-Joint, 499. The Knee-Joint, 499. Wounds of the Ankle and Foot, 501. Complications, 502. The After-Treatment of Joint Injuries, 505 491–508

CHAPTER II

WOUNDS OF THE LONG BONES

Types of Injury, 510. Complications of Fractures, 512. The Treatment of Fractures, 512. Treatment at the Front, 512. Treatment at the Base, 515. Wounds of the Humerus, 523. Wounds of the Radius and Ulna, 535. Wounds of the Metacarpal Bones, 540. Wounds of the Phalanges, 542. Fractures of the Femur, 543. Fractures of the Tibia and Fibula, 555. Fractures of the Metatarsals, 561. Bone Plating, 566. Bone Grafting, 576 509–577

SECTION XVII

THE TREATMENT OF WOUNDS OF THE HEAD AND FACE

THE SURGERY OF GUNSHOT WOUNDS OF THE SKULL AND BRAIN

By GILBERT HORRAX, M.D.
Assistant in Surgery, Harvard University; Associate in Neurological Surgery, Peter Bent Brigham Hospital, Boston

PLASTIC REPAIR OF WOUNDS OF THE FACE AND JAWS

By VILRAY PAPIN BLAIR, A.M., M.D., F.A.C.S.
Associate in Surgery, Washington University Medical School; Professor of Oral Surgery, Washington University Dental Department; Visiting Surgeon, St. Luke's Hospital; Assistant Surgeon, Barnes and St. Louis Children's Hospitals, St. Louis

CHAPTER I

THE SURGERY OF GUNSHOT WOUNDS OF THE SKULL AND BRAIN

PAGES

Optimum Time for Operation, 581. Preliminary Preparation, 582. Anatomical Considerations, 584. Anæsthesia, 585. Operative Procedures, 588. Scalp Wounds, 589. Fractures without Penetration of the Dura, 590. Fractures with Penetration of the Dura, 592. Surgical Treatment of Complications, 608. Meningitis, 608. Encephalitis, 608. Ventriculitis, 608. Cerebral Abscess, 609. Postoperative Measures, 610. Dressings, with Special Reference to Hernia Cerebri, 610. Prognosis, 612..... 581–614

CHAPTER II

PLASTIC REPAIR OF WOUNDS OF THE FACE AND JAWS

Early Treatment, 616. Care of the Vital Forces, 616. Removal of Foreign Bodies, 617. Treatment of Bone Injuries, 618. Repair of the Soft Tissues, 621. Evacuation, 622. Anæsthesia, 622. Later Treatment, 623. Delayed Union of Fractures, 624. Delayed Suture, 625. Trismus, 626. Traumatic Fistulae, 626. Reconstruction, 628. Bony Defects and Malpositions, 628. Plastic Operations for Repair of the Soft Tissues, 635. Skin Grafting, 647. Full-Thickness Grafts, 647. Thiersch Grafts, 647. Epithelial Inlays, 648. Plastic Operations, 649. Resection of a Depressed Scar, 649. Plastics upon the Lip, 650. Defects within the Mouth, 657. Defects of the Palate, 659. Defects of the Orbit and Eyelids, 660..... 615–662

SECTION XVIII

GUNSHOT WOUNDS OF THE TRUNK

WOUNDS OF THE THORAX

By J. L. YATES, Ph.B., B.Sc., M.D., F.A.C.S.

Chief of Surgical Staff, Milwaukee County Hospital; Attending Surgeon, Milwaukee Children's and Columbia Hospitals, Milwaukee

WOUNDS OF THE ABDOMEN

By BURTON J. LEE, Ph.B., M.D., F.A.C.S.

Clinical Professor of Surgery, Cornell University Medical College; Associate Surgeon, New York Hospital, New York

CHAPTER I

WOUNDS OF THE THORAX

Intrathoracic Resistance to Infection, 665. Principles of Treatment of Thoracic Injuries, 670. Types of Chest Injuries, 671. Injuries of the Thoracic Parietes, 671. Injuries Involving Both Parietes and

PAGES

Viscera, 672. Injuries Involving Viscera Alone, 674. Indications for Operation, 675. Surgical Methods, 678. Pre-operative Treatment, 678. Anæsthesia, 679. Excision of Parietal Wounds, 681. Thoracotomy, 682. Cleaning the Pleural Cavity, 686. Blocking the Phrenic Nerve, 688. Blood Transfusion, 690. Operations upon the Lung, 691. Operations upon the Heart and Mediastinum, 695. Operations upon the Diaphragm, 695. Closure of the Chest Wall, 696. Drainage, 702. Postoperative Treatment, 703. Complications, 704 665–708

CHAPTER II

WOUNDS OF THE ABDOMEN

Introduction, 709. Incidence of Abdominal Wounds, 712. Military Importance of Abdominal Wounds, 712. Nonpenetrating Wounds, 713. Nonpenetrating Wounds Involving the Abdominal Wall, 713. Retroperitoneal Visceral Injuries, 714. Subcutaneous Rupture of Viscera, 715. Penetrating and Perforating Wounds, 717. The Symptoms of Visceral Injury, 719. Indications for Operation, 720. Operative Technique, 722. Postoperative Treatment, 724. Postoperative Complications, 725. The Treatment of Visceral Injuries, 727. Wounds of the Stomach, 727. Wounds of the Small Intestine, 729. Wounds of the Colon, 731. Wounds of the Rectum, 732. Wounds of the Liver, 733. Wounds of the Pancreas, 734. Wounds of the Spleen, 735. Wounds of the Kidney, 736. Wounds of the Ureter, 737. Wounds of the Bladder, 737. Abdominothoracic Injuries, 739.. 709–742

SECTION XIX

THE EARLY TREATMENT OF GUNSHOT WOUNDS

By EUGENE H. POOL, A.B., M.D., F.A.C.S.

Clinical Professor of Surgery, College of Physicians and Surgeons, Columbia University; Attending Surgeon, New York Hospital; Consulting Surgeon, French and New York Orthopædic Hospitals, New York

CHAPTER I

THE EARLY TREATMENT OF GUNSHOT WOUNDS

Introduction, 745. Care of the Wounded in the Field Hospital, 746. Mobile and Evacuation Hospitals, 747. Shock, 748. The Early Treatment of Fractures, 751. Wounds of the Soft Parts, 754. The Technique of Débridement, 760. Primary Suture, 767. Bacteriologic Examination of Wounds with Reference to Suture, 768. Delayed Primary Suture, 769. Secondary Suture, 769. Wounds of the Face, 770. Wounds of the Hand, 770. Wounds of the Foot, 771. The Bacteriology of War Wounds, 771. Trench Foot, 773..... 745–775

LIST OF ILLUSTRATIONS

FIG.		PAGE
1.	Posterior View of the Rectus Abdominis Muscle below the Level of the Umbilicus	20
2.	The Pulmonary Artery and Adjacent Part of the Lung and Trachea (*Museum of the Middlesex Hospital*)	22
3.	A Pair of Pressure Forceps (*MacLaren*)	27
4.	Low Amputation of the Cervix	47
5.	Low Amputation of the Cervix. Incision of the lateral wall	48
6.	Low Amputation of the Cervix. Reflexion of the mucous membrane and excision of the anterior lip	50
7.	Low Amputation of the Cervix. Excision of the posterior lip and closure	51
8.	High Amputation of the Cervix. First step	52
9.	High Amputation of the Cervix. Second step	53
10.	Incision for Colpocœliotomy	56
11.	Incision for Posterior Vaginal Colpotomy	59
12.	Line of Incision for Excision of Urethral Caruncle	62
13.	Appearance at Completion of Operation	62
14.	Elephantiasis of the Vulva. Line of incision	63
15.	Elephantiasis of the Vulva. Resection of the redundant tissue between the two lines of incision	64
16.	Elephantiasis of the Vulva. Appearance after the removal of the redundant tissue	65
17.	Elephantiasis of the Vulva. Closure of the wound	66
18.	Line of Incision for Resection of the Clitoris	67
19.	Resection of the Hypertrophied Clitoris	67
20.	Discission of the Hymen	68
21.	Enlargement of the Vaginal Introitus	70
22.	Malignant Disease of the Vulva	71
23.	Formation of an Artificial Vagina from a Loop of Ileum	75
24.	Diagrammatic Illustration of Different Types of Genital Fistulæ	81
25.	Small, Easily Accessible Vesicovaginal Fistula	82
26.	Repair of Vesicovaginal Fistula by Sim's Method	82
27.	Vesicovaginal Fistula. Incision preliminary to separating vaginal flap	83
28.	Vesicovaginal Fistula. Closure of the bladder	83
29.	Vesicovaginal Fistula. Midline incision in case of more extensive fistula	84
30.	Vesicovaginal Fistula. Separation of the vagina and bladder completed	84
31.	Vesicovaginal Fistula. Closure of the bladder	85
32.	Vesicovaginal Fistula. Closure of the vaginal mucous membrane	86
33.	Vesicovaginal Fistula Close to the Cervix. Technique of the operation	87
34.	Vesicovaginal Fistula Close to the Cervix. Separation of the bladder from the cervix	88

FIG.		PAGE
35.	Vesicovaginal Fistula Close to the Cervix. Closure of the bladder	89
36.	Common Type of Rectovaginal Fistula	90
37.	Rectovaginal Fistula. Line of incision for raising the vaginal flaps	90
38.	Rectovaginal Fistula. Suture of the levator ani underneath the vaginal flaps	91
39.	Rectovaginal Fistula. Operation completed	91
40.	Rectovaginal Fistula. Suture of the rectal wall	92
41.	Rectovaginal Fistula of Congenital Origin	93
42.	Lateral View of the Same Case	94
43.	Rectovaginal Fistula Due to Imperfect Perineum	95
44.	Rectovaginal Fistula Due to Imperfect Perineum. First step	96
45.	Rectovaginal Fistula Due to Imperfect Perineum. Second step	96
46.	Rectovaginal Fistula Due to Imperfect Perineum. Third step.	97
47.	Vaginal Hysterectomy, Technique of operation	103
48.	Blood Supply of the Uterus and Vagina	105
49.	The Mattress Suture	107
50.	The Stump after Subtotal Hysterectomy	108
51.	Uterus in Sagittal Section	112
52.	Uterus in Sagittal Section	113
53.	A Sessile Subserous Fibroid	114
54.	Fibroid of the Left Broad Ligament.	117
55.	A Bicornate Uterus	118
56.	A Bicornate Uterus Shortly after Delivery	119
57.	Uterus and Subserous Fibroid in Section	133
58.	An Adenomyomatous and Tuberculous Uterus	141
59.	Uterus in Sagittal Section	142
60.	Uterus and Adjacent Segment of the Rectum in Sagittal Section. (*Cuthbert Lockyer*)	143
61.	Uterus with the Decidua *in Situ*	145
62.	Radical Extirpation of the Uterus by the Abdominal Route. First step	154
63.	Radical Extirpation by the Abdominal Route. Second step	155
64.	Radical Extirpation by the Abdominal Route. Third step	157
65.	Radical Extirpation by the Abdominal Route. Fourth step	158
66.	Radical Extirpation by the Abdominal Route. Fifth step	159
67.	Radical Extirpation by the Abdominal Route. Sixth step	160
68.	Radical Extirpation by the Abdominal Route. Seventh step	161
69.	Radical Extirpation by the Vaginal Route. First step	168
70.	Radical Extirpation by the Vaginal Route. Second step	169
71.	Radical Extirpation by the Vaginal Route. Third step	170
72.	Radical Extirpation by the Vaginal Route. Fourth step	171
73.	Nature's Method of Walling-off a Peritonitis (*Richardson*)	178
74.	Nature's Method of Walling-off a Peritonitis (*Royster*).	180
75.	Technique for Burying Knots in Peritonization	183
76.	Repair of Injury to the Intestinal Mucosa	184
77.	Peritonization after Panhysterectomy	185
78.	Technique of Defundation	186
79.	Technique of Defundation. Obliteration of the raw surface of the uterus	189
80.	Technique of Defundation. Appearance at the completion of operation	190

FIG.		PAGE
81.	Closure of the Serous Surface of the Uterus after Cæsarean Section	191
82.	Peritonization Following Removal of the Appendix	192
83.	Peritonization Following Suspension of the Uterus by Webster's Method	193
84.	Peritonization Following Suspension of the Uterus, Combined with Removal of the Tube and Ovary	194
85.	Proper Method of Peritoneal Closure	195
86.	Omental Graft. Microscopic appearance (*Finton* and *Peet*)	197
87.	Omental Graft. Microscopic appearance (*Finton* and *Peet*)	197
88.	Pelvic Peritoneum after Removal of the Uterus and Adherent Pus Tubes	199
89.	Peritonization after Panhysterectomy. Raw surfaces left following the removal of a cancerous uterus	200
90.	Peritonization after Panhysterectomy. Suture of the anterior and posterior peritoneal flaps	201
91.	Peritonization after Panhysterectomy. Closure of the peritoneal cavity	202
92.	Peritonization after Panhysterectomy. Suture of the sigmoid colon over raw areas	203
93.	Secondary Cancer of the Ovary	219
94.	Secondary Cancer of the Ovary in Section	220
95.	An Infected Uterine Tube	227
96.	A Tuberculous Uterine Tube and Ovary	228
97.	Primary Cancer of the Uterine Tube	234
98.	A Section of Primary Cancer of the Uterine Tube	234
99.	Salpingostomy	243
100.	Suspension of the Ovary and Fallopian Tube	245
101.	Salpingo-Oöphorectomy	248
102.	Salpingectomy with Conservation of the Ovary	249
103.	Author's Operation of Acrohystero-Salpingectomy	250
104.	Tubal Gestation Prolonged to an Unusual Duration without Rupture or Abortion	259
105.	Rudimentary Cornual Pregnancy	262
106.	Interstitial Pregnancy	263
107.	Displacement of the Bladder and Urethra during Labor	271
108.	Change in the Position of the Bladder and Urethra after Retraction of the Cervix	272
109.	Urethrocele	273
110.	Transposition Operation. First step	274
111.	Transposition Operation. Second step	274
112.	Transposition Operation. Third step	275
113.	Transposition Operation. Fourth step	275
114.	Transposition Operation. Fifth step	276
115.	Transposition Operation. Sixth step	276
116.	Transposition Operation. Seventh step	277
117.	Transposition Operation. Eighth step	278
118.	Transposition Operation. Ninth step	279
119.	Transposition Operation. Tenth step	279
120.	Transposition Operation. Eleventh step	280
121.	Transposition Operation. Twelfth step	280

FIG.		PAGE
122.	Sagittal Section of Normal Pelvis	281
123.	Sagittal Section of Pelvis Following Transposition Operation and Perineorrhaphy	282
124.	Vaginal Fixation of the Round Ligaments	284
125.	Amputation of the Cervix. First step	285
126.	Amputation of the Cervix. Second step	285
127.	Amputation of the Cervix. Third step	287
128.	Amputation of the Cervix. Fourth step	287
129.	Vaginal Hysterectomy. First step (*C. H. Mayo*)	288
130.	Vaginal Hysterectomy. Second step (*C. H. Mayo*)	289
131.	Vaginal Hysterectomy. Third step (*C. H. Mayo*)	290
132.	Vaginal Hysterectomy. Fourth step (*C. H. Mayo*)	291
133.	Perineorrhaphy. First step	293
134.	Perineorrhaphy. Second step	294
135.	Perineorrhaphy. Third step	294
136.	Perineorrhaphy. Fourth step	295
137.	Perineorrhaphy. Fifth step	295
138.	Complete Laceration of the Perineum	296
139.	Perineorrhaphy for Complete Laceration of the Perineum. First step	297
140.	Perineorrhaphy for Complete Laceration of the Perineum. Second step	298
141.	Perineorrhaphy for Complete Laceration of the Perineum. Third step	299
142.	Perineorrhaphy for Complete Laceration of the Perineum. Fourth step	300
143.	Perineorrhaphy for Complete Laceration of the Perineum. Fifth step	301
144.	Perineorrhaphy for Complete Laceration of the Perineum. Sixth step	301
145.	Operation for High Rectocele. First step	302
146.	Operation for High Rectocele. Second step	303
147.	Operation for High Rectocele. Third step	304
148.	Operation for High Rectocele. Fourth step	305
149.	Operation for High Rectocele. Fifth step	306
150.	Operation for High Rectocele. Sixth step	307
151.	Operation for High Rectocele. Seventh step	307
152.	Rectovaginal Fistula. Technique of operation (*Vernon David*)	309
153.	Rectovaginal Fistula. Dissection and closure of the fistulous tract (*Vernon David*)	310
154.	Shortening of the Uterosacral Ligaments (*John V. Young*)	314
155.	Shortening of the Uterosacral Ligaments (*John V. Young*)	315
156.	Webster-Baldy operation	317
157.	Webster-Baldy operation	318
158.	Advancement of the Bladder. First step	319
159.	Advancement of the Bladder. Second step	320
160.	Advancement of the Bladder. Third step	321
161.	Anterior Colpohysterotomy. First step	324
162.	Anterior Colpohysterotmy. Second step (*Crossen*)	325
163.	Anterior Colpohysterotomy. Third step (*Crossen*)	326
164.	Anterior Colpohysterotomy. Fourth step (*Crossen*)	326
165.	Anterior Colpohysterotomy. Fifth step	327
166.	Anterior Colpohysterotomy. Sixth step	328
167.	Anterior Colpohysterotomy. Seventh step (*Crossen*)	327
168.	Anterior Colpohysterotomy. Eighth step	329

FIG.		PAGE
169.	Vaginal Cæsarean Section. First step	334
170.	Vaginal Cæsarean Section. Second step	335
171.	Vaginal Cæsarean Section. Third step	336
172.	Vaginal Cæsarean Section. Fourth step	337
173.	Vaginal Cæsarean Section. Fifth step	338
174.	Vaginal Cæsarean Section. Sixth step	339
175.	Vaginal Cæsarean Section. Seventh step	340
176.	Vaginal Cæsarean Section. Eighth step	341
177.	The Anatomy of Pubiotomy. Line of incision in the bone	343
178.	The Anatomy of Pubiotomy. Position of the veins likely to be injured	344
179.	Ligature Carrier for Use in Pubiotomy	346
180.	Pubiotomy. Passing the needle around the bone	347
181.	Pubiotomy. Sawing through the pubic bone	348
182.	Cæsarean Section. The uterus being steadied by volsella	353
183.	Cæsarean Section. The uterine suture	355
184.	Porro Cæsarean Section. First step	359
185.	Porro Cæsarean Section. Second step	360
186.	Porro Cæsarean Section. Third step	361
187.	Porro Cæsarean Section. Fourth step	362
188.	Porro Cæsarean Section. Fifth step	363
189.	Porro Cæsarean Section. Sixth step	364
190.	Porro Cæsarean Section. Seventh step	365
191.	Porro Cæsarean Section. Eighth step	366
192.	Method of Exsecting the Tubes	367
193.	Cervical Cæsarean Section; Krönig's Operation. First step	368
194.	Cervical Cæsarean Section; Krönig's Operation. Second step	369
195.	Cervical Cæsarean Section; Krönig's Operation. Third step	370
196.	Cervical Cæsarean Section; Krönig's Operation. Fourth step	371
197.	Cervical Cæsarean Section; Krönig's Operation. Fifth step	372
198.	Cervical Cæsarean Section; Krönig's Operation. Sixth step	373
199.	Cervical Cæsarean Section; Krönig's Operation. Seventh step	374
200.	Cervical Cæsarean Section; Krönig's Operation. Eighth step	375
201.	Extraperitoneal Cæsarean Section; Latzko's Operation. First step	377
202.	Extraperitoneal Cæsarean Section; Latzko's Operation. Second step	378
203.	Extraperitoneal Cæsarean Section; Latzko's Operation. Third step	379
204.	Extraperitoneal Cæsarean Section; Latzko's Operation. Fourth step	380
205.	Extraperitoneal Cæsarean Section; Latzko's Operation. Fifth step	381
206.	Generalized Suppurative Inflammation of the Pelvis (*Cullen*)	390
207.	Pelvic Abscess. (*Cullen*)	391
208.	Method of Opening the Broad Ligament from the Vagina (*Cullen*)	392
209.	The Abdominal Approach to a Broad Ligament Abscess (*Cullen*)	394
210.	Apparatus for the Application of Radium	405
211.	Apparatus for the Application of Radium Emanation	408
213.	Pad of Cork Squares for Holding Radium in Position	413
214.	Photographs of Patient with Lymphosarcoma of the Neck Recurring after Operation	427
215.	Photographs of Patient with Cutaneous and Subcutaneous Angioma	436
216.	Palpator Made from a Small Wooden Rod, with a Screw and a Screw-Eye	453

FIG.		PAGE
217.	X-ray Tube Properly Centered, and Off Center	455
218.	Screen Appearance of a Tumbler with the Tube Properly Centered and not Properly Centered	459
219A.	Screen Appearance of an Intracranial Foreign Body	459
219B.	Screen Appearance Which Might Lead to an Erroneous Diagnosis of Intracranial Foreign Body	461
220A.	Method of Rotation of the Part (*Nogier*)	462
220B.	Method of Rotation of the Part	463
221.	Diagrammatic Representation of the Parallax Method	464
222.	Screen Appearance during Different Steps of the Parallax Method	465
223A.	Orthodiagraphic Method of Localization	466
223B.	Measurement in Two Directions. (Right-Angled Planes)	466
223C.	Screen Appearance and Method of Using the Ring-Localizer	468
224A.	Malleable Band and the Six Point Survey Methods	469
224B.	Classical Single Shift Triangulation Method	470
225A.	Method of Similar Triangles. (Double Shift Fixed-Angle Method)	472
225B.	Screen Appearance at Different Steps of the Double Shift Fixed-Angle Method	473
225C.	Screen Appearance after Notching the Diaphragm Leaves for the Roussel Method	474
226.	Hirtz Compass Guidance during a Surgical Operation	476
227A.	Extraction of a Foreign Body under Fluoroscopic Control	478
227B.	Extraction of a Foreign Body under Fluoroscopic Control	479
228A.	Arrangement of the Tube and Table for the Bonnet Method	482
228B.	Dessane Bonnet Fluoroscope for Screen Observation	483
228C.	Bonnet Method for Localization of Foreign Bodies. First step	484
228D.	Bonnet Method. Second step	485
228E.	Bonnet Method. Third step	486
228F.	Bonnet Method. Diagram illustrating the relative position of the tube, wound, radiologist's pointer, and bonnet fluoroscope (*Ledoux-Lebard*)	487
229A.	Perforating Wound of the Wrist-Joint Treated by Primary Excision and Suture (*Duval*)	498
229B.	Penetrating Wound of the Knee-Joint Successfully Operated upon Fifty-Six Hours after Injury	500
229C.	Penetrating Wound of the Knee-Joint Treated by Débridement and Primary Closure (*Duval*)	501
229D.	Perforating Wound of the Knee-Joint Treated by Débridement and Primary Closure (*Duval*)	502
229E.	Perforating Wound of the Ankle-Joint Treated by Débridement and Primary Closure (*Duval*)	503
229F.	Skiagram of Elbow-Joint Showing Extent of Bone Injury (*Willems*)	506
229G.	Restoration of Function Accomplished by Active Mobilization (*Willems*)	507
230.	Grooving Fracture of Humerus Caused by Rifle Bullet	513
231.	Perforating Bullet Wound of Humerus	514
232.	Fissured Fracture of Shaft of Humerus Caused by Bullet	514
233.	Comminution of Shaft of Humerus by Rifle Bullet with Indirect Fracture Below	515

FIG.		PAGE
234.	Comminuted Fracture of Shaft of Humerus Caused by Bullet	516
235.	Comminuted Fracture of Shaft of Humerus Caused by Rifle Bullet	517
236.	Comminuted Fracture of Shaft of Humerus Caused by Rifle Bullet	518
237.	Fracture of Shaft of Humerus Caused by Shell Fragment	519
238.	Severe Comminution of Shaft of Humerus Caused by Shell Fragment	520
239A.	Fracture of Shaft of Humerus Caused by Shell Fragment	520
239B.	Position of Fracture Treated by Thomas Arm Extension Splint	521
239C.	Same Fracture after the Application of the Osgood-Penhallow Splint	522
239D.	Method of Application of Splint and Strapping to Hold Splint in Proper Position	523
240.	Modified Thomas Splint for Fractures of the Humerus	524
241.	Page Aluminum Splint as Applied for Fractures of the Humerus	525
242.	Right-Angled Splint for Fractures of the Elbow or Forearm	526
243.	Compound Fracture of Humerus Treated by Extension and Suspension on Modified Hodgen's Splint	527
244.	Blake's Method of Treating Fractures of the Humerus by Suspension and Extension	529
245.	Extension Apparatus for Fractures of the Humerus	530
246.	Extensive Comminution of Upper Part of Humerus Caused by Bullet	531
247.	Fissured Fracture of Lower End of Radius Caused by Shrapnel Bullet	532
248.	Fissured Fracture of Shaft of Ulna Caused by Shrapnel Bullet	533
249.	Perforated and Fissured Fracture of Ulna from Deformed and Disintegrated Bullet	534
250.	Grooved and Fissured Fracture of Radius Caused by Shell Fragment	534
251.	Comminuted Fracture of Ulna Caused by Shrapnel Bullet	535
252.	Comminution of Radius and Ulna Caused by Rifle Bullet	536
253.	Perforating Rifle-Bullet Wound of Arm	537
254.	Splintering of Radius from Shell Fragment	538
255.	Grenade Wound of Forearm with Extensive Destruction of Soft Tissues and of Ulna	539
256.	Contact Fracture of 3rd, 4th and 5th Metacarpal Bones by Shell Fragment	541
257	Extension Splint for the Reduction and Alignment of Fracture of the Metacarpus	542
258.	Grooving Fracture of Phalanx Caused by Bullet	543
259.	Perforation of Proximal Phalanx, Simulating a Butterfly Fracture, Caused by Bullet	544
260.	Comminution of Terminal and Proximal Phalanges of Thumb Caused by Bullet	544
261.	Gutter Wound of Femur Caused by Shell Fragment	545
262.	Comminuted Fracture of Femur Caused by Rifle Bullet	546
263.	Oblique and Fissured Fracture from Deflected Bullet	547
264.	Oblique Indirect Fracture of the Lower End of Femur	548
265.	Page Aluminum Extension Splint for Fractures of the Lower Leg and Thigh	549
266.	Suspension Frame for Dressing Wounds of the Thigh	550
267.	Perforating Bullet Wound of Tibia without Fragmentation	553
268.	Perforating Bullet Wound of Tibia Associated with Fissured Fracture and Comminution	554

FIG.		PAGE
269.	Perforation of Tibia by Rifle Bullet with Fragmentation	554
270.	Perforation and Splintering of Fibula by Rifle Bullet	555
271.	Grooving Fracture of Lower End of Tibia Caused by Rifle Bullet	555
272.	Comminuted Fracture of Lower End of Tibia Caused by Bullet	556
273.	Comminuted Fracture of both Tibia and Fibula Caused by Shell Fragments	556
274.	Contact Fracture with Radiating Fissures Caused by the Lead Core of a Deformed Bullet	557
275.	Erosion of the Tibia just below the Tubercle, Caused by a Small Shell Fragment	558
276.	Splintering of Tibia Caused by Small Shell Fragment	559
277.	Contact Fracture of Fibula Caused by Small Shell Fragment	559
278.	Contact Fracture of Tibia by Large Fragment of Shell	560
279.	Grenade Wound of Tibia Showing Grenade Fragments	561
280.	Bridged Plaster Applied for an Infected Gunshot Wound of the Leg	562
281.	Parker Suspension Apparatus and Method of Application	563
282.	Cabot Posterior Wire Splint	564
283.	Author's Irrigation and Extension Splint for Fractures about Ankle-Joint	565
284.	Author's Irrigation Splint	566
285.	Gutter Wound of Foot Caused by a Deflected Bullet	567
286.	Bullet Wound of Humerus on Admission and Six Months after Operation	572
287.	Shell Wound of Tibia with Much Comminution	574
288.	Radiogram of Skull Showing Retained Metallic Foreign Body	583
289.	Diagram Showing the Position of the Lateral Ventricle	585
290.	Diagram Showing the Relation of the Various Parts of the Brain (*De Martel*)	586
291.	Bone Flap Method of Treatment of a Gunshot Wound of the Brain (*De Martel*)	591
292.	The Use of the Cranial Perforator (*Cushing*)	592
293.	The Use of the Cranial Burr (*Cushing*)	593
294.	The Use of the Montenovesi Forceps (*Cushing*)	594
295.	Removal of an Area of Cranial Injury (*Cushing*)	595
296.	Example of a Gutter Wound, Showing Partial Closure after Operation	596
297.	Cerebral Damage in a Gutter Wound (*Cushing*)	597
298.	Small Penetrating Type of Cranial Wound (*Cushing*)	598
299.	Diagrammatic Sketch of the Cerebral Damage Due to Penetration by a Metallic Foreign Body (*Cushing*)	599
300.	The Tripod Incision (*Cushing*)	600
301.	A Block of Bone Removed from a Case of Gunshot Wound of the Head	601
302.	A Block of Bone Removed with the Foreign Body and Three Bone Fragments	602
303.	The Catheter Method of Cleansing the Wound Track (*Cushing*)	603
304.	The Use of the Carrel-Gentile Syringe with a Catheter for Suction (*Cushing*)	604
305.	A Cranial Wound Which Had Been Left Widely Open at Operation	605
306.	The Use of a Nail and Magnet in Removing a Metallic Foreign Body	606
307.	Through-and-Through Wound of the Brain	607

FIG.		PAGE
308.	A Healing Abscess Track	609
309.	Method of Dressing a Cerebral Hernia	611
310.	Hernia Three Weeks after Operation	612
311.	The Same Patient Three Weeks Later	612
312.	Apparatus for Immobilizing Intra-oral Splints, Nasal Splints, or Facial Supports (*Kazanjian*)	618
313.	Prosthesis for Replacing a Loss of Bone in the Lower Jaw (*Kazanjian*)	619
314.	Indirect Bone Graft for the Repair of a Defect of the Symphysis of the Jaw	632
315.	Pedicled Flap from the Neck for the Repair of the Soft Tissues	633
316.	Pedicled Flap from the Cheek for the Repair of the Soft Tissues	634
317.	Pedicled Flap from the Forehead for the Repair of the Soft Tissues	635
318.	Pedicled Flap from the Forehead for Replacing a Defect of the Orbit and Lower Lid	636
319.	Flap from the Forehead with a Pedicle of Subcutaneous Tissue Containing the Temporal Artery and Vein (*Horsley*)	637
320.	Tubular Flap for Repairing a Defect of the Orbit and Lower Lid	638
321.	Esser's Plan of Obtaining a Combined Neck and Cheek Flap for Defects above the Oral Fissure	639
322.	Repair of a Defect of the Cheek and Lower Lip	643
323.	Repair of an Extensive Injury Due to a Burn (*Schaeffer*)	644
324.	Repair of a Defect Involving the Full Thickness of Both Lips	651
325.	Restoration of the Angle of the Mouth	652
326.	Restoration of the Angle of the Mouth	652
327.	Restoration of the Angle of the Mouth	653
328.	Repair of a Circular Defect of the Face	654
329.	Repair of a Circular Defect Involving the Lower Lip	654
330.	Repair of an Extensive Defect of the Lower Lip and Chin by Burrow Stewart's Operation	655
331.	Reconstruction of the Upper Lip by Burrow Stewart's Method	656
332.	Repair of an Ectropion of the Lower Lip Due to a Burn	657
333.	Restoration of the Upper Lip by Cheek Flaps	658
334.	Closure of a Defect of the Palate by Approximating Mucoperiosteal Flaps	659
335.	Repair of a Defect of the Palate by a Pedicled Flap of Skin and Platysma from the Neck	660
336.	Repair of a Defect of the Forehead and Eyelid by a Pedicled Flap	661
337.	Sheep's Lung Five Weeks after Ligation of the Artery Supplying the Left Upper Lobe	666
338.	Sheep's Lung Five Months after Ligation of the Artery Supplying the Inferior Margin of the Left Lower Lobe	668
339.	Experimental Splenization in a Dog's Lung	
340.	Patient in Position for Operation	683
341.	Method of Exposing a Rib for Resection	684
342.	A. Simple Type of Rib Shears. B. Bone Biting Forceps for Use in Chest Surgery	685
343.	A. Tuffier's Rib Spreader. B. Thin Bladed Clamp Used to Secure Hæmostasis, and as a Tractor	686
344.	Thoracotomy of Election	687

FIG.		PAGE
345.	A. Cow Horn Rib Stripper. B. Tuffier's Lung Forceps. C. Periosteal Elevator	688
346.	Incision for Exposure of the Phrenic Nerve	689
347.	Exposure of the Phrenic Nerve	690
348.	Lacerated Wound of the Lower Lobe of the Lung	
349.	Thoracotomy of Election	693
350.	Methods of Reducing the Number of Stitches Used in Repair after a Resection	694
351.	Closure of the Chest Wall after Thoracotomy	695
352.	Inner Aspect of the Chest Wall of a Fatal Case of Purulent Pleurisy	696
353.	Closure of the Chest Wall after Thoracotomy. First step	697
354.	Closure of the Chest Wall after Thoracotomy. Second step	698
355.	Closure of the Chest Wall after Thoracotomy. Third step	699
356.	Closure of the Chest Wall after Thoracotomy. Fourth step	700
357.	Closure of the Chest Wall after Thoracotomy. Fifth step	701
358.	Closure of the Chest Wall after Thoracotomy. Sixth step	702
359.	A. Trochar, Cannula, and Catheter for Intercostal Drainage. B. Flap Valve Used to Secure Automatic One-Way Drainage	704
360.	Form of Trap to Be Attached to a Catheter Drain	706
361.	Device for Warming Patient in Shock (*Allison*)	750
362.	Thomas Traction Leg Splint	751
363.	Hinged Modification of Thomas Leg Splint	752
364.	Canvas Anklet and Traction Bands	753
365.	Collins' Hitch	754
366.	Nail Twister or Spanish Windlass	755
367.	Stretcher Cradle for Transport	756
368.	Hinged Traction Arm Splint	757
369.	Long Liston Splint for Stretcher Transport	758
370.	Cabot Posterior Wire Leg Splint	759
371.	Cabot Leg Splint with Posterior and Lateral Splints of Ladder Splinting Material	760
372.	Ladder Splint Material	761
373.	Débridement. Excision of external wound	762
374.	Débridement. Excision of aponeurotic layer	763
375.	Débridement. Excision of injured muscle	764
376.	Change of Position of Wound Track Resulting from Changed Position of Limb	765

SECTION I

THE GENERAL PREPARATION OF PATIENTS FOR GYNÆCOLOGICAL OPERATIONS

BY

HENRY RUSSELL ANDREWS, M.D., B.S. Lond., F.R.C.P.,
Obstetric Physician to the London Hospital

CHAPTER I

THE GENERAL PREPARATION OF PATIENTS

PREPARATION OF THE PATIENT FOR GYNÆCOLOGICAL OPERATIONS

THE preparation of the patient for a gynæcological operation should begin, if possible, forty-eight or thirty-six hours before the operation. The pulse-rate and the temperature should be noted on two or three occasions. The urine must be examined if this has not been done before. If the patient suffers from a cough the operation must be postponed for a few days at least. It is important that the bowels should be thoroughly emptied before the operation, as the amount of discomfort which the patient must suffer is increased if for any reason this preliminary preparation has been neglected, and there is no doubt that auto-intoxication may occur from a loaded intestine. When possible, an aperient should be given the last night but one before the operation; an enema of soap and water the night before the operation. If the preparation cannot be begun until the day before the operation, half an ounce to an ounce of castor oil should be given not later than 3 p.m., so that its action shall be over in time for the patient to get an undisturbed night's rest. It is sometimes necessary to give an enema on the morning of the operation, but it is best to give it not later than ten o'clock the night before, as an enema on the morning of the operation sometimes takes a good deal out of the patient. If the operation is not to be performed until the afternoon, there is no objection to the giving of an enema in the early morning. It is not enough that the bowels are opened, they must be opened several times in the forty-eight hours preceding the operation. If the patient suffers from chronic constipation, it may be necessary to devote several days to getting the bowels properly emptied. A dose of calomel may be given first and then a saline mixture given daily or castor oil on one occasion, the action of the drugs being assisted by a daily enema. In some cases it is necessary to give large enemata to irrigate the whole of the colon. If the patient is kept in bed for a couple of days or more before the operation, it is worth while to get her to practise passing a motion and passing water in a recumbent position.

The evening before the operation she should have a light dinner, consisting of soup, fish, and a simple pudding or jelly. Nothing should

be given for four hours before the operation, otherwise there will be a risk of vomiting during the administration of the anæsthetic. If the operation is to be performed at 9 a.m., the patient may be given a cup of tea or beef-tea at half-past four or five a.m. Some anæsthetists object to anything being given by the mouth, even at this interval before the operation, but experienced nurses are of opinion that the patient suffers more distress if she has not been allowed some form of nourishment during the early morning. If she is very thirsty, and complains of the dryness of her mouth before or after the injection of atropine, she may be allowed to wash out her mouth with water or soda-water, but urged not to swallow any. If patients are warned that swallowing fluids a few hours before the operation entails vomiting afterwards, they usually submit. If the patient is nervous, and does not seem inclined to go to sleep on the night before the operation, an hypnotic drug—such as bromidia or trional—should be given. Most anæsthetists like a hypodermic injection of gr. 1/100 of atropine to be given not more than an hour and not less than half an hour before the operation, and some of them like ¼ gr. of morphine to be added. Before the operation the legs should be wrapped in cotton-wool, and bandaged from the toes to the thighs. In cold weather a cotton-wool or Gamgee jacket should be worn. If the patient's chest is wrapped up very warmly during the operation in hot weather, there is some risk of chill after the operation, unless this is carefully guarded against, resulting in the so-called ether-bronchitis or pneumonia.

If the patient is nervous the anæsthetic should be administered in a room adjoining the room or theatre in which the operation is to be performed, and not in the theatre itself. If this is impossible, the couch should be screened, as the sight of the operator and his assistants in modern operating garb, the instrument-tables, &c., even when covered with towels, may be startling and distressing to a nervous patient.

A gynæcological operation should not be performed during a menstrual period, unless postponement is considered to be dangerous. Probably all operators would agree with this statement in the case of vaginal operations, but there is a difference of opinion as to the necessity for postponing an abdominal operation if a menstrual period occurs just before the date chosen for the operation.

In a case where it is likely that vaginal drainage will have to be adopted, e.g. cases of thin-walled suppurating ovarian cysts, large pyosalpinx, &c., and before an operation which involves opening both the abdominal cavity and the vagina, such as panhysterectomy, the vagina should be prepared in the manner described under the heading 'Preparation for Vaginal Operations.'

PREPARATION FOR ABDOMINAL OPERATIONS

The preparation should be begun, if possible, as long as thirty-six hours before the operation. The pubic hair should be shaved, and the patient should take a warm bath on the last night but one before the operation. After this the skin of the abdomen should be thoroughly scrubbed by the nurse with gauze and soap and water, special attention being paid to the umbilicus and any folds of skin in a fat patient. In the case of a really dirty patient, it may be necessary to use ethereal soap solution or turpentine, short of causing soreness of the skin. On the evening before the operation, the skin of the abdomen is painted with a 2 per cent. solution of iodine in rectified spirit. The abdomen is then covered with sterilized gauze or wool, and a many-tailed bandage applied. This painting is repeated when the patient is under the anæsthetic. If the preparation can only be begun the night before the operation, the patient should have a dry shave if possible. If the nurse cannot manage this, and soap has to be used in the shaving, the skin should be painted with acetone afterwards, and a few hours later painted with the iodine solution. The reason why a dry shave is advocated is that the iodine solution is much less efficacious if it is applied to skin which has been wetted during the previous ten or twelve hours.

The bladder should be emptied with a catheter just before the operation. Some operators consider that, unless there is some special indication present, it is best to dispense with the use of a catheter, as the patient may be more likely to suffer from retention of urine after the operation if a catheter has been passed before. In the writer's opinion this risk is so small as to be negligible. Whether a catheter is passed as a routine measure or not, it *must* be used in cases where there has been retention of urine or difficulty of micturition, as, for example, in the case of fibroids, especially those situated in the cervix or low down in the body of the uterus. If a catheter is not passed in these cases, there must be a risk of the bladder being wounded when the abdominal incision is made, and, apart from this, the operator will be hampered by the presence of even a small quantity of urine in the bladder. In the writer's opinion, a catheter should be passed just before the administration of the anæsthetic when any operation is to be performed involving the lower abdomen. The nurse may be satisfied that the patient has emptied her bladder naturally, but it may be found that there is half a pint or more in the bladder when the abdomen is opened. It is possible that the patient's nervousness leads her to secrete urine rapidly just before the operation.

PREPARATION IN EMERGENCY CASES

There is usually time for an enema to be given, and this should always be done if possible. In cases of extra-uterine pregnancy, suppurating ovarian cysts, &c., the iodine method of preparation of the skin is especially useful, as it does not entail any scrubbing of the skin of the abdomen. If the skin is scrubbed with soap solution, water, ether, solution of biniodide of mercury in spirit, &c., much more time is taken up, and there must be a risk of starting fresh intra-abdominal hæmorrhage, and even of rupture of thin-walled sacs. Union by first intention is nearly always secured by a thorough painting with iodine solution, even when no sort of preliminary preparation of the skin of the abdomen has been made.

PREPARATION OF FEEBLE PATIENTS

If the patient is feeble and anæmic, rest in bed for a week or two before the operation is to be advised, especially if she is poor and insufficiently fed. In hospital practice some patients—most often those suffering from uterine fibroids or from carcinoma—arrive in such a debilitated condition that immediate operation is contra-indicated. Such patients should be kept in bed for a fortnight or three weeks, with careful feeding, regular sleep, and the administration of a bitter mixture containing strychnine, and of some preparation of iron. The improvement in a debilitated hospital patient after a week or two of this 'building-up' treatment is often astonishing.

OPERATIONS PERFORMED DURING PREGNANCY

In these cases violent purgation is to be avoided. If the patient is constipated, four ounces of olive oil should be administered per rectum a few hours after the castor oil has been given by mouth, followed by an enema of soap and water. If vaginal douches are given as a routine measure before abdominal operations, they should be omitted in the case of a pregnant woman. A quarter of a grain of morphine should be injected half an hour before the operation. If these precautions are taken, abortion or premature labour is unlikely to occur as the result of an operation.

PREPARATION FOR VAGINAL OPERATIONS

The complete preparation of the vagina cannot be carried out until the patient is under the anæsthetic. A douche containing 20 minims of lysol to a pint of water should be given the night before, and repeated

on the morning of the operation. The vulva must be shaved the night before. Most nurses find that a 'safety' razor is much easier and safer to use than an ordinary razor. After the shave, the vulva, perineum, anus, and the surrounding skin are thoroughly washed with gauze and soap and water or lysol solution, special attention being paid to any folds. After this preliminary cleansing, the parts should be thoroughly swabbed with a solution of perchloride of mercury, 1 in 2,000, and then covered with sterile gauze kept in position by a T-bandage. After defæcation or micturition, the swabbing is repeated. If a catheter is not passed before the administration of the anæsthetic in these cases, it can be passed when the patient is anæsthetized, as part of the final preparation. When the patient has been anæsthetized the vaginal walls are scrubbed gently but thoroughly with pads of sterile gauze or wool soaked in soap solution, then washed with plain water, followed by a solution of 1 in 1,000 biniodide of mercury in spirit, and lastly with a weak watery solution of biniodide or perchloride of mercury, or douched with saline solution or some other non-irritating solution. In a parous woman the pads of gauze or wool can be held in gloved fingers, in a nullipara they should be held in sponge-holder forceps, otherwise the upper part of the vagina cannot be swabbed thoroughly without an unnecessary amount of laceration of the vulval orifice.

PREPARATIONS FOR SPECIAL OPERATIONS

1. **Vesico-vaginal fistula.** If there is cystitis the operation must be postponed until this is cured. If there is much soreness and excoriation due to constant soaking of the skin and mucous membrane with urine, the patient must be kept in bed for a few days, and the condition treated by suitable applications, such as bathing with lead lotion, dusting with starch and boric powder, &c. The bladder must be washed out with saline solution before the operation. This is usually done under the anæsthetic.

2. **Repair of a ruptured perineum.** If the bowels are not thoroughly emptied before this operation there is likely to be a leakage of fæces during the operation, which is exceedingly unpleasant even though it does not necessarily interfere with healing. The passage of hard scybalous masses the first time the bowels are opened after the operation will endanger the rectal sutures and may cause the formation of a recto-vaginal fistula. The presence of hard scybala is a proof that the bowels were not emptied thoroughly before the operation. No aperient should be given within the 36 hours before the operation, or there may be some leakage during the operation. The bowels should be

well opened for several days before the operation, an aperient should be given on the last night but one, an enema the night before, and a rectal wash of saline solution on the morning of the operation. If the preparation cannot be begun until the day before the operation several enemata should be given.

3. Operations for prolapse of the uterus or vaginal walls. In cases of prolapse in which the mucous membrane of the protruding cervix or vaginal walls has become scaly and thickened or ulcerated the patient should be kept in bed for several days, the procident parts being reduced and kept in place, if necessary, by tampons. Ulceration can be cured by douches of lead lotion if slight, by application of silver nitrate followed by douches if severe. If an operation is performed while the mucous membrane is thickened, œdematous, or ulcerated, healing by first intention is unlikely to occur.

4. Cases in which a tent has been inserted. The aperient should be given before and not after the insertion of the tent, as there is a possibility of the tent being expelled when the bowels act. In these cases an enema should be given on the morning of the operation, as it does not matter much if the tent comes out just before the operation. A morphia suppository should be inserted into the rectum directly after the introduction of the tent, otherwise the patient, especially if nulliparous, may be unable to sleep on account of pain.

SECTION II

THE AFTER-TREATMENT, RISKS, AND SEQUELÆ OF ABDOMINAL GYNÆCOLOGICAL OPERATIONS

BY

SIR JOHN BLAND-SUTTON, F.R.C.S. (Eng.), Lieutenant-Colonel R.A.M.C.(T.)
Surgeon to the Middlesex Hospital

CHAPTER I

THE AFTER-TREATMENT OF ABDOMINAL OPERATIONS

THE performance of ovariotomy, hysterectomy, and allied procedures is attended by several risks, immediate and remote, which may spoil the best-planned and most carefully executed operation. Some of these may be avoided by careful attention to the details embraced by the phrase 'after-treatment.'

The patient is returned to the bed with gentleness and usually lies on her back, but many anæsthetists prefer to turn the patient on one or other side for an hour, until there is a fair return to consciousness. The patient then lies on her back and a pillow is placed under the knees. Hot-water bottles should not be placed in the bed with the patient until she is completely conscious, and they are rarely needed. The healing of blisters caused by hot-water bottles is a slow process. During the first twelve hours the patient complains of pain, thirst, and vomiting.

The thirst is in a measure relieved by administering six or eight ounces of normal saline solution by the rectum an hour after the patient returns to bed, and repeating it in three or four hours. The patient may wash her mouth out frequently with water, hot or cold, according to her fancy, and if there is no vomiting she may swallow a little hot water from time to time. As a rule, it is better for her to abstain from swallowing anything for the first eighteen hours; the best way to avoid vomiting after an anæsthetic is to keep the stomach empty.

There is always some pain after an abdominal operation, partly due to tension on the sutures, and colic. The injection of normal saline solution (a teaspoonful of salt to a pint of water) by the rectum often controls this, but occasionally the pain is so severe that it is necessary to give a quarter of a grain of morphine hypodermically, or in a suppository, about twelve hours after the operation, in order to procure sleep. The routine use of morphine after these operations is injudicious and rarely necessary.

At the end of twenty-four hours small quantities of barley-water, tea, or milk and water are given, and if retained they may be taken in increasing quantities. On the fourth day an enema is given to clear the bowel and then the patient will take fish, chicken, &c., and soon get on to convalescent diet.

When vomiting is very troublesome, it is sometimes necessary to keep a patient on rectal feeding two or three days.

When there is abdominal distension, this may be relieved by the passage of a rectal tube at intervals of three hours, and if this fails a turpentine enema should be given.

Patients should always be encouraged to empty their bladder naturally: many are unable to pass water whilst lying on their backs. In these cases the urine is drawn from the bladder by a carefully sterilized glass catheter. Before passing the catheter, the nurse carefully wipes away the mucus from the urethral orifice. Cleanliness and care with the catheter must be enforced: cystitis causes much misery. During the first few days the quantity of urine passed by the patient is measured, and recorded in the note-book.

The temperature should be observed every four hours during the first week and recorded. The first record after the operation is usually subnormal, and in twelve hours it rises to normal and beyond. During the first twenty hours it may rise to 100° without causing alarm; beyond this, if accompanied by a rapid pulse, an anxious face, and distended belly, it will cause anxiety to the surgeon. A temperature of 101° or 102° unaccompanied by other unfavourable symptoms is not a cause for alarm, unless maintained.

The state of the pulse is a valuable guide and more trustworthy than the temperature. When the pulse remains steady and full there is no cause for alarm. When it increases in frequency to 120 or 130 beats per minute, and is thin and thready, then there is danger, even if the temperature is only slightly raised.

On the seventh or eighth day the sutures will require removal. Occasionally a hæmatoma forms in the wound; and in patients in whom the operation has been performed for septic conditions, stitch abscesses will occur. In septic cases the sutures require to remain a few days longer, to allow the wound to unite more securely.

When oöphorectomy, ovariotomy, or hysterectomy is followed by a non-febrile convalescence the patient may be allowed to leave her bed on the fourteenth day, and at the end of another week she may return to her home or go to the seaside according to circumstances. When the wound has healed by primary union, and this is usual where aseptic methods have been followed and buried sutures employed for the fascial and muscular layers, an abdominal belt is unnecessary. When suppuration has taken place in the wound and healing has been retarded, especially in a patient in whom operations have been performed for septic conditions, it is a useful precaution to advise her to wear a well-made belt. This is more necessary for women who have to get their living by hard work.

CHAPTER II

COMPLICATIONS OF ABDOMINAL GYNÆCOLOGICAL OPERATIONS

Metrostaxis. After ovariotomy and oöphorectomy, unilateral or bilateral, blood sometimes escapes from the uterus in the course of the first week and simulates menstruation: it sometimes occurs within forty-eight hours of the operation, and is usually ushered in with a rise of temperature (100°–101°).

Bed-sores. These sometimes give trouble when operations are performed on elderly or enfeebled patients, especially when they are thin and have incontinence of urine. With due watchfulness and care on the part of the nurse, a bed-sore ought rarely to occur.

Post-anæsthetic paralysis. Paralysis following operations on the pelvic organs occurs in connexion with the upper and lower limbs; it is an awkward and avoidable complication. Some of the simplest cases are those which arise from the pressure upon an individual nerve, such as the ulnar, circumflex, or radial, due to the arm coming in contact with the sharp edge of a metal operating table. When the patient's legs are flexed across the sharp edge of the table and fixed, as in the Trendelenburg position, during a long operation, the common peroneal nerve is liable to be compressed and the muscles supplied by it paralysed. In some instances the paralysis is bilateral. Paralyses of this kind are identical with what are known as 'sleeping palsies.' The more serious paralyses are directly due to the Trendelenburg position, in which there is a great tendency for the arms to be displaced over the head and hang downwards, or abducted, as this position causes the clavicle to compress the nerves of the brachial plexus upon the first rib, or the scalenus anterior muscle, and perhaps, as some observers believe, between the clavicle and the transverse processes of the fifth and sixth cervical vertebræ.

Most of the writers on this subject attribute the paralysis more particularly to drawing the head to one side when the patient lies in the Trendelenburg position with the abducted upper limbs, as it tends to stretch the lower cervical nerves of the opposite side, especially the fifth. This stretching is probably a greater factor in producing paralysis than pressure.

The form of paralysis produced in this way is that known as Erb's palsy, and the muscles particularly concerned are the deltoid, brachialis anterior, biceps, and the brachio-radialis. Sometimes the spinati are involved. Occasionally the paralysis is bilateral. A case has been reported in which there was a total lesion of the brachial plexus, including the muscles of the shoulder girdle.

The following case serves to show that stretching rather than pressure is responsible for this class of paralyses. A patient had undergone a vaginal operation in the crutch position, when the assistant drew her along the table by means of his fingers hooked in the axillæ over the folds of the pectoral muscles: next morning both upper limbs were found to be paralysed, and they remained in this condition many weeks.

In some of the lighter forms the paralysis passes off in a few days, but cases are known in which it has persisted for many months, and as it renders the limb useless for a time it is a serious matter.

Halstead refers to a case of bilateral peroneal paralysis following salpingectomy in the Trendelenburg posture which disabled a patient for six months.

On the whole, prognosis is favourable, and recovery the rule.

Büdinger has described a case in which the upper limb was paralysed after an abdominal operation. The patient died some weeks later, and a clot of blood was found pressing on the surface of the brain at a spot corresponding to the arm centre.

References

Büdinger. Über Lähmungen nach Chloroformnarkosen. *Archiv f. klin. Chir.* 1894, Bd. xlvii. 121.

Cotton, F. J., and Allen, F. W. Brachial Paralysis—Post-narcotic. *Boston Med. and Surg. Journal,* 1903, cxlviii. 499.

Halstead, A. E. Anæsthesia Paralysis. *Surgery, Gynæcology, and Obstetrics,* 1908, vi. 201.

Turney. Post-anæsthetic Paralysis. *Clinical Journal,* 1899, xiv. 185.

Giving way of the wound. After cœliotomy the patient runs a risk of the wound being burst open, and this accident seems particularly liable to happen in cases where catgut has been selected for the suture material. Accidents of this kind belong to two categories:—

1. Many cases occur in patients from violent coughing or vomiting, as the straining causes the knots of the sutures to slip.

2. In feeble patients, and those debilitated by anæmia, diabetes, &c., and especially in septic wounds, the union of the edges of the incision

occurs very slowly; if the sutures are taken out on the eighth day, as is the custom, the wound is liable to burst asunder. This accident is prone to occur. in patients whose abdominal wall has been greatly distended by a large tumour, and especially by pregnancy. On the whole, the accident is more liable to complicate Cæsarean section than any other operation on the pelvic organs, and cases have been reported in which there has been a repetition of the accident. The largest collection of case-reports in which the wound has burst open after cœliotomy has been made by Madelung; a perusal of his paper shows that it is an accident with a high mortality. It is a fact that cases of this kind are rarely published, and from inquiries I find that it is of common occurrence. It has certainly diminished since surgeons have widely adopted the method of securing the wound with buried suture, but this is not always a preventive. The complication which makes the accident so unfortunate for the patient is the protrusion of the intestines (see p. 20).

In dealing with this condition the surgeon carefully and gently cleans the extruded intestines and omentum with sterilized water, returns them into the abdomen, and re-sutures the wound.

REFERENCE

MADELUNG, O. Ueber den postoperativen Vorfall von Baucheingeweiden. *Verhandlung. d. Deutschen Gesellsch. f. Chir.*, Berlin, 1905, xxxiv, 2. Theil, p. 168.

Hæmorrhage. However carefully an operation may be conducted, or whatever material may be employed for ligatures, there is a liability of bleeding after the patient has been returned to bed. Severe internal bleeding is usually due to the slipping of a ligature from an ovarian pedicle, or a uterine artery: it may come from a vaginal artery, especially in total hysterectomy, and occasionally from a vessel in an adhesion which has been missed in the course of the operation, for oozing which is scarcely appreciable when a patient is collapsed may become very free when reaction occurs.

Severe internal bleeding is manifested by very obvious signs: pallor, cold skin, rapid but feeble pulse, restlessness, and sighing respiration. When these symptoms are manifested the wound must be reopened, the blood and clot removed, and the bleeding-point secured. It often happens, where the bleeding is due to the slipping of a ligature from the uterine or ovarian artery, that by the time the surgeon reopens the wound the patient is so bloodless that there is difficulty in determining the source of the bleeding. In very bad cases it is a wise plan to

arrange for an assistant to perform the intravenous infusion whilst the surgeon deals with the bleeding vessel.

Intravenous injection is the best method of treating patients when the loss of blood has been great. It is unwise to transfuse more than three pints into the veins, or the lungs will become waterlogged and the patient will be later in great peril. When the loss is moderate in amount and the patient is not greatly enfeebled, a pint or more of saline solution may be poured into the abdomen before closing the incision, and this may be supplemented by the administration of six or more ounces of the solution by the anus at two-hourly intervals until the force of the circulation is restored.

In some instances the subcutaneous injection of normal saline solution may be employed. A suitable region is the loose tissue under and around the breasts. When this method is adopted the skin should be rendered antiseptic, otherwise troublesome abscesses and cellulitis will arise in the subcutaneous tissue at the situation where the saline solution has been injected.

Intrapelvic hæmorrhage. For many years I have maintained that two factors which have enabled hysterectomy to vanquish oöphorectomy in the treatment of uterine fibroids are *rigid asepsis* and *perfect hæmostasis*. In the early days of intrapelvic surgery there used to be much discussion on the subject of free blood in the pelvic cavity: some practical surgeons urged that it was harmful and would induce peritonitis, and others took the opposite view. From my own observations I came to the conclusion that effusions of blood in the abdomen were often quickly absorbed, but that this was not invariable; and that post-operative collections of blood were very liable to become septic, especially when drainage was employed. I also pointed out that the large effusions of blood in the abdomen due to tubal abortion, or to the rupture of a gravid tube, are often attended with fever, and in some instances the temperature rises to 103°. In such cases, when operative interference is undertaken, the deliquescent clot present in the pelvis often gives off a musty odour. Much light has been thrown on this condition by Dudgeon and Sargent, who have specially investigated the bacteriology of intraperitoneal effusions. These observers have isolated from intraperitoneal effusions of blood a white staphylococcus, which makes its appearance in the blood within a few hours of being effused, and they are of opinion that the febrile disturbances so frequently found after effusions of blood into the peritoneal cavity are due to the presence of this organism.

Apart from the pathological importance of these observations, there is a point of practical value connected with them. The white staphylococcus will infect sutures and give rise to stitch-abscesses in the wound;

in view of this fact it behoves the surgeon who has to deal with a stale effusion of blood in the pelvis and evacuates it by an incision through the abdominal wall, that in closing the incision he should employ through-and-through sutures, and not attempt to suture it layer by layer.

Pneumonia. This is a serious and not infrequent sequel of cœliotomy, especially when it concerns diseased conditions in the upper half of the abdomen; pneumonia occurs frequently as a sequel to ovariotomy, hysterectomy, and allied operations, and occasionally has a fatal ending. It may arise from inhalation, or may be due to the dorsal position (hypostatic pneumonia), or it may arise from infection.

Inhalation pneumonia is not uncommon, and although it is often attributed to the anæsthetic, especially ether, it is doubtless due to a combination of causes, such as a cold room, undue exposure of the body, septic teeth, the chilling effects of ether on the tissues of the lung, and occasionally to a dirty face-piece belonging to the ether or chloroform apparatus.

Hypostatic congestion of the lungs is liable to occur in the aged and in debilitated patients; it is a complication in such cases always to be guarded against.

Embolic pneumonia is the most serious form, and occurs as a sequel to operations for septic conditions, such as uterine cancer, suppurating ovarian cysts, septic fibroids, and post-operative sepsis; it is also associated with thrombosis, especially when the pelvic veins contain septic clot.

In the preceding section attention was drawn to the appearance in intra-abdominal blood effusions of a white staphylococcus: such collections of blood are prone to decompose and cause the temperature to rise.

On several occasions in which blood has been effused freely into the pelvic cavity, either as a consequence of tubal pregnancy, or as a sequel to an operation, such as an abdominal myomectomy, and the blood has been allowed to remain, or it has been inefficiently drained, the patients have died from septic pneumonia.

In cases of septic thrombosis the patients run a definite risk from pulmonary embolism. When the embolus is large the patient sometimes dies in a few minutes (see p. 22); but even in cases where the embolus is too small to promptly destroy the patient's life, its lodgement in the lungs entails in some instances a very serious illness, and occasionally a fatal termination.

Parotitis. Septic parotitis, or, as it is sometimes called, symptomatic or secondary parotitis, to distinguish it from mumps, is an occasional sequel to abdominal operations of all kinds. Careful observations have shown that parotitis is more common after operations for septic

conditions, and, although it occasionally occurs after operations which run an afebrile course, the conditions underlying it are mainly septic in character.

Septic parotitis is distinguished from mumps in the following points:—

It occurs as a complication of some other affection, is in itself non-contagious, and occasionally suppurates. There are two views held in regard to its ætiology: some hold that it is due to direct infection of the duct (Stenson's) of the parotid gland by micro-organisms from the mouth, whilst others maintain that the path of infection is mainly by the blood-stream.

Two able investigations have recently been published in regard to this condition, in which one writer (Bucknall) supports the view that it is an ascending affection from the mouth, and the other (Tebbs) brings forward evidence that the elements of infection reach it by the blood-stream.

Lequeu has seen many cases of post-operative parotitis, and at his suggestion Verliac and Morel investigated the condition in the laboratory. They came to the conclusion that this variety of parotitis originates in the duct of the gland.

When parotitis complicates post-operative convalescence, it is almost entirely confined to septic cases: it may occur within two days of the operation or as late as the thirtieth day. It is more common between the sixth and tenth days, and its advent is accompanied by much disturbance. The parotid swells and becomes painful and tender; the skin over it is red and often brawny. These signs are accompanied by fever, malaise, and depression of spirits. In mild cases they subside in a few days, but in severe cases rigors occur, with high fever and suppuration.

The mild cases are best treated with warm fomentations, frequently changed. If suppuration occurs, the pus will need to be evacuated by a scalpel, but incisions in a suppurating parotid gland should be carried out with careful regard to the branches of the facial nerve (pes anserinus), and the large vessels intimately associated with it.

The surgeon need not be in a great hurry to use the scalpel in these cases, for it seems occasionally as if the skin would slough, and yet when it is incised no pus escapes. This septic parotitis is deceptive in the red and brawny appearance of the skin covering the swollen gland, and the misleading sense of fluctuation. In many instances the inflammatory products escape by way of the parotid duct.

Septic parotitis is an unpleasant and painful complication of an abdominal operation, but it is rarely dangerous and has only had a fatal termination in very exceptional cases.

References

Bucknall, R. The Pathology and Prevention of Secondary Parotitis (with Literature). *Med.-Chir. Trans.*, 1905, lxxxviii. 1.

Lequeu. Sur les parotidites post-opératoires. *Bull. et Mém. de la Soc. de Chir. de Paris*, 1907, T. xxxiii. 1044.

Tebbs, B. N. Symptomatic Parotitis. *Med.-Chir. Trans.*, 1905, lxxxviii. 35.

Post-operative thrombosis. A perusal of surgical and gynæcological periodical literature of all countries contains frequent references to thrombosis of the saphena, femoral, and iliac veins as a sequel to pelvic operations. It is usually noticed about the twelfth day, and its occurrence is intimated by fever, pain in the thigh and leg, quickened pulse, and gradually increasing œdema of the leg. When the signs and history of cases of post-operative thrombosis are carefully considered they can be arranged in two groups: in one the saphena vein is involved, in another the femoral and iliac veins.

The simplest conditions are those in which thrombosis is limited to the saphenous vein. The patient complains of pain in the groin and along the front of the thigh; often pain and tenderness are confined to the calf. The tenderness is mainly in the skin overlying the thrombosed vein. When the thrombosis is confined to the saphenous vein, the acute symptoms subside in ten or fourteen days. As a rule, it affects one limb, but when both become involved, the occurrence is usually consecutive.

In many instances the thrombosis attacks the femoral and external iliac veins, and I have come to the conclusion that thrombosis of these veins occurring as a sequel of abdominal hysterectomy is often due to infection of the abdominal incision, and the channels of infection are the inferior epigastric veins, superficial and deep, and the collateral lymph-vessels (Fig. 1).

Femoral thrombosis and fatal pulmonary embolism are recognized sequels of hysteropexy. In this operation if the retaining sutures are passed too deeply into the uterine wall they traverse the endometrium, and if it be septic the silk thread will be infected and cause trouble. A study of the facts led me to believe that the factors which produce the changes in the abdominal wound ending in thrombosis of the femoral, external iliac, or femoral veins are buried sutures. I made a series of trials in which a number of median abdominal incisions were closed with buried silk sutures, also a series of cases in which through-and-through sutures were employed. However carefully the silk is prepared and the sutures inserted with hands covered with sterilized rubber gloves, now and then a buried suture will give trouble. Even when the sutures appear

to settle down without disturbance they often cause trifling rises of temperature.

Surgeons who habitually employ catgut for buried sutures admit that the absorption of the catgut is accompanied by fever, but there is a serious objection to this use of catgut. During the period of its absorption the union between the apposed surfaces of the incision become softened, and any undue exertion on the part of the patient, such as

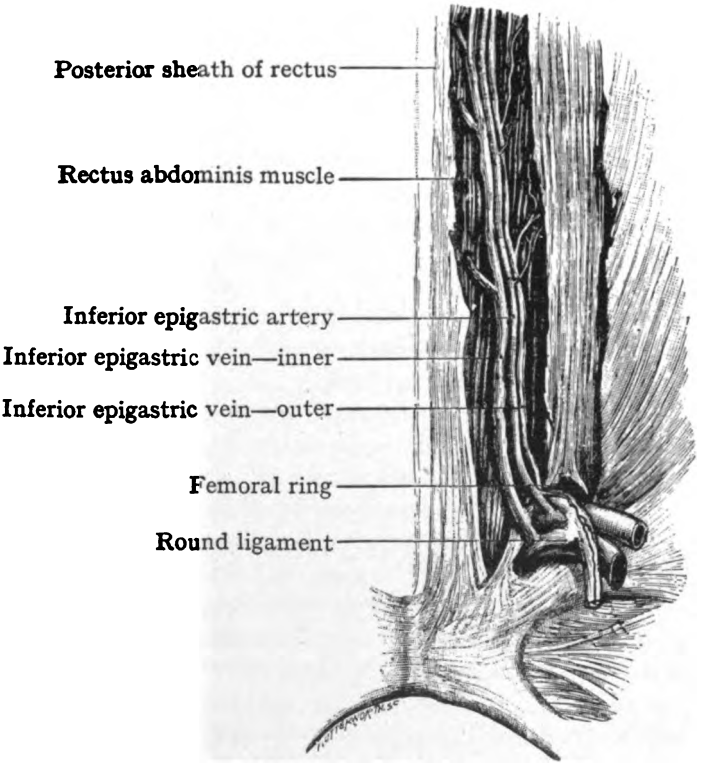

FIG. 1. POSTERIOR VIEW OF THE RECTUS ABDOMINIS MUSCLE BELOW THE LEVEL OF THE UMBILICUS. The origin of the inferior epigastric artery and the termination of the vein is shown.

coughing or straining, will cause them to separate and permit protrusion of the intestine. (See p. 17.)

The excessive frequency with which thrombosis occurs as a sequel of abdominal hysterectomy performed for cancer as compared with fibroids is another fact worth bearing in mind, for, as has been pointed out, cancer in the neck of the uterus often teems with streptococci, and these are notorious agents in causing thrombosis. When these things are

carefully considered and then compared with the comparative infrequency of thrombosis after vaginal operations, the evidence is strong that the excessive frequency of pulmonary embolism after abdominal hysterectomy is in a measure due to buried sutures becoming infected from the contaminated fingers of the surgeon.

The trifling modification in technique described on p. 108, consisting in applying tincture of iodine to the remnant of the cervical canal left in the stump, and to the cut surface of the stump, and thoroughly disinfecting the gloved hands in perchloride of mercury (1 in 5,000), before tying the uterine arteries and introducing the mattress sutures, has been followed by good consequences. The careful disinfection of the gloved hand should be repeated before suturing the wound.

The occlusion of the femoral and iliac veins by clot leads to solid œdema of the thigh, which gradually extends to the leg. This complication is often a serious matter for the patient, as it entails a long confinement to bed, a tedious convalescence, and the œdema will persist for many months, and occasionally impairs the circulation in the limb for several years, in spite of topical applications, careful bandaging, and judicious massage.

The œdema of the leg is usually attributed to obstruction of the femoral and iliac veins by clot, but the condition is not so simple, there is in addition lymphangitis. This associated plugging of the lymph vessels has probably a greater effect in producing the swelling of the leg than the obstruction caused by the intravenous clot. It is a frequent matter of comment, that the accident which so often has a tragic ending —the lodgement of an embolism in the pulmonary artery—occurs in patients when there has been no evidence of thrombosis, yet after death when the iliac veins are examined large thrombi are found therein.

During the time I was occupied in studying the effects of buried sutures in producing thrombosis, I buried no sutures in an abdominal incision for two years, except in one instance. During that period I had no post-operative thrombosis, and only one case of pulmonary embolism, and that happened to the patient in whom I used buried sutures. She was a midwife on whom I performed hysterectomy for a big submucous fibroid; and as she was a stout woman and led an active life, extra care was taken to secure a sound abdominal scar. She was making apparently an uneventful recovery until the eighth day; then her temperature rose without any warning to 103° Fahr. On examination, some hardness could be felt in the lower portion of the wound. There was no œdema and no tenderness in the groin, and no evidence of pulmonary complications. I warned my house surgeon that in all probability she had thrombosis of the deep veins, and there was impending danger of a pulmonary embolism.

She died suddenly a few hours later, and an embolus was found at the post-mortem examination firmly plugging the pulmonary artery.

EMBOLISM OF THE PULMONARY ARTERY AFTER HYSTERECTOMY

Although pulmonary embolism is common after abdominal hysterectomy, it is difficult to obtain reliable statistics because surgeons are reluctant to publish their experiences of this tragic sequel to an operation. There is sufficient evidence available to give some notion of the relative frequency of pulmonary embolism after hysterectomy for fibroids, and the following facts not only help in this direction, but show an extraordinary variation in the practice of different surgeons. For example: Baldy found that among 366 operations for fibroids in the Women's Hospital, Philadelphia, there were thirteen sudden deaths attributed to embolism. In the Middlesex Hospital in the years 1896–1906, both years inclusive, there were 212 abdominal hysterectomies for fibroids; three patients died from pulmonary embolism. At the New Hospital for Women, London, during 1901–1910, hysterectomy was performed for fibroids 189 times; two patients died from pulmonary embolism (Lepper). In the practice of individual surgeons the results differ widely. Lyle, among eight subtotal hysterectomies for fibroids, lost one patient from pulmonary embolism; Spencer lost two patients from this cause out of 85 total hysterectomies, and Olshausen five out of 366. Among 1,500 abdominal operations for fibroids I have lost three patients from pulmonary embolism, and in one of these women the fibroid was complicated with cancer of the corporeal endometrium.

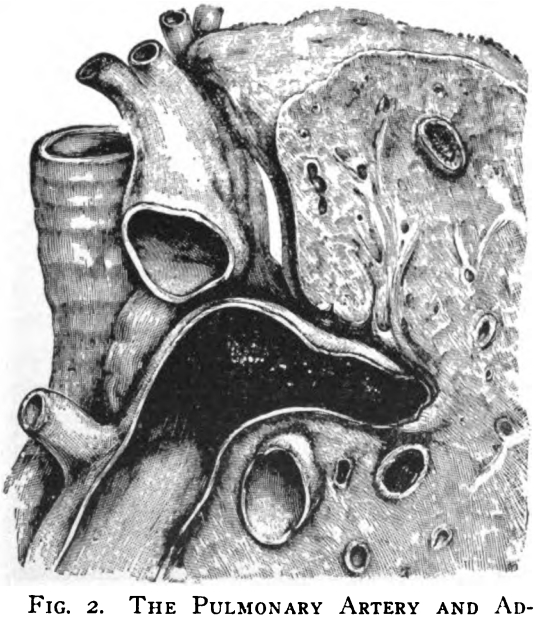

FIG. 2. THE PULMONARY ARTERY AND ADJACENT PART OF THE LUNG AND TRACHEA. The artery is completely occluded by a clot derived from a thrombus in the right auricle. (*Museum of the Middlesex Hospital.*) Three-quarter size.

A broad study of the statistics indicates that in the practice of some surgeons, fatal pulmonary embolism occurs in at least 1 per cent. of the patients who have abdominal hysterectomy performed for fibroids. This tragic mode of death is more frequent after total than after subtotal hysterectomy; it is a recognized sequel of hysteropexy, and the risk of its occurrence after abdominal hysterectomy for cancer is higher than for other pelvic operations.

In considering embolism of the pulmonary artery in relation to hysterectomy, it is necessary to point out that the pelvis contains two potential reservoirs of clot—the iliac and the ovarian veins; as a rule, the iliac veins are the common source of the fatal clot.

Before describing the mechanical occlusion of the pulmonary artery by an embolus, there are a few points worth consideration. This vessel has the structure of an artery, but conveys venous blood to the lungs; it has a greater diameter than any other artery, for the cross measurement above the sinuses of Valsalva is given by anatomists as 28 mm., so that a large clot is required to plug it effectually. An embolus large enough for this purpose comes, as a rule, from the inferior vena cava, or from a thrombus in the right auricular cavity, or from the iliac veins.

Often the pulmonary artery is found, at a post-mortem examination, completely blocked by an embolus, yet a careful examination of the venous system fails to reveal the source of the migratory clot. In these instances probably the whole of a clot formed in a vein of moderate size slips from its surroundings, and although an elongated thrombus may be too narrow to block the pulmonary artery, it may be doubled up by the blood-stream and form an effective plug. An embolus too small to occlude the pulmonary artery sometimes lodges on the ridge separating the right from the left branch; such a clot may act as an autochthonous thrombus and induce the propagation of additional clot which will fatally occlude the main trunk of the artery.

Pulmonary embolism may occur as a sequel of hysterectomy at any time from the hour of the operation onward to the thirtieth day. The majority of cases happen about the twelfth day; the detachment and transit of the clot is usually preceded by movement such as getting out of bed, sitting up in bed, but more particularly straining at stool. In one remarkable case, a woman complained of sciatic pain seventeen days after vaginal hysterectomy. To relieve this the surgeon flexed the patient's thigh on her abdomen and suddenly extended it. This dislodged a clot and the woman was seized with signs of pulmonary embolism and died in forty-seven minutes. At the post-mortem examination the pulmonary artery was found to be occluded and the left ovarian vein thrombosed (Byrom Robinson).

The most constant symptoms of pulmonary embolism are sudden, urgent dyspnœa, great pain in the chest, accompanied by agony and fear of death. 'Particularly striking is the contrast between the violence of the dyspnœa and the freedom with which the air enters the lungs, and in the absence of pulmonary physical signs' (Welch). As a rule, the face is blue and covered with cold sweat. Death may follow in a few minutes or it may be delayed several hours. The patient remains conscious, but suffers severe mental distress. On one occasion I saw a woman within ten minutes of the lodgement of an embolus in the pulmonary artery; she was livid and unconscious, and although she had ceased to breathe, her heart continued to beat regularly and forcibly for five minutes after my arrival, then stopped suddenly. A patient convalescent after hysterectomy, performed for fibroids, may be dressing to leave the hospital and fall dying across the bed, or on the floor of the ward, or in the courtyard of the hospital. Periodical surgical literature contains many instances of these dramatic forms of sudden death due to post-operative pulmonary embolism.

Occasionally a patient may rally after the most urgent symptoms; then, later, an extending thrombus or a fresh embolus will cause death. Recovery may occur even in very desperate cases. It is not uncommon for women recovering from hysterectomy to be seized with a sudden pain in the side of the chest severe enough to fill them with alarm: in a few hours the temperature rises perhaps to 102° or 103° Fahr., and there may be some blood-stained sputum ejected. The physical signs indicate a patch of pleurisy or pneumonia. Attacks of this kind are not fatal, but they occasionally delay convalescence: they are due to the arrest of small emboli in the pulmonary vessels. In some cases patients recovering from hysterectomy will exhibit signs which indicate that there has been a shower or a succession of small pulmonary emboli. The patients usually recover.

It has been suggested that the practice of keeping patients strictly confined to bed for two or three weeks after hysterectomy and allied operations is responsible for the thrombosis which is the source of these fatal emboli. Some American surgeons act on this suggestion and insist on their patients getting out of bed a few days after such operations. This method does not commend itself to British surgeons. In my own practice I make it a rule, even in the most favourable conditions, to keep the patients confined to bed for two weeks. No patient is allowed up until her temperature has been normal for at least three days. The consequences of this practice appear to be justified, for in my last thousand hysterectomies, only one of the patients lost her life in consequence of pulmonary embolism.

In cases of embolism of the pulmonary artery, death does not always occur immediately, but may be postponed for an hour or more after the lodgement of the embolus.

Trendelenburg is of opinion that it might be possible to remove the clot by direct surgical intervention. After careful consideration of the matter he carried out this operation on a woman aged sixty-three years; he raised an osteoplastic flap on the left side of the thorax, exposed the conus arteriosus and intended to withdraw the clot by means of a specially constructed pump, through a slit in its walls. The patient died from excessive bleeding before the clot could be extracted; the operation was hindered by an adherent pericardium.

Trendelenburg has carried out this operation on a man forty-five years of age. This patient was tabetic and sustained a spontaneous fracture of the femur. One month later he was seized with urgent dyspnœa and signs clearly indicating the lodgement of an embolus in the pulmonary artery. Trendelenburg exposed the heart, opened the pulmonary artery and by means of polypus forceps succeeded in withdrawing 34 centimetres of clot. The incision in the artery was carefully closed with sutures. The man improved considerably as the result of the operation, but died thirty-seven hours later. At the post-mortem examination the left and right branches of the pulmonary artery contained an embolus. From the surgical point of view there are no reasons why such a bold example should not be repeated with success.

References

Baldy, J. M. The Mortality in Operations for Fibroid Tumour of the Uterus. *Trans. Am. Gynecological Association*, 1905, xxx. 450.

Bartlett, W., and Thompson, R. L. Occluding Pulmonary Embolism. *Annals of Surgery*, 1908, xlvii. 717.

Bland-Sutton, J. Hunterian Lecture on Thrombosis and Embolism after Operations on the Female Pelvic Organs. *Lancet*, 1909, i. 147.

—— The Exotic Flora of the Uterus in relation to Fibroids and Cancer. *Brit. Med. Journ.*, 1913, i. 205.

Lyle, Ranken. A Series of Fifty Consecutive Abdominal Sections. *Journal of the British Gynæcological Society*, 1906–7, xxii. 120.

Robinson, B. Sudden Death, especially from Embolism, following Surgical Intervention. *Medical Record*, 1905, lvii. 47.

Spencer, H. R. Discussion at Exeter on Uterine Fibroids, &c. *British Medical Journal*, 1907, ii. 452.

Trendelenburg, F. Zur Herzchirurgie. *Zentralbl. für Chir.*, 1907, No. 44, 1302.

—— Ueber die chirurgische Behandlung der puerperalen Pyämie. *Münchener Med. Wochenschr.*, 1907, xxxiv. 1302.

Foreign bodies left in the abdomen. Every writer on ovariotomy and kindred operations insists on the importance of exercising the

utmost personal vigilance in counting instruments and dabs before and immediately after an abdominal operation in order to avert the dangers which ensue when instruments, dabs, gauze, or drainage tubes are accidentally left in the abdominal cavity. Before the era of antiseptic surgery nearly all the patients in whom foreign bodies were left in the abdominal cavity died. In several instances the surgeon has discovered, on counting the sponges and instruments after the operation, one or more to be missing, and, failing to find them in the room, has reopened the wound and recovered the missing article. In many lucky cases a sponge or compress has given rise to an abscess, the wound has reopened and the sponge presented at the opening. Often a compress of cotton-wool or gauze has slowly ulcerated into the rectum and been discharged through the anus.

When things of this kind are left in the abdomen the risks are not so great now as in pre-antiseptic days, but they cause much discomfort and anxiety as well as suffering: moreover, such an accident entails reopening the wound and occasionally a serious operation for the removal of the missing article, and as a recent decision in a Court of Law fixes the responsibility on the operator, there is always the possibility of an action at law with all its vexations and the liability of being mulcted in damages.

The behaviour of foreign bodies left in the abdomen is curious and also interesting from the great length of time which metal instruments will sometimes remain without causing very urgent symptoms, and the tendency they exhibit to penetrate adjacent viscera.

Among the early cases Sir Spencer Wells reported one in which a pair of forceps was found in a patient's bladder who died a month after ovariotomy. Olshausen mentions that a pair of forceps was passed by the rectum nine months after ovariotomy, and Terrillon tells of a pair of pressure forceps which remained eight months in the belly and came out close to the navel. One of the most remarkable instances is recorded by MacLaren, in which a pair of forceps was left in the abdomen in the course of a hysterectomy. Two years later, a swelling formed in the right iliac region; this was explored through an abdominal incision, and the hæmostatic forceps represented in Fig. 3 was found embedded in the omentum; the forceps had ulcerated into the cæcum and the blades were lodged in the vermiform process. The patient recovered.

In order to illustrate the diminished risks run by patients when the instruments and dabs used in operations are thoroughly sterilized, reference may be made to a case reported by J. E. F. Stewart (Australia), in which he removed a pair of pressure forceps which had remained in the abdomen for ten years and a half. The patient, who had been more or less an invalid since the primary operation, had suffered from attacks of acute pain, constipation alternating with diarrhœa, and pains in the

lower limbs. The instrument, which measured 5 inches long and 2½ across the handles, was lying point downwards in the pelvis, and the ring-handles could be felt through the belly-wall before the operation: it had made its way into the small intestine.

The tendency for a foreign body, whether hard like forceps, or soft like gauze pads, to erode its way into the intestine is very remarkable. Thus Gifford operated on a patient with intestinal obstruction: an impacted mass was felt in the ileum, it was extracted through an incision in the gut and proved to be a pad of cotton-wool enveloped in gauze. She recovered. Three months previously this woman had undergone abdominal myomectomy.

Doléris had a remarkable experience in 1912. A woman had her left uterine appendages removed and subsequently became pregnant. When labour began delivery was obstructed by a mass in the pelvis

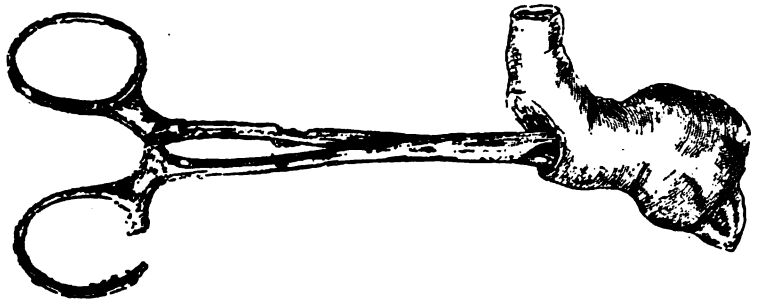

FIG. 3. A PAIR OF PRESSURE FORCEPS. This instrument had remained in the abdomen two years after hysterectomy. The forceps had ulcerated into the cæcum and the blades had lodged in the vermiform process. (*After MacLaren.*)

which felt like a tense ovarian dermoid. Cæsarean section was performed; in the course of the operation a gauze pad, six inches in diameter, was found in the pelvis, bathed in pus. The uterus was removed and the pelvic cavity drained.

Another source of risk to patients is the practice or habit of packing the pelvic recesses with strips of gauze temporarily, either with the hope of controlling oozing, or to serve as a drain. I have long abandoned this habit. The disadvantage of gauze stuffing which needs consideration in this section is the risk that some portion, or the whole of it, is sometimes left in the wound. Examples are known where long strips of 'gauze stuffing,' sometimes amounting to a yard or more, have been passed through the anus a year after the operation. Many intractable sinuses have had a forgotten piece of gauze as the cause of their persistence.

A woman had cœliotomy performed for peritonitis, the consequence of criminal abortion; she had a long convalescence due to an intractable sinus. Eventually the patient was thought to have tuberculous disease of the appendages, and a mass, formed mainly by the uterine tube, was removed; the walls of the tube were intact, but when slit open it was found to contain a small gauze tampon (Kouwer).

The isolated records relating to foreign bodies left in the abdomen are very numerous. Thus Wilson, in 1884, was able to collect twenty-eight cases from periodical literature and personal reports from friends. An interesting discussion took place on the reading of a paper on this subject before an American gynæcological society, by R. W. Waldo, and the number of cases related by the members is astonishing and refer to such things as sponges, dabs, forceps, a strip of iodoform gauze 'a yard wide and two yards long,' a pair of spectacles, and 'an operating-room towel,' which were left in the abdominal cavity.

The most comprehensive collection of records relating to foreign bodies left in wounds of all kinds has been made by F. von Neugebauer; they amount to 195.

References

Doléris. *Bull. de la Soc. d'Obstét. et de Gynécol. de Paris,* 1912, xv. 771.
Gifford, G. T. *British Medical Journal,* 1907, ii. 1042.
Kouwer, Prof. *Zentralbl. für Gynäk.,* 1907, xxxi. 1447.
MacLaren, A. *Annals of Surgery,* 1896, xxiv. 365.
Neugebauer, F. v. *Monatsschrift für Geburtsh. u. Gyn.,* 1900, Bd. xi, 821, 933. *Zentralbl. für Gynäk.,* 1904, xxviii. 65.
Stewart, J. E. F. *Australian Medical Gazette,* 1906, xxv. 446.
Waldo, R. W. *American Journal of Obstetrics,* 1906, liv. 533.
Wilson, H. P. C. *Trans. American Gynecological Society,* 1884, ix. 94.

Tetanus. This dread complication of wounds occasionally occurs after ovariotomy, and during the 'reign of the clamp' it was especially frequent in Germany (Olshausen). Cases have been reported in England, and tetanus has been noticed to affect patients who have been ovariotomized in rooms recently plastered.

Since Kitasato demonstrated the bacillary origin of tetanus poison, and showed that the bacillus can be transported by dust, knowing its liability to attack suppurating wounds, we can understand that when the pedicle of an ovarian cyst was secured by a clamp and allowed to slowly slough away, more or less exposed to air and dust, it offered a nidus for the tetanus bacillus.

Tetanus, however, has not quite disappeared as a sequel to operations on the pelvic organs, for in 1902 a case was reported by Dorsett in

which a patient died of this disease after hysteropexy, and the tetanus bacillus was detected in some wallaby tendon employed to suspend the uterus. Tetanus has also been traced to infected catgut employed in cholecystotomy (1905).

Ed. Martin reported the occurrence of tetanus after vaginal fixation of the uterus and colporrhaphia anterior. Cumol-catgut was employed.

Menzer has recorded a similar case which occurred in Dührssen's Klinik (1901). The ligatures were of catgut.

Mallet refers to two post-operative deaths from tetanus. One patient had undergone an operation for bilateral pyosalpinx and the other had a fibroid of the uterus complicated with an ovarian cyst. There was an interval of eighteen months between the two fatal cases. Catgut was employed as the ligature material.

In practice it is important to remember that tetanus arises from infection: hence all instruments which have been in contact with this disease must be sterilized, and this should be effected by submitting them to prolonged boiling.

Tetanus occurs as a rare sequel to miscarriage and normal labour. Kraus and von Rosthorn have reported some carefully investigated cases of this kind.

References

Dorsett, W. B. Two Fatal Cases of Tetanus following Abdominal Section due to Infected Ligatures, &c. *Am. Journ. of Obstet.*, 1902, xlvi. 620.

Mallet, G. H. Some Unusual Causes of Death following Abdominal Operations. Ibid., 1905, li. 515.

Martin, Ed. Postoperativer Tetanus (with references). *Zent. f. Gyn.*, 1906, xxx. 395.

Meinert. Drei gynäkologische Fälle von Wundstarrkrampf. *Arch. für Gyn.*, 1893, xliv. 381.

Menzer. Tetanus Infection after Vaginal Fixation of the Uterus. *Zeitsch. f. Geb. u. Gyn.*, 1901, xliv. 517.

Olshausen, R. Tetanus nach Ovariotomie Billroth-Lücke's. *Handb. der Frauenkrankheiten*, 1877–9, ii. 367.

Taylor, H. Tetanus after Hysterectomy. *Am. Journ. of Obstet.*, 1908, lvii. 574.

Injury to intestines. The intestines, great and small, are very liable to injury in the performance of intrapelvic operations. Unless care is taken in opening the abdomen, the intestines are apt to be cut, especially when there has been chronic peritonitis, as in tuberculous and gonococcal infections, which cause the small intestine to adhere to the parietal peritoneum investing the anterior abdominal wall. Where cœliotomy is being performed a second or third time, through or near

the original cicatrix, it is necessary to proceed with extreme caution for fear of cutting an adherent coil of gut.

Intestine is also liable to be torn in separating adhesions from the tumour, and great care is necessary when cysts are firmly adherent to the floor of the pelvis, for in separating them the rectum runs a great risk of being damaged.

In removing tumours to which the vermiform process adheres it is necessary to be careful and avoid mistaking it for an adhesion, for there is reason to believe that this structure has been divided and its nature overlooked; an accident of this sort leads usually to fatal peritonitis.

It has happened, in the course of removing very adherent ovaries and tubes from the floor of the pelvis, that in transfixing the pedicle a coil of ileum has also been transfixed with the needle and tied to the stump. This accident is not likely to happen now that the Trendelenburg position is almost universally employed.

In sewing the abdominal incision the intestines have been pricked with a needle, and in some instances the bowel has been accidentally included in the sutures and sewn to the abdominal wall. On one occasion, while securing a very long incision with through-and-through sutures, while passing the needle through the abdominal wall it broke, and the broken end came with great force against the anterior wall of the stomach and tore a hole in it. This I secured at once with suture and the accident had no bad consequences.

An unrecognized wound of the bowel in the course of a pelvic operation is almost certainly fatal. Accidental injuries, such as punctures and cuts, require immediate suture, and I have never known any harm follow. On the other hand, ragged tears in thickened and inflamed bowel require careful consideration in order to spare patients the inconvenience and distress of fæcal fistulæ.

In regard to small intestine a very small opening may occasionally be safely secured with fine silk, but in most cases it is wiser, if the bowel is thickened and inflamed around the hole, to resect well wide of the damaged portion and join the cut ends (circular enterorrhaphy).

Holes low down in the rectum are difficult to suture securely. These should be treated by drainage, using a wide rubber drain; the convalescence will be tedious, but the fistula will close.

It is useful to remember that if the rubber tube be too long it may enter the hole in the bowel and thus maintain the fistula. On one occasion I was asked to close a fæcal fistula which had followed an oöphorectomy. This fistula persisted five years. At the operation I found a hole in the sigmoid colon with its margins adherent to the opening in the parietes, so that the tube passed directly into the bowel. The gut

was detached and the opening closed with sutures, and it gave no further trouble.

If, in the course of an ovariotomy or hysterectomy, the surgeon discovers a cancerous stricture in the colon or cæcum he should resect the affected section, if it permits of this treatment; otherwise lateral anastomosis should be performed.

Intestinal obstruction. It is difficult to estimate with any approach to accuracy the relative frequency of intestinal obstruction after operations on the uterus and its appendages; nevertheless the danger is real. The obstruction may be acute or chronic: it may occur within thirty hours of the operation or be delayed for months or years. The causes may be arranged under five headings:

1. Adhesions to the abdominal wound.
2. Adhesions to the pedicle, stump, or a raw surface in the pelvis.
3. Strangulation around an adventitious band.
4. Obstruction due to an overlooked cancer in the colon.
5. Strangulation in a sac formed by a yielding cicatrix.

The form of intestinal obstruction with which we are most concerned here arises shortly after the operation and in the course of convalescence; it may be caused by adhesions to the abdominal incision, the pedicles, raw surfaces in the pelvis left after the removal of adherent cysts and tumours, and the cervical stump of a subtotal hysterectomy.

The subject is one of importance, for the complication is fairly common in the practice of some surgeons, and is one which it is very necessary to recognize, for unless measures of relief are undertaken promptly the patient surely dies.

From a careful study of the matter I have come to the conclusion that acute intestinal obstruction is more frequent after ovariotomy than after hysterectomy, and this is due to the fact that the stump or pedicle left after the removal of an ovarian tumour lies higher in the pelvis, and in closer relation to the ileum and jejunum, than the cervical stump left after the removal of the uterus. This view also receives support from the fact that acute intestinal obstruction following hysterectomy is more frequent in the practice of those surgeons who perform subtotal hysterectomy improperly, and leave a large piece of the neck of the uterus sticking up like a median post in the floor of the pelvis. As far as I can judge from the scanty records relating to this complication after hysterectomy, it is the sigmoid colon which is most commonly adherent to the cervical stump. The best way of avoiding this accident is to remove the supravaginal cervix so freely that, when the peritoneum is closed over the incision in the floor of the pelvis, there is nothing visible except a narrow thin line of suture at the base of the bladder.

The only rational method of treating acute intestinal obstruction following operations in the pelvis, is promptly to reopen the abdomen and set free the adherent coil of gut. Operations of this kind after hysterectomy are more often successful than when they are a sequel to ovariotomy, and this is, I think, due to the fact already mentioned, that when intestinal obstruction follows ovariotomy or oöphorectomy, the obstruction arises in the small intestine and is usually very acute and more dangerous; whereas after hysterectomy the obstruction affects, as a rule, the sigmoid colon, and though it may be fairly acute, is not nearly so dangerous, and gives far better results to operative treatment.

Perforating ulcer of the stomach and small intestine. A rare cause of death after ovariotomy or hysterectomy is a perforating ulcer of the stomach or jejunum. Since 1887 I have seen three cases. In each instance the patient died from septic peritonitis. Rosthorn lost a patient from perforating ulcer of the stomach after hysterectomy. Olshausen states that he has seen at least four examples of this accident.[1]

Injuries to the bladder. This viscus has been injured in a variety of ways during operations on the pelvic organs. An over-full bladder has been mistaken for an ovarian cyst and been punctured with a trocar before the mistake was discovered. When tumours are impacted in the pelvis the bladder is often pushed up into the hypogastrium; this happens with bilateral ovarian tumours, incarcerated fibroids, and especially with large cervix fibroids. When the bladder is pushed up care should be exercised in making the abdominal incision, or it will be cut. Punctures and incisions in the bladder should be immediately closed with sutures of fine silk.

The bladder is liable to be injured in the performance of subtotal and total hysterectomy, especially in the latter operation when separating it from the neck of the uterus. In the subtotal operation the risk arises chiefly in suturing the peritoneal flaps over the cervical stump, for the bladder is liable to be punctured with the needle as it lies close to the anterior flap.

Injuries to the ureter. Since the vulgarization of hysterectomy injuries to the ureters have become common; nearly all are inflicted in cases where the neck of the uterus is removed, as in total abdominal hysterectomy, and in vaginal hysterectomy, because the vesical segments of these ducts come into close relationship with it.

The injuries to which the ureters are liable in the course of hysterectomy are as follows:

[1] Bland-Sutton, J. On Perforation of the Stomach and Small Intestine as a Sequel to Ovariotomy and Hysterectomy. *Journ. of Obstet. and Gyn. of the British Empire*, 1909, xv.

1. One or both ureters have been included in the ligatures applied to the uterine arteries.

2. One or both ureters have been cut or completely divided with scissors, or knife, in removal of the uterus.

3. A segment of a ureter 7 centimetres in length has been accidentally exsected.

4. One or both ureters have been compressed by clamps applied to restrain bleeding in the course of vaginal hysterectomy, and subsequently sloughed.

5. Ureters exposed in the course of 'radical' operations for cancer of the neck of the uterus often slough.

6. A ureter is sometimes transfixed by a needle and thread when sewing the layers of the broad ligament together in the course of a subtotal hysterectomy.

When a ureter has been injured during the performance of subtotal hysterectomy, and the accident has not been noticed at the time of the operation, the urine leaks into the connective tissue of the broad ligament and the extravasation may extend to the loin. When the urine leaks into the pelvis it will, in a few days, escape through the abdominal wound. In cases where the neck of the uterus has been removed, as in total or in vaginal hysterectomy, and the ureters have been injured, the leakage of urine through the vagina soon apprises the surgeon of the accident. When both ureters have been tied or clamped accidentally anuria is the immediate consequence.

When a ureter is injured in the course of an operation it is important that the surgeon should recognize the accident, as this enables him to deal with it at once.

The primary treatment for a ureter injured in the course of a pelvic operation depends in a large measure on the ability, judgment, and experience of the surgeon, as well as on the extent of the injury.

1. When a ureter is partially divided the opening may be closed with sutures of fine silk.

2. When the duct is completely divided the cut ends may be invaginated, the upper into the lower.

3. If a piece measuring 5 centimetres, or more, has been exsected two courses are open. (*a*) A ligature may be applied to the upper end with the prospect of causing atrophy of the kidney. (*b*) The kidney may be removed if its companion is healthy; otherwise the proximal end of the ureter should be secured in the wound, or be brought out through a stab-wound in the loin.

4. When the cut ends of a ureter cannot be safely joined, the proximal end should be engrafted into the bladder. Many cases have been

successful, but there is reason to believe that when the ureter has been engrafted into the wall of the bladder the ureter becomes sclerosed and the lumen narrowed and obliterated.

The sclerotic obliteration of a ureter engrafted into the bladder is a slow process and it does not happen in every case. For example, Lockyer, in removing a fibroid which burrowed between the layers of the broad ligament, wounded the bladder and divided the right ureter; he sutured the hole in the bladder and removed the right kidney. During the twenty-four hours following the operation there was anuria. On reopening the abdomen and finding that the left ureter had been divided he engrafted its proximal end into the bladder, through the wound which had been already sutured. Convalescence was disturbed by a urinary fistula, but the woman recovered and reported herself in good health three years later.

When a ureter has been injured in the performance of total hysterectomy and is unnoticed, urine escapes by the vagina, and at first there is doubt whether the leak is due to an injury to the bladder or to a ureter. In such conditions the quantity of urine voided through the urethra is compared with that which escapes through the vagina. If the quantities be equal, the leak is in the ureter; the surgeon has to decide which ureter has been injured, but he need be in no hurry to determine this, for a fistula due to partial injury of a ureter sometimes closes; if it persist for more than three months it will not heal spontaneously.

In order to ascertain which ureter is injured the surgeon avails himself of the cystoscope. This instrument will not only enable him to determine the point, but he can sometimes learn whether a ureter is completely divided.

Jonas related the details of a case in which he performed total hysterectomy for fibroids and on the tenth day the nurse reported the escape of urine from the vagina. The urine voided from the bladder measured on the average fifty ounces, but it now fell to twenty-five ounces. On cystoscopic examination urine could be seen issuing from the right ureteric orifice; at first the left orifice could not be seen, but on careful watching a movement was detected similar to the contraction of a ureter discharging urine, but no fluid came from the opening. This aimless movement of the ureter, known as 'empty contraction,' indicates that there is not complete interruption of the ureter. Such cases should have an opportunity of healing spontaneously. This happened to Jonas's patient.

When a ureteric fistula refuses to heal and the surgeon decides to remove the kidney, he not only satisfies himself cystoscopically to which kidney the cut ureter belongs, but he will be wise on exposing the kidney

to inject a coloured fluid, such as methylene blue, into the pelvis of the kidney and then ascertain if it escapes by the leak before removing the organ. The danger of removing the kidney belonging to the undamaged ureter is real. Morris reported a case in which this happened: A woman had total hysterectomy performed for a cervical fibroid by a gynæcologist; in the course of the convalescence a ureteral fistula was recognized, and as this failed to close spontaneously a surgical colleague performed nephrectomy, and the next day found to his chagrin that he had removed the kidney belonging to the uninjured ureter. Serious accidents of this kind are less likely to happen now, because the surgeon can avail himself of the cystoscope and ureteral catheter; with these instruments it is possible, not only to decide with certainty which ureter is injured, but also to determine the position and extent of the damage.

I was present at a hysterectomy when a gynæcologist cut three inches out of a ureter, mistaking the duct for an adhesion. He overcame the difficulty by firmly tying the proximal end of the cut ureter with a silk thread. The patient, a middle-aged woman, recovered without an untoward sign and remained well. This led me to take interest in this method of dealing with a cut ureter, and in 1909 I expressed the opinion that 'it is possible and probable that a ureter has been ligatured in the course of an operation, and the patient has recovered, without anyone having a suspicion that such an accident has happened.' Dr. J. D. Barney has collected and analysed the reports of sixty-two cases of injury to the ureter. Of these sixteen were bilateral and forty-six unilateral. The majority of the accidents occurred in the course of hysterectomy. He finds that sudden occlusion of a ureter by ligature often produces no symptoms; sometimes it is followed by pain and tenderness in the kidney, which subsides spontaneously. In some instances the accident is followed by hydronephrosis, and he reiterates the opinion expressed above that there is a strong probability that a ureter is often unconsciously ligatured.

A ureteral fistula is a serious matter for the patient. Dr. G. F. Blacker has had three of these accidents after total hysterectomy. In one the kidney was removed on account of septic changes. The second had an attack of anuria lasting twenty-four hours; it passed off, she recovered, and the fistula healed. The third died eight weeks after hysterectomy with symptoms of pyæmia; a small abscess had formed near the site of the fistula.

When a fistula of the ureter has healed spontaneously the risks are by no means at an end, for the patient is liable to attacks of anuria, pyelitis, and pyæmia.

REFERENCES

BARNEY, J. D. The Effects of Ureteral Ligation: Experimental and Clinical. *Surgery, Gynæcology, and Obstetrics,* 1912, xv. 290.

BLACKER, G. F. *Lancet,* 1909, i. 395.

JONAS, E. Temporary Uretero-vaginal Fistula after Panhysterectomy for Fibroid of the Uterus. *Am. Journ. of Obstetrics,* 1907, lvi. 731.

MORRIS, H. Lectures on the Surgery of the Kidney. *British Medical Journal,* 1898, i. 1039.

The fate of ligatures. When a ligature is satisfactorily applied to a pedicle the tissue on the distal side of the ligature is isolated from the circulation. The fate of this tissue and of the ligature has been the subject of much speculation.

It is a matter of common observation that when animal tissues are cut off from the circulation, they atrophy; but if pathogenic micro-organisms gain access to such parts, suppuration ensues. In due course, through the activity of the living cells, the dead tissues are detached from the living, a process termed sloughing.

When a piece of healthy tissue is removed from the body and immersed in a sterile solution, and absolutely isolated from the atmosphere, decomposition is indefinitely postponed, but as soon as unsterilized air is allowed access to it, putrefactive changes ensue. The pedicle after ovariotomy is in an air-tight chamber, and if the tissues included by the ligature are healthy, and the silk employed for the purpose is absolutely aseptic, this pedicle, when returned into the abdomen, resembles the piece of tissue isolated from contact with the atmosphere. No septic changes occur, but aggressive leucocytes attack the silk and may, in course of time, effect its removal, even the knots. For this desirable result three conditions require to be fulfilled: (1) the ligatured tissue must be aseptic; (2) the ligature should be absolutely sterile; and (3) air or intestinal contents must be excluded.

These conditions may be prevented in many ways. The tissues included in the ligature are not always free from infective organisms, especially the uterine tube, which is usually included in the ligature, and this structure, especially in cases where oöphorectomy is performed for inflammatory diseases, often contains septic microbes; this endangers the ligature and leads to the formation of pus, with its complications, sloughing of the pedicle and abscess. The tissues may be healthy and aseptic, but the ligature may have been imperfectly sterilized, or become contaminated by assistants, or even by the hands of the surgeon during its application.

The operation may have been conducted aseptically and the

tissues be healthy, but the ligature becomes infected by the admission of air as a result of drainage, or implication of the bowel or bladder.

I made a careful study of the fate of silk sutures employed in pelvic surgery extending over many years, and came to the conclusion that, even under favourable conditions, silk ligatures disappear very slowly. The silk used to secure an ovarian pedicle may, in very favourable circumstances, disappear in twelve months, but the knots require nearly double that time. The piece of silk which encircles the uterine tube is apt to behave in a curious way; in 1898 I removed an ovarian cyst the size of a fist, and tied its slender pedicle with thin silk. Although the recovery was uneventful, the patient complained during many weeks of cramp-like pains on the side from which the cyst was removed. These pains gradually subsided, and ten months later, during menstruation, the patient noticed on the napkin a tiny loop of silk, which she saved. This was the loop of silk which secured the uterine tube; it had ulcerated into the tube and been conducted into the uterus and escaped. I have since had a like condition, the loop making its appearance three weeks after an ovariotomy. It has been established by experiments on the long uterine cornu of rabbits, that an encircling ligature will ulcerate through, leaving the lumen of the cornu intact. Clinical observations regarding ligatures applied to uterine tubes in the performance of Cæsarean section for the purpose of preventing pregnancy prove that this is a useless measure, for these tubes in many instances have recovered their patency, and pregnancy has recurred. It is a fair inference that the ligature ulcerates into the lumen of the tube, which then heals behind it, without stricture of the canal. A similar condition of things sometimes arises after Cæsarean section, especially when the uterine incision is closed by two layers of sutures. Those sutures which involve the endometrium will ulcerate into the uterine cavity and cause irregular slight losses of blood until they escape.

It is important to emphasize the fact that silk sutures in uterine tissue will, in some instances, remain unabsorbed for many years. A patient who had been submitted to Cæsarean section in 1903 came under my care four years afterwards for the removal of the tumour which caused obstruction; the sutures used to close the uterine incision were visible, and a miscroscopic examination showed that each silk suture was enclosed in a fibrous tissue sheath.

The fact that silk sutures will resist absorption for such a long period has an important practical bearing, because so long as pathogenic micro-organisms are denied access they remain inert, but if any septic condition arises in their neighbourhood, and these sutures become involved, they

will give rise to abscesses and sinuses as surely as if they had been buried but a few days.

Patients often suffer great distress and annoyance on account of abscesses and sinuses due to septic ligatures, and a sinus will persist as long as the ligature remains. Abscesses and sinuses resulting from troublesome ligatures may escape in many directions; the most common spot is at the lower angle of the abdominal incision; the rectum is another channel of escape, and also the bladder. When a ligature makes its way into the bladder it will set up cystitis and serve as a nucleus for a vesical calculus. In an unusual case recorded by Edebohls, double oöphorectomy was performed for uterine fibroids; a year later the ligature on the left side escaped through the vagina; six months later he performed abdominal hysterectomy. The vermiform process was adherent to the stump on the right side; it was removed, and a silk ligature tied in a complicated knot was found in it, making its way towards the cæcum.

On one occasion a woman, who had been submitted to subtotal hysterectomy in the Antipodes, suffered from frequent micturition and fœtid urine; she came under my care. On dilating the urethra, it was found that the cervical stump had ulcerated through the posterior wall of the bladder and projected freely into the vesical cavity, bristling with thick silk ligatures encrusted with phosphatic deposit. The ligatures were removed, the urine soon became acid, and the vesical discomfort quickly subsided, in spite of the anomalous position of the cervical stump.

Until surgeons fully realized the importance of thoroughly sterilizing the silk employed for the pedicles in ovariotomy, it was quite common for the silk loops to ulcerate through the bladder wall and set up cystitis.

Many cases have been reported in which a loop of silk, effecting an entrance into the bladder in this fashion, has formed the nucleus of a phosphatic calculus.

Post-operative kraurosis. In a small proportion of patients (perhaps not more than 1 per cent.) who have undergone bilateral ovariotomy, oöphorectomy, or hysterectomy, the vulva undergoes the peculiar atrophic changes which are characteristic of the condition known as *kraurosis vulvæ*. This change, so far as my observations go, is chiefly seen in patients who have been submitted to these operations after the fortieth year of life. The cause of this change is unknown. The condition is troublesome and inconvenient in married women, but spinsters rarely complain of it. Post-operative kraurosis is as rebellious to treatment and its causation is as inexplicable as kraurosis occurring independently of operation.

The cicatrix. Although the employment of buried sutures has

made abdominal incisions more secure in the process of healing, and renders them firmer after union, thus reducing the chances of a yielding scar, and saving the patient the inconvenience of an abdominal hernia or the annoyance of wearing an abdominal belt, it renders the patient liable to another discomfort, namely, stitch-abscess. The complication arises from a variety of causes—for example, imperfect sterilization of the suture material, or of the patient's skin preceding the operation. The sutures may be soiled by the hands of nurses and assistants, or the fingers of the surgeon. Every precaution may be taken, but the operation may have been required for the removal of infected cysts or pelvic peritonitis; in such cases it is unwise to bury sutures.

Troublesome buried sutures should be removed. In many instances this is easy of accomplishment, and in others it requires patience and perseverance, even when the patient is under an anæsthetic. The simplest implement for removing a buried suture is a crochet-hook.

The disadvantage of stitch-abscesses, apart from the inconvenience they cause patients during their convalescence, is that they often cause the scar to yield at that spot, and necessitate the wearing of an abdominal belt. If the hernia is of small extent, and especially when it is situated near the lower angle of the scar, it is difficult to fit a belt which will restrain it without the use of perineal bands or straps. In such cases a truss, on the principle of those employed for inguinal hernia, is more satisfactory than a belt.

Occasionally a scar forms a raised, hard, red, keloid band, and causes some anxiety to the patient. These keloid scars shrink and whiten in the course of a year or eighteen months.

Cancer of the cicatrix. Several cases have been recorded in which, after the removal of an ovarian adenoma, a new growth, described as 'cancer of the cicatrix,' has formed in the scar. These growths are probably due to the soiling of the wound at the time of operation with epithelial fragments from the tumours.

After abdominal hysterectomy for cancer of the body of the uterus, or the cervix, the abdominal wound may become infected with this disease, and in cases where exploratory cœliotomy has been performed for diffuse cancerous disease of the peritoneum the cicatrix is liable to become permeated by malignant disease also.

Acidosis and postoperative vomiting. Recent studies in blood chemistry have shown that anything which tends to deplete the alkaline reserve of the blood and consequently to favour the development of acidosis may produce serious postoperative complications. Late evidence of this condition is found in the presence of acetone and diacetic acid in the urine. Lesser degrees of acidosis may be recognized by a deter-

mination of the alkaline reserve of the blood plasma. Anything which tends to lessen the alkaline reserve,—as starvation, decreased fluid intake before operation, excessive metabolism from disease, the administration of chloroform or ether,—will affect the recovery of the patient to a greater or lesser degree. The clinical evidence of a beginning acidosis may be found in persistent postoperative vomiting. The surgeon should guard against this complication by continuing the administration of liquids up to the time of operation, and by limiting as much as possible the amount of anæsthetic used. The patient should receive water in sufficient quantity by rectum or other means following operation. To patients in whom acidosis is feared, because of general debility or a protracted illness before operation, it is wise to give thirty grains of sodium bicarbonate three times a day for several days before operation, and to continue its use in tap water by rectum after operation. Five per cent of glucose may be added to the enema with advantage.

Dilatation of the stomach. This complication is discussed in the section dealing with abdominal operations. The surgeon will be wise to begin gastric lavage in all patients who continue to vomit after operation for more than twenty-four hours. If this were done as a routine fewer patients would be found to suffer from this complication. In severe cases one of the smaller duodenal or stomach tubes may be inserted and left in place continuously for several hours or days. As Moynihan, Borchgrevink and others have pointed out, the patient should be kept prone, with a pillow under the abdomen in order to raise the pelvis and prevent the small intestine from falling downward and dragging upon the mesentery.

Blood transfusion. To patients who have a low blood count from repeated hæmorrhages or other causes a transfusion of blood should be given, with proper precautions, preliminary to operation. After an operation in which the blood loss has been excessive blood transfusion should also be done. The technique is so simple and the advantages so great that the surgeon should not wait until the patient is in a critical condition, but should resort to it in the lesser degrees of blood depletion. Blood transfusion should be removed from the class of procedures used only as a life-saving measure, and its use more often resorted to as a means of hastening convalescence, and preventing those complications that may develop during convalescence as a result of the lowered vitality incident to depletion of the blood volume. The technique of administration is considered elsewhere.

SECTION III

OPERATIONS UPON THE VULVA AND VAGINA

BY

CAREY CULBERTSON, M.D., F.A.C.S.

Assistant Professor of Obstetrics and Gynæcology, Rush Medical College; Associate Attending Obstetrician and Gynæcologist, Presbyterian Hospital; Attending Gynæcologist, Cook County Hospital, Chicago.

CHAPTER I

SURGERY OF THE VULVA AND VAGINA

INTRAVAGINAL OPERATIONS UPON THE UTERUS

Dilatation of the cervix and exploration of the uterus. The chief indication for this operative procedure is to secure material for diagnosis, to ascertain the various conditions which may obtain in the uterine cavity, such as the presence of mucous polypi, submucous fibroids, malignancy, and the latent products of gestation, and to permit their removal.

The patient is prepared for operation in the lithotomy position. A hanging speculum is placed in the vagina. In some cases this alone will expose the cervix. If it should not, however, a narrow-bladed anterior retractor is introduced; on rare occasions where the cervix is situated deeply in the pelvis or where the vaginal walls are prolapsed or excessively redundant, lateral retractors may be required in addition. The cervix having been exposed, its anterior lip is grasped with a volsellum in the left angle of the external os and brought down as far as possible. A second volsellum is then used to seize the corresponding right angle of the anterior lip, after which the anterior retractor is withdrawn. For traction on the cervix during its dilatation two single volsella, introduced as described, are preferable to one instrument at the middle of the anterior lip, or to the four-tooth bullet forceps. No operator can tell whether a cervix can be dilated readily or with difficulty, and strong traction may frequently be necessary. With the instruments placed as described they are much less liable to pull out and lacerate the tissues. For the same reason volsella whose teeth have cutting edges should not be employed in the cervix.

With the cervix held well down towards the vaginal introitus, a uterine sound is first introduced for the purpose of testing the patency of the external and internal openings, the direction which the cervical canal takes, its regularity, and the depth of the uterine cavity. The sound is passed, much as is the catheter or the probe, with little or no force, and adapted to the known position of the uterus. Only in occasional instances is it necessary to employ the sound to determine the direction of the uterine cavity. Where there is stenosis or tortuosity of the canal any excessive pressure will readily force the sound through the uterine wall.

particularly if this is softened by œdema or inflammation. With the sound in the uterus and its tip resting gently against the fundus, the index finger of the hand holding the sound is placed against the external os. When the sound is withdrawn the depth of the uterine cavity may be measured directly upon the instrument.

Dilatation is effected by the use of graduated dilators of the Hegar type. These are passed, one after the other, without haste. Particularly in the cervix of the nullipara or in the stenosed cervix is gradual dilatation safest. The cervix is a musculo-connective tissue structure, and in dilating it the tissues must be stretched in all directions as equably as possible and not merely anteroposteriorly or laterally. In the rigid cervix too rapid dilatation may produce a rupture entirely through the cervical wall into the broad ligament, just as the soft, œdematous wall in pregnancy may burst from the same cause. A second point of importance is that it is necessary to dilate the internal os. The novice tends to fail in this by not inserting the dilators far enough through fear of perforating the fundus. It is not necessary to dilate above the internal os.

As a rule dilatation as far as that effected by a No. 15 sound is sufficient for gynæcological exploration. This readily admits instrumentation. Only in case of abortion may it be desirable to secure wider dilatation. Examination of the uterine cavity is effected with the finger, directly introduced—the most satisfactory method of palpation. With the curette forceps the cavity is explored for projecting growths, such as polypi, or for foreign material or placental remnants. If the latter are found they are best removed with the placental forceps, which is less dangerous to the integrity of the fundus than the curette forceps. The curette may also be used as a palpator. Introduced into the uterine cavity, its sharp edge is swept lightly over the surface of the mucosa. A fine grating sensation is elicited where this membrane is intact and normal. No instrument, however, can accurately reveal irregularity or tortuosity of the uterine cavity, much less the presence of submucous growths. Even retained chorionic villi in the fundus may be entirely missed. In the final analysis the gloved finger gives the best information as to the character of the uterus, its wall, its mucosa, and the presence or absence of growths or débris.

Following thorough exploration, the uterine cavity is swabbed with tincture of iodine on two applicators, one for the corpus and one for the cervix. With the first the iodine is applied gently, but on the cervical mucosa it is rubbed in rather vigorously. As a rule no uterine tampon or gauze pack is required. The writer does not place much value on the application of antiseptics to the uterine mucosa by means of a gauze pack. The best indication for packing is to control active hæmorrhage into the

uterine cavity, such as occurs after the removal of placental débris, or of carcinomatous material. Occasionally, too, for the same reason, the pack will be necessary following the extirpation of mucous polypi or pedunculated fibroid tumors. Here, also, the application of the tincture of chloride of iron is preferable to that of iodine.

Curettage of the uterine cavity has but one indication—that of securing material for diagnosis by microscopical section. The operation should cease as soon as this material is obtained. Where the uterine cavity is occupied by a large, friable mass of cancerous material there is no advantage in shelling out large quantities of it and thus opening avenues for secondary infection or exciting profuse hæmorrhage. This is particularly the case in view of the most recent methods of treating uterine carcinoma by radium or heat. The curette is of little or no value in removing gestation products. As a cure for leucorrhœa, dysmenorrhœa, sterility, menorrhagia and metrorrhagia curettage has no logical place in view of our present conception of these symptoms.

Actual curettage should always be done with a sharp curette of medium size, preferably of the spoon or loop variety, the edge scraping the endometrium firmly from above downward, passing systematically over the anterior wall first, then the posterior. Inasmuch as malignancy may be early, or at least not extensive, the entire surface of the mucosa may have to be covered in order to disclose its presence. After going over the walls of the uterine cavity, a smaller instrument is employed to curette the fundus and the lateral borders, so that no portion of the mucosa may escape examination. Since this procedure is for the purpose of securing material for diagnosis, care is taken to avoid losing the scrapings in the flow of blood or in blood clots. For the same reason an irrigating curette should not be used.

Extirpation of uterine polyps. Cervical polyps are single or multiple, pedunculated or sessile, and either composed of mucous tissue or myomatous in character. In order to remove them a speculum is introduced into the vagina, the cervix is exposed and grasped by a volsellum, and pulled down and dilated, as has already been described. Mucous polyps projecting into the cervical canal are seized with a clamp and twisted off. As a rule this will not be followed by hæmorrhage, but should such be the case, the bleeding points are grasped with forceps and ligated. It is not deemed wise to cauterize bleeding points in the cervix owing to the danger of too extensive cauterization and subsequent stricture.

Mucous polyps of the corpus are seized in exactly the same manner and twisted off. Here, however, it will be virtually impossible to grasp the polyp directly, owing to its not being in the field of vision, unless its

pedicle is sufficiently long to permit it to hang into the cervical canal. With a curette forceps the polyp may be grasped blindly, but it is much wiser to undertake a thorough and systematic curettage of the corpus with a sharp curette. The removal of polyps should be followed by the application of iodine to the uterine cavity. A gauze pack is introduced only in case the bleeding is sufficient to warrant it.

Myomatous polyps of the cervix, if pedunculated and if the pedicle is small, may be removed by simply seizing them and twisting them off. If the pedicle is thick, the growth may have to be cut with the scissors. Fortunately there is little danger of hæmorrhage. If the polyp is so large as to obstruct its pedicle, it is seized with a volsellum and its capsule incised and reflected. The tumor is then shelled out of its bed, or removed with its capsule by morcellation. The pedicle is twisted or cut off at its base.

Large myomata, which fill the vagina and make it impossible to get at the cervix in the first place, are treated by morcellation.

A myomatous polyp of the corpus in nearly every case requires removal by morcellation. Where its pedicle can be reached it may be twisted off directly, but this is not feasible in the majority of cases. If the polyp has not dilated the cervix, the cervix must be dilated sufficiently to permit the growth to be removed. Where the tumor is in the internal os and thus dilates the cervix, it may be seized and pulled down, after the lower portion of the cervix is further dilated, and its pedicle cut. It may also be removed by morcellation. In either case the operator should be on his guard against the possibility of an inverted uterus being present or of producing inversion by traction on the growth.

The writer does not advocate discission of the cervix for the purpose of reaching polyps of the uterine body, or for any other purpose, indeed, in operating upon the non-pregnant uterus. Even with painstaking repair and fortunate healing the resultant scars may form the basis for subsequent dystocia, or for stenosis and sterility. Too many surgeons who find it easy to split the uterus open in order to inspect its interior forget the obstetrical significance of this important organ.

Polyps composed of placental tissue, are usually not recognized as such until examined microscopically. Where they are recognized, they are best removed with a sharp curette, the uterine cavity being subsequently packed with gauze in order to stop excessive bleeding.

Amputation of the cervix uteri. Low amputation of the cervix is indicated in erosion of the portio, especially if this condition is associated with the stellate laceration of the external os which is so common in the multipara. Indeed, this operation is little more than the removal of the portio, since not more than one-third of the canal is

removed in the classical operation for low amputation of the cervix.

High amputation of the cervix has for its indications the deeper lacerations, bilateral or unilateral; eversion of the cervical muscosa with

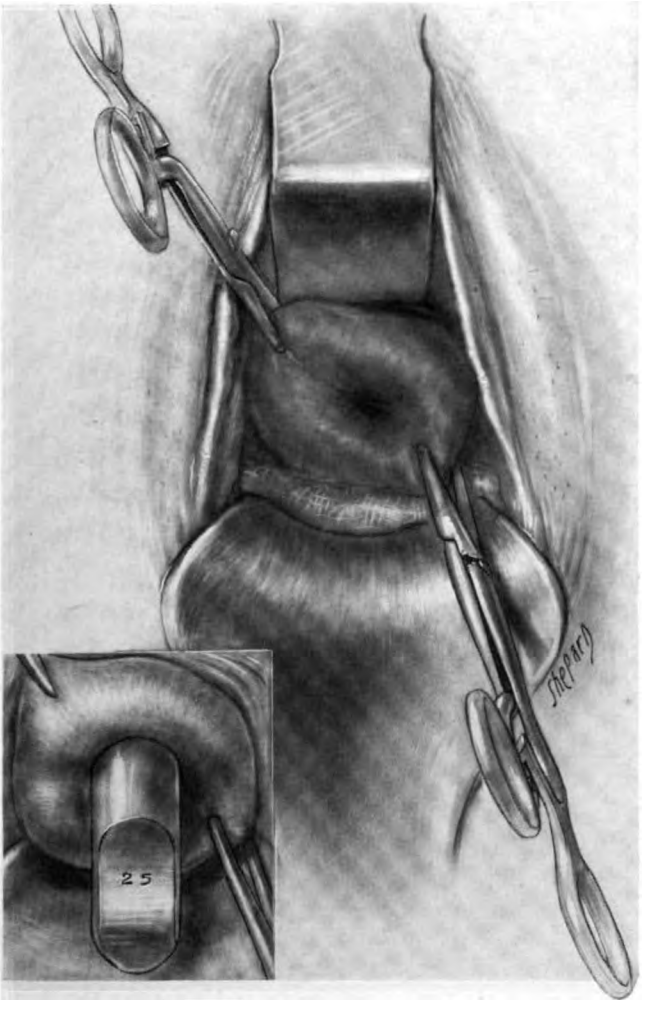

FIG. 4. LOW AMPUTATION OF THE CERVIX. Exposure and dilatation of the cervix.

considerable thickening of all tissues; and the development of erosions and follicular cystic changes. It is also done in chronic cervicitis without laceration, and, by some clinicians, as a prophylactic procedure in all multiparæ at or near the menopause.

After the cervical canal has been dilated and curetted, or the uterine cavity treated appropriately, the volsella are shifted to the anterior and posterior lips, so that they are held spread apart. Short lateral vaginal retractors are introduced and held by the assistants. The cervix is split

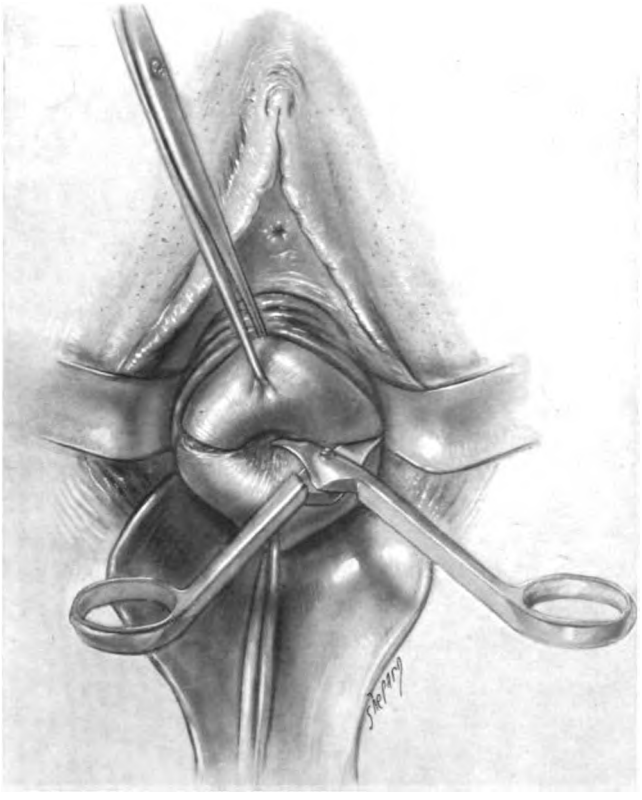

FIG. 5. LOW AMPUTATION OF THE CERVIX. Incision of the lateral wall; the cervix is drawn downward and steadied by volsellum forceps.

up on each side with the scissors for one-half or five-eighths of an inch (Fig. 5). Beginning with the anterior lip, the outer vaginal mucous membrane is cut through with a scalpel from the right lateral incision to the left in a direction slightly curved downward (Fig. 6). This curved flap of vaginal mucosa is dissected upward from the cervical wall as far as the lateral incisions. The cervical lip is amputated with the knife, its blade passing from within outward and from below upward.

so that the plane of the incision forms an acute angle with the axis of the cervical canal. This leaves a clean-cut, free, tapering edge of cervical wall to form the new external os, as suggested by Webster. With chromic catgut the reflected portion of the vaginal mucosa is sutured over this raw cervical edge (Fig. 7), care being taken to bring it down so well that no mucosa of the cervical canal will remain exposed. This can be done with the over-and-over interrupted sutures, which are tied and left long in the grasp of a clamp to be used as tractors.

The mucosa covering the posterior lip is incised from side to side and dissected back, and the posterior lip is amputated in the manner just described, after which the two raw edges are brought together posteriorly exactly as they were anteriorly (Fig. 7). The posterior sutures are cut short after tying. There is now left on each side a gaping angle, which is closed by coapting the opposing edges, one or two over-and-over sutures being sufficient in each angle. The sutures are tied and cut short. A narrow strip of gauze is lightly inserted into the cervical canal to serve merely as a surgical dressing for the new cervical lips. The long tractor sutures in the anterior lip are cut away, and the cervix falls back into the vagina. The strip of gauze in the cervix is left long enough so that it may be packed down lightly in the vagina, after which it is cut off at the vaginal introitus. It may be removed, with the aid of a few whiffs of nitrous oxide, at the end of twenty-four hours.

The advantage of this particular method of amputation lies in the fact that it avoids the formation of lines or bands of scar tissue in the cervical wall, an objection of a definite and practical nature in case of subsequent labor. It is possible in this way to avoid the dystocia which has followed amputation by the Schroeder or Martin methods, or the trachelorrhaphy plastic of Emmett. A second advantage is that the cervix is restored to its normal conical contour.

In performing a high amputation of the cervix, the cervical canal is dilated and the uterine cavity treated as before. The lateral retractors are introduced and the cervix is again held in the grasp of two volsella, one in each lip at its midpoint. With the scalpel a clean cut incision is made entirely around the cervix through the mucosa covering its vaginal portion (Fig. 8), much the same as in a vaginal hysterectomy, except that the incision is not exactly circular. Instead, it dips down anteriorly and posteriorly towards the cervical lips, but, as a rule, the depth of its lacerations requires that it extend laterally for some distance. The anterior and posterior flaps are dissected free from the cervical walls. An iodized catgut ligature is passed on a ligature carrier just above the lateral angle of the incision on either side, and tied (Fig. 8, *c*). These are only for the purpose of ligating the vessels of the vaginal walls and hence are

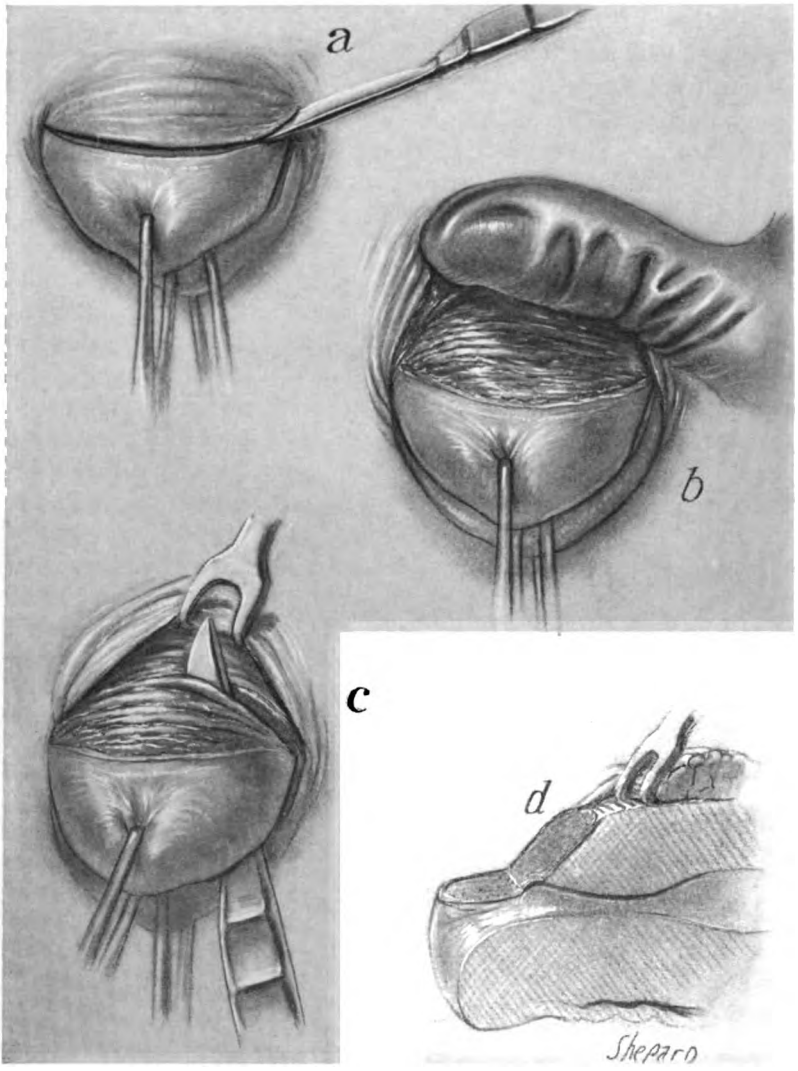

FIG. 6. LOW AMPUTATION OF THE CERVIX. Reflection of the mucous membrane and excision of the anterior lip.

not passed deeply. With the scissors the tissues are cut away from the cervical walls laterally, and the vaginal mucosa flaps are dissected further back both anteriorly and posteriorly until as much of the cervix is exposed as it is desired to amputate, i. e., until the diseased portion, or the scar tissue of laceration, has been passed. A second iodized catgut

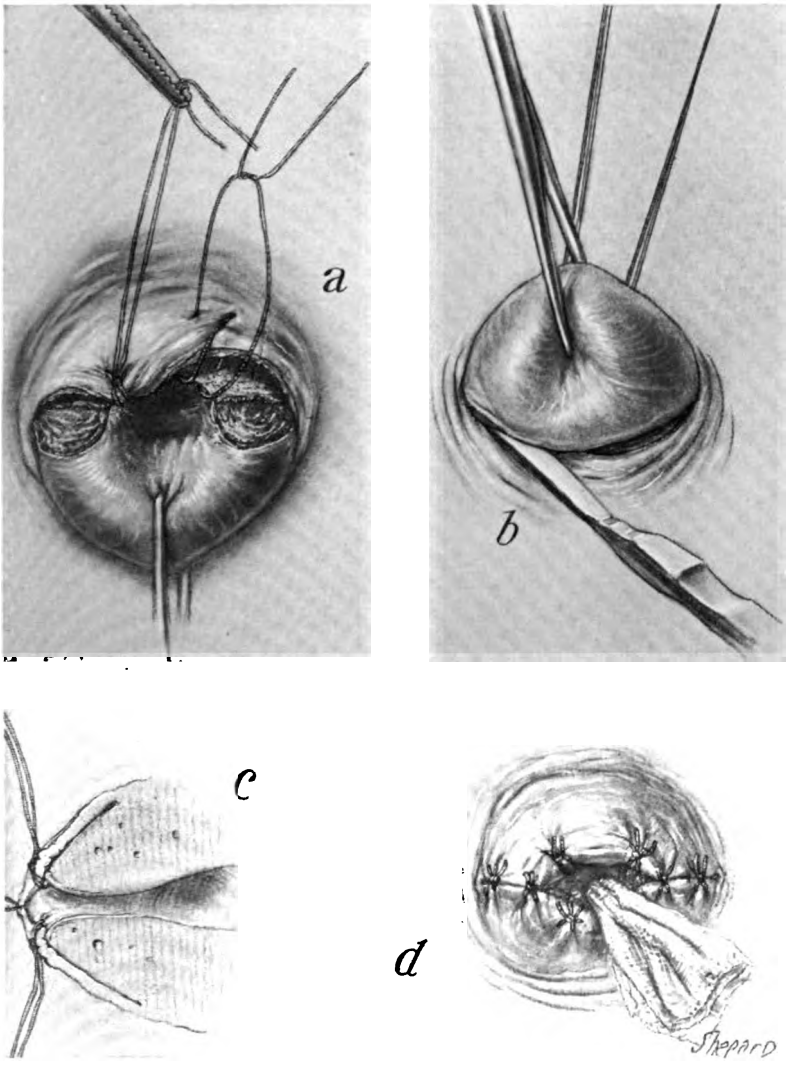

FIG. 7. LOW AMPUTATION OF THE CERVIX. Excision of the posterior lip and closure of the wound.

ligature is passed, on either side, close against the uterine wall, just above the angle of dissection, and tied (Fig. 9). In all respects this part of the procedure is the same as in vaginal hysterectomy.

From this point the operation is performed as described for low amputation. The cervix is split laterally, and each lip is amputated and

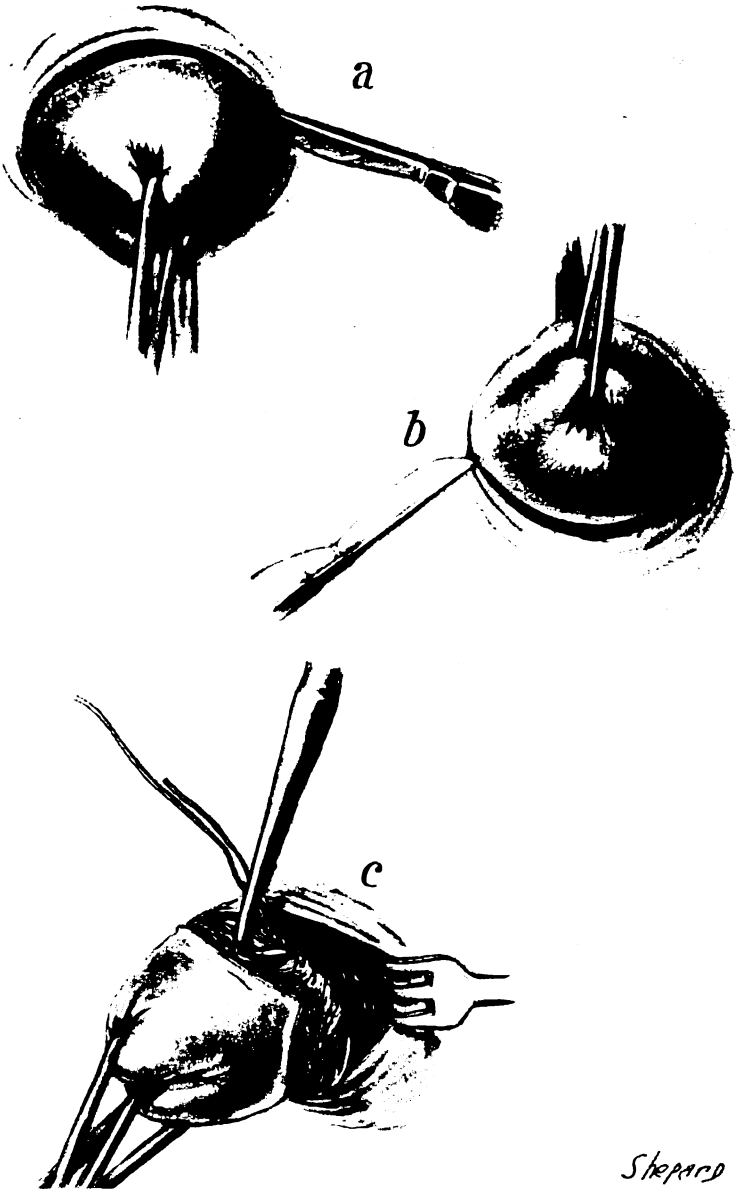

FIG. 8. HIGH AMPUTATION OF THE CERVIX. *a, b,* Incision of the cervical mucous membrane; *c,* ligation of the blood vessels of the vaginal wall.

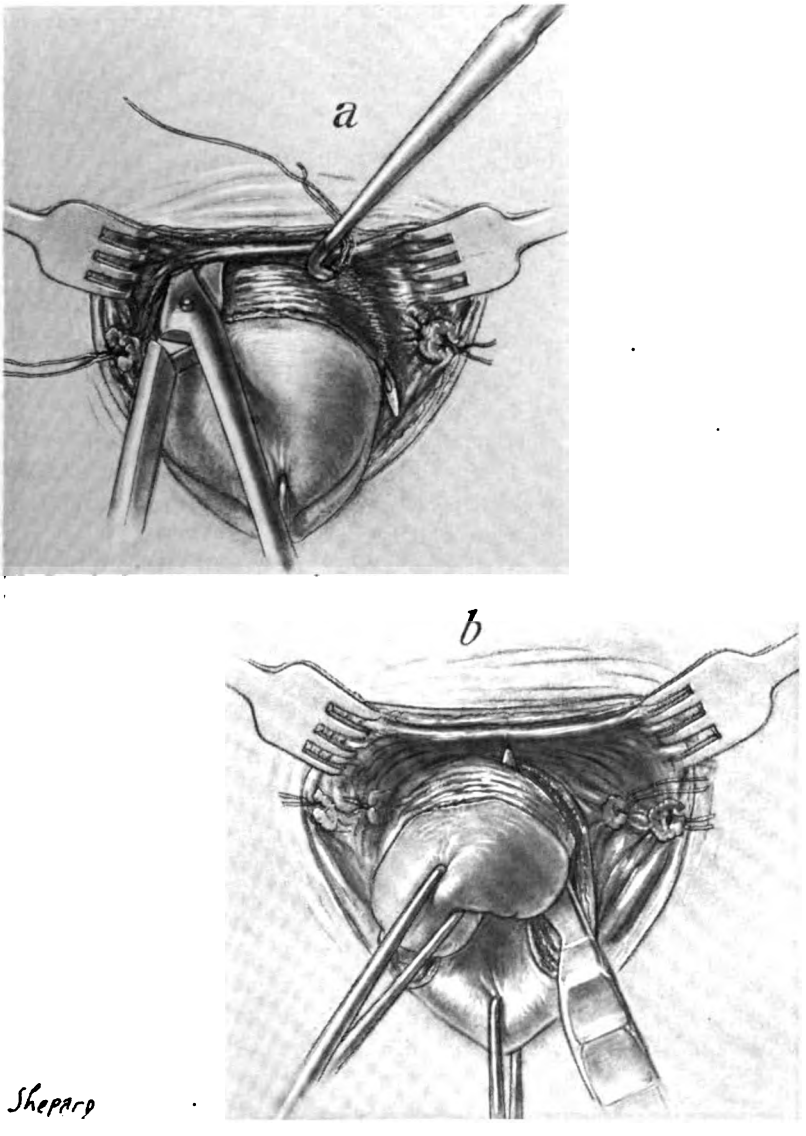

FIG. 9. HIGH AMPUTATION OF THE CERVIX.

sutured to its respective fold of vaginal mucosa. The lateral fornices are sutured as has been described. If it is desired to amputate the cervix completely, i. e., as high as the internal os, the second lateral ligatures must take in the uterine arteries. If, however, the amputation is below

the internal os the uterine arteries need not be ligated. In extremely high amputation, it will be necessary to reflect a small portion of the bladder wall, and care must be taken to avoid injury to it. If the operation for amputation is associated with anterior colporrhaphy, for prolapsus of the anterior vaginal wall or for cystocele, it is better to run the two incisions together and carry out the dissection of the vesical wall in such a way that it suffices for both procedures.

In freeing the posterior cervical wall, it must be remembered that the peritoneum of the pouch of Douglas often comes down low. In spite of this, even in extremely high amputations of the cervix, it is not necessary to penetrate the peritoneal cavity. It is not difficult to reflect the peritoneum from the cervix, and it is better to do this, even in the low operation, rather than to run the risk of passing stitches through the serosa of the cul-de-sac. There should be little or no difficulty in avoiding the rectum except in the presence of extensive adhesions following pelvic peritonitis. In such a case the finger of an assistant within the rectum will help to avoid injury of this structure.

Stenosis or atresia of the cervix. Congenital stenosis or atresia of the cervix is almost always associated with a corresponding condition of the uterus and therefore does not come under surgical treatment. Where, however, this condition is acquired subsequent to ulceration, labor trauma, or previous operations, and leads to such conditions as hydrometra, pyometra and hæmatometra, it may be possible to overcome the condition by a plastic operation. Dilatation of the cervix followed by the insertion of a tight pack may be sufficient to cure some cases. In others the narrowing of the cervical canal can be overcome by dilatation followed by excision. To accomplish this a speculum is inserted in the vagina, the cervix is exposed and seized with a volsellum and brought down, as described in the paragraphs on dilatation of the cervix. If it is impossible to pass a sound the cervix must be incised. The fluid is allowed to escape and the canal is dilated, if possible, to the size of a No. 12 Hegar dilator. Seldom will it be found that the entire canal is constricted, a condition extremely difficult to overcome. Far oftener the constricted area is at one point only in the lumen, and here scar tissue may have replaced the mucosa. As soon as dilatation is effected the scar tissue is dissected away, the mucous membrane of the cervix is sutured to the vaginal surface, and a gauze pack is placed in the vagina. Since this operation is not universally successful, since the patency of the cervix is essential to the escape of menstrual blood, and since the cervix that has become stenosed or atresic is almost certain to produce dystocia should pregnancy take place, it may be necessary to treat this condition more radically, either by amputation of the cervix or by hysterectomy.

COLPOCŒLIOTOMY

Colpocœliotomy may be performed by the anterior and by the posterior routes. Anterior colpocœliotomy is the operation performed for the purpose of opening the peritoneal cavity anterior to the uterus in order to investigate the condition of the uterus or its appendages, and to carry out certain operative procedures involving them. The conditions upon which this procedure rests, as outlined by Dührssen, are that the uterus must be one that can be readily brought down, that there should be no tumors larger than the size of one's fist, and that there should be no extensive internal adhesions.

The operation is contra-indicated in cases where there are severe parametric adhesions or where the tubes and ovaries are so extensively involved in inflammatory conditions as not to be palpable; where there are large, fixed tumors, especially if adherent; where the ovaries are enlarged and adherent to the pelvic wall; or where there are adhesions involving the bladder, especially in connection with adnexal tumors high up or with tuberculosis of the tubes.

The operation has been advocated for vaginal fixation of the uterus, for shortening the round ligaments, for exploration of intraligamentous cysts, for the enucleation of small myomata and small ovarian cysts, and for the removal of ectopic pregnancies.

The operation includes two steps: first, the separation of the bladder from the cervix and the uterus; and, second, the exposure and opening of the peritoneal cavity. In order to perform this a weighted speculum is placed in the vagina, an anterior retractor is introduced for exposure of the cervix, and the cervix is grasped by a volsellum and pulled down, the anterior blade being withdrawn in order to permit the cervix to come down as far as possible. Lateral retractors are then introduced. The anterior vaginal wall a short distance below the urethra is grasped in the volsella and traction made upwards. With the cervix held well down against the weighted speculum and as far through the vaginal introitus as it can be brought, an incision is made through the mucosa at the point where the vaginal mucous membrane is reflected from the cervix (Fig. 10). This incision extends from side to side about the anterior cervical wall. The vaginal mucosa is reflected upward for a short distance until the margin of the bladder is reached. The lower portion of the base of the bladder can then be readily separated from the cervix by the finger wrapped in gauze. The dissection may be carried out readily enough from this point, but more room can be obtained by incising the anterior vaginal wall from the midpoint of the previous incision upward for 2 or 3 cm. The angles of the vaginal mucosa thus made are grasped

by two artery forceps, and with the scissors the vaginal wall is dissected away from the bladder. The two corners having been dissected free, the finger wrapped in gauze dissects away the bladder laterally as far as

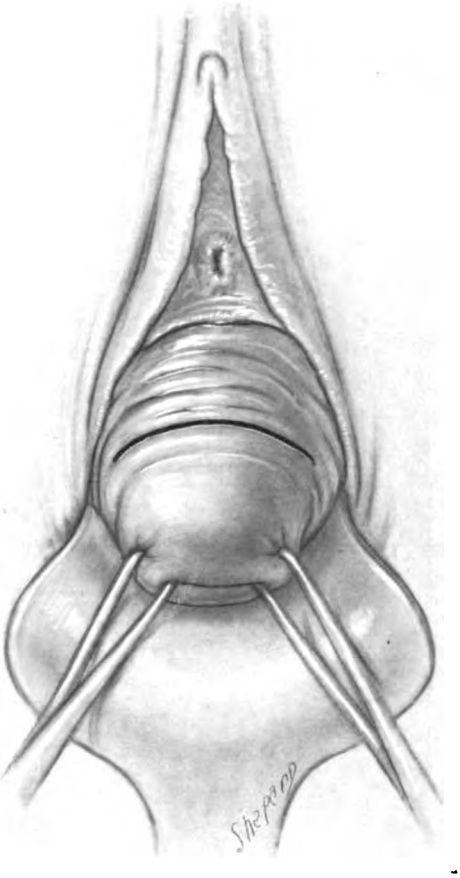

FIG. 10. INCISION FOR COLPOCŒLIOTOMY.

desired. After the bladder has been freed anteriorly, it is much more readily separated from the cervix and the lateral uterine wall higher up. Occasionally the thick vesico-uterine ligament must be cut through in the midline before the peritoneum is reached. Every effort is made to avoid injury to the bladder, and if the operator is in any doubt as to its position, the sound passed through the urethra should be kept *in situ*. As soon as the peritoneum is reached the bladder is elevated by an anterior retractor

so that fully one-half inch of peritoneum, if not more, is exposed. With the cervix still held strongly downward, the peritoneum is seized with a long tissue forceps and pulled away from the uterine wall. It can then be opened with the scissors. It is extremely important that the bladder be held well up out of the way, at least one-half inch above the upper angle of the longitudinal incision. This gives more room after reaching the peritoneal fold, and after the peritoneal cavity is opened. As soon as the peritoneal fold has been snipped through with the scissors the incision can be carried upward as far as the bladder has been loosened from the peritoneum, or it may be carried lateralward on either side to the broad ligaments of the uterus, the method depending upon the amount of exposure required. For simple pelvic exploration, or for examination of the uterus or its appendages it is sufficient to incise the base of the anterior pouch transversely. For shortening of the round ligaments, or for pulling the uterus into anteversion in order to perform salpingectomy or resection of the ends of the tube, it will be necessary to enlarge the incision, as first suggested, in a vertical direction.

In palpating the corpus of the uterus through this incision, as soon as the peritoneum is opened and sufficient exposure is obtained the anterior retractor is passed into the peritoneal cavity. Care must be taken at this time to avoid the omentum or loop of intestine which is very apt to come down into the field. In order to avoid such a complication it is best to introduce at once a small laparotomy pad with a long tape to which an artery forceps has been applied. With the anterior retractor supporting the bladder and holding open the anterior peritoneal pouch, the wall of the uterus is exposed. This is seized as high up as possible with a volsellum forceps and brought down into the field, the cervix at the same time being displaced backward by the volsellum already attached to it. This enables one to bring the corpus of the uterus well down into the field, but, as a rule, not sufficiently far for its complete delivery. With another volsellum the anterior uterine wall is seized high up, and by gentle traction the corpus is brought further and further into the field until the fundus is brought through the incision. Before this can be accomplished it may be necessary to introduce the index finger into the pelvic cavity, and by sweeping it around the fundus of the uterus break up such adhesions as may be present. The efficacy of this operation depends upon the relative or actual freedom of the uterus. Where the adhesions are light and readily broken up no difficulty will be experienced in freeing the uterus and bringing it into the field of operation. Neither will raw areas then be left which cannot be peritonized. Where the adhesions are extensive or extremely dense, or so well organized that freeing them is difficult if not impossible, or where after the uterus has

been freed, extensive raw areas are left in the pelvis, postoperative adhesions can only result if any further operative procedures are undertaken. This holds true, likewise, for adhesions involving the appendages, particularly when the tubes or ovaries are fixed by organized adhesions to the pelvic walls.

After the fundus of the uterus is delivered into the field of operation, the tubes and ovaries are examined and such operative procedures as deemed necessary are carried out.

In closure of the wound the thing of first importance is the closure of the peritoneal opening. This is done by suture of the vertical incision first and of the lateral one afterward, care being taken to turn the cut edges outward. The vertical incision in the vaginal wall is closed with a continuous suture of chromic catgut on a sharp, curved needle; and the transverse incision about the cervix last of all. The greatest care must be exercised in accurately approximating the edges of the vaginal wound, in order to prevent puckering during the process of healing and shortening of the anterior vaginal wall.

This operation may be combined with or made a part of anterior colporrhaphy, with or without elevation of the bladder.

Posterior colpotomy. Posterior colpotomy is indicated in but one condition, i.e., suppurative inflammation of the parametrium.

With a weighted speculum in the vagina, the posterior cervical lip is seized with a volsellum and drawn forwards and upwards. With lateral retractors introduced into the vagina this should give adequate exposure of the posterior vaginal fornix. With a scalpel a transverse incision is made about the posterior cervical wall through the mucosa covering the vaginal portion of the cervix (Fig. 11). Where the parametria are involved this incision alone is sufficient for drainage. In some cases, however, the suppurative process has not come down in the midline posteriorly, in which case it may be necessary to strip back the connective tissue, with the finger wrapped in gauze, until the peritoneum is exposed Exploration laterally on either side will open into the abscess cavities. This is done either with a curved clamp which is passed in and then opened, thus enlarging the hole through which the pus may escape, or it may be done with curved scissors. While a transverse incision alone may be sufficient for the evacuation of the abscess, it is not always adequate for maintenance of drainage subsequently. In order to obviate this difficulty it is wiser to extend the opening downward by incision of the vaginal wall in the midline at right angles to the transverse incision. This need not be a long incision, 2 or 2.5 cm. being sufficient. Care is taken only to avoid the rectum. As a rule parametritic abscesses bulge well down laterally or posteriorly, and at times even separate the vagina

from the rectum, so that in the majority of cases there is relatively little danger of injuring the rectum in making this incision.

Inasmuch as the wound is made for drainage of an abscess it is not closed. After the pus has drained away, a light strip of rubber tissue is inserted. Packing the wound must be avoided but the strip must be long

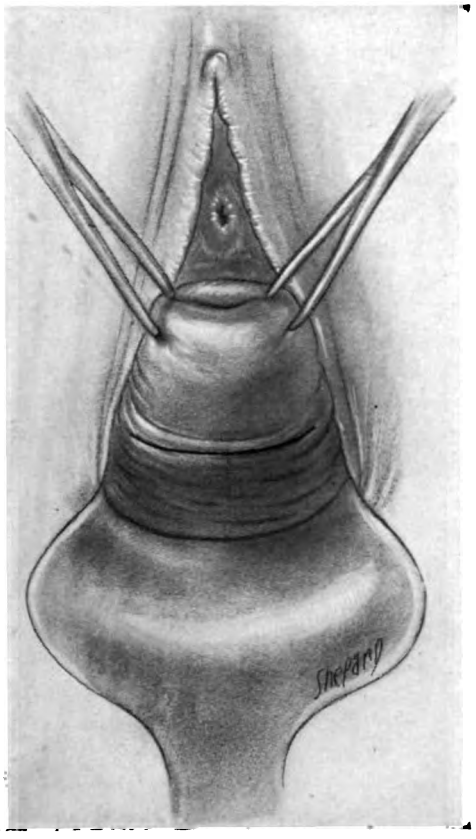

FIG. 11. INCISION FOR POSTERIOR VAGINAL COLPOTOMY.

enough to pass well through the wound and yet project from the vagina. It is removed twenty-four hours later, when another strip may be inserted or not, according to the judgment of the surgeon.

Posterior colpocœliotomy. This operation is undertaken for the purpose of opening into the posterior pelvis through the pouch of Douglas. It is carried out in order to drain the pelvis, for the purpose of examining the uterus and its appendages, to break up adhesions, and to perform certain operative procedures about the uterus or its ap-

pendages, such as the removal of small subserous fibroids, plastic operations upon the tubes, or the removal of small ovarian tumors.

The operation is carried out as has already been described under posterior colpotomy. The peritoneum having been exposed posteriorly by a separation of the connective tissue from the posterior cervical wall, the opening into the peritoneal cavity is made with scissors after the peritoneum has been seized with long tissue forceps and pulled away from the posterior uterine wall. The incision is then extended laterally on either side, after which the finger can readily be introduced into the pelvis, and the uterus and its appendages definitely palpated. Only rarely will it be necessary to increase the peritoneal wound by an anteroposterior peritoneal incision.

If for drainage, the operation ends as soon as the pus sacs have been opened up and the material has come away, a rubber tissue drain being introduced as described in posterior colpotomy. Where the procedure has been undertaken for the purpose of further operations upon the uterus or its appendages, the uterus must be brought into the field of operation. With the cervix pulled well up toward the symphysis the posterior uterine wall is grasped by a volsellum and pulled down. A second volsellum is introduced along the corpus until it is possible to deliver the fundus into the vagina. To avoid a prolapse of the intestine a small laparotomy pad on a long tape is introduced before the uterus is brought down.

Where closure without drainage is desired, the free peritoneal edge is stitched by light iodized catgut back to its proper situation in the posterior cervical wall, after which the vaginal wall is closed with a continuous chromic catgut suture.

OPERATIONS UPON THE BLADDER AND URETHRA

Vaginal cystotomy. Operation for the production of a vesicovaginal fistula is indicated in those conditions where it is necessary to drain the urinary bladder through the vagina. Most frequently the indication is found in stricture of the urethra resulting from chronic cystitis and urethritis, not tuberculous in nature. It has been employed also for drainage in the cure of ulcer of the bladder, and by clinicians in past years, for the removal of vesical calculi, or of such foreign bodies as cannot be removed by way of the urethra.

For its performance a vaginal speculum is introduced and the anterior vaginal wall exposed by grasping it with one volsellum just below the urethra and with another well anterior to the cervix uteri. A sound passed through the urethra into the bladder is made to depress the anterior

vaginal wall in the median line, and an incision with the scalpel is made over this point through the vaginal wall, vesical septum, and into the bladder. The sound is then withdrawn from the bladder and, after the vesical contents have escaped, the index finger is introduced into the wound and the incision enlarged as may be desired with the scissors. It is important that this incision be made exactly in the median line and that it be as far anterior as possible in order to avoid the ureteral orifices. The foreign body or stone is removed, after which the incision is closed exactly as described for closure of vesicovaginal fistula.

Where drainage is an indication the patency of the wound must be maintained. As the vesical mucosa tends to become everted its edges are seized with forceps, drawn out through the incision, and stitched to the vaginal mucous membrane with one or two interrupted catgut sutures on either side. At the completion of the operation the orifice should be about twice as large as would appear necessary for drainage, since subsequent contracture will reduce it to a considerable extent.

Extirpation of urethral caruncle. The orifice of the external urinary meatus is dilated, the caruncle is seized with forceps and drawn well down into view. A wedge-shaped incision is made through the posterior urethral wall well below the base of the growth. This is best done with a scalpel in order that the incision may be clean and not carried too high up into the urethral canal. Laterally and externally the incision should be quite wide of the growth (Fig. 12). Incision is usually followed by free bleeding, owing to the vascular character of the tumor and its pedicle. The bleeding is best stopped by the introduction of one or two fine chromic catgut sutures which approximate the edges of the urethral mucosa from side to side and help to avoid stricture of the external urinary meatus.

The importance of thorough removal of the caruncle cannot be overemphasized, because of the tendency of these growths to recur. For the same reason the cauterization method of extirpation is not regarded by the writer as sufficiently adequate.

Prolapse of the urethra. The urethral orifice is dilated, the prolapsed portion of the urethra seized with forceps and drawn downward and outward. While it is thus held on the stretch, incisions are made on each side at the junction of the mucous membrane of the urethra with that of the vestibule. A suture is passed from the free edge externally, through the mucosa and back through the free edge on the same side—virtually a mattress suture. This is tied and a corresponding suture is introduced on the other side and tied. The prolapsed portion of the urethral mucous membrane is removed with scissors, after which the cut edge of the mucosa is sutured to the external edge anteriorly and again

posteriorly. In this way any retraction of the urethral mucosa is prevented, a condition which would occur if it were not sutured to the free edge externally before the redundant portion is cut away. Care must be

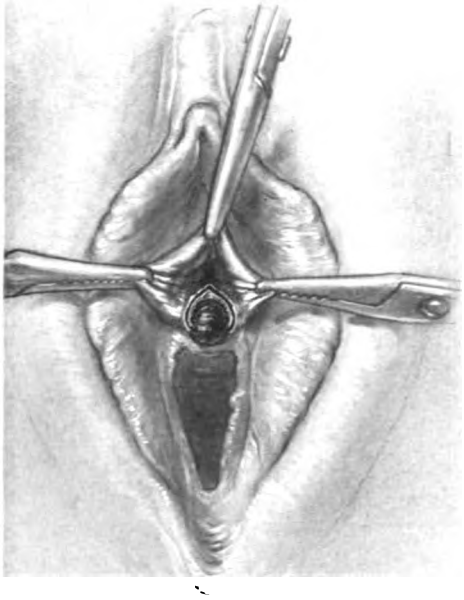

FIG. 12. LINE OF INCISION FOR EXCISION OF URETHRAL CARUNCLE.

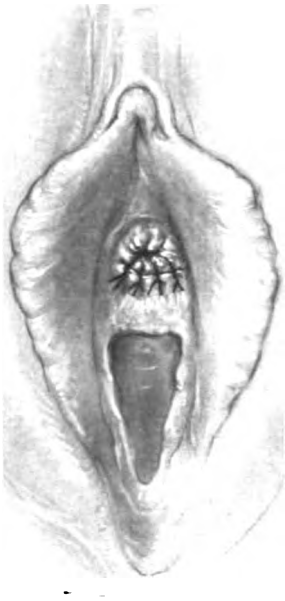

FIG. 13. APPEARANCE AT COMPLETION OF OPERATION.

taken to bring the urethral mucosa well down from above and to suture it widely in order to avoid postoperative stricture.

OPERATIONS UPON THE VULVA

Excision of the vulva. Excision of the vulva in part or in whole is indicated in certain extensive diseases, such as carcinoma, sarcoma, kraurosis vulvae, elephantiasis, etc.

An incision through the skin and subcutaneous tissues down to the deep fascia and well clear of the involved area is carried from above the clitoris downward and posteriorly on each side to the fourchette. The

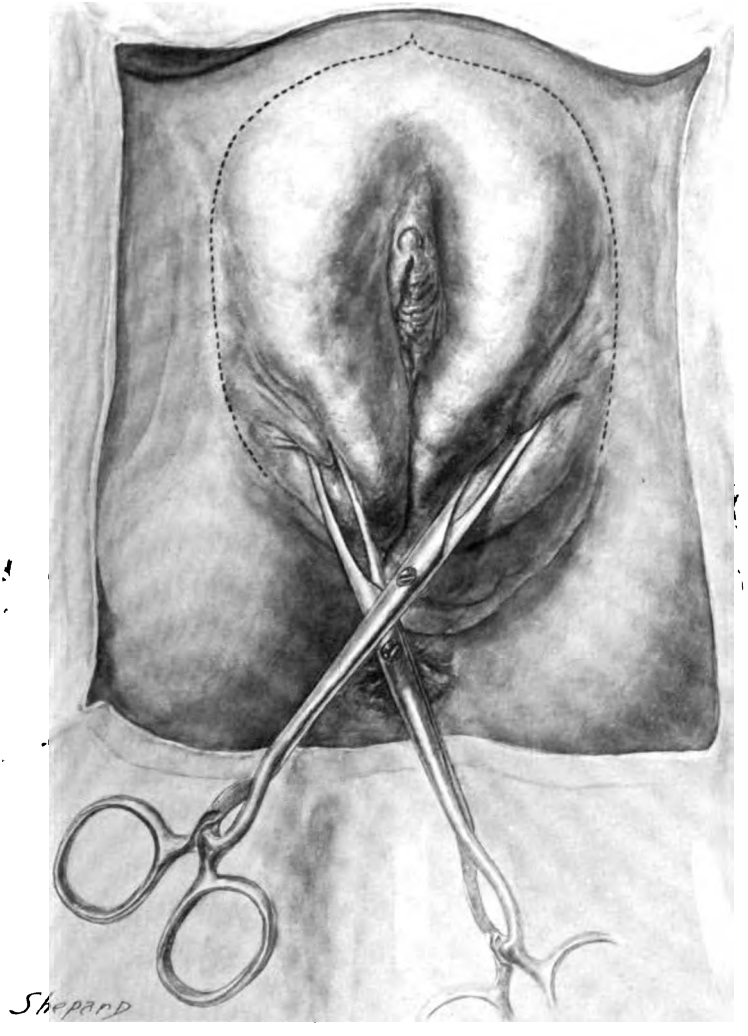

FIG. 14. ELEPHANTIASIS OF THE VULVA. Line of incision.

incision includes both labia majora and thus describes a complete oval about the entire vulva (Fig. 14). A second incision is made around the urinary meatus and the vaginal orifice (Fig. 15). The tissues between these two incisions down to the deep fascia are dissected

free in a single piece, the arteries being clamped and ligated as they are met. The worst of these bleeders are the basilar artery of the clitoris

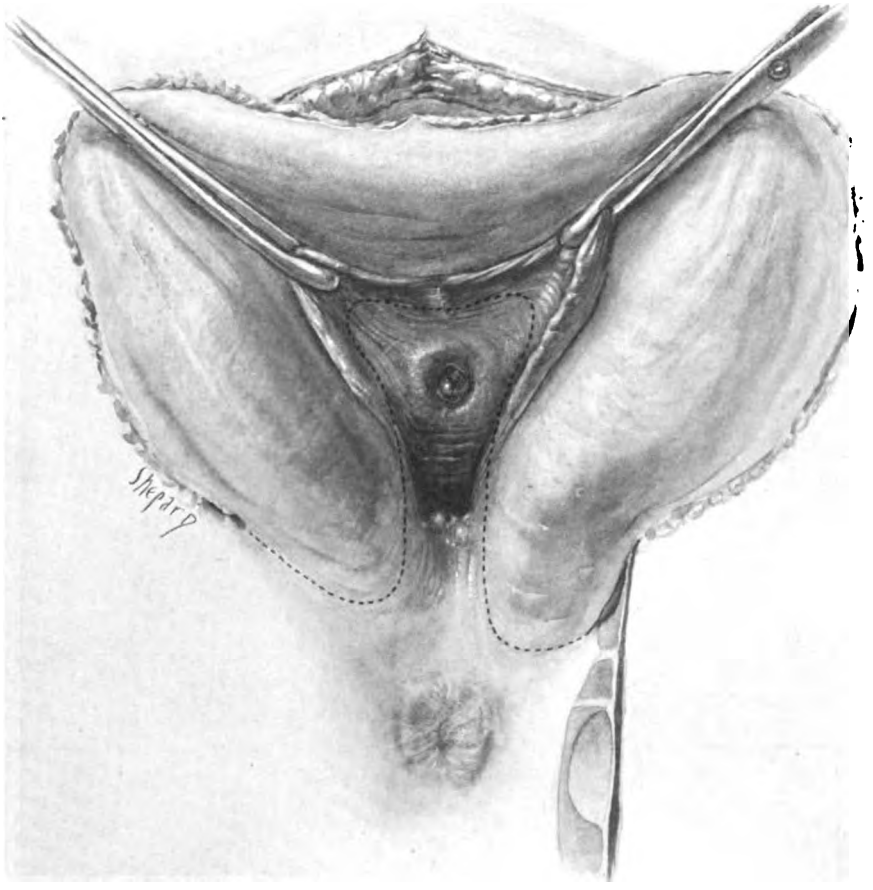

FIG. 15. ELEPHANTIASIS OF THE VULVA. Resection of the redundant tissue between the two lines of incision.

and some large vessels in the region of the vestibule, which may require mattress sutures beneath the vascular area. After the removal of the resected tissues, the edges of the skin are freed for a short distance, as

well as the edges of the mucosa about the urethra and the vaginal introitus. The subcutaneous tissues above the level of the urethral orifice are brought together by iodized catgut, after which the right and left edges of the incision itself are approximated with interrupted silk sutures. Below the urethra the cut edges of the skin and the vagina are brought

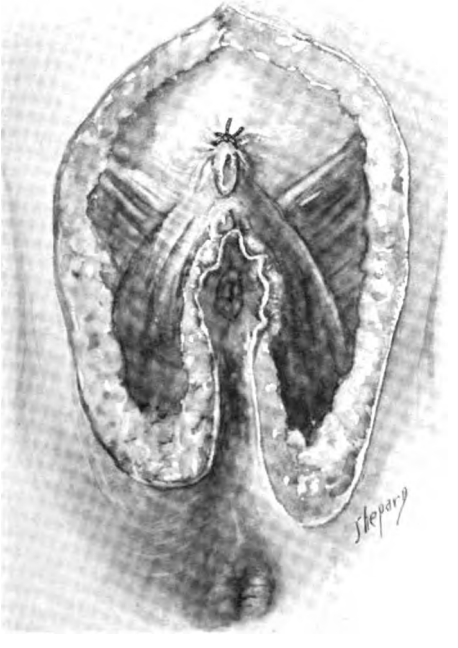

FIG. 16. ELEPHANTIASIS OF THE VULVA. Appearance after removal of the redundant tissue; the bulbo-cavernosus muscle (sphincter vaginæ) is exposed in almost its entire extent.

together in their respective relations. In some instances it may be necessary to free as much as one inch of the lower end of the vagina in order to accomplish this approximation without undue tension. Where opposing edges are widely separated tension may be overcome by the introduction of occasional subcutaneous catgut sutures, which aid also in securing more perfect hæmostasis (Fig. 17).

The incision about the urethra should be as wide as possible, and where the vestibule itself is not involved in the diseased process most of it had best be left.

Danger of postoperative sloughing is greatest about the urethra, and the ever-present possibility of infection in tissues containing so much fat must not be forgotten. In cases of cancer, where the inguinal glands are to be removed, the incision is extended, parallel to Poupart's ligaments, from the upper part of the already denuded area into both inguinal regions. The skin flaps are turned back and all the soft tissues down

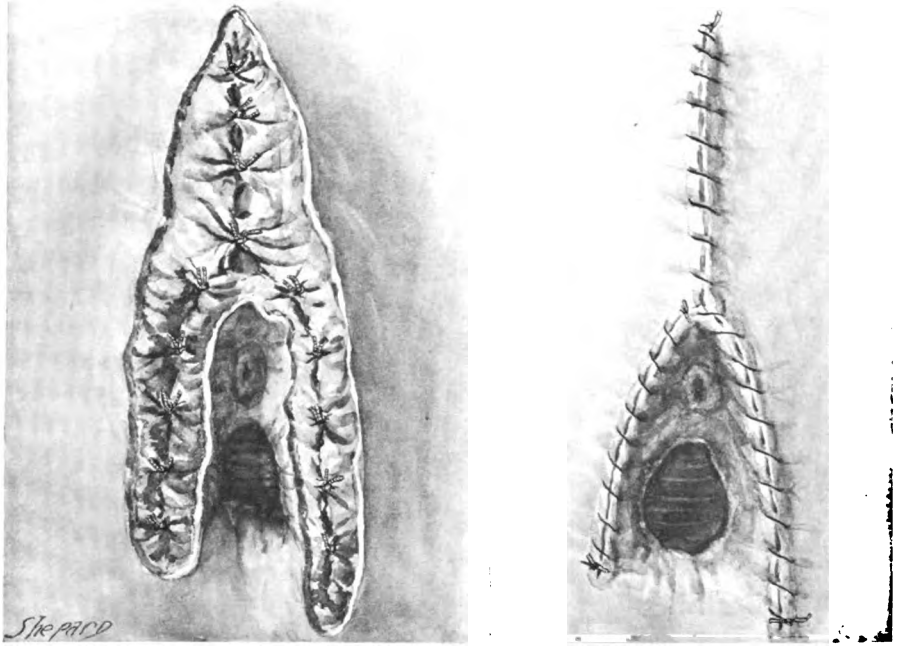

FIG. 17. ELEPHANTIASIS OF THE VULVA. Closure of the wound.

to the aponeurosis, including the glands, are dissected out in one piece. Bleeding vessels are ligated and the incisions closed. Owing to the extreme vascularity of these tissues and the fact that for excision of the vulva the patient must be in the lithotomy position, whereas for excision of the inguinal glands the legs must be extended, it is best to perform one part of this operation and close the wound before undertaking the other.

Partial excision of the vulva is carried out on exactly the same lines. Ablation of the hypertrophic labia is very apt to be associated with free hæmorrhage.

Circumcision. This operation is indicated where the prepuce about the clitoris is redundant or large and flabby. The prepuce is grasped on either side of the gland and held open. A mesial incision is then made along the dorsum of the clitoris with a scalpel, the redundant portion is dissected away and each half removed separately. The raw edges are brought into approximation with chromic catgut or silk.

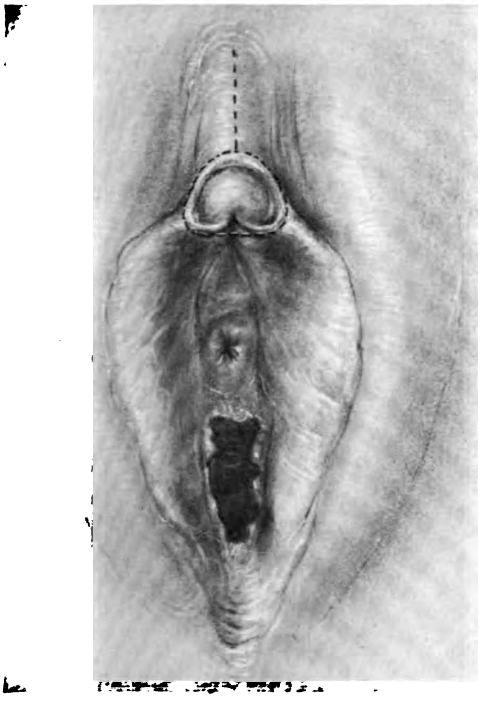

FIG. 18. LINE OF INCISION FOR RESECTION OF THE CLITORIS.

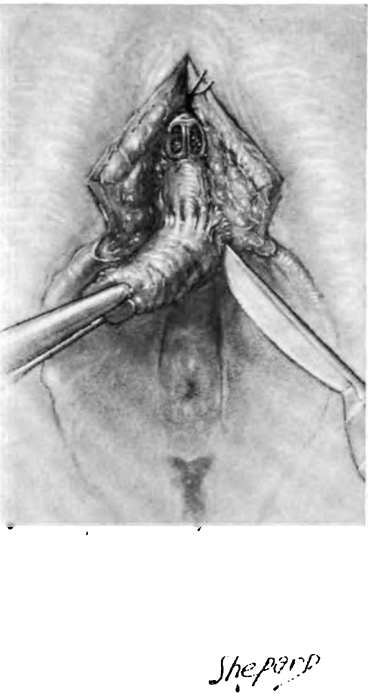

FIG. 19. RESECTION OF THE HYPERTROPHIED CLITORIS.

Clitoridectomy. The operation for removal of the clitoris is indicated where this organ is hypertrophied or where it is diseased, particularly if that disease be a malignant one.

The skin is incised around the base of the organ, the incision extending deeply, close to the symphysis (Fig. 19). The tissues about the clitoris are dissected free until it is well exposed. It is then divided close to the crura, the incision passing from above downward. The divided end of the body is grasped with forceps and each half dissected away from its junction with the pubic arch. As the arteries are cut they are grasped

with forceps and ligated. The skin edges are coaptated with interrupted silk sutures.

Amputation of the clitoris, an operation somewhat less extensive than clitoridectomy, is indicated only in excessive hypertrophy. Here the hypertrophied portion is removed by a wedge-shaped incision from side

FIG. 20. DISCISSION OF THE HYMEN.

to side, close down toward the base of the organ. The wound is closed by one or two interrupted silk sutures.

Discission of the hymen. This operation is indicated where the hymen is imperforate. A small incision is made through the bulging hymen from before backwards. The blood and mucus collected in the vagina are allowed to escape. The incision is enlarged and another, from side to side at right angles to the first, is made. This produces four small, angular, mucous membrane tags which may be ignored (Fig. 20). As a rule, the vascularity is slight and it is not necessary to clamp bleeding vessels or to suture the raw edges.

Where the vagina alone is distended with retained menstrual material it may be irrigated until clean and the wound lightly packed with a strip of gauze. Where the uterus and tubes are distended the wound must be left open in order that drainage may continue.

Enlargement of the vaginal introitus. Operation for enlarging the vaginal introitus is indicated chiefly for the condition known as vaginismus. Where gradual or forcible dilatation is not sufficient to overcome this at times obstinate condition, an incision may be the only method that will bring the required relief. The anterior vaginal wall is elevated with a flat-bladed retractor and a deep incision is made into the perineum from the edge of the vaginal introitus one-third or one-half way to the anus (Fig. 21). Each vaginal sulcus is incised for an inch or an inch and a half, the two incisions converging towards the median line and uniting with the perineal incision. These incisions must be deep enough to divide the fascia down to the underlying muscle fibers. The gaping of the cut edges of these three incisions forms a somewhat Y-shaped continuous wound which is closed by approximating its edges anteroposteriorly with interrupted silk sutures. As explained by Ashton, the operation results in more or less relaxation of the vaginal introitus, relieving spasmodic contractions by lessening the contractile action of the bulbocavernosus and levator ani muscles.

Plastic separation of the labia is indicated where the labia are adherent, this adherence being congenital or acquired as a result of chronic vulvitis.

A curved director is passed through such opening as persists and the tissues are divided in the median line with a scalpel or scissors. Where adherence is considerable, extending close to the urethra, it may be necessary to pass a sound into the urethra in order to avoid injury. If the raw surfaces are extensive the wound may be closed on either side with a few interrupted chromic catgut sutures. Otherwise the parts may be kept separated by a light gauze pack, to be removed and replaced daily until the wound is healed.

Extirpation of benign tumors and cysts of the vulva. As a rule benign tumors or cysts of the vulva are small in size, though they may become large enough to cause considerable swelling underneath the skin. Hard tumors, with the exception of angiomata, are seldom vascular, and the cysts are usually of a sebaceous nature, occupying the lower portion of the labia majora.

An incision from above downward is made directly over the most prominent portion of the swelling, parallel with the labium. The skin edges are grasped with hæmostats and separated, and the tumor is then readily dissected free from the surrounding structures with the scalpel

or scissors. Blunt dissection may be sufficient, particularly in the case of an hard tumor. Where it is desired not to spill the cyst contents, as in a sebaceous cyst, sharp dissection may accomplish this end most success-

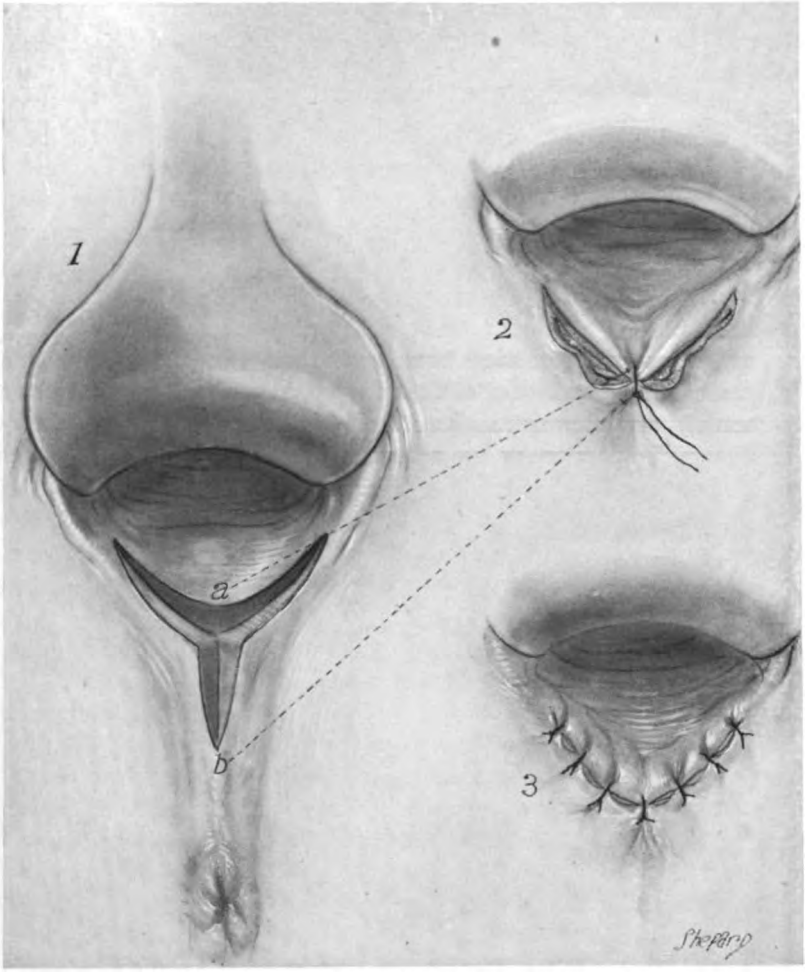

FIG. 21. ENLARGEMENT OF THE VAGINAL INTROITUS. The Y-shaped incision is converted into a V by interrupted sutures.

fully. Following extirpation of the cyst the space left is closed from below upwards by interrupted over-and-over sutures of iodized catgut until no free pocket remains. The skin edges are approximated by interrupted silk sutures.

Extirpation of the vulvovaginal gland. This is indicated in chronic inflammation of the gland or where it has become cystic. An incision is made through the skin over the entire length of the swelling, just lateral to its junction with the mucous membrane and parallel with the labium. The tumor is separated gently from the surrounding tissues, care being taken first to separate the vaginal surface of the labium from the gland. By this method it is possible to avoid buttonholing the thin

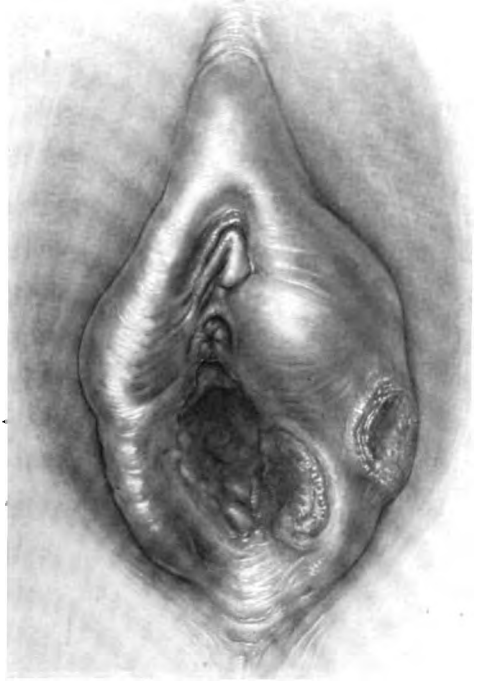

FIG. 22. MALIGNANT DISEASE OF THE VULVA.

mucous membrane of the inner surface of the labium. Throughout the operation sharp dissection will prove to be more certain in avoiding laceration of the delicate structure of the labium. Posteriorly only the scalpel or scissors will free the denser tissues. The vascular bulb may be avoided by not carrying the incision too high. In any event a branch of the internal pudic artery and vein will be encountered above and posteriorly. These must be clamped and ligated as they are cut. Where the cyst has been of considerable size, an extensive pocket will be left after its extirpa-

tion. In such cases it is best to approximate the submucous and subcutaneous tissues by interrupted over-and-over buried sutures of iodized catgut. At least one layer of catgut is advisable and in some instances two may be necessary. The skin and mucous membrane edges are brought into approximation by interrupted silk sutures. The sutures are so tied that they remain outside of the vagina.

Hydrocele of the labia majora. Hydrocele of the labia majora is a rare condition produced by an accumulation of serous fluid in the peritoneal sac formed in the canal of Nuck during fœtal life. The fluid may become hæmorrhagic or purulent as a result of infection. In order to accomplish its removal an incision is made through the skin over the most prominent part of the swelling, parallel to its long diameter. The skin edges are separated with retractors or with hæmostatic clamps. The sac is exposed and partially dissected free. In the majority of cases it is shut off from the peritoneal cavity, but since this condition is not constantly present it is best to open the sac and evacuate its contents. It may then be dissected out if it is free from the peritoneal cavity. If not free its neck must be ligated before the dissection is completed. The internal abdominal ring, if it be large, is closed with interrupted catgut sutures placed through the borders of the transversalis and internal oblique muscles and Poupart's ligament. The skin edges are approximated with interrupted silk sutures.

Extirpation of varicose veins. Varicocele of the labium is removed by an incision over the most prominent part of the bulging mass, the skin having put on the stretch by traction above and below. After the skin is incised its edges are reflected until the veins are exposed. With blunt dissection they are then freed from their bed, drawn out and tied off as far apart as possible, i.e., at the upper and lower angles of the wound. The portions between the two ligatures are excised and the two ligatures are tied together. The wound is closed by approximating the skin edges with interrupted silk sutures.

OPERATIONS UPON THE VAGINA

Atresia or stenosis of the vagina. Cases of atresia or stenosis of the vagina may be divided into three groups: (1) Those in which a transverse septum exists, closing off the vagina in some part of its course; (2) those in which the vaginal canal in some part of its course is absent; (3) those in which there is an entire absence of the vagina.

In the first group the condition is either congenital or acquired, the acquired form being due in a great proportion of cases to injury resulting from labor. In either case the operation for its correction consists in a

simple dissection of the transverse septum. It is similar in many respects to that for imperforate hymen. Where the septum has a small circular perforation this must be dissected away first. In some cases, particularly where the base of the contraction ring is broad, it will be necessary to remove the entire septum well back into the vaginal walls in order to avoid reunion of the raw edges that would be left following discission. The two edges of the vaginal canal thus left separated are united by interrupted chromic catgut sutures. As a rule, two or three sutures anteriorly, the same number posteriorly, and one on each side are sufficient. A gauze pack is introduced to serve simply as a surgical dressing for the wound, and should be removed at the end of forty-eight hours.

The cases comprising the second group are in nearly every instance congenital in origin, though conditions that are nearly indentical may result following the trauma of labor. Here a transverse incision is made across what should be the vaginal orifice, and with the finger and scissors the wound is gradually enlarged upward. The bladder and rectum may be avoided by introducing a sound into the bladder and a rectal speculum into the rectum in order to protect these structures. The dissection is carried up until the patent vaginal canal is reached. The retained fluid is then allowed to escape. The skin at the vaginal introitus is freed entirely around the orifice and united with the vaginal mucosa in order to cover all the raw edges. It will probably be necessary to undermine the vaginal mucosa to some extent, the exact technique depending upon the length of the wound resulting from the dissection through the atresic area. Where this is of considerable length it is not always possible to bring the skin and vaginal mucosa together. In such cases it will be necessary either to perform a hysterectomy and permit the vagina to close or, better, to construct an entirely new artificial vagina. Where it is possible to unite the skin edge with the mucous edge a gauze pack is introduced rather firmly to serve as a surgical dressing, and the vagina is kept dilated with a glass tube or dilator.

Complete absence of the vagina is usually congenital, but there have been cases reported where, as a result of labor injury, the vaginal tube has been so considerably destroyed as virtually to produce atresia.

Various methods have been devised in past years for the purpose of securing a patent vagina where it is absent or has been destroyed. Attempts to transplant skin flaps from the thighs or mucous membrane from other patients, as suggested by Bech and Mackenrodt, have been made, but with no success. The first effort to reconstruct a vaginal canal by use of intestinal tissue was reported by Snevireff in 1892. This operator employed a portion of the rectum after resection of the coccyx, but the result was only moderately satisfactory. In 1904 Baldwin suggested

the employment of the sigmoid colon or of a loop of ileum to serve in the reconstruction of an artificial vagina in the case of a woman whose vaginal canal had been destroyed as the result of a difficult labor. Subsequently Baldwin was able to accomplish this in other cases, and today his operation is somewhat widely employed with almost uniform success (Fig. 23).

Baldwin's operation is performed in three stages. In the first stage a perineal incision is made from above downward, between the labia, in the position where the vaginal introitus normally should exist. Blunt dissection separates the structures as far upwards as possible; it is not necessary, however, to carry the separation into the pelvic peritoneum. The abdomen is opened, and a loop of ileum 10 inches from the cæcum is isolated. This loop, about 12 inches in length, is resected and the free ends of the loop inverted by purse-string sutures. Care must be taken to preserve the blood supply of the resected portion. Restoration of intestinal continuity is accomplished by a preferred method of anastomosis. The detached loop of intestine is then drawn down into the pelvis, the peritoneum at the point covering the dissected tract is opened, and the folded ileum is drawn down into it by means of a piece of tape tied loosely to its center. This tape is tucked into the previously dissected canal, through the peritoneum, whence it is pulled down from below until the loop of ileum protrudes beyond the skin border. The parietal peritoneum at the center of the broad ligaments, or the vesicorectal septum, is reunited around the proximal ends of the intestinal loop, thus isolating them from the general peritoneal cavity. The abdomen is then closed.

The patient is again placed in the lithotomy position, thus exposing the intestine protruding from the perineal wound. This is secured in place with several interrupted chromic catgut sutures. The convex surface of the loop is incised and each limb of the loop is cleansed and packed with gauze. Ten days later the septum between the two limbs is destroyed by clamp pressure.

Since Baldwin reported in 1910 the six cases operated on successfully up to that time, some modifications have been suggested, which would appear to add to the feasibility of the procedure. Robinson has recently described an operation performed in all respects according to that suggested by Baldwin except that but two stages are required. In the first stage, as Robinson performs the operation, the abdomen is opened, a loop of ileum is isolated as before, and the continuity of the intestinal lumen restored by an end-to-end anastomosis. A transverse incision is then made through the peritoneum between the two bulb-like portions of the rudimentary uterus, after which the septum between the bladder and the rectum is dissected free down to the floor of the pelvis. In the meantime

an assistant pushes a dull instrument from below against the roof of the vaginal pouch, thus putting it on the stretch and bringing it in closer

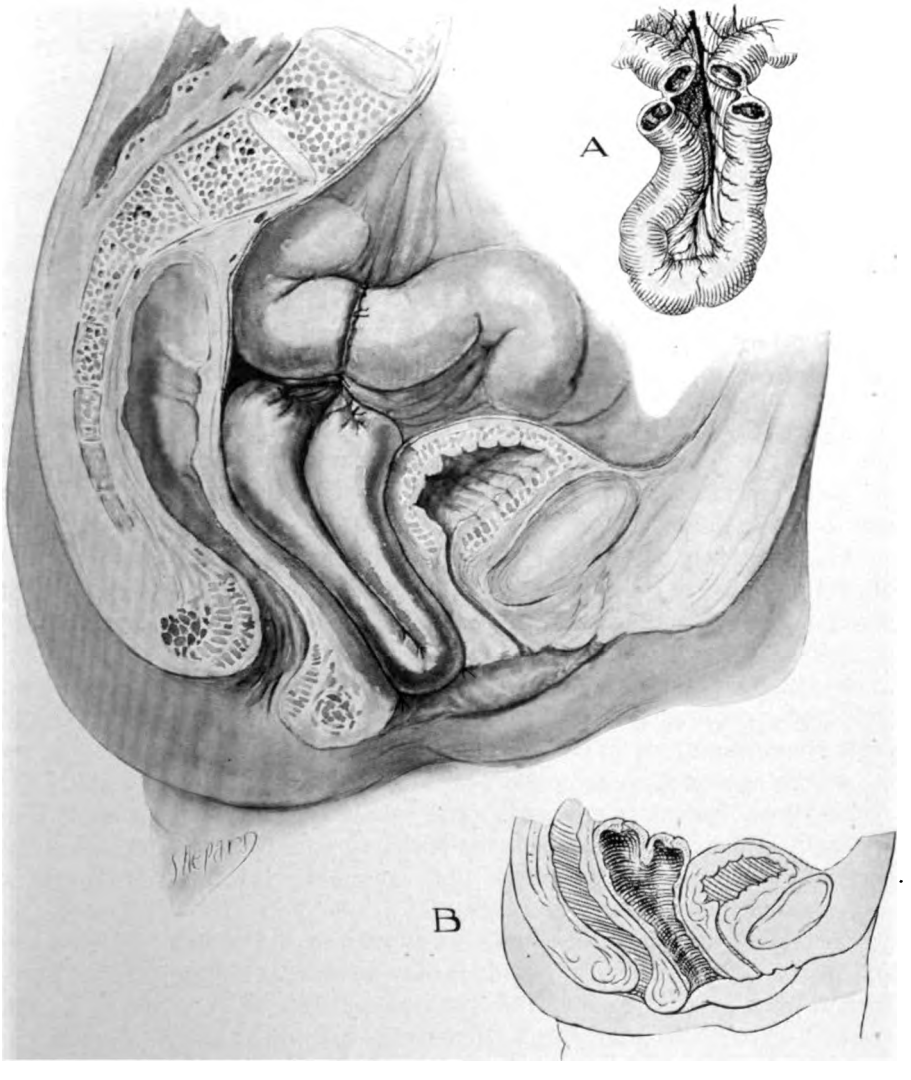

FIG. 23. FORMATION OF AN ARTIFICIAL VAGINA FROM A LOOP OF ILEUM.

apposition to the floor of the pelvis. An incision over this point establishes communication between the vaginal skin depression and the peritoneal cavity. This dissection is apparently done with comparative ease

and with greater assurance than when it is started blindly from below. By this method the bladder and rectum are always under the vision of the operator and he does not have to rely solely on his sense of touch.

The patient is now placed in the lithotomy position, so as to expose the protruding intestine which has been pulled down into the wound by a piece of tape tied loosely at the bend of the loop, and the operation is carried on as previously described.

A. W. Abbott has also recently suggested a modification which would appear to be well worth while. He regards the diameter of the ileum as entirely sufficient for the reconstruction of an artificial vagina. His technique follows that of Baldwin except that a single leg of ileum is used instead of a loop. Abbott regards this as advantageous inasmuch as it takes less bowel, requires closure of but one end of the isolated bowel instead of both limbs, and a second operation to divide the septum between the two legs of the loop is not necessary. The operation is, therefore, completed in one sitting.

Where the uterus is present it is, of course, possible to unite the upper end of this loop of resected ileum about the cervix. This has been done by Ward in the case of a thirteen-year-old girl with establishment of the menstrual function.

Extirpation of benign tumors of the vagina. Benign tumors of the vagina are as a rule limited to small myomata or cysts. The myomata are pedunculated or sessile, the cysts usually submucous and embedded.

In the operation for their removal the vaginal orifice is exposed by a weighted speculum if the tumor is in the anterior wall, or by lateral and posterior retractors if in the posterior wall. The mucous membrane over the tumor is seized and put on tension, and carefully incised until the cyst wall or myoma is exposed. The tumor is enucleated by blunt dissection and the excessive mucosa is trimmed. Oozing is stopped by one or two buried catgut ligatures. The wound edges are coapted with a continuous chromic catgut suture.

In large cysts there is a definite danger to the ureter and bladder, and injury to the rectum and bladder may be severe. Occasionally, therefore, it may be wiser to open the cyst and evacuate its contents, and after removing as much of the cyst wall as projects into the vagina to pack the cavity with gauze and permit healing by granulation.

In the case of a myoma the growth must be removed *in toto* after incising its capsule. If there is danger to the ureters, the bladder, or rectum in case deep sutures should be passed, the cavity may be lightly packed with gauze and allowed to fill in by granulation.

SECTION IV

OPERATIVE TREATMENT OF GENITAL FISTULÆ

BY

CHANNING W. BARRETT, M.D., F.A.C.S.

Professor of Gynæcology, University of Illinois College of Medicine;
Attending Gynæcologist, Cook County Hospital, Chicago
Policlinic and Hospital, Henrotin Memorial, and
West Side Hospitals.

CHAPTER I

OPERATIVE TREATMENT OF GENITAL FISTULÆ

WHILE the scope of this work precludes any extended consideration of the history of the subject, mention may be made of the pioneer workers in this field. As early as 1663 Roonhuysen suggested closure by suture of vesicovaginal fistulæ, and upon this suggestion Fatio first operated in 1675. Later, Marion Sims, by performing thirty-nine operations upon three slave women, surmounted one difficulty after another until at last he reached his brilliant success. In the surgical treatment of vaginal fistulæ he remained the master workman. Seldom, if ever, has any one else been able to apply his method to varying cases with the degree of success which he attained. Only recently in fact has the cure of even moderately simple fistulæ been removed from the class known as uncertain operations. While these cases now yield readily to operative treatment, fistulæ now and then occur which, because of inaccessibility or great destruction of tissue with extensive scar formation, tax the ingenuity of the most skilled surgeons.

Fistulæ which give trouble by reason of leakage of urine or fæces are vesicovaginal, vesicocervicovaginal, vesico-uterine, ureterovaginal, uretero-abdominal, urethrovaginal, urethrovesicovaginal, rectovaginal, rectoperineal, enterovaginal, and entero-uterine. Among those which may occur without causing loss of control of urine and fæces are fistulæ from Bartholin's gland into the vagina, and from pus tubes, ovarian cysts, abscess cavities, and tuberculous processes of the bony structures into the vagina, rectum, or bladder.

Vesicovaginal fistula. By far the most common and perhaps the most troublesome fistulæ are those from some part of the urinary tract into the vagina or cervix. Loss of urinary control follows, urinary changes take place because of infection and irritation, excoriations and incrustations are formed, infections of the bladder are the rule, and ascending infections of the ureter and kidney are not uncommon. In ureterovaginal fistulæ ascending infections are the almost universal rule. The odor of ammoniacal urine which accompanies these patients makes their presence disagreeable to their associates and a constant worry to themselves. The treatment must necessarily vary with the cause, location, extent, and consequent results of the fistulæ.

Formerly the most common causes of urinary fistulæ were trauma and necrosis caused by prolonged childbirth. Laceration of the bladder sometimes occurred, but not so frequently as necrosis of tissue due to pressure of the impacted child's head upon the vagina and bladder. Of recent years accidents of surgery have resulted in vesicovaginal, vesicocervical, and perhaps more frequently in ureterovaginal fistulæ. Foreign bodies, such as vaginal and uterine pessaries of different forms, spools, hairpins, and other instruments introduced into the vagina and bladder for purposes of masturbation or abortion have resulted in fistulæ. Wandering ligatures have also played a part. Ulcerations from carcinoma, tuberculosis, and syphilis are not uncommon causes. Suppurative processes occasionally play a part, especially in the formation of ureterovaginal fistulæ. Occasionally the ureter is allowed to open into the vagina from surgical election. Therapeutic vesicovaginal fistulæ are sometimes made for drainage and in cases of malignancy of the urethra.

The location and size of vesicovaginal fistulæ may vary greatly. There may also be great variation in the amount of scar tissue and contraction even in fistulæ of a similar size. A considerable share of the former difficulty in dealing with extensive fistulæ with marked contraction has been done away with by the recognition of the fact that the septum is made up of the walls of two distinct organs which may be repaired separately, rather than of a single septum whose edges must be approximated; and by a realization of the fact that both the bladder and the vagina can be mobilized when separated and that both are capable of considerable changes in size. The operator in trying to utilize these advantages may meet cases in which the great loss of tissue, the dense formation of scar, the involvement of urethra and ureters, the very limited size of the bladder and the friability of tissue offer difficulties well nigh insurmountable. If the fistula has resulted from carcinoma, syphilis, tuberculosis, or suppuration, plastic surgery is not to be thought of in their presence. Small fistulæ from recent penetrating bodies, wandering ligatures, etc., may be given a chance to heal spontaneously. Frank reports the spontaneous cure of larger fistulæ and recommends the use of the retention catheter for a time in nearly all cases of fistula in the hope of a spontaneous cure.

The greatest possible effort should be made to overcome the mental depression which accompanies this condition and to prepare the tissues locally. This may require a few days or a few weeks, but it is impossible to make a plastic repair of tissues covered with ulcerations and foul concretions. Urinary antiseptics and medications to render the urine acid should be employed, the parts should be shaved, a prolonged tub or sitz bath given daily, encrustations removed, ulcerated surfaces touched

with 5 or 10 per cent silver nitrate and vaseline applied. Gauze strips saturated with vaseline may be used to advantage. Frequent boric acid or lactic acid douches and bladder irrigations are to be recommended. By these methods the tissues gradually lose their induration, friability, and septic condition, and may be brought to a state suitable for operation.

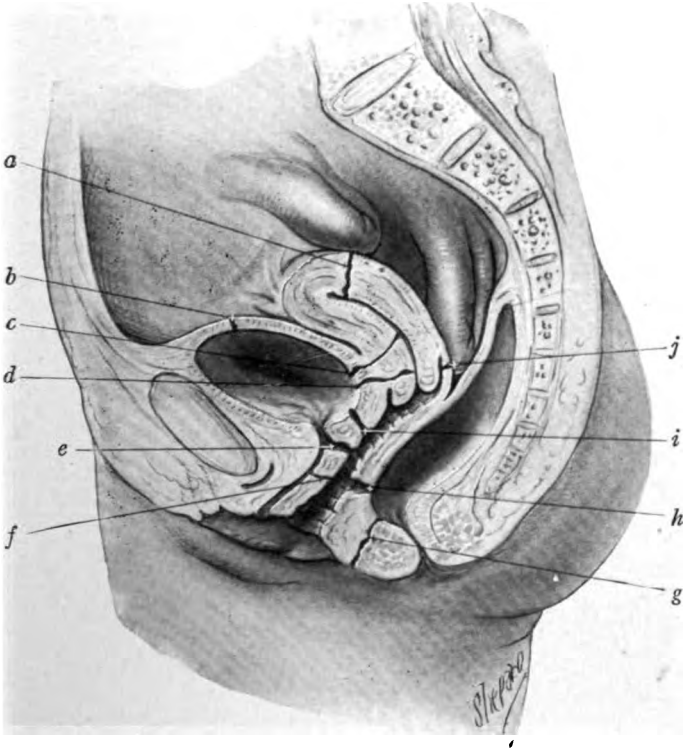

FIG. 24. DIAGRAMMATIC ILLUSTRATION OF DIFFERENT TYPES OF GENITAL FISTULÆ. *a*, Entero-uterine; *b*, enterovesical; *c*, vesico-uterine; *d*, vesicocervical; *e*, vesico-urethrovaginal; *f*, urethrovaginal; *g*, rectoperineal; *h*, rectovaginal; *i*, vesicovaginal; *j*, enterovaginal.

In difficult cases a general anæsthetic is to be preferred, for complete relaxation and the avoidance of the tissue infiltration of a local anæsthetic have some advantages. Spinal anæsthesia may be chosen in selected cases if ether inhalations are objectionable. An adjustable table is of great value in operating on vesicovaginal fistulæ as the marked upward tilt of the buttocks and lowering of the head greatly facilitates the work

Usually the vaginal route is to be chosen. Occasionally a high fistula is seen in which the abdominal route with the Trendelenburg position is plainly the route of choice. Trendelenburg himself first recommended suprapubic extraperitoneal opening of the bladder with in-

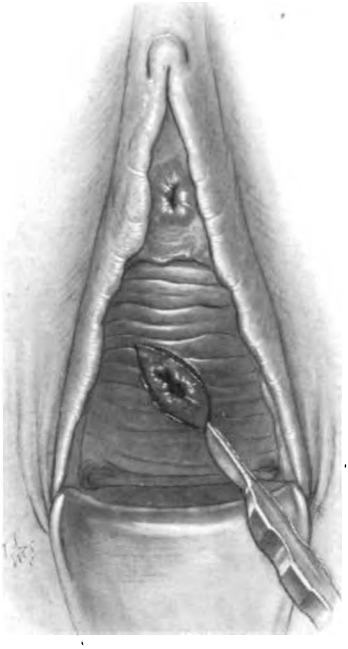

FIG. 25. SMALL, EASILY ACCESSIBLE VESICOVAGINAL FISTULA.

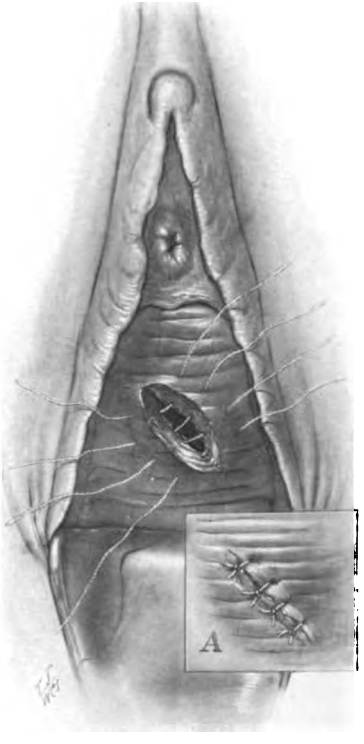

FIG. 26. REPAIR OF VESICOVAGINAL FISTULA BY SIMS' METHOD.

travesical suturing. The transperitoneal route is preferred by some. especially for fistulæ resulting from accidents of operation. Successful closure is of such importance and accessibility so necessary that the lateral vaginal incisions of Schuckhardt are warranted in some cases with narrow, undilatable outlets.

A very small and easily accessible fistula may be dealt with according

to the method of Marion Sims, by freshening and beveling the edges of the fistula from the vagina to the bladder, and placing, one-fourth inch from the vaginal edge, interrupted sutures which just fail to reach the mucous membrane of the bladder. In cases with loss of tissue it has

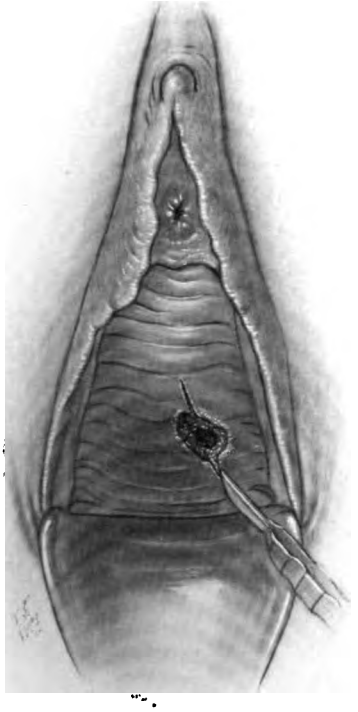

FIG. 27. VESICOVAGINAL FISTULA. Incision preliminary to separating vaginal flap.

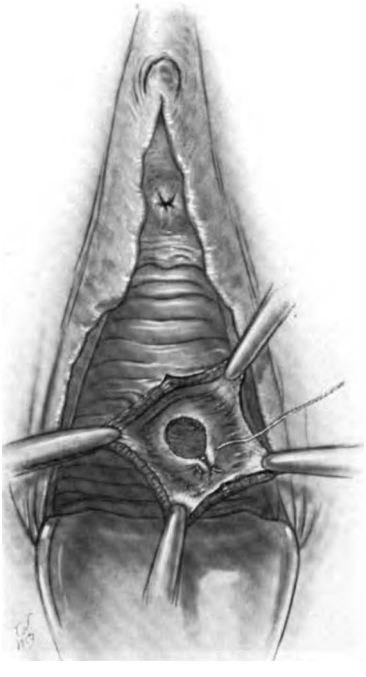

FIG. 28. VESICOVAGINAL FISTULA. Closure of the bladder.

been said that the oval denudation should be made in a direction to allow the best approximation of the edges with the least tension, but in cases in which this is of great importance, that is, with fistulæ of any size and with fixation of the tissues, it is far better to split the septum to such an extent as will allow closure of the bladder opening without tension, according to the method devised by Mackenrodt (Fig. 27). This

closure should be made with a Lembert suture which slightly turns in the edges of the bladder (Fig. 28). Some recommend silk, but since there is some risk of its being projected into the bladder and serving as a center for a vesical calculus, chromic catgut is to be preferred. The

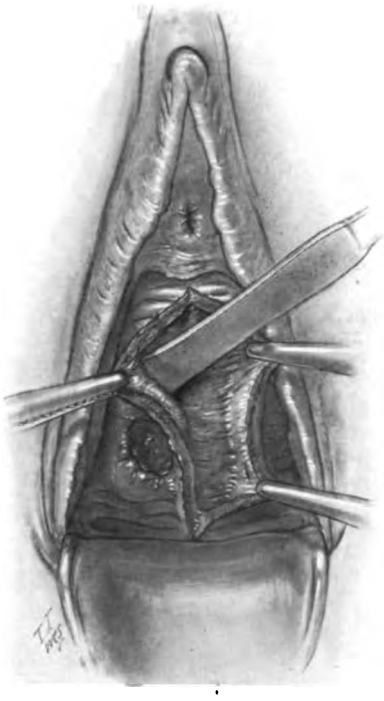

FIG. 29. VESICOVAGINAL FISTULA. Midline incision in case of more extensive fistula.

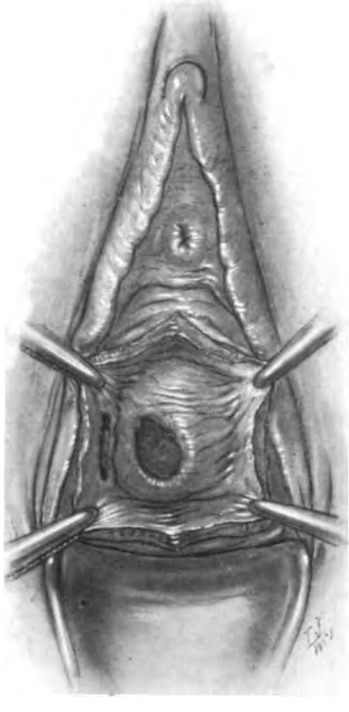

FIG. 30. VESICOVAGINAL FISTULA. Separation of the vagina and bladder completed.

bladder closure should be reinforced by another layer of Lembert sutures so as to make it secure. The sutured vaginal wall gives strength but does not prevent leakage from the bladder. If such leakage occurs it will cause less damage if it takes place into the vagina than into the vesicovaginal interspace. Such leakage must not be taken as evidence of failure. If the bladder is kept empty by the use of a retention catheter,

and provision made for urine to escape from the interspace, healing may yet take place. This method of reaching and closing the bladder opening makes a firm wall-to-wall closure even for large openings. If the bladder is mobilized there is no tension; and though its size may be diminished

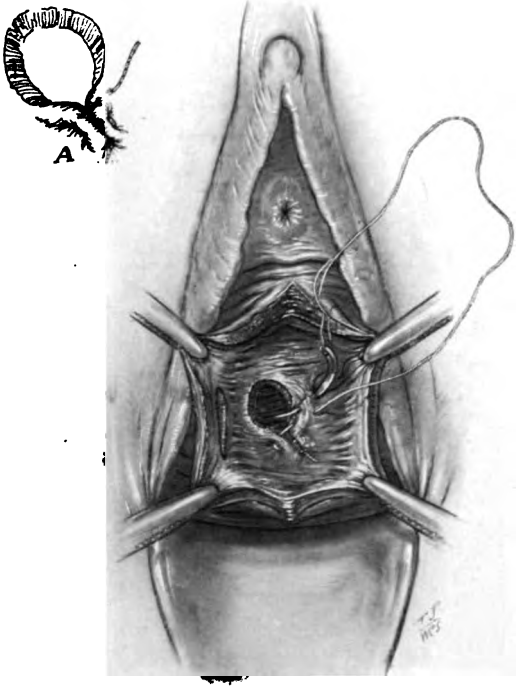

FIG. 31. VESICOVAGINAL FISTULA. Closure of the bladder.

temporarily it will develop a larger capacity in time and functionate in an entirely normal way.

After the bladder is closed the vaginal opening may be sutured longitudinally, obliquely, or transversely as seems most suitable. If there is a loss of vaginal tissue that threatens stricture or shortening of the vagina, a plastic operation may be done by sliding a flap from a healthier portion of the vagina, or, in rare cases, from the vulva. These methods, however, are seldom necessary.

Ward, Frank, and others recommend a median longitudinal or

transverse incision in the healthy vaginal wall so as to separate the bladder from the vagina in a normal area, as in an extensive cystocele or interposition operation. One must use caution as the fistula is approached to preserve the bladder wall and not enlarge the fistula (Fig. 29). Frank lays stress upon the separation of the adherent bladder from the pelvic bones and upon carrying the separation of the bladder to the point

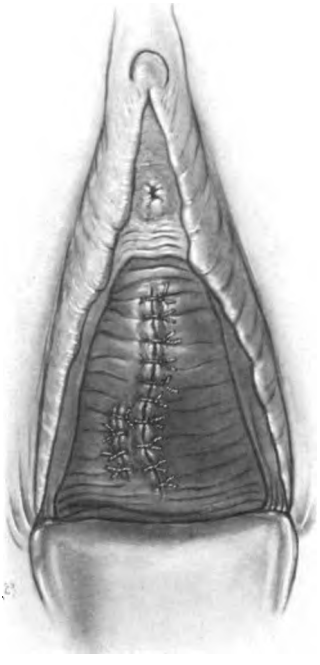

FIG. 32. VESICOVAGINAL FISTULA. Closure of the vaginal mucous membrane.

of complete mobilization. It has been recommended that the vaginal flap be taken from a sufficient distance to allow the edge of the flap to be turned in so as to cover the opening, and thus cause the vaginal wall to become the bladder wall and the vaginal mucous membrane to become bladder mucous membrane. This would, of necessity, cause the scar edge to be turned into the bladder, and seems to the writer to have, in most cases, great drawbacks over the former methods, particularly in view of the usual capacity of the bladder for mobilization. Such a

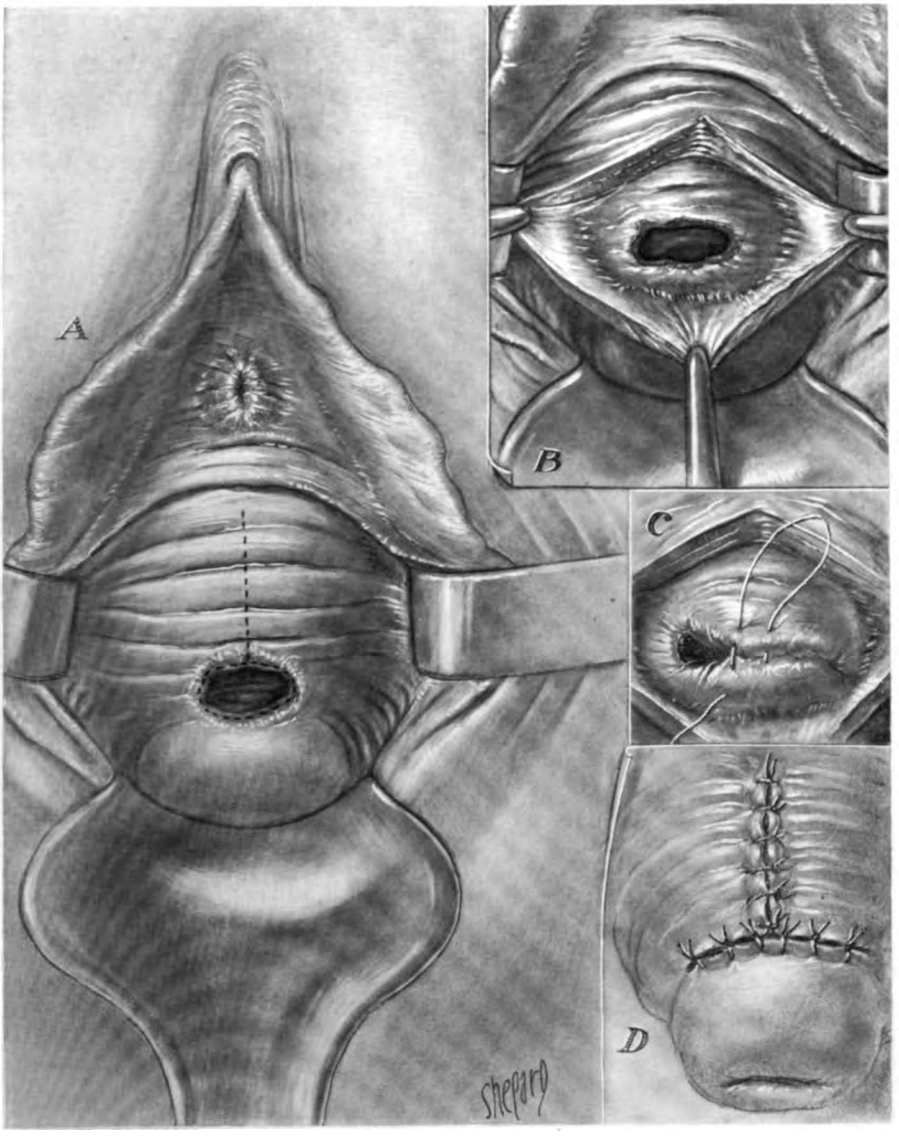

FIG. 33. VESICOVAGINAL FISTULA CLOSE TO THE CERVIX. *a*, Line of incision; *b*, separation of the vagina and cervix from the bladder; *c*, closure of the bladder; *d*, closure of the vaginal mucous membrane.

procedure would also require a larger amount of normal vaginal tissue, a consideration of importance with fistulæ of considerable size.

In cases with a small fistulous tract the connective tissue about it may be preserved by dissecting the vagina around it and turning this tube of connective tissue into the bladder, after the manner of an appendix stump. This, perhaps, is harmless in most cases, but with small fistulæ it is quite unnecessary for successful closure.

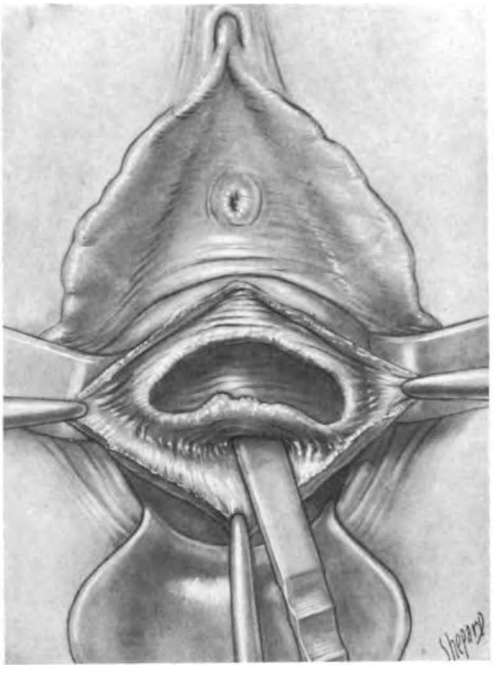

FIG. 34. VESICOVAGINAL FISTULA CLOSE TO THE CERVIX. Separation of the bladder from the cervix.

In cases with extensive loss of tissue, bladder tissue may be procured for closure by separating the bladder from the uterus, so that it may be brought down as far as desired. When once the bladder wall is complete, a vaginal covering can usually be secured without great difficulty. It has been recommended that the whole uterus be drawn down, but this does not seem to offer sufficient advantages over separating the bladder from the uterus. Frank recommends the interposition operation in cases of sphincter loss, that the fundus may act as a ball to close the opening. He recognizes, however, the uncertainty of such action, particu-

larly in cases of long standing, or in certain cases with wide involvement.

In some very extensive cases when no plastic operation will successfully close the opening between the bladder and vagina, one may resort to a closure of the vagina below the opening. Unfortunately, these are apt to be cases with loss of the sphincter vesicæ. Maisonneuve has recommended the substitution of the sphincter ani in cases of loss of the sphincter vesicæ by completely closing the vulva and diverting the urine

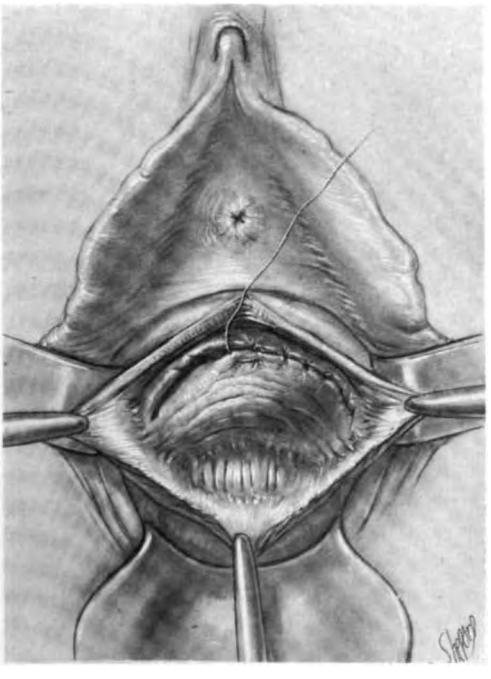

FIG. 35. VESICOVAGINAL FISTULA CLOSE TO THE CERVIX. Closure of the bladder.

into the rectum. Peterson has collected experimental and clinical results which are fairly satisfactory as to freedom from rectal irritation, sphincter control, time of retention, absence of colon bacillus infection of the uterus, bladder, and kidneys, and lack of bowel disturbance. In complete loss of the sphincter vesicæ this method promises the best results. Efforts have been made to form a new urethra and obtain retention by artificial pressure, but these have proven failures.

If the uterus is at all pathologic it would seem more ideal to do a preliminary hysterectomy, though in some cases this would not be justified.

Cervicovaginal fistula. With fistulæ opening into the cervix a transverse incision should be made at the junction of the vagina and the cervix, and the cervix and bladder separated up to and beyond the fistula so as to make a good exposure for bladder repair. A longitudinal vaginal incision is desirable. After the bladder closure the cervical fistula may be freshened and closed or, in some cases, packed. If the

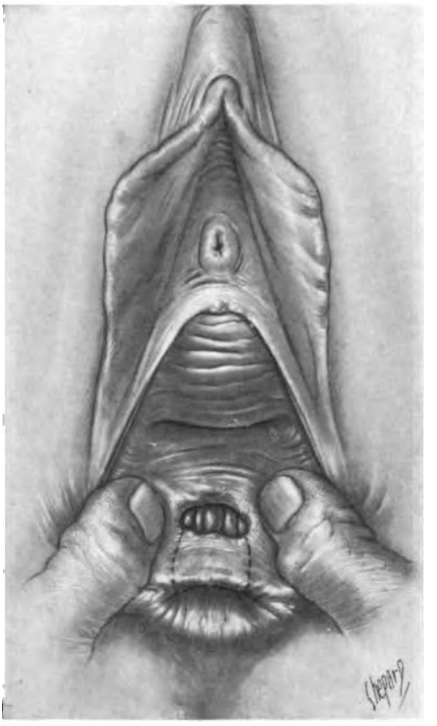

FIG. 36. COMMON TYPE OF RECTOVAGINAL FISTULA. The dotted lines indicate the line of excision of the septum between the rectum and vagina.

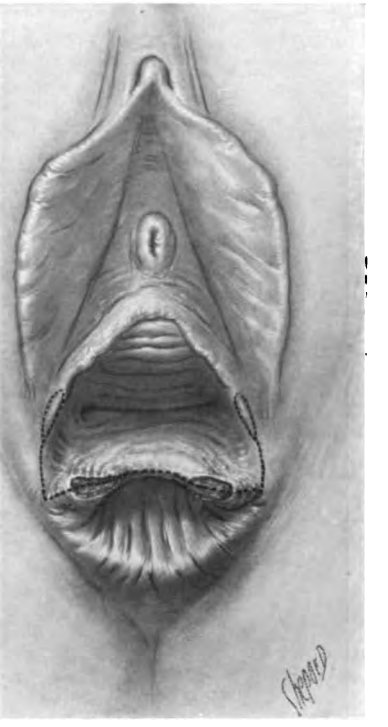

FIG. 37. RECTOVAGINAL FISTULA. Line of incision for raising the vaginal flaps. The rectovaginal septum below the fistula has been excised.

uterus comes down with difficulty, an abdominal operation may be preferable.

Ureterovaginal fistula. This type of fistula should be dealt with by abdominal or possibly, in some cases, vaginal implantation of the ureter into the bladder, providing the kidney and ureter remain healthy. If ascending infection has occurred no implantation should be thought

of during the active stage, and a nephrectomy will probably become necessary. A ureterovaginal fistula, the result of a pelvic abscess, may be cured spontaneously even after some ascending infection has occurred. Should it persist, transplantation of the ureter may be possible when the infection has disappeared. The more common result, however, is the formation of a stricture, due to the contraction of inflammatory adhesions and the gradual development of an infected hydronephrosis.

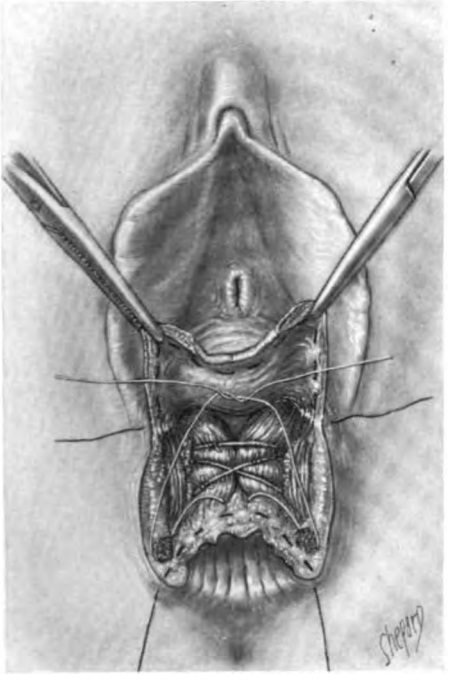

FIG. 38. RECTOVAGINAL FISTULA. Suture of the levator ani underneath the vaginal flaps by interrupted catgut sutures.

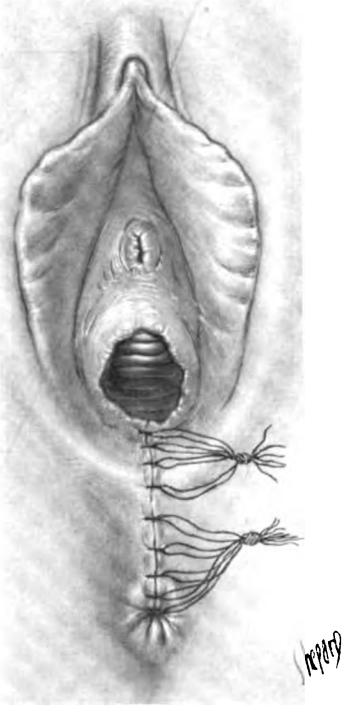

FIG. 39. RECTOVAGINAL FISTULA. Operation completed; closure of the skin with interrupted silkworm sutures.

After operating upon cases of urinary fistulæ care should be exercised to keep the bladder empty with a retention catheter or by frequent and careful catheterization. I much prefer the former. Close observation should be made to make sure that the catheter is not obstructed. The bladder should be washed out once or twice a day with boric solution. Abundance of water should be taken and a urinary antiseptic adminis-

tered. The treatment of urinary fistulæ is the most exacting work that the pelvic surgeon has to do, but carefulness as to the details of operation and thorough use of the principle of mobilization of the bladder will cure most cases.

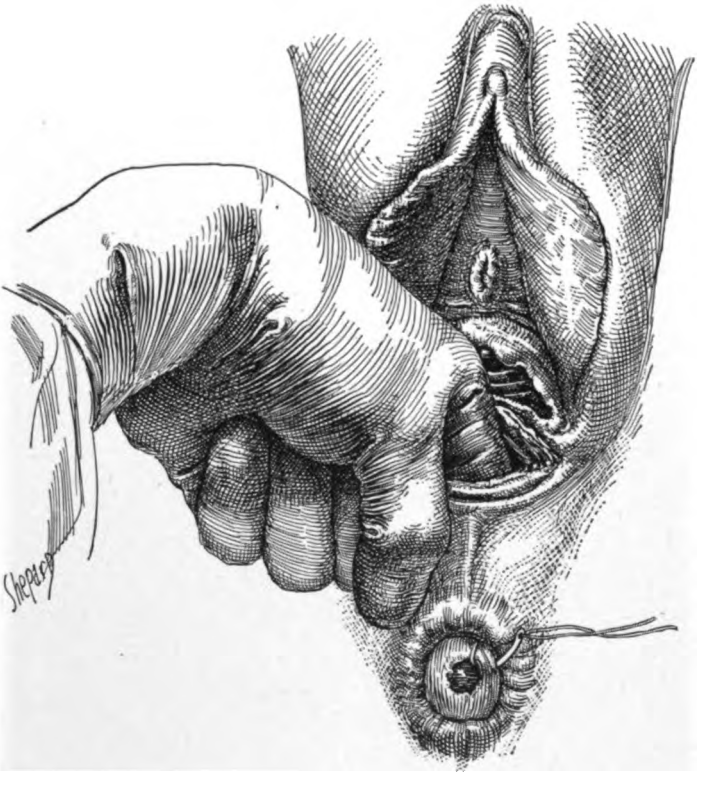

FIG. 40. RECTOVAGINAL FISTULA. Suture of the rectal wall brought down from above to the anal opening.

Rectovaginal fistula. Rectovaginal fistulæ result largely from injuries at childbirth, operative injuries, pathologic destruction of tissue, foreign bodies, such as pessaries, and congenital malformation. They result in more or less fæcal soiling, lack of control of bowel gases, sexual disgust on the part of the husband, and colon bacillus infection of the genital and possibly the urinary tracts. Rectovaginal fistulæ due to suppuration, carcinoma, syphilis, and tuberculosis are not amenable to surgical treatment except as it aims to remove the cause. If these con-

ditions have become extensive little can be accomplished surgically, and attention must be directed toward alleviating the symptoms and keeping the patient as comfortable as possible.

Rectovaginal fistulæ, the result of childbirth, are usually low down

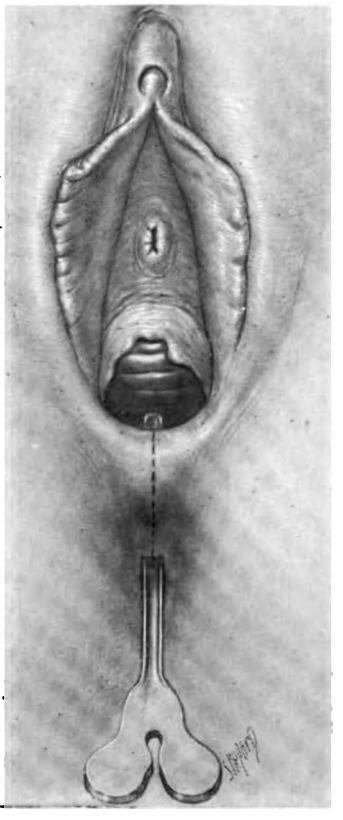

FIG. 41. RECTOVAGINAL FISTULA OF CONGENITAL ORIGIN. Illustration of a case which had been operated upon unsuccessfully twelve times.

and combined with complete laceration of the perineum. They not infrequently follow some effort at repair. Often the patient states that she has had a repair but that the stitches did not hold. More often than otherwise this is a result of inadequate efforts at repair. Seldom do the stitches fail to hold when the proper tissues are brought together in an adequate way. These cases usually present a complete tear of the sphincter with a little bridge of tissue between the vagina and the rectum, and

above this a fistula from one-eighth to three-fourths of an inch in diameter. Lying between the fistula and the anal outlet may be one-half or one inch of the rectovaginal septum. It is necessary to obliterate the fistula, restore the sphincter control of the rectum, and repair the pelvic floor.

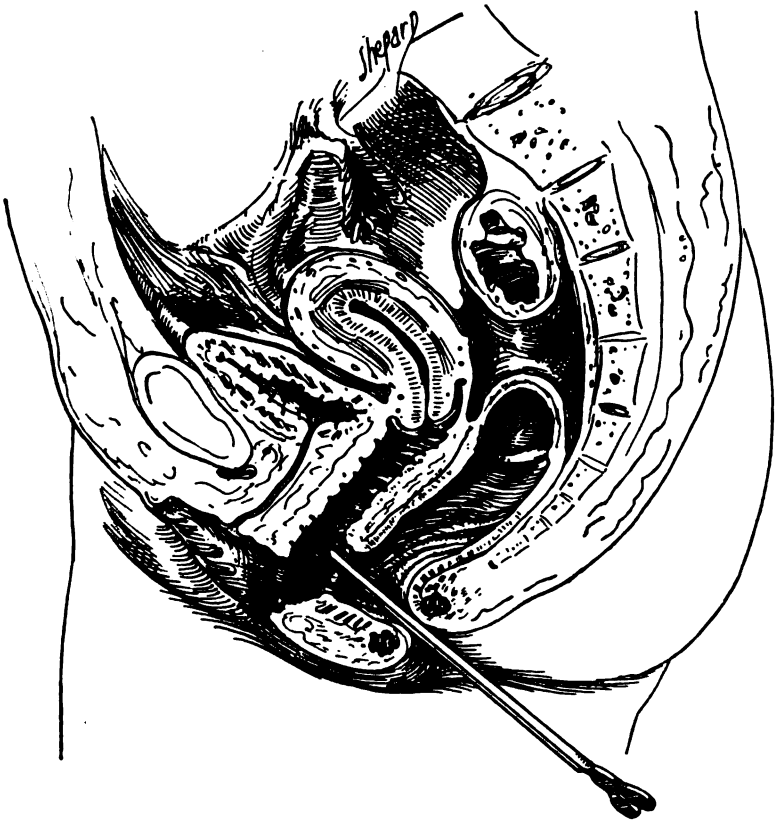

FIG. 42. LATERAL VIEW OF THE SAME CASE.

Repair of such a fistula according to Tait's method would restore the sphincter ani, but it would not bring together the separated fibers of the levator ani nor extend to the fistula itself. It is the repair of the deep muscular diaphragm formed by the levator ani muscle which is the essential factor for success.

The customary method of treatment has been to split the rectovaginal septum and close the opening in the anterior rectal wall. This step has

been the weak point of the operation, and not infrequently has resulted in a fistulous opening from the rectum to the perineum through the wound of operation. I wish here to emphasize the value of a method which obviates this difficulty. The bridge of tissue between the anal outlet and the fistula is cut away so as to leave the tissue at the upper circumference of the fistula as the lower edge of the rectovaginal septum. This

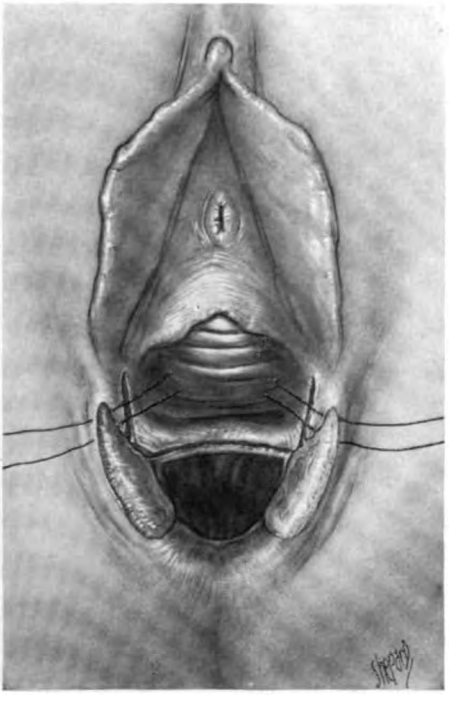

FIG. 43. RECTOVAGINAL FISTULA DUE TO IMPERFECT PERINEUM.

is split to such a depth as to reach the levator ani muscles and mobilize the rectum. The levators are then brought together as in an incomplete tear. The incomplete anterior rectal wall is drawn down to the outlet, the ends of the sphincter ani brought together in front of it, and fastened to the rectal wall high enough to hold it down. The superficial structures are brought together with interrupted sutures, and the vaginal flap with a purse-string suture. This repair gives no opportunity for leakage from the bowel into the wound, as the anterior wall is complete. Such is not the case if a fistula is closed or if an incomplete wall is formed with sutures.

If the rectovaginal fistula lies high in the pelvic floor and the floor is intact, an opening is made in the vaginal wall, the rectal opening is closed with a Lembert or purse-string suture, and reinforced by other sutures. The vaginal opening is closed last. After either closure a small tube is placed in the vagina to prevent gas collecting under pressure and breaking open the line of suture.

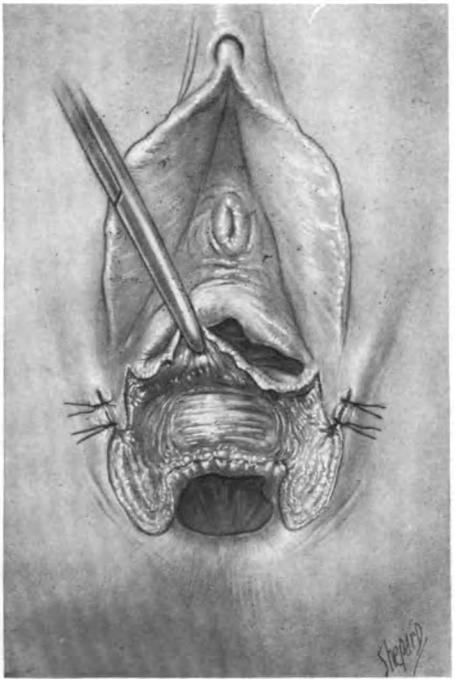

FIG. 44. RECTOVAGINAL FISTULA DUE TO IMPERFECT PERINEUM. The raw perineal surfaces on either side anterior to the septum have been closed. A vaginal flap is being raised to mobilize the rectum and expose the levator ani muscle.

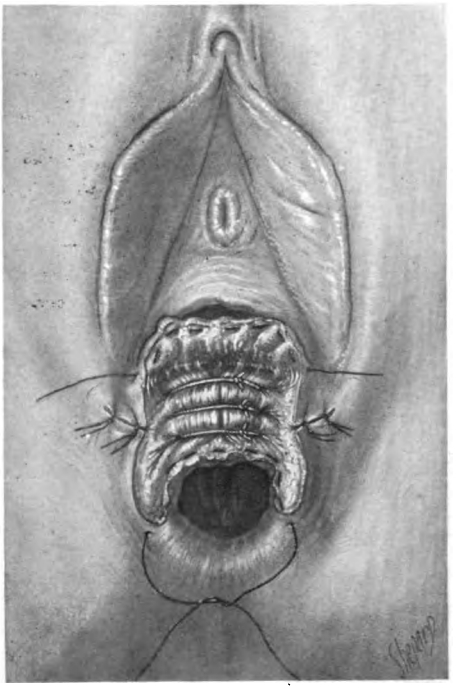

FIG. 45. RECTOVAGINAL FISTULA DUE TO IMPERFECT PERINEUM. Approximation of the levator ani muscles as a substitute for the sphincter ani; anterior and posterior purse-string sutures in place.

In cases of congenital rectovaginal fistulæ, the imperfect gut opens into the vagina posteriorly and the anal opening does not exist. Frequently the anal fossa is well marked and a rudimentary muscle is evidenced. A tunnel opening should be made at this point, and the rectum brought down to the skin margin through the anal fossa. The small opening into the vagina may be closed at the same time or at a

subsequent operation. As a rule, the opening will be somewhat smaller at a later time.

Congenital rectovesical fistulæ occur in the same way in male children. An anal opening should be made and a closure of the fistula undertaken later if it does not close spontaneously. This usually must be undertaken abdominally.

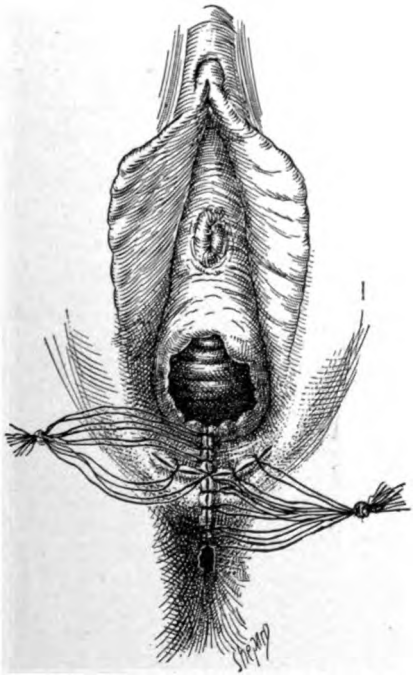

FIG. 46. RECTOVAGINAL FISTULA DUE TO IMPERFECT PERINEUM. Closure completed.

Enterovaginal and enterovesical fistula. Enterovaginal fistulæ result from pelvic abscesses involving the bowels. Enterovesical fistulæ result from spontaneous rupture of an appendiceal or other abscess into the bladder. Chronic ulcerative processes, such as tuberculosis, syphilis, or carcinoma, may bring about a like result.

In cases of enterovaginal fistulæ the abdomen is opened after the inflammatory process has subsided, and the bowel separated from the vagina. The opening in the bowel is closed and the opening in the vagina allowed to heal spontaneously. Such cases frequently offer serious difficulties for the surgeon because of the inaccessibility of the pathological

process, because of the extensive adhesions and fibrous tissue formation involving the surrounding area, and because of the lowered vitality of the tissues not uncommonly present. The presence of a low-grade infection over a considerable period of time is an important factor in retarding recovery.

Cases of enterovesical fistula are even more difficult of cure because of the intense cystitis invariably present in addition to the conditions mentioned above. In such cases it is necessary to place a retention catheter in the bladder to prevent distention, and to combat in every way possible the infection of the urinary tract.

SECTION V

OPERATIONS FOR NON-MALIGNANT AFFECTIONS OF THE UTERUS

BY

SIR JOHN BLAND-SUTTON, F.R.C.S. (Eng.), Lieutenant-Colonel R.A.M.C.(T.)

Surgeon to the Middlesex Hospital

CHAPTER I

HYSTERECTOMY

Indications. Hysterectomy is most frequently indicated in the radical treatment of fibroids and malignant disease, such as carcinoma, sarcoma, and chorio-epithelioma. It is occasionally required for injury, and certain morbid states due to acute and chronic sepsis; and for a condition but little understood, termed fibrosis. Hysterectomy is also carried out for such conditions as adenomyoma of the uterus, hæmatometra, tuberculous endometritis, and on rare occasions for chronic inversion of the uterus and inveterate dysmenorrhœa.

Fibroids present the most frequent indication for hysterectomy, and in these cases the abdominal route is to be preferred. The position of the fibroid with reference to the cavity of the uterus, whether submucous, intramural, or subserous; its location with reference to the cervix and body of the uterus; and particularly its position with reference to the peritoneum and the sigmoid flexure are all factors of importance in determining the best method of treatment. In former years smaller fibroids, especially those occurring in cases in which there was some contra-indication to abdominal incision were removed by the vaginal route, but the introduction of radium has largely removed this indication. Small fibroid tumours respond well to the application of radium, and in the presence of complications contra-indicating abdominal section one may use radium in the treatment of larger tumours, even though complete disappearance of the tumour cannot be expected. For a more extended discussion of the subject the reader is referred to the section on radium treatment.

The uterus may be removed by two methods. In one, the uterus is extirpated through the vagina, and on this account the operation is termed vaginal hysterectomy or colpohysterectomy. In the other, access is obtained to the uterus through an incision in the belly-wall; this operation is termed abdominal hysterectomy.

The abdominal method of removing the uterus may be performed in two ways. In one, the body of the uterus and a portion of its neck is removed; this is called subtotal hysterectomy. In the other, the body of the uterus and the whole of its neck are excised; this is total hysterectomy, or panhysterectomy. The ovaries and uterine tubes may, or may not, be removed, according to the disease for which the operation is undertaken.

VAGINAL HYSTERECTOMY

The operation of vaginal hysterectomy should be restricted to cases in which there is an absence of extensive pelvic adhesions or disease of the adnexa, and in which the fundus is not so large as to interfere with delivery through the vagina. It has the advantage of a limited interference with the intestines, and the absence of an abdominal incision with its consequent scar and possibility of hernia. The disadvantages of the limited field for operative examination and work are evident. The technique in carcinoma of the uterus is discussed under another section.

The vagina should be thoroughly cleansed and held open by retractors. The cervix is grasped by a volsellum and drawn downward, a sound placed in the bladder to indicate the position of the bladder, and a transverse or T-shaped incision made at the cervico-vaginal junction. With the index finger covered with gauze the bladder is separated from the anterior surface of the uterus upward to the line of peritoneal reflection and laterally to the broad ligament. The peritoneum is recognized by its glistening white appearance, and by the ease with which the finger glides over the peritoneum covering the fundus of the uterus as soon as the bladder is freed from the fundus. Care should be taken to carry the line of separation close to the uterus so as not to injure the bladder. In case of doubt the sound in the bladder will help to guide the operator. All actively bleeding vessels should be ligated.

The peritoneum is opened with the finger or the scissors close to the uterus, and the opening widened sufficiently to pack the intestines away from the field of operation with a laparotomy pad.

The cervix is drawn downward and forward so as to expose the posterior surface. A transverse incision is made through the vaginal wall at the posterior vagino-cervical junction and carried laterally to meet the anterior incision, so that the entire vaginal wall is separated from the cervix with the lower border of the broad ligaments. After the bleeding points are ligated the connective tissue and peritoneum close to the posterior surface of the uterus are punctured with the finger or scissors so as to open the cul-de-sac of Douglas. This opening is widened on either side until the uterus is held in position only by the broad ligaments. A laparotomy pad is placed in the cul-de-sac to hold the intestines away from the field.

The surgeon is now ready to sever the broad ligaments. A broad retractor is inserted to hold the bladder up out of the field, and an assistant draws the cervix to the patient's right side while the surgeon grasps the lower part of the left broad ligament between his thumb and index finger, identifies the uterine artery by its pulsation, and with a

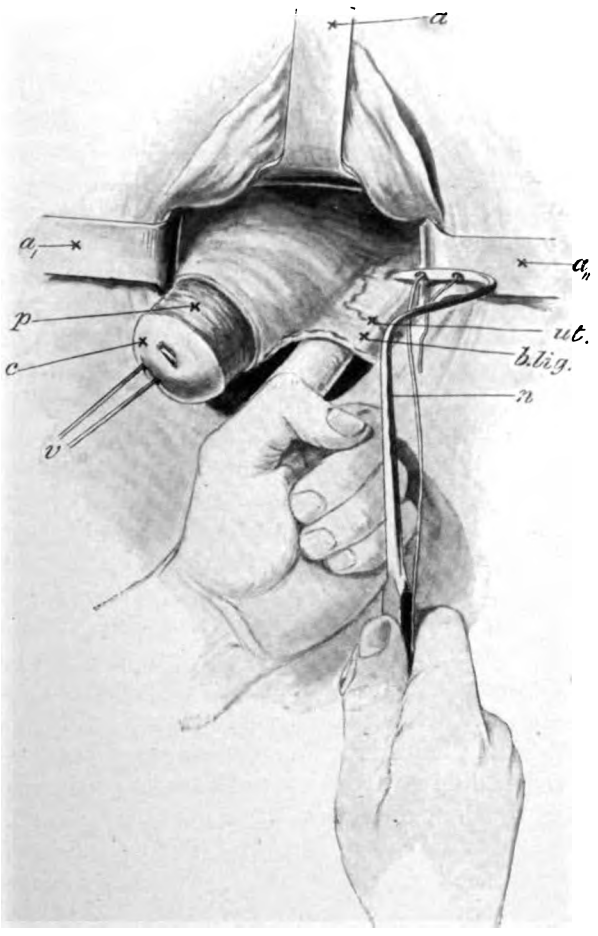

FIG. 47. VAGINAL HYSTERECTOMY. The vaginal incisions have been made, the bladder separated from the uterus, and the peritoneal cavity opened. *a, a,* Retractors; *b. lig.,* broad ligament; *c,* cervix; *n,* Galabin's needle; *p,* denuded cervix; *ut.,* uterine artery; *v,* volsella.

needle or ligature carrier passes a strong ligature around it and the exposed base of the broad ligament. A clamp is now placed on the uterine side and the tissue between the clamp and the ligature is cut. In order to avoid injuring the ureter, which passes approximately an inch outside the cervix, one should ligate as close to the cervix as conditions will permit. Succeeding sections of the broad ligament are now ligated in similar manner until the entire broad ligament is severed. The same steps may be repeated on the opposite side, but ordinarily the fundus of the uterus will now be drawn out into the vagina and the broad ligament ligated in sections from above downward, with the same precautions. The tubes and ovaries are examined, and removed, if necessary, by piercing the stump and ligating with a strong ligature.

All bleeding points are secured, the vaginal packs removed, and the peritoneum closed carefully so as to prevent bleeding into the abdomen and the development of postoperative adhesions. As much as possible of the stumps of the broad ligaments are sutured, together with the round ligaments, in the middle line, so as to support the bladder and prevent a subsequent cystocele. A small drain is inserted for twelve or twenty-four hours to prevent the accumulation of blood, and the vaginal mucous membrane is closed, except at the site of the drain, by interrupted sutures.

If oozing of blood cannot be stopped by ligatures, a pack of adrenalin gauze may be inserted for twenty-four hours and then cautiously removed.

In C. H. Mayo's method (Figs. 129–132; pp. 288–291) the cervix is pulled down strongly and a pear-shaped incision is made with its apex one and one-half inches below the external urinary meatus. The vaginal wall is separated from the bladder by blunt, gauze dissection, the apex of the vaginal flap turned down from the anterior lip of the cervix, and the bladder separated by blunt dissection from the front of the uterus. The peritoneum is incised and divided laterally. The posterior vaginal wall is then separated from the uterus, the fundus drawn down into the field of operation and the cervix replaced within the vagina. The broad ligaments are clamped on either side and the uterus excised by incising the ligaments between clamps. The clamps remaining on the broad ligaments are approximated, and the broad ligaments united by a mattress suture in such a way that their surfaces are approximated for a distance of one or one and one-half inches (Fig. 131). The same suture serves to ligate the blood vessels and prevent their retraction lateralward.

Occasionally it may be advisable to place clamps instead of ligatures on the broad ligament. This permits more rapid operation, but gives a less satisfactory result. In this case the peritoneal roof is closed as well as possible. The vaginal walls are brought together with one or two sutures in the median line and a fair-sized pack is placed in the cavity

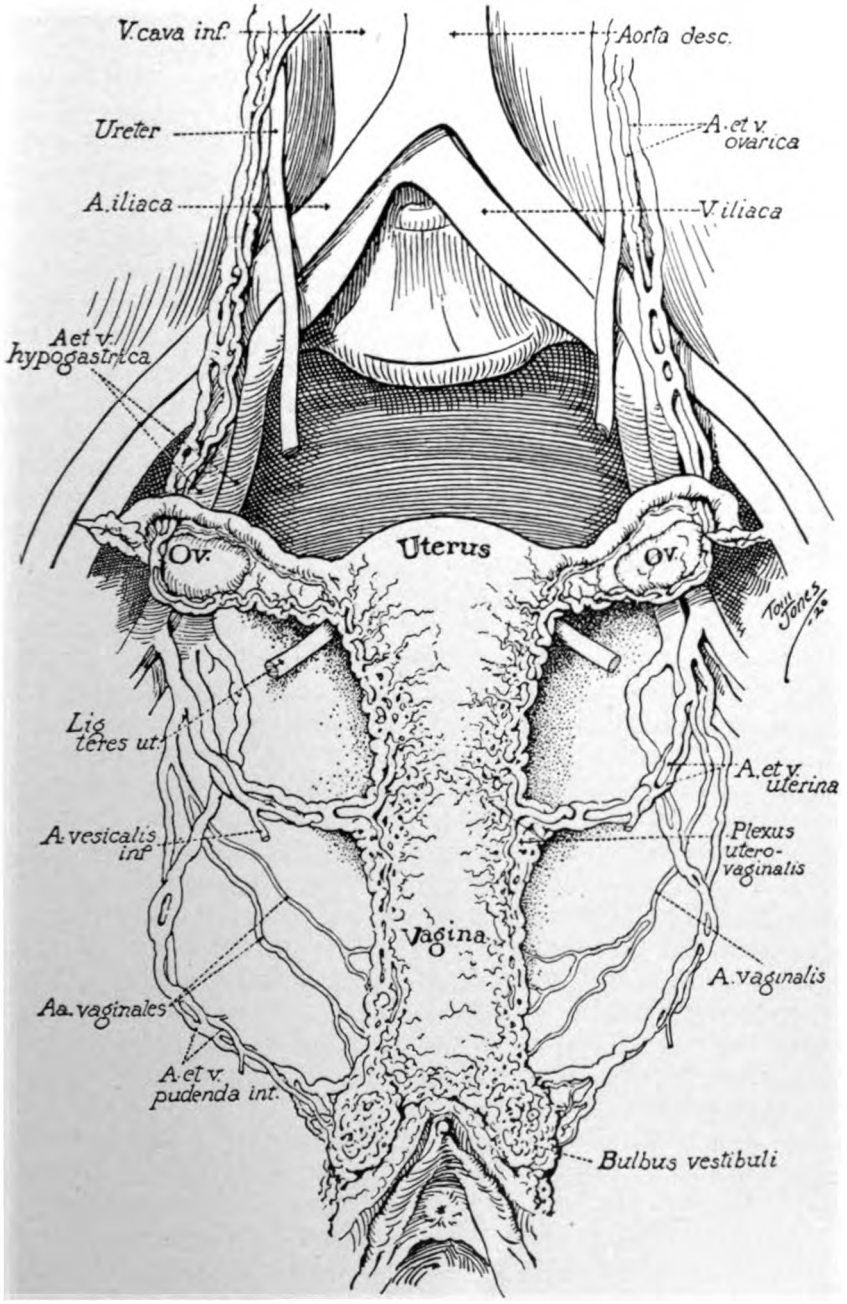

FIG. 48. BLOOD SUPPLY OF THE UTERUS AND VAGINA.

from which the uterus has been removed. The forceps are loosened at the end of twenty-four hours and removed two hours later.

If the patient does not urinate she may be catheterized under aseptic precautions. After three days vaginal douches may be given if necessary.

SUBTOTAL HYSTERECTOMY

The abdomen is opened by the median subumbilical incision; but when the operation is performed for the removal of large tumours the incision will frequently require extension above the umbilicus. The operator should never allow himself to be embarrassed by a small abdominal opening. As soon as the peritoneal cavity is reached, the surgeon introduces his hand into the abdomen and carefully determines the nature of the case, the presence of adhesions or of other tumours, the relation of the fibroid to the uterus, and whether it is impacted in the pelvis. The uterus is carefully lifted out through the incision, or drawn out with the assistance of a volsellum forceps; the intestines and omentum are isolated from the pelvis with warm, moist gauze.

In a simple case the broad ligaments are seized with hæmostatic forceps; if the ovaries and tubes are healthy and the surgeon wishes to preserve them, the forceps are applied between the ovary and the uterus; but if they are obviously diseased and must be sacrificed, the forceps are applied to the broad ligaments near the brim of the pelvis beyond the outer pole of the ovary. It is an advantage at this stage to secure the round ligament with forceps, in order to control bleeding from its artery and to prevent the stump of the ligament from retracting the peritoneum. As the broad ligament on each side is divided, each uterine artery is exposed at the side of the uterus near the cervix and caught with forceps; a peritoneal flap is fashioned on the anterior wall of the uterus at its junction with the neck, care being taken not to injure the bladder. A similar flap is cut on the posterior wall, and the uterus is then detached at a point well below the junction of the cervix with the body. If the forceps are correctly applied to the vessels the detachment of the uterus is an almost bloodless proceeding; a small vessel here and there will perhaps require the application of a pair of forceps.

The principle involved in this part of the operation may be explained by reference to the diagram (Fig. 48). The blood-supply of the uterus is carried by the ovarian and uterine arteries. The former traverse the broad ligaments to reach the cornua of the uterus, where they anastomose with the terminations of the uterine arteries; the latter come into relation with the uterus near the junction of the body and cervix, and ascend in a somewhat tortuous manner to the uterine cornua. No large vessels are

found on the anterior or posterior surface of the uterus. An arterial twig runs along the round ligament, bringing the ovarian artery into relation with the inferior epigastric artery. If the surgeon thoroughly appreciates the distribution of the ovarian and uterine vessels he will at once perceive that if the four forceps are properly applied to the vessels the blood-supply is under absolute control; indeed, in many cases a subtotal hysterectomy can be performed without the loss of more than an ounce of blood. When the broad ligament is clamped and detached there is a spurt of blood from the uterine cornu which lasts until the corresponding uterine artery is caught with the forceps, and the cessation of the bleeding at the uterine cornu is a sign that the artery is securely clipped. It must be remembered that with a small tumour in the uterus the vessels follow their normal courses and can be easily found, but when the uterus is deformed by huge tumours, the vessels are not so easily seen, and they are of large size and give rise to furious bleeding when divided. In dealing with large and vascular uterine fibroids another factor has to be reckoned with, namely, the enormous veins in the pampiniform plexus, interspersed with lymph-vessels which in some cases are as thick as the index finger; it is not an uncommon thing to meet with lymph-vessels in this situation a centimetre in diameter and filled with straw-coloured lymph.

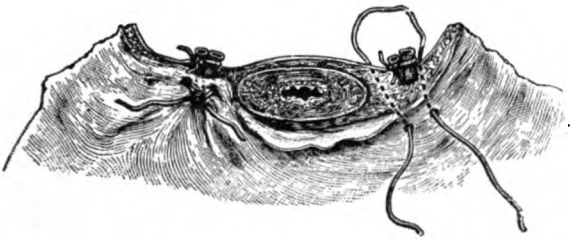

FIG. 49. THE MATTRESS SUTURE. A diagram to show the method of applying it.

The surgeon now secures the vessels. The ovarian pedicles are transfixed and ligatured with silk as in ovariotomy; the round ligament is usually included in the ovarian pedicle. It occasionally happens that a fibroid situated near the uterine cornu will grow in such a manner that it widely separates the ovarian ligament, the uterine tube, and the round ligament from each other. In such a condition it is impossible to save the ovary without risk, and also inadvisable to attempt the inclusion of the round ligament in the pedicle containing the ovarian vessels. In these circumstances the round ligament is easily secured by a mattress suture, which should include both layers of the corresponding broad ligament.

When the surgeon decides to leave an ovary and the corresponding uterine tube, these structures are carefully examined to determine if they are healthy and free from any suspicious fluid. *When the endometrium is septic or cancerous both ovaries and tubes should be removed.* When the surgeon decides to leave an ovary and its corresponding uterine tube,

he should take care in securing the ligatures to include the ligament of the ovary: it is very liable to slip out of the encircling loop of silk. It is often convenient to include the round ligament of the uterus in the pedicle, but it is not a disadvantage when it is tied separately. As a rule, the cervical canal is free from micro-organisms, especially in spinsters, but they are present with sufficient frequency to make an application of tincture of iodine to the cervical endometrium and the cut surface of the stump a judicious act before applying the ligatures. It is important also to wash the gloved hands in a solution of perchloride of mercury (1 in 5,000) before applying the sutures.

The uterine arteries are ligatured with thin silk; these vessels as they run up the sides of the uterus are accompanied by veins, so that there is a vascular tract at the point where the cervix is divided. If after the uterine vessels are secured there is oozing from these veins, it is easily controlled by a mattress suture. This kind of suture is so useful that the mode of inserting it may be given in more detail. In the diagram (Fig. 49) the silk is represented in position before it is tied, and in that particular instance it is represented as being passed through the peritoneal flaps from before backwards, and this is usually the most convenient route; occasionally the reverse direction is easier. It will be noticed in the diagram that this suture not only controls oozing from the tissue in the immediate neighbourhood of the uterine vessels, but it also embraces the main vessels, and thus serves as an additional security against hæmorrhage; it also brings the peritoneal flaps into apposition.

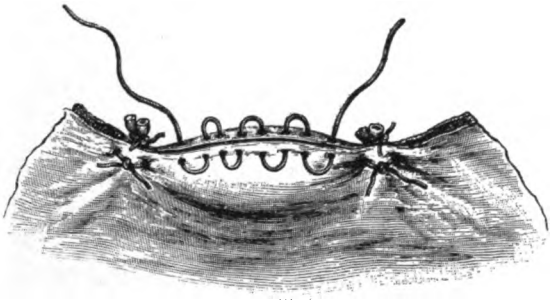

FIG. 50. THE STUMP AFTER SUBTOTAL HYSTERECTOMY. To show the method of applying the continuous suture.

As soon as the oozing of blood has been controlled, the cervical canal is examined to ascertain if it be free from polypi or cancer. Should the condition of the cervix be in the least degree suspicious of cancer it must be extirpated. When it is healthy, then the flaps are brought together by one or two interrupted sutures, and the edges more carefully approximated by a continuous suture of thin silk. In suturing the flaps it is necessary to avoid puncturing the bladder, which is quite close to, and often forms part of, the anterior flap. Care must also be taken in passing the needle (especially when it has sharp edges) in the neighbourhood

of the stumps of the uterine arteries, or they will be pricked, and then free bleeding will cause delay in the operation.

When this operation is properly performed, there should be no projecting stump on the floor of the pelvis; the sutured edges of the peritoneum merely appear as a thin line below the base of the bladder.

The pelvis is now cleared of blood and clot; the dabs and instruments are counted, and it is also useful to examine the condition of the vermiform process, and if grossly diseased it should be removed.

The abdominal incision is then sutured in the usual way.

TOTAL HYSTERECTOMY

This operation differs from the preceding in the fact that the neck of the uterus is removed as well as its body. The abdomen is opened in the usual way and the uterus is withdrawn from the abdomen and the arteries controlled by forceps, and the broad ligaments divided exactly as in the case of the subtotal operation. Unless the uterus be very big, it is drawn well out of the abdomen and the bladder peeled off its anterior aspect. The surgeon then feels for the extremity of the cervix and opens the vagina with the scalpel and carefully detaches it from the neck of the uterus, taking great care to keep close to the cervix in order to avoid wounding the bladder or the ureters. As soon as the uterus is detached, the cut edge of the vagina is seized with the volsella to prevent it retracting. In some instances the body of the uterus may be removed as in the subtotal operation, and the cervix detached separately; occasionally the surgeon begins his operation with the intention of performing the subtotal operation, but finds the cervix unhealthy or cancerous, and removes it.

As soon as the uterus is removed and all bleeding under control, then the blood-vessels are secured with ligatures; the ovarian artery and vein are secured on each side in the usual manner. The chief point in this operation is the method of dealing with the vaginal opening. In the subtotal operation the vessels concerned in the stump are the uterine arteries, but in the total operation the territory of the vaginal arteries is invaded, and these vessels are apt to bleed when the patient is returned to bed, unless care is taken to secure them in the course of the operation. The parts which require most attention are the lateral angles in the immediate neighbourhood of the uterine arteries; these angles may be secured by a mattress suture involving the anterior and posterior walls of the vagina; any oozing on the anterior or posterior wall is commanded by a mattress suture involving these walls separately, so as not to completely close the vaginal opening. Bleeding from the cut edges of the vagina may also be readily controlled by means of a continuous

suture of thin silk. The peritoneum is sutured over the cut ends of the vagina, so that when the operation is completed a thin seam is seen lying under the base of the bladder.

In cases where the uterus is removed for septic conditions, such, for example, as an infected or gangrenous fibroid, or when cancer of the corporeal endometrium and a submucous fibroid coexist, I modify the last stages of the operation. After the ovarian and uterine arteries are ligatured, the cut edges of the vagina are secured in the following way: the cut edge of the peritoneum covering the bladder is stitched to the cut edge of the anterior wall of the vagina, and in the same way the peritoneum in relation with the posterior vaginal wall is stitched to the corresponding cut edge of the vagina. The flaps at the lateral angles of the vaginal opening are drawn together with a suture and the intervening segment is left with merely the cut edges in apposition; this affords a route for the escape of inflammatory exudation.

Whether the peritoneum is sutured over the vaginal opening, or whether the edges are merely left in apposition, the recesses of the pelvis are thoroughly cleared of fluid and clot. The dabs and instruments are counted, and the abdominal wound sutured in the usual way. In septic conditions the abdominal incision should be closed with a single row of through-and-through sutures. Before the patient leaves the operating table it is useful to examine the vagina and mop out any blood which has found its way there in the course of the operation. It is also useful to pass a glass catheter and withdraw any urine that has accumulated during the operation.

If there is evidence of free oozing it is most likely to come from the cut edges of the vaginal wall in a case of total hysterectomy: under such conditions it is easy to apply a pair of fenestrated forceps to the oozing area and leave them on for thirty-six hours. They will cause the patient trifling inconvenience. Care must be taken not to fix the blade too far on the anterior flap or it will lead to subsequent sloughing of the bladder.

When there is free oozing of blood from the cervical canal after subtotal hysterectomy, it is easily and safely controlled by applying a pair of fenestrated forceps on each side of the cervix, but not too deeply, or the ureters may be nipped. These should be left on for thirty-six hours.

TOTAL HYSTERECTOMY WITH PRELIMINARY LIGATURE OF THE HYPOGASTRIC ARTERIES

With the hope of abolishing the trouble caused by the ligatures applied to the cut edges of the vagina becoming septic I have tried the effect of tying the hypogastric arteries. This is easily carried out. After

the abdomen is opened, the peritoneum is incised where it lies over the brim of the pelvis at the sacro-iliac synchondrosis.

On the right side, care must be taken not to injure the ureter which lies in close relationship to the artery. On the left side, in addition to the ureter, the rectum complicates the proceeding. It is necessary to incise the mesorectum and turn the bowel laterally. When there has been much inflammatory trouble in the pelvis the peritoneum lining is often thick and œdematous. Under such conditions, additional care is necessary in exposing the hypogastric arteries, as the ureters are then not so easily recognized, and therefore run a greater risk of being cut during the exposure of the artery.

After the hypogastric arteries are tied the uterus is completely extirpated. Sometimes there is no bleeding from the uterine arteries when they are cut in the course of the operation; in others a thin jet of blood escapes. In either case they should be ligatured.

This method has no advantage over the ordinary operation of total hysterectomy for fibroids. It is useful when the uterus is removed for septic conditions because the ligatures applied to the cut edges of the vagina act as setons until they are extruded into the vagina.

Drainage. When the uterus has been removed for fibroids associated with inflamed and adherent ovaries, or uterine tubes distended with pus, and oozing surfaces exist in the pelvis, it is a wise precaution to drain. This is especially necessary in cases where fibroids of the uterus are complicated with cancer of the cervix. Cancer in this part of the uterus is colonized with micro-organisms.

After trying many methods I find the following useful:—

A rubber tube reaching to the bottom of the pelvis and emerging at the lower angle of the abdominal incision. It is rarely required more than forty-eight hours. Drainage judiciously employed is useful, and a tube inserted in the manner described acts better than one introduced through the vagina, and it is more easily managed; if retained too long the scar may be weak at the site of the drain tract, and is more liable to yield.

IMPACTION OF FIBROIDS

In the majority of cases an abdominal hysterectomy is a straightforward operation, but there are conditions which render the operation tedious or difficult and from these reasons are worth consideration. A common difficulty is impaction of the uterus in the pelvis. A fibroid is said to be impacted when it fits the true pelvis so tightly that the tumour cannot rise into the abdomen. At times the impaction is so complete that the surgeon finds difficulty in withdrawing the tumour even after the parts are exposed through an incision in the abdomen: in such an event

he incises the capsule and enucleates the fibroid. This relieves the impaction and allows the uterus to be freely withdrawn from the pelvis.

A common form of impaction occurs when a fibroid grows in the anterior and one in the posterior wall of the uterus. These are known as twin-fibroids (Fig. 51). So long as the antero-posterior diameter of the uterus does not exceed 10 cm. it may occupy its normal position. When this diameter increases the uterus rotates and the tumours will occupy

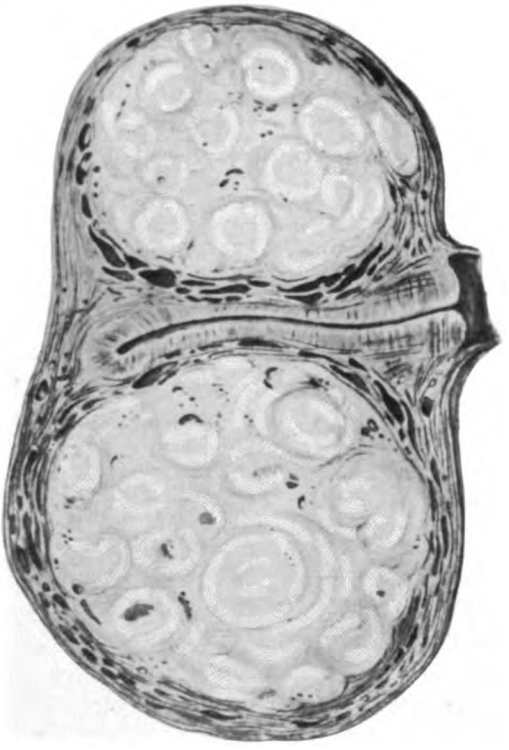

FIG. 51. UTERUS IN SAGITTAL SECTION. It is occupied by twin-fibroids which give it a 'dumb-bell' shape. The larger tumour occupied the posterior wall; it was lodged in the pelvis and had an average diameter of 9 cm. The smaller fibroid grew in the anterior wall and lay in the hypogastrium. The cavity of the uterus was at right angles to its normal position, and the endometrium is œdematous.

the transverse diameters of the pelvis, and if they continue to grow the whole of the available space in the pelvis will be occupied, and one of the tumours being lodged under the sacral promontory prevents the mass rising above the pelvic brim. This leads to complications with the rectum and bladder. One of the common causes of acute impaction of a dumb-bell shaped uterus is pregnancy. It can be easily understood that when

a uterus has a fibroid in the anterior and another in the posterior wall, one being as big as a cricket-ball and the other the size of a tennis-ball, if the woman should be unlucky enough to become pregnant the quickly-enlarging uterus in the pelvis causes awkward complications, and in many instances leads to surgical interference. Without surgical aid miscarriage occurs and occasionally ends disastrously.

A large, solitary intramural fibroid in the fundus of the uterus (Fig. 52) sometimes becomes impacted and leads to a curious error in the course of hysterectomy. Such a fibroid is usually globular. When it has a diameter of six inches or more, it will fill the pelvis and push the uterus downwards in a way that hinders the surgeon reaching the cervix, and he is sometimes astonished to find (on examining the parts after completing the operation) that he has amputated the uterus through the middle of its body instead of dividing the neck. I have seen this happen on several occasions. Patients under forty-five years of age, in whom this occurs, will menstruate after the operation if an ovary has been conserved.

FIG. 52. UTERUS IN SAGITTAL SECTION. A globular intramural fibroid occupies the fundus. From a nulliparous woman aged 45.

Axial rotation. This is a rare complication of fibroids, so rare that in more than two thousand operations for fibroids I have only seen three with a twisted pedicle.

One was a subserous fibroid the size of a tennis-ball; it had a thick stalk and a coil of ileum became entangled in the twist, producing symptoms of acute intestinal obstruction, which were relieved by operation. The patient recovered.

The second was a calcified subserous fibroid in a patient aged fifty-three. The uterus contained two large and twenty small fibroids; one of them, as big as a fist, had twisted its pedicle, producing sudden violent pain, frequent micturition, and tenesmus. Temperature 102° Fahr., and pulse-rate 120 per minute. Subtotal hysterectomy was successfully performed. The tumour, with its stalk twisted, is preserved in the Museum of the Royal College of Surgeons, England.

These are examples of twisted pedicles such as we are familiar with in the case of ovarian cysts and tumours, but when a large sessile fibroid

rotates the uterus serves as a pedicle, and a long supravaginal cervix predisposes to this abnormal movement. In some specimens, the neck of the uterus has been tightly twisted and reduced to the dimensions of a quill at the point of greatest torsion. We must distinguish between torsion of the pedicle of a fibroid and torsion of the uterus. The following is a good example of the latter:—

A spinster, aged sixty-seven, sought advice on account of pain, discomfort, and frequency of micturition associated with a tumour which could be felt in the hypogastrium. It presented the usual features of a fibroid. When exposed in the course of an operation performed for its removal the tumour was as big as the head of a new-born child. Its anterior surface was pearly white in consequence of a deposit of organized fibrin, produced by the friction of the tumour against the abdominal wall. On withdrawing the tumour from the belly, the pedicle was found to be twisted like a rope; on untwisting it, the ovaries, uterine tubes, and uterus were recognized. Subtotal hysterectomy was performed; after removing the uterus I torsioned the parts to the same degree as before removal, and hardened the specimen in a solution of formalin for preservation. The fibroid had undergone degenerative changes coincident with age, I think, and in no way a consequence of the torsion (Fig. 53). The thickness of the tissue forming the milk-white patch on the surface of the fibroid proves it to be an old tumour. It is conceivable that the involvement of the uterus was due

FIG. 53. A SESSILE SUBSEROUS FIBROID which had undergone axial rotation, involving the uterus and the appendages in the twist. From a spinster aged 67.

to, if indeed the whole movement was not facilitated by, the atrophic condition of its neck, and it is probable that the absence of acute symptoms depended on the senile condition of the uterus. B. S. Schultze collected the cases up to 1906, and Kynoch reported an interesting example in 1912. Axial rotation of an ovarian cyst with a short pedicle will sometimes involve the uterus in the twist.

There is a form of incomplete torsion of the pedicle which occurs in pedunculated subserous fibroids, such as is represented in Fig. 57, p. 133. Subserous fibroids with a thin stalk do not enlarge the uterus, and it is curious to see a tumour of this kind, weighing ten pounds or more, attached to a uterus of normal size. Such fibroids are usually cystic, due to degenerate changes induced by frequent interruption in the circulation through the narrow pedicle, caused by partial rotation of the tumour twisting and straining the narrow stalk.

Cervix fibroids. The operative treatment of this variety needs separate consideration, for these tumours do not lend themselves to any routine method. Cervical fibroids of moderate size can be easily enucleated by the vaginal route, large examples demand hysterectomy. Of all the varieties of fibroids none can cause so much difficulty in an operation as the cervix-fibroid, and, as a rule, it begins at the outset of the operation, for on opening the abdomen the surgeon finds the pelvis filled with an ovoid tumour with the uterus perched on its summit, like the lantern on the dome of a cathedral.

When the uterus, with the tumour in its neck, is not large enough to fit the pelvis tightly and can be drawn up, the operation can be easily and expeditiously performed. A tumour may be so firmly impacted that it cannot be drawn up; in such conditions the broad ligament should be divided on each side: this often facilitates the elevation of the parts, and permits access to the uterine arteries which lie on the lateral wall of the expanded cervix. (The bladder is a source of difficulty in dealing with these tumours, for it is often pushed out of the pelvis and its walls are sometimes very thick.)

In performing subtotal hysterectomy, the surgeon cuts through the thick cervix below the tumour, but in removing a central cervical fibroid he incises what appears to be the capsule of the tumour, but it is in fact the expanded cervix, and in this part of the operation he divides the uterine arteries. The cut edges of the expanded sac usually bleed freely. After the tumour is enucleated the cup-shaped sac quickly shrinks; the vessels in its wall are ligatured, and the edges of the expanded cervix approximated with sutures, and the ovarian pedicles secured in the usual way. As soon as the tumour is removed the bladder retracts into the pelvis and assumes its normal position.

Occasionally a central cervix-fibroid is so tightly impacted in the pelvis that even after the broad ligaments have been divided it cannot be raised out of the pelvis. In such a case it is a good plan to split the uterus longitudinally, taking care not to incise the bladder, then, after incising the capsule, the tumour as a rule enucleates easily. The enucleation of a large impacted fibroid requires to be conducted without undue display of force, or so much shock will be caused as will place the patient's life in peril. After the tumour has been enucleated the expanded cervix quickly contracts, and the operation is completed on the lines of a subtotal hysterectomy. Experience teaches that, as a rule, it is easier and safer to split the body of the uterus (hemisection) and enucleate a cervix-fibroid than to remove the uterus, cervix, and fibroid as one mass.

In some of my early operations for cervix-fibroids I was anxious to save the uterus; after enucleating the tumour and tying the cut blood-vessels, the edges of the incision in the expanded cervix were sewn together. In two instances I split the uterus in two lateral halves, and after shelling the fibroid out of the expanded cervix, sutured the two halves of the uterus together. These cases recovered, but on the whole the removal of the uterus with conservation of an ovary is a safer and more satisfactory proceeding. There are, of course, conditions where the surgeon feels justified in making great efforts to save the uterus even at an increased risk to the patient's life. Here, as in so many other surgical procedures, the surgeon has to exercise judgment and discretion.

When a fibroid grows from the posterior aspect of the cervix immediately beneath the peritoneum it affects the cervix very differently to one growing within it, for the neck of the uterus is stretched, but not distended, by the tumour. In such a condition, after dividing the broad ligaments and obtaining access to the pelvis, it is a good plan to split the capsule covering the tumour posteriorly, and then enucleate the fibroid; this accomplished, the operation reduces itself to a subtotal hysterectomy, but there is this difference, the surgeon will, when the tumour is big, find a pouch formed by the portion of the capsule which covered the lower pole of the fibroid: this pouch extends lower than the point at which the cervix is divided, and the vaginal stump of the cervix lies in the anterior wall of the pouch. Before suturing the stump, it is a good practice to split this portion of the cervix longitudinally with scissors in order that blood and serum from the pouch may freely escape into the vagina.

In some examples of cervix-fibroids, after removing the uterus and making the blood-vessels secure, instead of stitching the edges of the expanded cervix together, it is only necessary to sew the peritoneum over the cut edges.

Fibroids growing from the anterior aspect of the cervix either bulge into the vagina or rise into the hypogastrium. The former can be safely enucleated by the vagina; those which grow into the hypogastrium sometimes strip the peritoneum from the anterior abdominal wall for two or three inches, or more. Occasionally such tumours can be removed through a median sub-umbilical incision without opening the peritoneal cavity.

OPERATIONS FOR THE REMOVAL OF FIBROIDS FROM THE BROAD LIGAMENT

Fibroids of large size unconnected with the uterus and growing between the layers of the broad ligament are often troublesome tumours to remove. On opening the abdomen, the surgeon recognizes the nature of the tumour-mass when he finds that the uterus is not incorporated

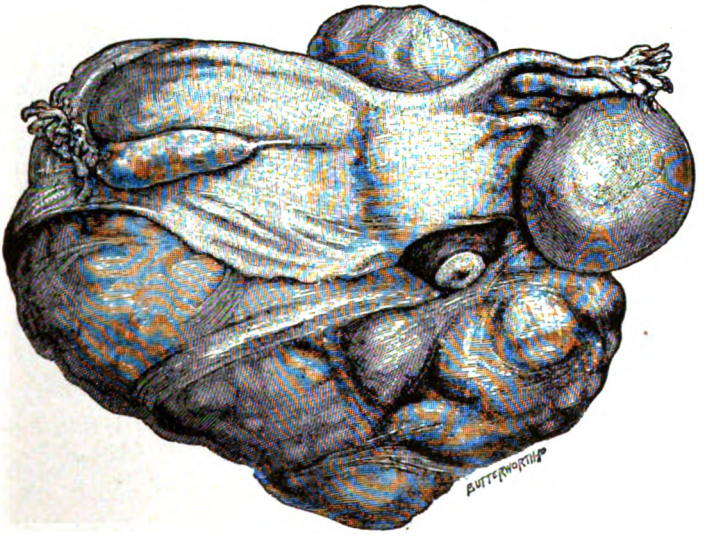

FIG. 54. FIBROID OF THE LEFT BROAD LIGAMENT. The uterus rests upon, but is not involved in, the tumour. A process of the fibroid bulges between the ovary and the tube. The right ovary is cystic. From a married woman aged 52.

with it, and the tumour itself covered with a thin, loose, transparent veil of peritoneum. On incising the peritoneal covering, the fibroid is easily enucleated, and, as a rule, there is free bleeding from the large veins in its capsule, especially in the vicinity of the bladder. The process of enucleation should be conducted carefully, for the ureters lie below the tumours and in this operation are easily injured. The bladder is spread out over the surface of a broad ligament fibroid and runs great risk of being cut. When the tumour is very large and has interfered with the

bladder so as to cause chronic retention of urine, the vesical walls, as a result of repeated distension, become thin and resemble peritoneum: in such conditions a large portion of the bladder is sometimes accidentally cut away with the tumour. On one occasion, in such a case, I cut off the upper third of the bladder, but recognizing my fault, carefully joined the divided edges of the bladder with very fine silk sutures and drained it with a self-retaining catheter for ten days. The woman recovered. Three years later I was able to investigate the capacity of the bladder and found that it could hold fifteen ounces of urine.

The tumour represented in Fig. 54 occupied the left half of the broad ligament; after the enucleation, I could see the terminal four

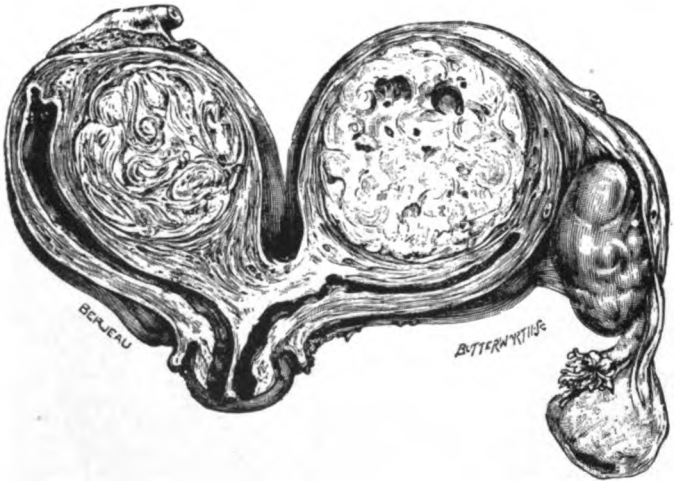

FIG. 55. A BICORNATE UTERUS. This uterus is shown in frontal section; each cornu contains a fibroid. Removed from a spinster aged 32 on account of acute pain, probably caused by the axial rotation of one cornu. Two-fifths size.

inches of the ureter lying on the floor of the cavity left by the removal of the fibroid. The bladder was carefully detached from the surface of the tumour, and the cavity drained with a rubber tube. Next day the dressings were soaked with urine, and it was uncertain whether the urine leaked from the ureter or the bladder. The drainage-tube remained in position ten days; the leakage of urine gradually diminished and finally ceased. The patient made a quick and permanent recovery.

Experience teaches that in removing a mesometric fibroid the operation is made safer by the removal of the uterus. In many cases the surgeon has no choice, but occasionally he is tempted to leave the uterus, but it is an unwise step which leads to troublesome bleeding. Removal of the uterus enables the surgeon to make hæmostasis more complete.

The two chief causes of the high mortality of operations performed for the removal of broad-ligament fibroids are injury to the ureter, and uncontrollable venous bleeding. The bladder and ureters are more often injured in the removal of mesometric fibroids than in any other pelvic operation. It is fortunate that such tumours are uncommon.

On hysterectomy when the uterus is double. Fibroids and cancer arise in malformed uteri, as well as in those of normal shape (Fig. 55). When the body of the uterus is double (bicornate), and the surgeon stumbles upon it in the course of a pelvic operation, he may be

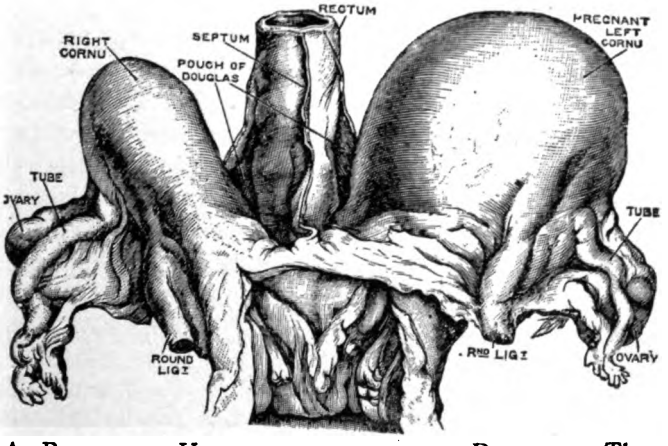

FIG. 56. A BICORNATE UTERUS SHORTLY AFTER DELIVERY. The pregnancy occurred in the left half. The vesico-rectal ligament is well shown.

puzzled if he is not familiar with the anatomical conditions associated with this malformation.

When the body of the uterus is bicornate the rectum lies in the middle line of the pelvis, and a median vertical fold of peritoneum, the *ligamentum vesico-rectale,* passes from its anterior aspect through the gap between the uterine cornua to become continuous with the peritoneum covering the posterior surface of the bladder (Fig. 56). That portion of the vesico-rectal ligament which lies between the rectum and the neck of the uterus divides the recto-vaginal fossa into a right and left half. This peritoneal ligament requires careful treatment, or the surgeon may accidentally open the rectum or the bladder. In closing the peritoneum over the cervical stump it is sometimes necessary to bring the edges of the abnormal fold into apposition vertically by a continuous suture.

In a case of this kind in which I performed total hysterectomy for cancer of the neck of the uterus the extensive peritoneal connexions were somewhat troublesome, and when the uterus was removed it seemed as if

the floor of the pelvis had been stripped of its serous covering. The bifid nature of the uterus had been anticipated before the operation, as an imperfect vertical septum was known to exist on the posterior vaginal wall. I removed, from a spinster, aged fifty-four, a uterus which contained a quickly growing fibroid. The tumour, when the abdomen was opened, appeared to be an intramural fibroid in the fundus of the uterus; it was ovoid and its upper pole reached as high as the ensiform cartilage. On examining the parts after the operation, it proved to be an intramural fibroid growing between the horns of a double uterus of the variety known as *uterus bicornis unicollis*. The operation was as simple as when the uterus is normal. The patient made an excellent recovery.

Experience teaches that bicornate uteri cause more difficulties in diagnosis than in technique, but the presence of the vesico-rectal ligament would probably bar the removal of the uterus by the vaginal route. The existence also of a median longitudinal septum, partial or complete, in the vagina would be another difficulty.

References to Reports of Hysterectomy performed for Fibroids in Malformed Uteri

Bland-Sutton, J. Fibroids in a Unicorn Uterus. *Clin. Journ.*, Lond., 1901–2, xix. 1.

Bland-Sutton, J. Case of Fibroids in both halves of a Bicornate Uterus. *Proc. Roy. Soc. of Medicine*, 1908. Obstet. and Gyn. Sect., ii. 95.

Doran, A. The Removal of a Fibroid from a Uterus Unicornis in a Parous Subject. *Brit. Med. Journ.*, 1899, i. 1389.

Gow, W. J. Cystic Intraligamentous Myoma with Double Uterus. *Trans. Obstet. Soc.*, Lond. (1898), 1899, xl. 314.

Heinricius. Ein Fall von Myoma im rudimentaren Uterus bicornis unicollis. *Monatschr. f. Geburts. u. Gyn.*, Berl., 1900, xii. 419.

Kamann. Uterus bicornis unicollis with a Myoma in the Left Horn; Subtotal Extirpation of the Left Horn. *Centralbl. f. Gyn.*, 1905, xxix. 795.

Routh, A. Fibroid of One-horned Uterus. *Trans. Obstet. Soc.*, 1888, xxix. 2 and 57, with a good drawing.

THE FLORA OF THE UTERUS IN RELATION TO HYSTERECTOMY

Micro-organisms play a great part in the production of uterine disease. Injuries of the uterus of all kinds are often more serious from sepsis which follows such accidents than from actual damage to the organ. The micro-organisms of the uterus also influence in a remarkable degree the results of hysterectomy. For example, the death-rate of hysterectomy for fibroids is under 2 per cent., whilst the removal of the uterus for cancer of its neck by the abdominal route is 20 per cent. This

difference in the results of hysterectomy for fibroids and for cancer of the neck of the uterus depends on the flora of the uterus.

The uterus of virgins, as a rule, contains no micro-organisms. Being desirous of ascertaining the bacteriologic condition of the cervical canal and the uterine cavity of women with fibroids I had a series of observations made in cases of subtotal hysterectomy. The investigation was conducted by two independent observers (Somerville Hastings and C. H. S. Webb), and their findings tallied uniformly and were confirmed by the clinical course of the patients. In the majority, especially nulliparous spinsters, the cervical canal and uterine cavity were sterile. In married women who have had children, and in whom the mouth of the womb is patulous, staphylococcus, bacillus coli, and Döderlein's bacillus occur. In extruded fibroids streptococci exist sometimes in pure culture and occasionally mixed with the colon bacillus. The proportion of cases is small in which pathogenic micro-organisms are found, but they are more common in a uterus containing a submucous fibroid when the patient is multiparous, than in that of a nulliparous spinster with a narrow cervical canal.

In regard to the fibroids: I have had very many examined, especially those which have undergone degenerative changes, such as softening and red degeneration. In all cases, except one, where the red degeneration was associated with pregnancy, the fibroids have been sterile. The exception occurred in a subserous fibroid which was associated with pregnancy and was the most acute example of red degeneration I have seen. A staphylococcus was grown from it. The comparative freedom of the uterus from pathogenic micro-organisms explains the great success of subtotal hysterectomy. Streptococci exist in the cervical canal sufficiently often to entail on this important operation a risk of a peculiar kind; they hinder convalescence in a considerable number of patients, and entail the death of a few. (See Pulmonary Embolism.)

When we turn to cancer of the neck of the uterus, the picture is quite different, for the morbid tissue in this disease abounds in micro-organisms, such as staphylococcus, streptococcus, the colon bacillus, bacillus pyocyaneus, &c. The streptococcus occurs either in pure culture in carcinoma of the cervix or in company with the staphylococcus and colon bacillus; it is extremely virulent for the peritoneum. The presence of the streptococcus is important in another aspect. This micro-organism not only infects the pelvic tissues in the course of the operation, but the gloves of the surgeons are contaminated; this leads to infection of the sutures used to close the wound.

REFERENCES

BLAND-SUTTON, J. The Exotic Flora of the Uterus in relation to Fibroids and Cancer. *Brit. Med. Journ.*, 1913, i. 205.

WEBB, C. H. S. A note on the Bacteriology of the Uterine Cavity in Fibromyomatous Disease. *Arch. Middlesex Hosp.*, 1912, Clinical Series, No. x. 5.

VISCERAL COMPLICATIONS ASSOCIATED WITH FIBROIDS IN RELATION TO HYSTERECTOMY

Fibroids, being common tumours, are often present in patients suffering from diseases in organs which have no intimate connexion with the uterus. From time to time attention is drawn to the remote effects which rapidly-growing uterine fibroids may exert on the heart, or the thyreoid gland. We know that the pressure of a large fibroid can, and often does, exert a deleterious effect on the bladder, but albuminuria may be present and have no relation to the fibroid. Another disease occasionally associated with fibroids is diabetes. It is necessary to discuss some of these conditions.

Cardiac lesions. It has been maintained by several writers that submucous fibroids exert a causative influence in the production of heart disease, especially when they cause menorrhagia. It is quite true that many patients with fibroids in the uterus have valvular lesions as the result of rheumatic fever, and in many who have been reduced to a condition of profound anæmia by profuse menstruation, the heart will furnish a hæmic murmur on auscultation. I have had careful observations made on the cardiac condition of patients with fibroids under my care; there is nothing that can be described as peculiar to the influence of these tumours.

On a dozen occasions I have removed a uterus containing large tumours, when the heart has furnished a murmur clearly due to a valvular lesion. In such circumstances the patient is always submitted to a careful examination at the hands of a physician, and if the compensation be satisfactory, the operation is undertaken. There are conditions when the removal of a large fibroid may benefit a patient with heart disease. For example: A stout patient, aged fifty, with a huge ovarian cyst and a fibroid as large as a football, suffered from severe attacks of dyspnœa, due to a dilated heart and myocarditis. The anæsthetist would not give her a general anæsthetic, but I felt if the tumour could be removed great relief would follow. Chloroform, in any form, or in any combination, being out of the question, I resorted to an intradural injection of novocaine and removed the tumours. The operation was followed by a rapid convalescence: the cardiac symptoms disappeared, and within three

months the woman was robust and well, leading an active and useful life.

When we consider the enormous size and vascularity of some fibroids we might readily believe that the extra duty thrown upon the heart would lead to its enlargement. The heart is an adaptable organ: it was formerly taught that it enlarged during pregnancy and returned to its natural size during the puerperium, but statements of this kind could only be founded on speculation. When a vascular fibroid, weighing thirty pounds, has been removed from an otherwise healthy woman, it is not unreasonable to expect that the amount of work required of the left ventricle would be reduced, therefore, the muscle tissue in that part of the heart would undergo a corresponding reduction.

Lesions of the thyreoid gland. The thyreoid gland is another organ believed for ages to be in correlation with the reproductive organs, and modern physiological and pathological researches confirm the tradition.

On three occasions I have removed a uterus containing fibroids from women who, at the time of the operation, possessed enlarged thyreoid glands. The goitres being of the parenchymatous type, I have been surprised, on seeing the patients six months after the hysterectomy, to notice marked diminution in the size of the goitrous thyreoids.

In 1908 a spinster, aged 44, suffered from menorrhagia due to multiple fibroids, but she also suffered from exophthalmic goitre and the thyreoid was enlarged and pulsated strongly. It occurred to me that as the removal of the uterus for fibroids caused goitrous thyreoids to shrink, such a sequel might be expected if the uterus were removed from this patient. After a careful consideration of the circumstances, I decided to remove the uterus with the ovaries and tubes by the subtotal method. The operation was carried out in the Middlesex Hospital; it lasted twelve minutes. Chloroform was employed for the anæsthesia. Before operation the patient's temperature was 99° Fahr., and the pulse-rate 130. Twenty hours after the operation her temperature was 102° Fahr., and the pulse-rate 140 per minute, but the thyreoid gland had markedly diminished and the eyeballs were less prominent. Forty-eight hours after the operation she was in a desperate condition; the temperature was 104° Fahr.; pulse-rate 180 per minute, the thyreoid gland had further diminished in size, and a condition of acute thyreoidism prevailed. The patient died fifty-six hours after the operation. A post-mortem examination was not permitted by the patient's friends.

Diabetes. This is a condition which will sometimes place the surgeon in a quandary when he is considering the propriety of advising hysterectomy for fibroids. I have performed this operation on three

occasions in diabetics. One case is instructive. A widow, aged 43, passed sugar in her urine to the extent of 5 grains per ounce. She also suffered from menorrhagia, her menstrual periods lasting on an average ten days; the elongation depending on a large submucous fibroid. She wished to re-marry and was deterred from doing so, not by the glycosuria, but by the menorrhagia. She wished to have the tumour removed. I performed subtotal hysterectomy. The patient made a quick and uneventful convalescence, re-married, and was in good health three years after the operation.

All patients who come under my care for hysterectomy have their urine examined for sugar. It is a serious responsibility to operate upon a patient whose urine contains sugar, but the risk must be faced in exceptional cases of which the following is an example:

A married woman, aged 69, had a fibroid as big as a football. There was free bleeding from the vagina at frequent, but irregular intervals, which led us to suspect that cancer existed in the body of the uterus as well as a fibroid. The condition was complicated by diabetes, the sugar amounting to ten grains per ounce of urine. Abdominal hysterectomy was performed in 1904. The uterus contained a large submucous fibroid and a cancerous mass as big as a tennis-ball. The patient recovered quickly and was reported to be alive and well eight years afterwards (December 1912).

PELVIC COMPLICATIONS

Among the complications which the surgeon may find in the abdomen when he embarks on the performance of hysterectomy the following may be mentioned:

Fibroids are often associated with cysts of the ovary, large and small. Twenty-five years ago it was the common practice to remove the ovarian tumours and leave the fibroids to shrink. To-day the uterus is removed with the cysts.

It is a common thing in the course of abdominal hysterectomy to find the vermiform process thickened, inflamed, or adherent to a fibroid. In such circumstances it should be removed. It happens occasionally that patients make it a condition of the operation that the vermiform process be removed as well as the uterus. I invariably conform to their wishes, but I do not remove the vermiform process as a routine measure.

On three occasions I have removed the gall-bladder in the course of a hysterectomy for fibroids. In each patient it was enlarged and filled with gall-stones. In these three cases the uterus was so big that an incision was needed reaching nearly as high as the xiphoid cartilage to enable the tumours to be withdrawn from the abdomen. In such con-

ditions the gall-bladder was easily accessible, and easily, as well as safely, removed. In two other instances of this combination I removed the gall-bladder six months after hysterectomy.

FIBROIDS AND PREGNANCY

It is well to note that when fibroids are associated with pregnancy—uterine, tubal, or cornual—the operative procedures are in no way rendered difficult and the consequences, immediate and remote, are invariably favourable. Perhaps the rarest combination of this kind is the co-existence of fibroids and hydatidiform degeneration of the chorion. I have had one such case. The masked signs of pregnancy accompanying this degenerate form of conception occasionally mislead surgeons. Mrs. Scharlieb extirpated the uterus under the impression that it contained a soft degenerate fibroid, and on incising the uterus a dead fœtus of the third month was found in its cavity but no fibroid. The patient was aged 51. Such a combination would mislead many.

It is remarkable, considering the frequency with which fibroids interfere with the bladder, that hydronephrosis so rarely occurs as a serious complication. I had under my care a woman with a fibroid impacted in the pelvis and a definite movable tumour in the left loin as big as an ostrich's egg. I regarded this as a hydronephrotic tumour secondary to the pressure exerted on the left ureter by the fibroid in the pelvis. Hysterectomy was performed, and on its completion I was able to reach the movable cystic kidney quite easily through the median incision, and after dividing the left meso-colon, the pedicle was ligatured and the kidney detached. On examining the parts after removal I was astonished to find the ureter thin and narrow, the pelvis was dilated and the kidney sacculated but not in consequence of pressure on the ureter, and the trouble in the kidney could not be attributed to the fibroid.

FIBROIDS AND CANCER OF THE COLON

Fortunately uterine fibroids rarely contract adhesions to the intestines unless the uterus and uterine tubes have been the seat of infection, gonorrhœal or puerperal. It is unusual for the surgeon to be hampered with bowel complication when he undertakes hysterectomy for fibroids, but there are two conditions in which he may have to deal with cancer of the sigmoid colon, or the upper part of the rectum. It has happened to me on three occasions in the course of removing the uterus for fibroids to find cancer of the sigmoid colon. After completing the hysterectomy I excised the cancer in the colon and joined the cut ends of the bowel by an end-to-end anastomosis. In a woman much blanched from profuse uterine bleeding due to a cervical fibroid I removed the uterus and its

neck (total hysterectomy), and in adjusting the intestines preliminary to closing the incision detected a cancerous focus in the sigmoid colon. The patient had sustained a serious operation, and in her weak condition I did not think it wise to excise the bowel. She made an excellent recovery and was kept under observation: two months later I excised the growth from the sigmoid and she recovered easily from the operation.

The growth of cancer in the colon is slow and insidious, and there is a massive form of colic cancer which, during its symptomless stages, especially when the mass lies in contact with the uterus, furnishes signs indistinguishable from a subserous fibroid. The diagnostic signs are sometimes especially deceptive if there should, at the same time, be a few small hard fibroids in the uterus.

On several occasions I have found it difficult to decide the nature of a pelvic swelling. Sometimes I have undertaken an abdominal operation hoping to find an impacted fibroid, but have found a hard cancerous growth in the sigmoid colon impacted in the pelvis, and the operation has ended in colotomy. In happier cases I have started on the operation with strong suspicions that the patient had a malignant mass in the bowel, and found an impacted fibroid. The most evil combination is to find a patient with a fibroid of moderate size in the uterus and a massive cancer of the sigmoid colon adherent to it. Here colotomy is the usual remedy.

I am not alone in such experiences, because some of my colleagues have occasionally stumbled on a cancerous pelvic colon in mistake for a fibroid and have handed the patients to their surgical associate for the operation of resection.

CANCER OF THE BREAST AND FIBROIDS

A very cursory study of morbid anatomy will suffice to show that many women who die with cancer of the breast have fibroids in the uterus. In spite of this it is rare for a woman to come under observation with a troublesome uterine fibroid and cancer of the breast. In 1905 a schoolmistress, aged 54, had a very large fibroid which she was anxious to have removed because it interfered with her activity. At the same time she drew my attention to an obvious cancerous lump in her breast. After careful consideration I performed subtotal hysterectomy, removing both ovaries. After closing the abdomen I excised the cancerous breast and the axillary lymph glands. I removed both ovaries with the hope that she would obtain whatever inhibitory effects bilateral oöphorectomy is supposed to exercise on mammary cancer.

The patient recovered easily from the double operation and died from recurrence and internal dissemination five years later.

I have performed this double operation on two other patients:

A patient doing missionary work in India was invalided home on account of profuse uterine bleeding due to a submucous fibroid as big as an orange. She was anxious to return to India and casually asked me to examine a lump in her breast. It was an undoubted carcinoma. I therefore performed subtotal hysterectomy at the Middlesex Hospital, 1911, and at the same time removed the diseased breast. The tumour was examined microscopically and showed the typical signs of cancer. The patient made a quick recovery from the double operation.

The third case was a spinster aged 54, with an enormous fibroid and an unmistakable cancer in the breast. As she was much embarrassed by the uterine fibroid I decided to perform the double operation. On this occasion, as respiration was much impeded by the fibroid, I performed hysterectomy, then amputated the breast and cleared out the axilla. I think this is the wiser course. The patient made a quick and uninterrupted recovery.

SARCOMA OF THE TIBIA AND FIBULA

In 1909 the wife of a medical practitioner who suffered severely from menorrhagia and pain due to a uterine fibroid was anxious to have the uterus removed. In the course of the consultation she casually drew my attention to a swelling on her tibia which presented the clinical signs of a periosteal sarcoma. In order to make the diagnosis definite, I excised a fragment of the tibial tumour and examined it microscopically. It was a spindle-celled sarcoma. I amputated the leg through the knee-joint. After the patient recovered from the operation the menorrhagia caused so much trouble that she requested me to remove the uterus. Hysterectomy was performed in November 1911. She was reported to be in good health in December 1912.

THE RISKS OF ABDOMINAL HYSTERECTOMY FOR FIBROIDS

The dangers of hysterectomy are those common to all forms of abdominal operations, such as sepsis, peritonitis, shock, and the risks of the anæsthetic. There are certain special dangers such as hæmorrhage; injury to the pelvic segments of the ureters, and especially the bladder; injury to the intestines, and especially the rectum; acute intestinal obstruction; thrombosis and pulmonary embolism. These risks and dangers are considered in a special chapter (p. 13).

Among rarer forms of death after hysterectomy may be mentioned acute perforation of the stomach or the small intestine; cerebral hæmorrhage; lobar pneumonia; thrombosis of the right auricle; embolism of the femoral artery ending in gangrene; suppression of urine; and acute

mania. These are causes of death which follow any major operation in surgery, and have no special connexion with hysterectomy.

Mortality. In order to give some idea of the great improvement which has taken place in the operation of abdominal hysterectomy for fibroids in London, the following figures will be found of great interest.

In the year 1896 the results of abdominal hysterectomy for fibroids in the hospitals of London may be inferred from the following table:—

St. Bartholomew's	7	with	3 deaths
St. Thomas's	5	"	2 "
St. George's	1	"	0 "
Middlesex	6	"	1 "
University College	3	"	0 "
Samaritan	17	"	4 "
Soho (for women)	1	"	0 "
Chelsea Hospital for Women	9	"	1 "
	49	"	11 "

In these hospitals and the New Hospital for Women the returns in 1906 are as follows:—

St. Bartholomew's	26	with	4 deaths
St. Thomas's	40	"	2 "
St. George's	8	"	0 "
Middlesex	50	"	0 "
University College	21	"	1 "
Samaritan	37	"	2 "
Soho (for women)	60	"	1 "
Chelsea (for women)	80	"	1 "
New (for women)	26	"	0 "
	348	"	11 "

During the years 1906 and 1907, at the Middlesex Hospital and the Chelsea Hospital for Women, I performed abdominal hysterectomy for fibroids on 101 patients and they all recovered: the series continued unbroken until I had performed 130 of these operations without a death.

My predilection for subtotal hysterectomy may be gathered from the following statement: Mr. C. H. S. Webb, Surgical Registrar to the Middlesex Hospital, has examined my case-records. He finds that among the last 109 abdominal operations for fibroids I have performed in that institution, 103 were subtotal and 5 total hysterectomies. There was one abdominal myomectomy. All these patients recovered. (March 1, 1913.)

As a rule, subtotal hysterectomy is simpler than the total operation. There are conditions in which it is imperative to remove the whole cervix, especially when it is big and hard, or big and spongy: or when the cervical canal is wide and perhaps septic, and especially if there is the least suspicion that the neck of the uterus is cancerous (see p. 136).

Subtotal hysterectomy is a safe method for removing the uterus when pregnancy and fibroids co-exist, for this combination is sometimes so

dangerous to the life of the mother as to render an operation necessary.

In 1901 I collected and published a dozen cases in which subtotal hysterectomy had been performed for this combination. Since that date a large number of cases have been reported, and as this experience is crystallized in practice it is unnecessary to adduce further evidence in its favour. I have performed subtotal hysterectomy with success for big fibroids complicated with tubal pregnancy.

Hysterectomy is sometimes required when labour is obstructed by a fibroid. In this event some surgeons prefer the total, and others the subtotal method. When hysterectomy is performed during labour, the cervix is so thin and expanded that it is difficult in the course of the operation to determine the junction of the cervix with the vagina.

In 1901 I collected some records relating to labour obstructed by uterine fibroids; most of them revealed a grim history of tragedy and woe. A broad survey enabled me to form the opinion that ovarian tumours have caused great trouble to parturient women, but fibroids have been more lethal as they frequently become septic during the lying-in. The whole subject is an instructive and impressive illustration of the baneful effects which environment often imposes on so-called innocent tumours. The subjoined table indicates that surgical interference when labour is obstructed by fibroids is more merciful to the mother than to her offspring.

CASES OF HYSTERECTOMY PERFORMED ON PATIENTS IN LABOUR FOR OBSTRUCTION DUE TO FIBROIDS

Operator.	*Result to Mother.*	*Fate of Child.*	*Nature of Operation.*	*Reference.*
Spencer	R.	L.	Cæsarean Section, Subtotal Hyst.	*Trans. Obstet. Soc.*, xxxviii. 389.
Bland-Sutton [1]	R.	D.	Total Hyst.	*Trans. Obstet. Soc.*, xlvi. 238.
Morison	R.	D.	Cæsarean Section, Total Hyst.	*Northumberland and Durham Med. Journ.*, 1904.
Acland	R.	?	Cæsarean Section, Subtotal Hyst.	*Lancet*, 1904, ii. 948.
Spencer	R.	L.	Cæsarean Section, Total Hyst.	*Trans. Obstet. Soc.*, 1906, xlviii. 240.
Spencer	R.	D.	Cæsarean Section, Total Hyst.	*Trans. Obstet. Soc.*, 1908.
Bland-Sutton	R.	L.	Cæsarean Section, Total Hyst.	1912, unpublished.

[1] This is the first recorded case of total hysterectomy during labour. Operation May 9, 1904.

Hysterectomy has been performed successfully on patients over 70 years of age. My experience of the subtotal operation in patients after the menopause proves it to be even safer than during menstrual life. The atrophy of the cervix after the fiftieth year of life leads to the formation of a thin and almost bloodless stump that gives no trouble during the operation afterwards.

TABLE OF CASES IN WHICH HYSTERECTOMY WAS PERFORMED ON WOMEN OF 70 YEARS AND UPWARDS

Reporter.	*Age.*	*Nature of Operation.*	*Result.*	*Reference.*
Bland-Sutton	73	Subtotal for Fibroid 28 lb.	R.	*Trans. Obstet. Soc.*, 1900, xli. 300.
Bland-Sutton	70	Subtotal for Fibroid	R.	*Middlesex Hosp.*, 1910.
Stewart McKay	70	Subtotal for Fibroid 19 lb.	R.	*Australian Med. Gaz.*, 1907, 14.
Bland-Sutton	83	Vaginal Hyst. for Villous Disease	R.	*Trans. Obstet. Soc.*, 1906, xlix. 46.
Malcolm	74	Total for Fibroids	R.	*Brit. Med. Journ.*, 1907, ii. 1571.

CHAPTER II

ABDOMINAL MYOMECTOMY

Under this general term it is usual to include operations for the removal, through an abdominal incision, not only of pedunculated subserous fibroids, but also sessile and interstitial (intramural) fibroids of the uterus.

The earliest operations of this kind were performed by Spencer Wells (1863); but little attention was given to this matter until the advantages of abdominal myomectomy were strongly advocated by A. Martin (1880) and Schroeder (1893). The operation has been practised by many surgeons and gynæcologists imbued with conservative ideals in regard to the uterus. In its early days the operation was attended with a very high mortality, but the great improvements in hysterectomy have limited very materially the scope of abdominal myomectomy.

ABDOMINAL MYOMECTOMY AND ENUCLEATION FOR FIBROIDS

Abdominal myomectomy. This signifies the removal of one or more pedunculated subserous fibroids through an incision in the abdominal wall, preserving the uterus, uterine tubes, and the ovaries.

Abdominal enucleation. In this operation a sessile fibroid is shelled out of its capsule: the uterus, ovaries, and tubes are preserved.

Hysterotomy. In this operation a submucous fibroid is removed, through an incision in the wall of the uterus, which opens the uterine cavity.

The preliminary steps for each of these procedures are the same as for ovariotomy, and the Trendelenburg position is of great advantage.

After opening the abdomen the intestines are carefully protected by a warm dab, and the tumour carefully examined. When the stalk is narrow it may be transfixed and secured with silk thread, like the pedicle of an ovarian cyst. When the pedicle is short and broad the tumour should be shelled out of its capsule, and any obvious blood-vessel is secured with forceps and ligatured with silk. The flaps of the capsule are brought into apposition by mattress sutures, and the redundant portions of the capsule cut away and the free edges carefully brought together by a continuous suture of thin silk.

On two occasions I have found a subserous fibroid of moderate size, growing from the posterior wall of the uterus by a long stalk, so firmly

impacted in the pelvis that it could not be extracted; the uterus was also tightly compressed in the pelvis by the fibroid. In these circumstances I found the operation greatly facilitated by dividing the stalk of the tumour. The fibroid was then easily extracted.

When a fibroid is embedded in the wall of the uterus, the tumour is exposed by cutting through its capsule and seizing it with a volsella; as a rule it shells out quite easily. This is followed by free bleeding. The vessels are then seized with forceps and ligatured with thin silk. In order to completely control the oozing, mattress sutures are passed through the wall of the capsule on each side, their number varying with the size of the tumour.

The difference in the risks and difficulty of enucleating a fibroid from the uterus and of removing a pedunculated fibroid is easily explained. Pedunculated subserous fibroids do not cause enlargement of the uterus (Fig. 57), but an intramural fibroid, like the submucous variety, leads to great thickening of the uterine walls and increased vascularity. The normal uterus in an adult weighs 2½ ounces. The uterus and tumours represented in Fig. 51 weighed 80 ounces. Of this total weight the tumours represented 64 ounces and the uterus 16 ounces. This increase in the tissues of the uterus is accompanied by increased vascularity, and helps to explain the troublesome bleeding which attends an enucleation.

Although there is less bleeding in the removal of pedunculated subserous fibroids, there is another serious risk to the patients which must not be forgotten, for they are very liable to intestinal obstruction from adhesion of intestine to the stump.

In some instances a uterus contains ten or more fibroids, and each must be enucleated and the capsule secured with ligatures, as described above.

Sometimes the oozing is difficult to control, and the surgeon sutures the edges of the capsule to the lower angle of the incision, and stuffs the cavity or bed of the tumour with gauze.

In removing a large submucous tumour through an incision in the wall of the uterus, the surgeon necessarily opens the uterine cavity (hysterotomy). After controlling the bleeding the walls of the uterine incision are closed, as in Cæsarean section.

In many instances in which the surgeon attempts to carry out myomectomy or enucleation, he has such difficulty in controlling the oozing that he is driven to remove the uterus.

It is admitted by most writers that the ideal method of dealing with fibroids requiring removal by cœliotomy is to remove them either by ligature or by enucleation. In actual practice this ideal operation of removing the tumours and leaving the uterus and ovaries intact can only

be carried out in a small proportion of cases, probably less than 10 per cent., and it is fair to state that enucleation and hysterotomy are often more troublesome and serious operations that hysterectomy; also the preservation of the uterus is not always an advantage to the patient.

When a woman is submitted to hysterectomy for fibroids we can assure her that the tumours will not recur, but after a myomectomy or enucleation in a woman in the reproductive period of life we cannot give her this assurance, for she may have in her uterus many 'seedlings' or 'latent fibroids,' and one or several of these may grow into formidable tumours.

There are three conditions in which myomectomy and enucleation are legitimate procedures:

1. A young woman contemplating marriage, or a married woman anxious for offspring, if her tumour be single and admits of myomectomy or enucleation, may have her uterus spared. Although I have carried out these measures on many occasions, I only know of five patients who have subsequently borne children.

2. Occasionally in pregnancy.

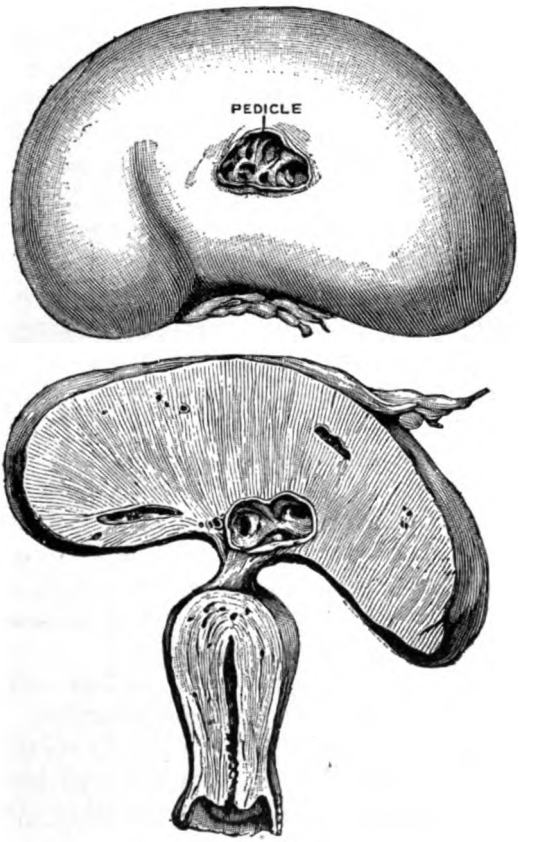

FIG. 57. UTERUS AND SUBSEROUS FIBROID IN SECTION. The fibroid has a narrow vascular stalk. Pedunculated subserous fibroids do not cause the uterus to enlarge. The tumour, in shape and mobility, furnished the clinical signs of a wandering spleen.

3. Myomectomy is a very safe undertaking in patients at or after the menopause, where a stalked fibroid gives trouble by twisting its pedicle, or by shrinking to such a size that it falls into the true pelvis and becomes impacted; or, more rarely, the pedicle of such a tumour entangles a loop of small intestine and obstructs it.

In order to give the matter a statistical basis I have drawn up an

analysis of ninety-five consecutive cases of myomectomy and enucleation out of my practice, with the subsequent history of some of the patients. This experience covers a period of twelve years.

Of these ninety-five patients three died as the result of the operation—two from pneumonia in the fourth week after operation, and one a few days after operation: in this case there is reason to believe that the tumour was complicated with cancer of the body of the uterus.

Six of the women were submitted to myomectomy during pregnancy, and in four cases the operation was undertaken under the impression that the tumour was an ovarian cyst which had undergone axial rotation. These cases occurred in the days before I recognized that 'red degeneration' of fibroids complicating pregnancy caused them to be painful and tender. In one patient this complication was clearly recognized. In the sixth patient the tumour was regarded by some capable gynæcologists who examined her as a tubal pregnancy complicating a gravid uterus. Five of these patients went to term and were delivered of living children. The sixth miscarried two months after the myomectomy.

Of the ninety-two successful myomectomies, five subsequently became pregnant and had living children, but in each instance the fibroids were subserous. I have not known a patient to become pregnant after abdominal myomectomy for a submucous fibroid, large or small. In calculating the probability of pregnancy from these statistics it must be mentioned that the patients fall into three categories:

1. Forty women were in the child-bearing period of life and married; many of them were multiparæ.

2. Twenty were single women and probably capable of bearing children in a favourable environment.

3. The remainder were elderly spinsters or barren wives.

A significant feature in the after-history of ten of these women is the fact that some years later other fibroids grew in the uterus, and hysterectomy became a necessity on account of menorrhagia in seven of them; of these, two died from the operation, which was difficult and tedious. One patient was operated upon two years after the myomectomy, and had borne a child in the interval, and the other seven years.

The last fact to mention is that one patient, from whom a submucous fibroid had been enucleated from the cavity of the uterus (hysterotomy), died four years later from cancer arising in the body of the uterus.

Olshausen, in a careful consideration of this question, finds that the chief objection to the abdominal enucleation of uterine fibroids is the high mortality of the operation: he states that out of 563 myomectomies collected from 12 surgeons, including himself, 59 patients died, representing a mortality of 10.5 per cent. In the years 1900–5, Olshausen

performed enucleation on 124 patients, with 14 deaths. Eight of the patients subsequently came under his notice with recrudescence of the fibroids.

Christopher Martin has performed 73 abdominal myomectomies, with one death. He informs me that he is less inclined to do abdominal myomectomy (except in young married women very anxious for children), as in many cases he has had to perform a second operation for a further crop of fibroids.

My attitude to abdominal myomectomy may be gathered from the following epitome of my experience: In the first 1,000 abdominal operations for fibroids there were 97 myomectomies; in the second 1,000 there were 15.

References

MARTIN, C. On the Dangers and Treatment of Myoma of the Uterus. *Lancet*, 1908, ii. 1682, and a private letter, 1913.

OLSHAUSEN, R. In Veit's *Handbuch der Gynäkologie*. Wiesbaden, 1907, Bd. ii. 607.

CHAPTER III

ON THE RELATIVE VALUE OF TOTAL AND SUBTOTAL HYSTERECTOMY

THE great success which followed the use of the short ligature in ovariotomy induced several surgeons to apply the same principle to the cervical pedicle when removing the uterus for fibroids. The result was dismal failure. Matters improved somewhat after Kœberlé introduced the serre-nœud, and this continued the safest method until 1892. In the meantime antisepsis had begun to take effect in pelvic surgery, and attempts were made by Bardenheuer (1881), Polk, and other surgeons to avoid the dangerous difficulties connected with the treatment of the stump by removing the cervix as well as the uterus (total hysterectomy), and they attained an encouraging measure of success. Nevertheless, other surgeons (Goffe, Milton, Heywood Smith, and Stimson) felt that the enucleation of the cervix was not always necessary, and sought to find a way of avoiding it. The credit of solving this difficulty fell to Baer, of Philadelphia (1892), for he showed that it is dangerous to constrict the neck of the uterus with ligatures, it is only necessary to secure the arteries.

Baer's method of supravaginal hysterectomy, or, as it is now commonly termed, the subtotal operation, soon supplanted the total method of Bardenheuer. The publication of Baer's paper had great consequences; it came at a time when the attention of gynæcologists was centred on improvements in hysterectomy. The method was promptly tested and adopted in London. The effects of this improvement in technique in a few years revolutionized the surgical treatment of uterine fibroids, as the statistical results set forth on p. 128 amply prove.

The great advantage of Baer's method is its simplicity and safety; but there is a disposition on the part of a few surgeons to prefer the total operation, mainly on the ground that the cervical stump left after subtotal hysterectomy is liable to become attacked by cancer.

As far as I can ascertain, Dr. M. Mann, of Buffalo, was the first to draw attention to the occurrence of cancer in the neck of the uterus after the body of the organ had been removed. He stated in 1893 that he 'removed an ovarian tumour and the body of the uterus, by accident, along with it; the cervix was left.' The patient recovered. 'Six months afterwards cancer developed in the cervix, from which she died.'

When cases of cancer supposed to arise in the stump left after subtotal hysterectomy come to be critically analysed, they fall into four groups:

1. The disease existed in the neck of the uterus at the time of the primary operation, but was overlooked.

2. Cancer attacked the cervical stump subsequent to subtotal hysterectomy.

3. The fibroid which necessitated the hysterectomy was really a sarcomatous tumour of the uterus.

4. The suspected growth on the cervix is not malignant, but a granuloma.

Each of these postulates requires separate consideration.

Many observations have been published which show beyond dispute that surgeons have performed subtotal hysterectomy in ignorance that the cervix was already cancerous, and the hæmorrhages of which the patients complained before the operation were due as much to the cancer in the neck of the uterus as to the fibroids. This should serve as a warning that, in cases where the surgeon contemplates performing a subtotal hysterectomy, he should carefully examine the cervix beforehand; at the time of the operation he should also critically examine the cut surface of the cervix, and if it be in the least suspicious he should remove the neck of the uterus. It is necessary to remember that cancer attacks any part of the cervical endometrium, therefore an early cancerous ulcer in the middle of the cervix will run a great chance of being missed by a surgeon who is content with a subtotal hysterectomy.

It is certain that cancer does occasionally attack a cervical stump left after subtotal hysterectomy at such an interval after the operation as to make it certain that the cancer did not exist at the time of the operation. Such a case occurred in my practice. I performed subtotal hysterectomy in 1901 on a woman forty-two years of age, mother of one child; eighteen months later there was a cancerous ulcer on the cervix; the whole of the cervical stump was promptly removed and the nature of the disease established microscopically. In 1908 the patient was in excellent health.

In another case under my care I performed total hysterectomy for fibroids in ignorance that the patient had cancer of the cervix. Some months after the operation cancer recurred in the vaginal vault and scar of the hysterectomy; the neck of the uterus had been preserved by the doctor, and on examination the cancer was found. In this instance, although total hysterectomy was performed, it had no effect in staying the course of the disease.

It is necessary to utter a caution in regard to the occurrence of cancer of the cervix after subtotal hysterectomy. I removed a uterus containing

a large globular submucous fibroid from a barren married woman forty-five years of age. Six years later she came under my observation with a large granulating and bleeding growth on the cervix uteri. I had no doubt from the naked-eye characters that this was a primary carcinoma, although it surprised me to find it there, especially as the woman had never been pregnant. On my urgent representations she allowed me to remove the cervix. On microscopic examination the suspected cancer turned out to be a granuloma. Two years later the patient was in good health. Polk has recorded a similar experience. These facts show that caution is necessary in accepting reports of cancer of the uterine stump after subtotal hysterectomy.

Surgeons who have had extensive experience of subtotal hysterectomy for fibroids are unanimous that there is no special liability of the cervical stump left after this operation to become cancerous.

Cancer of the body of the uterus and fibroids. In deciding between total and subtotal hysterectomy for fibroids the probable presence of cancer requires consideration in another aspect. Although uterine fibroids do not predispose to cancer of the neck of the uterus, many writers in recent years have expressed their suspicions that the presence of a submucous fibroid favours the development of cancer in the corporeal endometrium. Piquand, in 1905, drew attention to this matter and emphasized what other observers had pointed out, namely, that a submucous fibroid is often associated with changes in the mucous membrane of the uterus, which not only causes excessive bleeding, but sets up inflammatory conditions giving rise to leucorrhœa, salpingitis, pyosalpinx, and morbid changes in the endometrium, rendering it susceptible to cancer. His statistics support his conclusions, for they represent that in one thousand women with fibroids fifteen will probably have cancer of the body of the uterus. My own observations support this opinion. This complication is found most frequently between the fiftieth and the sixtieth year of life. If we narrow the ages of the patient and exhibit the liability in its most emphatic form it would run thus: that in patients submitted to hysterectomy for fibroids over the age of fifty years, about 10 per cent. of them will have cancer of the corporeal endometrium.

In 1906 I looked through the case-notes of five hundred patients who had been submitted to operation for uterine fibroids under my care. Of these sixty-three patients had attained the age of fifty years and upwards. Among these sixty-three women there were eight cases of cancer of the corporeal endometrium; the nature of the disease in each case was verified by careful microscopic examination.

The statistics on which this statement is founded were published in

1906; since that date, I have made a careful study of uteri with this sinister combination which have occurred in my practice; these new observations support the conclusion expressed in the preceding paragraph. The following case may be mentioned: A spinster, aged sixty, came under my care with her uterus so enlarged by a submucous fibroid that its fundus reached high above the navel. The existence of the fibroid had been detected by Sir Spencer Wells when the patient was 30 years of age. She complained to me of irregular issues of blood and the increasing size of the tumour. On examining the uterus after its removal, cancer of the endometrium was found in addition to a large fibroid. The patient survived the operation fifteen months.

Consequently, in performing subtotal hysterectomy for fibroids in women of fifty years and upwards, the surgeon should have the uterus opened immediately after its removal and assure himself that the endometrium is free from cancer. If there be any suspicion in this direction he should remove the cervix.

From a careful study of the question, I have formed the opinion that if a woman with fibroids and concomitant cancer of the neck of the uterus seeks advice on account of hæmorrhage, and the cancer has attacked the vaginal portion of the cervix, the nature of the case will be appreciated. The cases likely to be overlooked are those where the cancer is situated somewhat higher in the cervical canal than usual, so that it is not easily detected by the examining finger, and so low in the cervix that the disease is not exposed when the body of the uterus is amputated in the course of a subtotal hysterectomy. A knowledge of this, as well as the fact that cancer of the cervix is almost exclusively a disease of women who had been pregnant, should make the surgeon particularly careful in performing subtotal hysterectomy for fibroids in women who have had children, in order to assure himself that it is not cancerous.

Sarcoma. The most insidious danger which besets the surgeon in dealing with fibroids of the uterus is the occurrence of an encapsuled sarcoma in the guise of an innocent fibroid. I have for some years dropped the name of myoma for these common uterine tumours, preferring to apply the term fibroid in a generic sense to all encapsuled tumours of the uterus. Every histological condition is found in them, from the hard calcified body looking like a block of coral to a soft diffluent collection of œdematous connective tissue, and tumours composed of tissue indistinguishable from that of a spindle-celled sarcoma.

I removed the uterus from a woman forty years of age, which contained a fibroid as big as an ostrich's egg. On section it appeared to be a moderately firm fibroid, with its tissue whorled as is usual in hard fibroids and enclosed in a complete capsule. Some months later the patient

complained of pain, and on examination a hard mass occupied the floor of the pelvis; a portion of this was excised and submitted to three competent histologists, who reported the growth to be an innocent fibroid. The patient died fourteen months after the primary operation with her pelvis filled with recurrent growth. The tumour was a spindle-celled sarcoma.

Sarcoma of the uterine wall—and this is the variety most likely to be mistaken for a fibroid—is commonest after the age of forty and by no means infrequent after the menopause: a solid tumour arising in the uterus after the fiftieth year and growing quickly, is sure to excite suspicion especially if accompanied by hydroperitoneum. There are few complete records of uterine sarcoma, complete in the sense of furnishing an account of the minute structure of the tumour and the subsequent history of the patient. No uterine operation is attended with so little success as hysterectomy for sarcoma.

Cancer of the uterus after bilateral ovariotomy. The uterus, after complete removal of both ovaries, is not only a useless organ, but it may become attacked by cancer. Blacker reported a case in which a woman, thirty-nine years of age, underwent bilateral oöphorectomy for a uterine fibroid: eight years later cancer attacked the neck of the uterus and destroyed the patient.

In 1902 I performed abdominal myomectomy on a woman forty-seven years of age, and removed both ovaries and uterine tubes; the latter contained pus. Four years later this patient came under observation with extensive cancer of the cervix.

In 1901 a patient had bilateral ovariotomy performed; five years later she complained of severe uterine hæmorrhage. I removed the uterus by the abdominal route (total hysterectomy). The corporeal endometrium was cancerous throughout. The patient survived the operation six months. Similar cases have been recorded by Martin, Butler-Smythe, Playfair, and Munro-Kerr.

References

Blacker, G. F. *Transactions of the Obstetrical Society,* 1896, xxxvii. 213.
Butler-Smythe. *Ibid.,* 1901, xliii. 214.
Martin, A. *Die Krankheiten der Eierstöcke,* 1899, S. 907.
Munro-Kerr. *Lancet,* 1911, i. 95.
Playfair. *Transactions of the Obstetrical Society,* 1897, xxxix. 288.

Adenomyoma of the uterus. This disease has not received adequate recognition at the hands of British surgeons, yet it is a condition which occasionally causes much doubt in the surgeon's mind in the course of hysterectomy. This adenomyomatous change affects the endometrium and is, in some cases, associated with interstitial and subserous fibroids:

it causes often great enlargement of the uterus, and under these conditions the fundus can be felt high in the hypogastrium. The patients are often profoundly anæmic as the result of long-continued menorrhagia. The physical and clinical signs of the disease are those present in patients with a large degenerating submucous fibroid. Indeed, the surgeon often removes the uterus under this impression, and, after the operation is completed, when he divides the uterus expecting to see the

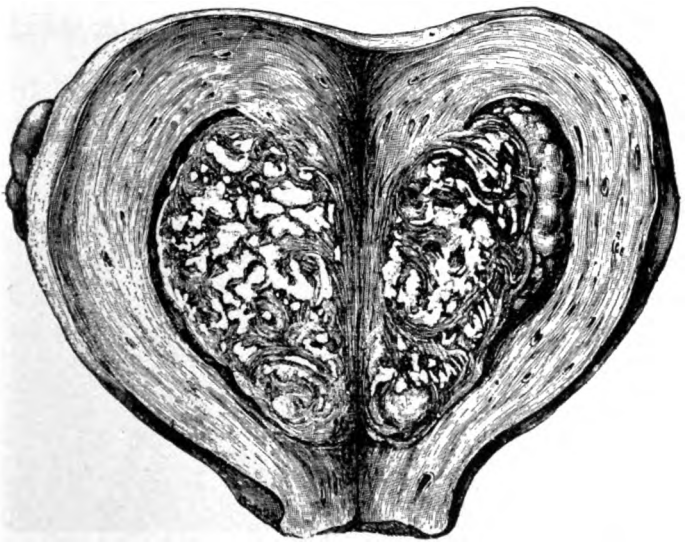

FIG. 58. AN ADENOMYOMATOUS AND TUBERCULOUS UTERUS. The uterus is opened by a vertical incision in its posterior wall. The anterior wall is occupied by a mass of tuberculous adenomyomatous tissue. The patient, a spinster aged 46, was in excellent health four years after the operation. Two-thirds size.

usual encapsulated tumour, to his surprise finds a uterus with greatly thickened walls.

Microscopically the adventitious tissue is made up of irregular tracts of endometrium containing glands and strands of unstriped muscle tissue. This overgrowth is probably due to the action of micro-organisms. Adenomyomatous uteri are often associated with inflammatory affections of the uterine tubes such as chronic pyosalpinx and hydrosalpinx. Occasionally the adventitious gland-mass is tuberculous (Fig. 58).

Sometimes the adenomyomatous change is so localised that it causes a prominence on the serous surface of the uterus and so resembles a sessile subserous fibroid. The distinction is only possible with the aid of a microscope. The collection of adenomyomatous tissue (Fig. 59) looked so like a simple fibroid that it would not have been examined

microscopically except for the fact that it had implicated the wall of the rectum. This was the first example I had seen in which an adenomyoma of the uterus had displayed invasiveness which is such a common feature of cancer. It is important to emphasize this aspect of the disease because some examples have been described as cancer of the uterus. The importance of surgeons being aware of this is illustrated by a remarkable case recorded by Cuthbert Lockyer:

A woman, aged 35, had a hard mass in the posterior vaginal fornix, fixed to the supravaginal portion of the neck of the uterus and adherent

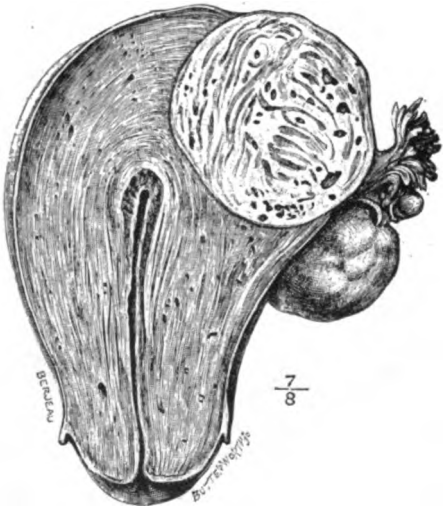

FIG. 59. UTERUS IN SAGITTAL SECTION. Showing a localised patch of adenomyoma resembling a subserous fibroid: it had invaded the rectum. From a primipara aged 35.

to the pelvic floor. No definite diagnosis appeared to be possible, and, as the poor woman's health was seriously impaired, total hysterectomy was performed. In the course of the operation the neck of the uterus and the rectum were found so firmly fused together, that the implicated section of the rectum was removed with the uterus, and the proximal end of the divided bowel secured to an opening made in the left flank (inguinal colotomy).

When the excised parts were examined, the new growth, which implicated the uterus and the rectum, displayed the microscopic structure of adenomyoma. The pathological features of this rare condition are made easily intelligible by Lockyer's excellent illustrations. It is startling to find adenomyomatous changes involving the supravaginal segment of the uterus and extending into the pelvic connective tissue like

malignant disease. The specimen represented in Fig. 60 shows also that the disease may perforate the serous covering and invade adjacent organs. This is a feature of this interesting disease as yet imperfectly appreciated by surgeons.

In adenomyoma of the uterus, subtotal hysterectomy gives admirable results; even in cases in which the disease is complicated with tubercle the patients make excellent recoveries, immediate and remote. It is also worthy of note that no instance is recorded in which hysterectomy for this disease has been followed by recurrence. It is probable that in

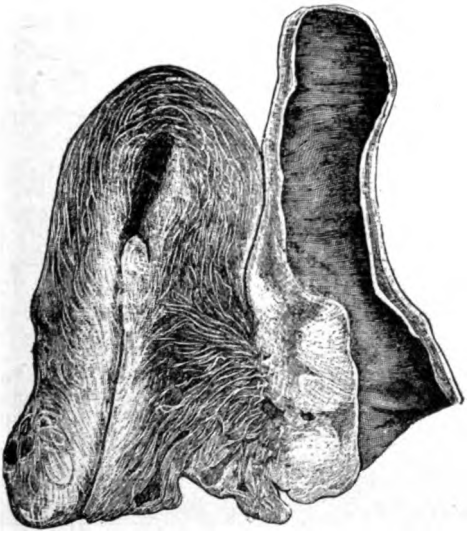

FIG. 60. UTERUS AND ADJACENT SEGMENT OF THE RECTUM IN SAGITTAL SECTION. The cervix is the seat of adenomyomatous disease which spread to and invaded the wall of the rectum. The clinical appearances were so like cancer that the uterus and rectum were excised. (*After Cuthbert Lockyer.*)

many cases in which the uterus has been removed for so-called adeno-carcinoma of the body of the uterus and the patients remained free from recurrence, the disease was really adenomyoma of the corporeal endometrium.

REFERENCES IN RELATION TO ADENOMYOMA OF THE UTERUS

BLAND-SUTTON, J. Fibroids of the Uterus, 1913, p. 98.

—— On a case of Adenomyoma of the Uterus involving the Rectum. *British Journal of Obstet. and Gyn.*, 1913, xxiii. 402.

LOCKYER, C. Adenomyoma in the Recto-uterine and Recto-vaginal Septa. *Proc. Roy. Soc. of Med.*, 1913, vi, *Obstetrical Section*, 112.

SCHARLIEB, M. Note on a case of pregnancy in a woman aged 51. *Journ. of Obstet. and Gyn. of the Brit. Empire*, 1903, iii. 348.

THE FATE AND VALUE OF BELATED OVARIES

The only improvement of any importance made in Baer's operation of subtotal hysterectomy concerns the ovaries. These Baer removed with the uterine tubes, but in 1897 I advocated, at the Obstetrical Society, London, that they were of great value to the patient, and pointed out that their conservation, when healthy, spared the patient the annoyance of that curious vaso-motor phenomenon, known to women as 'flushings,' which is the only obtrusive sign of the menopause.

It is now admitted by those surgeons in London who have had much experience of hysterectomy for fibroids, that the immediate results of preserving at least one healthy ovary in this operation are admirable, especially in women under forty years of age, for the retention of an ovary is of striking value 'in warding off the severity of an artificial menopause' (Crewdson Thomas).

Although I have left one or both ovaries in the performance of abdominal hysterectomy for fibroids in more than 300 patients, in only two instances have I found anything detrimental in the practice. In these two patients it was necessary to remove one of the ovaries. Since 1906 I have modified the method by leaving only one ovary, even when both were healthy, and find that the immediate good consequences of the operation are in no way impaired. There is reason to believe that whatever good effects follow the practice of leaving a belated ovary (that is, an ovary divorced from the uterus and left in the pelvis), they are temporary, for in the course of a few years the ovarian tissue disappears and the patients experience the usual symptoms of the menopause. It is possible that the rate of atrophy of the secreting tissue of a belated ovary depends on the age at which a patient is submitted to hysterectomy.

In 1898 I performed subtotal hysterectomy on a woman, thirty-one years of age, for fibroids, conserving the right ovary. Nine years later (1907) I operated again for intestinal obstruction, and found this ovary healthy and functional, for a ripe corpus luteum was visible on its surface. Even a portion of an ovary, if it contain follicles, will maintain menstruation.

In performing abdominal hysterectomy for fibroids, there are three points which require consideration in relation to the subsequent comfort of the patient, and they depend mainly on the conservation of a healthy ovary. These three points relate to: (*a*) the patient's comfort in securing freedom from flushings; (*b*) if she be married, her marital relations; and (*c*) if single, her nubility.

In regard to marital relations in women with a belated ovary, nothing trustworthy is forthcoming, but I believe the retention of an ovary is an additional factor in promoting domestic bliss. The question of nubility is interesting; I am able to state that women who have had subtotal

hysterectomy performed, with conservation of one ovary, have married and lived happily with their husbands; and I am of opinion that the preservation of the vaginal segment of the neck of the uterus is an important factor, as it leaves the vagina intact, and though such women are sterile, they are certainly nubile.

Without overstating the case, it may be said that a belated ovary is a very precious possession to a woman under forty years of age, whether she be married or single.

In regard to the fate of such ovaries, in the present condition of our knowledge it may be stated that:—

In a woman under the fortieth year of life, a belated ovary remains active and discharges ova.

An ovary belated after the fortieth year of life atrophies, and menopause symptoms will often ensue in the course of a few months after the operation. The retention of an ovary minimizes the menopause disturbances, and they are never so acute and prominent under these conditions as they are when an acute menopause is induced by the sudden and complete removal of all ovarian tissue. Some experienced observers maintain that an ovary is a valuable possession to any woman who menstruates, even at the age of fifty years, the persistence of menstruation being obtrusive evidence that this gland is functional. Experimental evidence, obtained from rabbits, proves that the removal of the whole uterus has no deterrent effect on ovulation, and it does not prevent the occurrence of œstrus and ovulation at periodically recurring intervals. There is no necessity to appeal to experiments on animals in this matter, as clinical observations on women are most eloquent in proclaiming the great value of a conserved ovary when the uterus is removed on account of troublesome and dangerous fibroids.

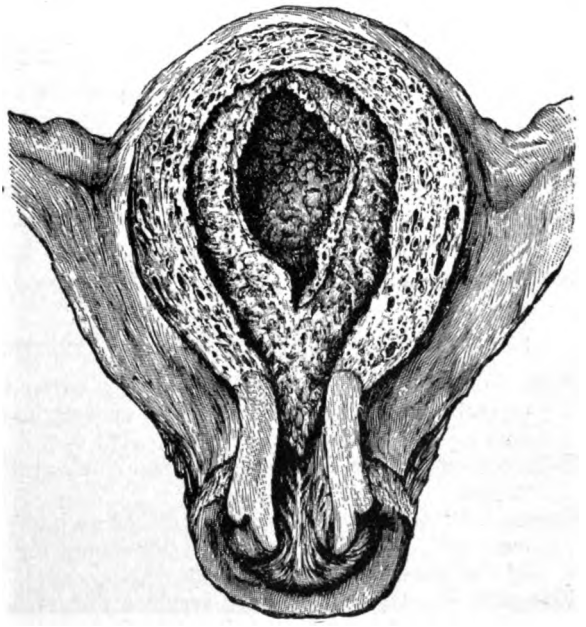

FIG. 61. UTERUS WITH THE DECIDUA IN SITU. The parts of the uterus occupied by the decidua represent the menstrual area of the uterus.

In reference to the value of ovarian tissue after hysterectomy for fibroids, attention should be drawn to a modification of this operation known as the Abel-Zweifel method, by which a small segment of the menstrual area of the uterus is left as well as one or both ovaries: this permits menstruation to continue in a subdued form.

Doran has particularly studied this method and practised it, but I cannot express any opinion as to its value, never having had the courage to perform it.

My aim in performing hysterectomy for fibroids is to abolish as completely as possible the menstrual area of the uterus (Fig. 61), and up to the present my efforts have been successful, and I have no complaint from any patient that this disagreeable phenomenon has manifested itself, although I have been at great pains by my own exertions, as well as by the kind efforts of those who have been associated with me in my hospital work, to keep in touch with women who have been so unlucky as to require such a serious operation as the removal of the uterus.

References to the History of Hysterectomy for Fibroids

Baer, B. F. Supravaginal Hysterectomy without Ligature of the Cervix in Operation for Uterine Fibroids. A new method. *Transactions of the American Gynecological Society*, 1892, xvii. 235.

Bardenheuer. Die Peritonealdrainage. *Centralblatt für Gynäkologie*, 1881, v. 515.

Goffe, I. Riddle. This surgeon furnishes an interesting account of the development of Total and Subtotal Hysterectomy for Fibroids, in the *Transactions of the American Gynecological Society*, 1893, xviii. 79.

Kœberlé, E. Documents pour servir à l'histoire de l'extirpation des tumeurs fibreuses de la matrice par la méthode suspubienne. *Gaz. méd. de Strasbourg*, 1864, xxiv. 17; 66; 158. 1865, xxv. 78; 118.

Pozzi, S. *Traité de Gynécologie*, 1905, i. 424. This contains an interesting review of the serre-nœud and clamp period of hysterectomy. He states that Tillaux, in a communication to the Academy in 1879, proposed the use of the word Hysterectomy.

References concerning the Value of Belated Ovaries

Bland-Sutton, J. Abdominal Hysterectomy for Myoma of the Uterus, with brief notes of twenty-eight cases. *Transactions of the Obstetrical Society*, 1897, xxxix. 292.

—— The Value and Fate of Belated Ovaries. *Medical Press and Circular*, 1907, ii. 108.

Bond. An Inquiry into some Points in Uterine and Ovarian Physiology and Pathology in Rabbits. *British Medical Journal*, 1906, ii. 121.

Doran, A. Subtotal Hysterectomy: after-history of sixty cases. *Transactions of the Obstetrical Society*, 1905, xlvii. 363.

Thomas, G. C. The after-histories of one hundred cases of Supravaginal Hysterectomy for Fibroids. *Lancet*, 1902, i. 249.

SECTION VI

OPERATIONS FOR MALIGNANT DISEASE OF THE UTERUS AND CERVIX

BY

VICTOR BONNEY, M.S. (Lond.), F.R.C.S. (Eng.)
Assistant Gynæcological Surgeon, Middlesex Hospital;
Surgeon, Chelsea Hospital for Women

CHAPTER I

OPERATIONS FOR CARCINOMA OF THE CERVIX UTERI

THE surgical extirpation of carcinoma of the cervix may be attempted either by the abdominal or vaginal route, or by both routes combined.

Before describing the technique of these operations it will be pertinent briefly to outline the pathological and anatomical facts that determine the principles of their performance.

Carcinoma of the cervix is of the squamous-cell variety in 98% of the cases, and is preceded in all of them by chronic cervicitis and cervical erosion.

In the remaining 2% the growth is of the columnar-cell glandular variety, and originates in the racemose cervical glands.

As in all varieties of carcinoma, that of the cervix spreads by two processes—(1) infiltration, and (2) permeation.

Infiltration is going on around the whole periphery of the growth. It consists in a slow absorption and replacement of the normal tissues of the part by the carcinoma cells.

Permeation is a much more rapid process. It consists of entrance into and progression along trunk lymph-channels by the carcinoma cells, and it only occurs along certain definite tracts.

The vexed question of vascular dissemination of carcinoma need not be considered when dealing with growth arising in the cervix, since, like the squamous-cell variety occurring elsewhere, metastases possibly arising by this method of conveyance are extremely rare.

Growth by infiltration takes place downwards into the vagina, forwards into the bladder, backwards towards the rectum and the peritoneum of Douglas's pouch, and laterally into the paracervical tissue.

Lymphatic permeation takes place chiefly along two tracts. The first of these, the commoner and the more important, is laterally into the tissue immediately underlying the ureter and forming the base of the broad ligament. The lymph-vessels, in their course through this tissue, pass through several aberrant lymph glands, and finally reach the wall of the pelvis. Here they communicate with a group of lymph glands lying in the obturator fossa, and from thence mount the pelvic side wall to join the external iliac glands lying on the inner side of the external iliac vein, and between the hypogastric and the external iliac

arteries. From thence the tract continues upwards through the common iliac glands to the aortic glands.

The second tract proceeds backwards by way of the utero-sacral ligaments, and passes out of the pelvis in the interval between the psoas muscle and the last lumbar vertebra to reach the aortic glands, and join with the first tract.

In order, therefore, to fulfil the modern tenets governing the surgery of malignant disease, it is necessary so to plan the excision that while the line of section at all points lies well outside the area of growth by infiltration, it shall be extended in certain directions so as to ablate the areas of growth by lymphatic permeation.

From the point of view of operative removal the cervix is in fact a favourable site for carcinoma, for it has been shown by Archibald Leitch that of persons dying of the disease, only 45% exhibit metastatic growths on autopsy, and in the larger proportion of these the secondaries are limited to glandular deposits.

These findings agree with the results of operative experience. In a series of over one hundred and fifty cases of radical abdominal extirpation performed by the writer of this article and Comyns Berkeley, only fifty-six (37%) exhibited carcinoma of the regional glands.

The comparative rarity with which secondary growths are present in carcinoma of the cervix is in striking contrast to carcinoma of the breast, in which disease only 6.5% of those dying of it are found to be free of metastases.

It is from the anatomical standpoint that the aspect of carcinoma of the cervix is seen to be a grave one, for on account of the proximity of the cervix to the bladder, ureters, great vessels, and rectum, radical extirpation of a growth in this situation is a very formidable operation.

It is further to be noted that while the difficulties increase with the advancement of the growth, and the stamina of the patient diminishes, the necessity for an extensive radical procedure becomes more imperative. Thence arises the considerable primary mortality rate which attends the operation when applied to advanced cases.

RADICAL EXTIRPATION BY THE ABDOMINAL ROUTE (WERTHEIM'S OPERATION)

The modern radical operation by the abdominal route consists in the removal of the uterus and appendages and an amount of healthy vagina sufficient when clamped to form a bag which encapsules the diseased cervix. Together with these parts the para-metric and para-vaginal cellular tissue is removed with as many of the regional glands as may be feasible.

The glands commonly first affected are those lying in the obturator fossa and along the external and common iliac vessels.

To thus widely remove the diseased area it is absolutely necessary to isolate and displace the ureters.

TECHNIQUE OF THE OPERATION

Previous preparation of the patient. As a large number of the patients are extremely enfeebled it is important to endeavour beforehand to improve their general condition. This should be attempted by keeping them in bed for a week or more before the operation, during which time they should be fed up and tonics (especially strychnine) and a little wine given.

They should be given a couple of warm baths a day, special attention being directed to cleansing the external genitals.

If the discharge from the cervical growth is very foul, it may be advisable first to erase it thoroughly by means of the curette and cautery, but if this practice is followed, several weeks should be allowed to elapse between the preliminary operation and the major procedure, for it takes this time for the sloughs caused by the cautery to separate and the surface to become clean.

If it is not deemed advisable to wait so long, then the preliminary cauterization should immediately precede the extirpation.

Scraping and cauterization have, however, this disadvantage, that they may so thin the cervical tissues that the latter readily tear during removal.

For this reason it is better in cases without foul discharge to dispense with such measures and to rely on the application of strong antiseptics to the vagina and cervix immediately before the operation.

Where the growth is large and fungating it should be cut away with scissors, otherwise its bulk will necessitate a very large amount of the vagina being removed in order completely to surround it.

Position of the patient for the operation. The Trendelenburg position is required, but an extreme tilt should be avoided, or at all events maintained for as short a time as possible. There can be no doubt that where shock is marked the lowering of the patient from an extremely tilted position to the horizontal is followed by an immediate diminution in the force of the pulse.

The anæsthetic. A good anæsthetist is of the greatest importance, because the fullest relaxation of the abdominal wall is desirable. On the whole, chloroform is the best anæsthetic because it tends to minimize the bleeding during the operation, which is undoubtedly the most important cause of the post-operative shock. On the Continent spinal anæsthesia is

extensively used. Its drawback is that the Trendelenburg tilt is incompatible with it, that the anæsthesia may not last long enough to enable the operator to complete the operation without recourse to chloroform or ether, and that to nervous patients consciousness is a severe mental trial.

Preparation of the vagina. Immediately after the patient has been anæsthetized, the vagina should be thoroughly washed out with soap and water and then irrigated with a solution of 1 in 500 biniodide of mercury in water.

All excess of this having been mopped out, the canal should be packed with gauze soaked in 5% nitrate of silver solution. The end of the gauze hanging out of the vagina should be left long for convenience of subsequent removal.

(See also remarks on cauterization, p. 151.)

The abdominal incision. This should be of ample length. In all cases it should extend to the umbilicus and in obese patients an inch or more above it.

Preparation of the wound edges. It is most important to guard against infection of the edges of the abdominal wound both by cancer cells and by organisms present in the vagina. The first of these objects is achieved by the encapsulization of the growth in the manner presently to be described. The second event, however, is more difficult of prevention, because the vaginal surface is brought into continuity with the operation area directly the uterus has been removed.

Transference of organisms present in the vagina (and derived from the growth) is avoided, firstly, by the thorough cleansing of that canal which has already been described as a preliminary step. In spite, however, of the most painstaking care, absolute sterilization of the vaginal surface is impossible and it is, therefore, most advisable to cover the edges of the abdominal wound with some impervious substance such as thin sheet rubber. This is folded over the wound edges and held in place by a self-retaining retractor, the best of which for the purpose is Berkeley's. Not only does this device save the abdominal wound from the possibility of infection from the cervix but it also excludes the abdominal skin from the operation area.

Exposure of the pelvic cavity. The Trendelenburg tilt coupled with wide opening out of the abdominal wound by a self-retaining retractor suffices in thin patients to give a good view of the pelvic cavity.

In stout patients, however, the intestines obscure the operator's view. In such cases they may be dammed back by the insertion of a large abdominal swab. This method has, however, the disadvantage of thrusting the mass of intestines against the diaphragm, and by hindering the patient's respiration making the anæsthetist's task much more difficult.

An alternative, which I have lately adopted in very stout patients, is to eventrate the intestines and wrap them up in a towel moistened with warm saline solution. Though at first sight this proceeding would appear likely to be productive of shock, it does not in practice have any such effect, while it certainly makes the operator's task much easier.

Investigation of the conditions. The degree of advancement of the growth should now be investigated by handling the parts. Involvement of the bladder is indicated by a puckered indrawing of the peritoneum at the bottom of the utero-vesical pouch. The glands along the iliac vessels and aorta should be palpated.

In most advanced cases it will be found that bilateral salpingitis is present, often with many dense adhesions. The tubes or ovaries may have suppurated. Pyometra is another common accompaniment. The uterus when thus affected is enlarged and soft, and there is dilatation of the capillary vessels over its surface.

The operator will now be in a much improved position to decide whether the extirpation is feasible or not; and if the latter, then the abdominal wound should be immediately closed.

In some cases, however, he will still be in doubt, and he should then proceed to find out if the bladder is separable; for if this is the case, the operation should be able to be completed. On the other hand, dense adhesion, which will necessitate excision of part of the bladder, as a rule contra-indicates any further measures.

Division of the broad ligaments. Ligatures are now placed upon the ovario-pelvic and round ligaments of either side as far out as possible, and a pressure forceps having been temporarily placed on the ovarian vessels as they enter the uterus, the broad ligaments are divided immediately inside the ligatures, and the incisions on either side are continued forwards through the peritoneum to meet in front of the uterus. To do this the peritoneum covering the front of the cervix should be separated first by the finger, and the division should be made at the upper limit of the loose attachment so as to ensure a maximum size of the anterior peritoneal flap.

The two appendages are thus freed except at their uterine attachments. The forceps holding the ovarian vessels on either side should now be replaced by ligatures tied round the whole remaining attachments. The ends of these ligatures should be left long to act as tractors for the uterus.

Beginning the separation of the bladder. The separation of the bladder from the supravaginal cervix should now be begun.

This is a most important step, for on its possibility the indication for proceeding with the operation rests.

Where there is no morbid adhesion the separation is easily effected

by a few snips with the scissors and pressure from a gauze swab, but where it is otherwise very careful dissection is required lest the bladder be opened.

When it is obvious that the separation can be effected, the operator should for the present desist, because complete separation entails a good deal of oozing which is better left till a later stage.

Identification of the ureter. The ureter is now sought for on one

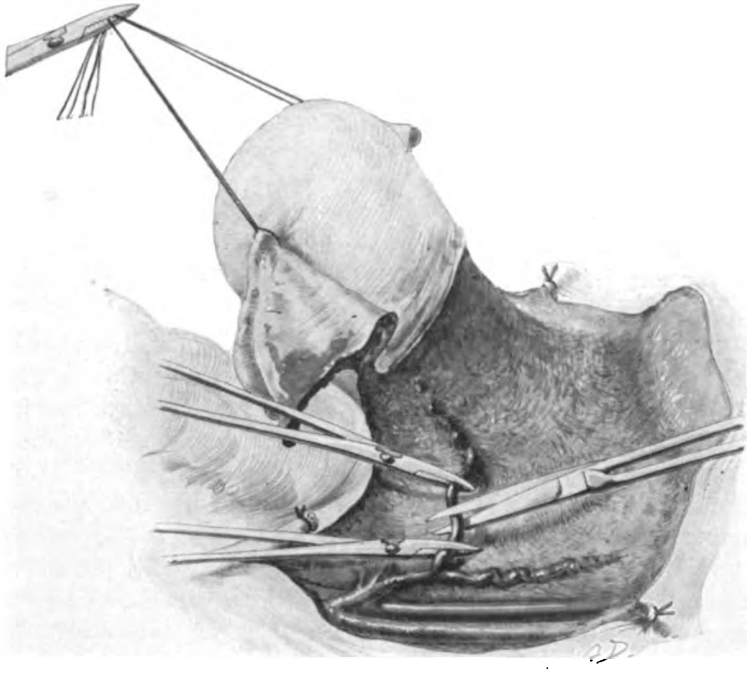

FIG. 62. RADICAL EXTIRPATION OF THE UTERUS BY THE ABDOMINAL ROUTE. *Division of the uterine artery.* (Semi-diagrammatic.)

side as it runs downwards clinging to the peritoneum covering the back of the broad ligament and the pelvic side wall.

It may be clearly seen by pushing the peritoneum in towards the median plane, a proceeding that is made easier by dividing this membrane for about an inch upwards outside the ligature previously placed on the ovario-pelvic ligament.

In stout patients it may be difficult to see, in which case it should be felt for by the finger and thumb, feeling like a cord the size of a goose quill, which slips under the finger.

If it cannot even thus be detected the operator should proceed to the next step of the operation.

Ligature of the uterine artery. The uterine artery should be sought for, as it runs from the pelvic side wall to the side of the uterus. This is done by gently separating the loose cellular tissue of the base of the broad ligament until the vessel is seen.

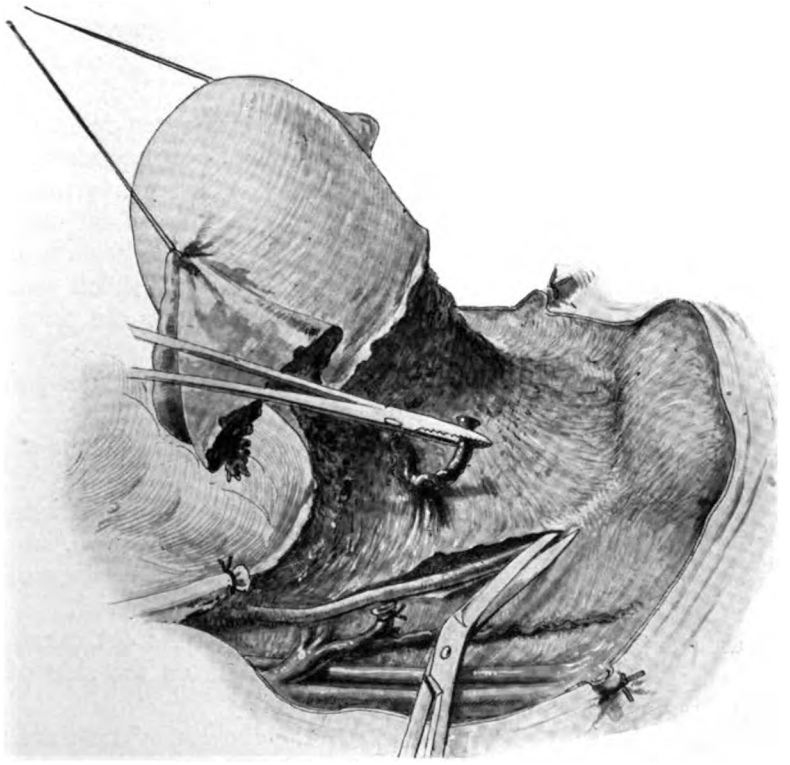

FIG. 63. RADICAL EXTIRPATION OF THE UTERUS BY THE ABDOMINAL ROUTE. *Opening up the ureteric canal.* (Semi-diagrammatic.)

It is here to be remembered that this artery usually comes off from the hypogastric artery as a common trunk with the umbilical artery, leaving which it runs inwards at right angles to the side of the uterus, crossing the ureter in its path.

Occasionally, however, it arises direct from the hypogastric artery, in which case it takes an oblique course to the uterus, almost parallel to the ureter, but above it, and lying on the same sheet of peritoneum.

The artery having been found, it should be divided between two pairs of pressure forceps, as far outward as possible. The proximal end

should then be immediately ligatured. By means of the forceps holding the distal end the artery inside of this should be separated backwards towards the uterus, when the ureter will be disclosed as it passes underneath it (Fig. 62).

This is an excellent method of finding the ureter in difficult cases. The distal end should now be ligatured.

The uterine vein is often included in the forceps that seize the artery. In other cases it requires separate treatment in the same way.

Not infrequently it passes under the ureter instead of over it like the artery.

Isolation of the ureter. The ureter is now separated from its bed at a point slightly above where it passes under the uterine artery.

In its further course downwards it will now be seen to pass into a mass of tissue connecting the cervix with the sides of the bladder. Through this it travels in the 'ureteral canal,' a space through which it is easy to insinuate the finger in simple cases, but which scarcely exists where the para-cervical and para-vaginal tissues are thickened either by cancerous infiltration or chronic cellulitis.

The ureteral canal is best opened by means of angular probe-pointed scissors passed along it in the line of the ureter (Fig. 63).

Several small vessels crossing from the bladder to the cervix will be divided in this proceeding.

The ureter having thus been laid bare up to its entrance into the bladder, should be lifted out of its bed by gentle dissection, until it is quite free. Several large veins are usually opened in the floor of the 'ureteral canal' while effecting this, and these must be secured.

The difficulty of isolating the ureter varies in different cases. In advanced cases it most commonly lies in a groove on the side of the growth from which it will have to be displaced.

Less frequently it actually runs through the growth. These are very bad cases, and the operator may decide to abandon further attempts to remove the growth, but if it appears feasible on other counts to proceed with the operation, the whole mass of infiltrated tissue should be resected together with the involved segment of the ureter, and the upper end of this structure subsequently implanted into the bladder.

Treatment of the uterine artery and ureter of the opposite side. Both uterine arteries may be secured before either ureter is isolated, or one side may be completed before the other is touched.

Separation of the rectum. The uterus having been drawn forwards, the peritoneum at the bottom of Douglas's pouch is picked up with forceps and divided with the scissors. The finger then seeks for the cleavage plane that separates the vaginal and rectal walls, and when this is found,

the two canals are parted from one another for the distance the surgeon thinks proper. There should be little or no bleeding during this step if the right plane is arrived at, and if no morbid adhesion exists (Fig. 64).

Completion of the separation of the bladder. The separation of the bladder is now completed. The extent to which this is desirable varies in different cases, but it should certainly be not less than one and a quarter inches below the lowest level of the growth.

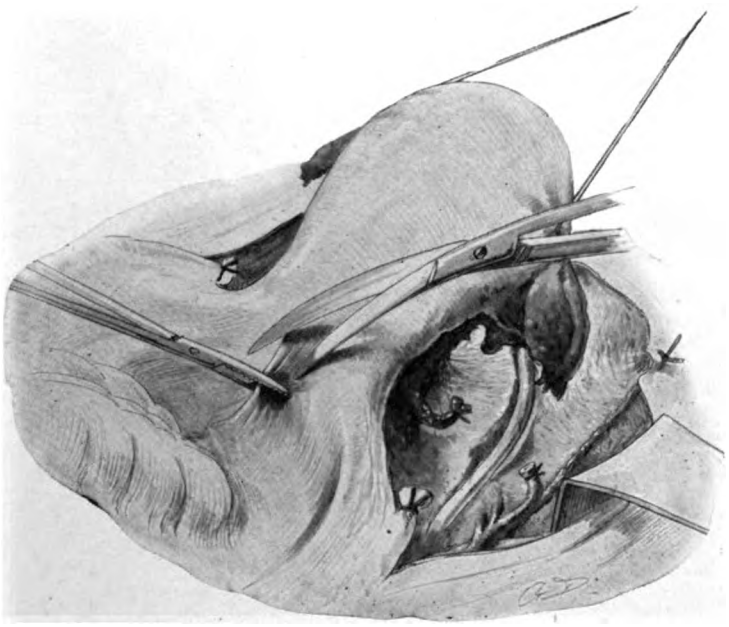

FIG. 64. RADICAL EXTIRPATION BY THE ABDOMINAL ROUTE. *First step in the separation of the rectum from the vagina.* (Semi-diagrammatic.)

It is effected by cautious snipping with scissors, and gentle pushing down by swab and finger pressure. There is often considerable oozing, especially from the more lateral aspects of the anterior vaginal wall.

The insertion of a broad retractor to hold back the bladder above the line of separation is very useful.

Division of the utero-sacral ligaments. When the bladder has been separated the uterus is once more held forwards and the peritoneum that intervenes between the opened broad ligaments and the aperture in the bottom of Douglas's pouch is divided on either side, the tissue of the utero-sacral ligaments not being included.

The operator should now assure himself that the rectum is completely separated, especially on the left side, where it is apt to adhere to the utero-sacral ligament. Long pressure-forceps are then placed upon

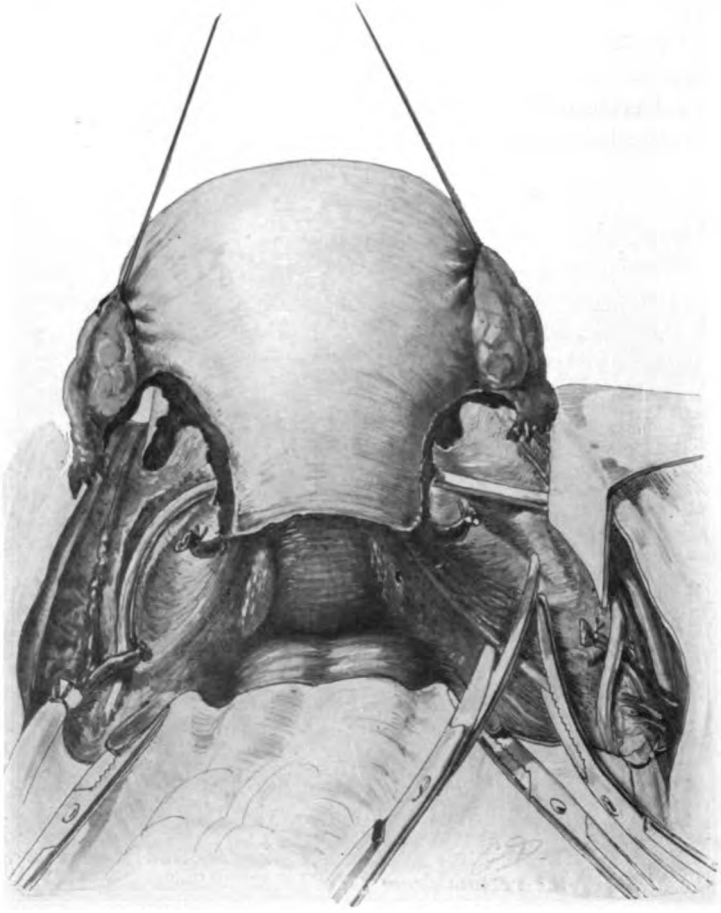

FIG. 65. RADICAL EXTIRPATION BY THE ABDOMINAL ROUTE. *Division of the lateral cervico-pelvic ligaments.* The ureter is held aside. The utero-sacral ligaments are already divided. (Semi-diagrammatic.)

the utero-sacral ligaments of either side as far back as possible and the ligaments are divided in front of this.

Division of the lateral cervico-pelvic ligaments. It will now be found that the uterus is still held down by a couple of broad fan-shaped bands running laterally from the cervix and vaginal vault to the side-wall of the pelvis and pelvic floor. These are the lateral cervico-pelvic or 'Mackenrodt's' ligaments.

They are to be divided after clamping them as far out as possible by means of two or more angular or curved pressure-forceps, on either side (Fig. 65).

Directly they are divided the uterus becomes much more mobile, remaining attached merely by the vagina.

Division of the vagina. The gauze previously placed in the vagina is now withdrawn and the T-shaped vaginal clamp illustrated is applied to the vagina just above the point where the bladder is attached.

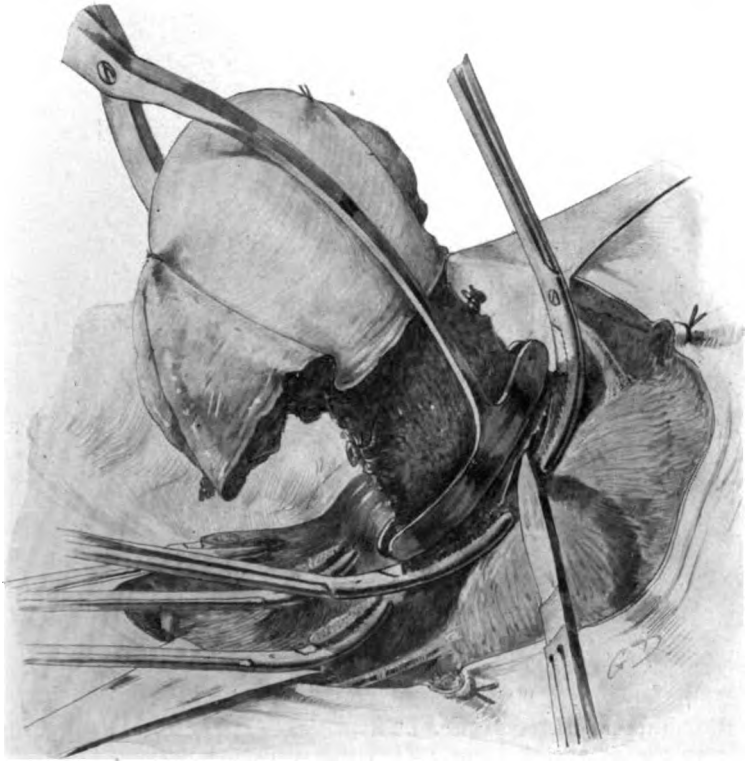

FIG. 66. RADICAL EXTIRPATION BY THE ABDOMINAL ROUTE. *Application of the T-clamp and division of the vagina.* (Semi-diagrammatic.)

Before doing this it is advisable to apply to either side of the vagina below the clamp a right-angled short-bladed pressure-forceps, so as to control the lateral vaginal vessels. The vagina should now, if possible, be mopped dry by an assistant, and the operator then proceeds to divide it with a scalpel immediately below the T-clamp and above the right-angled forceps holding the lateral angles (Fig. 66).

Applying the ligatures. The various pressure-forceps holding the

divided ligaments and the lateral vaginal angles are now replaced by ligatures. Of these, by far the most important are those that secure the vaginal angles and the vessels in them. If this is not done thoroughly very troublesome oozing will occur.

The application of ligatures deep down in the pelvis is facilitated by the use of Worrall's notched needle.

Removal of the pelvic glands and lymphatic tracts. Though in theory it would be best to remove the regional glands and lymphatic tracts

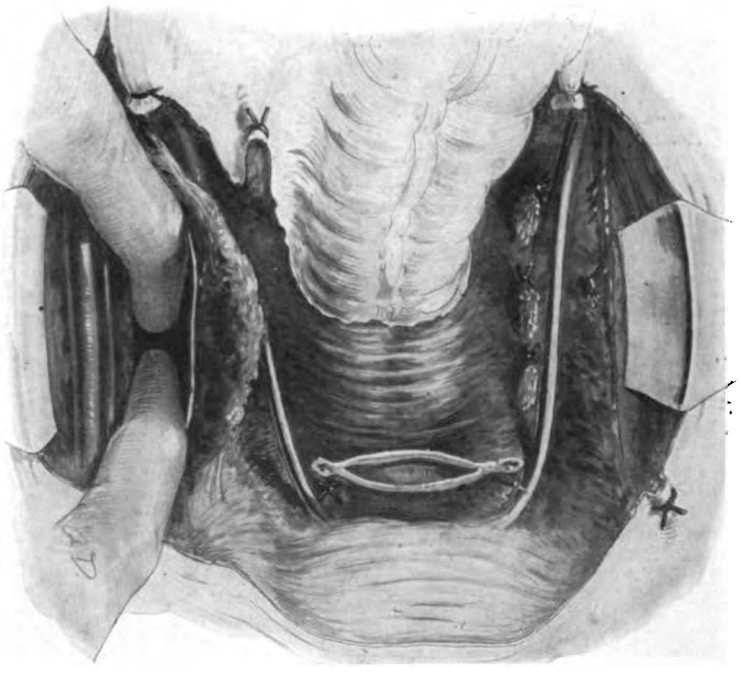

FIG. 67. RADICAL EXTIRPATION BY THE ABDOMINAL ROUTE. *Separation of the tissue in the obturator fossa.* Note the obturator nerve. (Semi-diagrammatic.)

in one piece with the primary growth, in practice it is impossible. The removal of the glands should, therefore, be made the second stage of the operation.

Many operators do not remove the glands at all, holding the case inoperable if they be found enlarged.

Others, amongst whom Wertheim himself is numbered, content themselves with removing them only if they be enlarged.

The author is, however, of opinion that logically the operation is

incomplete without the removal of, at least, the tract of most frequent lymphatic permeation, and both he and his colleague, Comyns Berkeley, have systematically carried it out.

There can be no doubt that this step materially increases the severity of the operation, but, on the other hand, it enables cases to be successfully dealt with that, by less radical measures, it would be useless to operate upon.

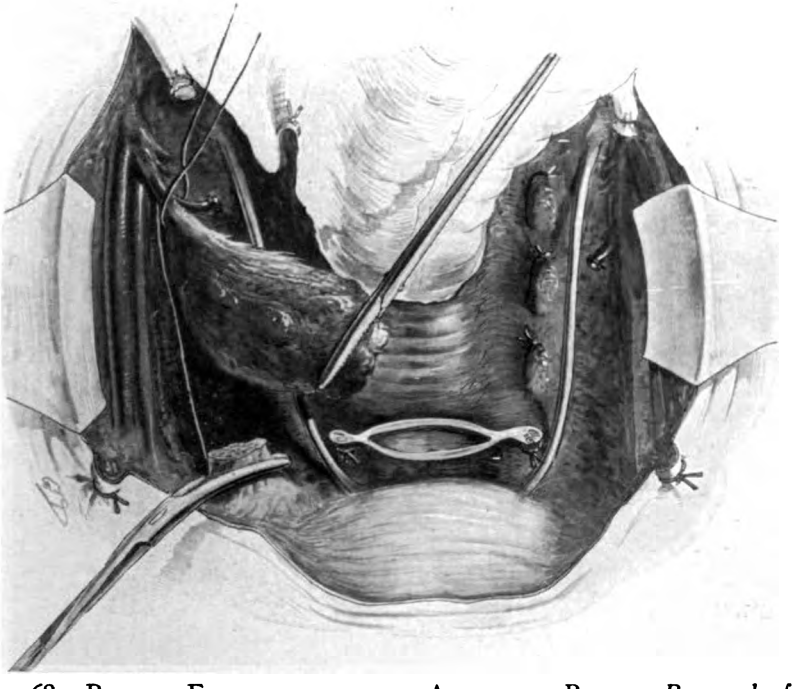

FIG. 68. RADICAL EXTIRPATION BY THE ABDOMINAL ROUTE. *Removal of the tissue occupying the obturator fossa.* The ligature is placed round the anterior trunk of the hypogastric artery. (Semi-diagrammatic.)

The ablation desired is that of the main lymphatic tracts already described (see p. 149).

The operator should begin above. When the glands along the external iliac vessels are not enlarged it will suffice to begin at the bifurcation of the common iliac artery; when they are enlarged it is necessary to start just below the bifurcation of the aorta or even higher.

The vessels having been exposed by reflecting the peritoneum, the connective-tissue sheath covering them should be divided on the outer side of the artery and then reflected immediately off the vessels. In favourable cases it will be found that the whole sheath can be separated

en masse with its contained lymph glands. In advanced cases it is common to find one or more carcinomatous glands adherent to the external iliac vein, from which they should be separated with the greatest care. The sheet of connective tissue will now remain attached only along its inner side where it is continuous with the mass of tissue occupying the obturator fossa.

This mass has at its upper edge the obliterated hypogastric or umbilical artery.

The finger is now gently insinuated between this vessel and the side wall of the pelvis and the mass of tissue occupying the obturator fossa with the contained obturator glands is pushed inwards (Fig. 67).

In this manœuvre the obturator nerve is included in the mass, from which it should be separated unless it is adherent to cancerous glands there.

The obturator vessels cling to the bony wall of the pelvis and are not endangered.

The surgeon still working with his finger separates the cellulo-fatty tissue from the pelvic floor below so that it only remains attached by its upper and lower ends.

The lower end is clamped just above the lateral angle of the bladder, and divided above the clamp, when it will be found that the whole mass can be reflected upwards pivoted on the anterior trunk of the hypogastric artery.

A stout ligature having been made to encircle this pedicle, the mass is cut away, carrying with it the original ligature on the uterine artery, the hypogastric artery, the obturator and hypogastric glands, and a considerable amount of cellulo-fatty tissue (Fig. 68).

The tissue adjacent on the side of the cervix and vagina is thus cleared away down to the bony pelvic side wall.

In carrying out this proceeding great care must be taken that the ureter is not inadvertently included in the parts removed.

Suture of the peritoneal floor. All oozing having been stopped, a small piece of gauze is packed into the cavity and one end pushed down the vagina. The anterior cut edge of the peritoneum is now sutured to the posterior cut edges, beginning at the site of the ligature on one ovario-pelvic ligament, and continuing across to the same point on the other side.

A new pelvic floor composed of peritoneum is thus formed.

Closure of the parietal wound. The parietal wound must now be closed. Inasmuch as the healing powers of these patients are below the normal, it is well to use a few through-and-through sutures to supplement the buried stitches.

ULTIMATE RESULTS OF THE OPERATION

As might be expected from the facts of pathology previously quoted, the prospects of permanent cure in those surviving the operation are good.

Thus Wertheim, the apostle of the abdominal operation, had 53 per cent. of his cases that recovered from the operation alive after five years.

In this country these radical procedures have not been practised long enough to afford statistics of anything like the value of those of Wertheim and some of the Continental surgeons. It may, however, be assumed that the results of British surgeons will not be found inferior.

In estimating the value of the operation in the hands of any particular surgeon, it is absolutely necessary to consider not only the number of deaths from the operation and the percentage of patients surviving it after five years, but also the operability-rate, i.e. the proportion of patients operated upon out of those presenting themselves for treatment.

Thus Wertheim's first 250 operations were selected out of 607 patients attending his clinic—an operability-rate of 41%.

Of these 250 patients, 106 were alive and well at the end of five years, that is to say, out of 607 patients presenting themselves with carcinoma of the cervix, 106 were cured of the disease. This equals 18.4%, and the figure thus arrived at is termed the actual achievement or absolute efficacy-rate, and is the only real test of the value of any individual surgeon's results.

Although, as it has been said, the operation has been performed too short a time in this country to allow of the ultimate results being forthcoming, the following figures of the author and his colleague, Comyns Berkeley, are of interest.

Up to July 1910, we had performed 71 operations selected from 112 patients seen—an operability-rate of 63%. Of the 71 patients operated on, 16 died of the operation (a mortality of 22%).

At the present day (July 1913), of the 55 patients who survived the operation, 23 have died, or are dying of recurrent growth, 2 have died of other disease, 2 have disappeared (known to be alive over three years), and 28 remain alive and free of recurrence.

In 5 out of these 28 patients the glands removed at the operation were microscopically shown to be carcinomatous.

The immediate mortality. The immediate mortality of the operation varies according to the stage of the disease, the physique of the patient, and the thoroughness with which it is carried out.

Thus, when the growth is limited to the cervix, the task set the operator and the demands made on the patient's resisting powers are

far lighter than when it has extended into the bladder or parametrium, or has involved the ureters.

In elderly persons the risk is much increased, especially in patients over 60 years of age. In obese patients the difficulties of the procedure are greatly increased. Many of the sufferers from this disease are in a miserable state of health when they present themselves. This is due partly to the effect of the growth, and partly to the fact that carcinoma of the cervix is undoubtedly much commoner in the neglected and ill-nourished poor than in the well-to-do.

In general it may be said that as regards physique these patients, as a class, are probably the most unsatisfactory of any that come before the surgeon. It is therefore obvious that a general mortality-rate cannot be applied to individual cases, each being a law unto itself in this regard.

Speaking broadly, however, it may be stated that the death-rate in early cases is not much above 5%, in moderately advanced cases probably about 15%, and in advanced cases 25%.

CAUSES OF DEATH AND COMPLICATIONS OF THE OPERATION

Shock. The shock caused by the operation is considerable, and is the chief cause of death. It is greater in proportion to the difficulty and duration of the proceeding.

The time taken varies in different cases. Thus, in the hands of the author it has varied as a rule between one hour and one hour and thirty minutes. It is a matter of real importance to be speedy in its performance, especially in elderly patients. The shock, however, is out of all proportion to the time taken, and no doubt chiefly depends on the extensive 'tissue and sympathetic injury' that the procedure necessitates.

The operation as has been described is by far the most difficult of any recognized surgical procedure, not excepting abdomino-perineal excision of the rectum, and it is desirable that both operator and assistant should be experts if the best results are to be obtained. In patients over 60 years of age the chances of death from shock are considerable.

Hæmorrhage. The operation involves considerable loss of blood by reason of the persistent oozing that characterizes most cases.

From this point of view young plethoric patients are worse subjects for it than the attenuated and anæmic.

Chloroform is preferable to ether as an anæsthetic, because the latter increases the bleeding. In particular, cyanosis of the patient should be avoided.

The principal loss of blood is by venous oozing. It is for this reason that ligature of the hypogastric arteries as a preliminary step does not materially diminish the bleeding.

The steps associated with the freest oozing, namely, the complete separation of the bladder and the division of the sub-ureteric tissues, should be left to as late a stage as possible.

The use of continuous saline infusion during the operation, though beneficial as far as shock is concerned, has, however, in the experience of the author, increased the loss of blood during the operation, and therefore it should be used with much caution and not in any case at the outset of the proceeding.

Injury to the bladder. With the greatest care the bladder will sometimes be opened during its separation. The event is a misfortune because secure suture is very difficult owing to the position of the hole and the attenuated condition of the bladder wall.

Moreover, since more or less septic infection of the large cavity left by the operation is usual, the chances of the sutures holding are problematical and a fistula is very likely to result.

In some cases it may be justifiable to cut away a piece of adherent bladder, but it is a proceeding not often advisable.

Quite apart from actual opening of the viscus during the operation, sloughing of the exposed and thinned bladder base sometimes occurs during convalescence. Easily absorbable catgut should always be employed for suture of the bladder. Permanent sutures lead to calculus formation.

Injury to the ureters. A segment of the ureter may be deliberately excised during the operation. If this is done, or if the ureter is accidentally divided, the upper cut end should be implanted into the bladder. The expedient of simply tying it is a bad one.

Ureteral grafting, though often successful, is apt to be followed by a ureteral fistula for the same reason that suture of the bladder often fails.

Where the ureter is cut high up the bladder will have to be displaced to allow of a junction being made.

Sloughing of the ureter some days after the operation is the commonest cause of ureteral fistula. It is often associated with pyelitis and high fever.

Some of these fistulæ close spontaneously after weeks or months, but others are permanent.

The problem of how to deal with one of these latter is difficult—certainly no operation should be attempted for a year. The choice then lies between nephrectomy or an attempt to graft the ureter into the bladder. Where the opening is situated only a short distance from the bladder (as proved by the attempted passage of the ureteral catheter) it would be better to attempt the latter proceeding provided the bladder

and kidney were healthy. Easily absorbable catgut should be used, for even the finest thread or silk may be the origin of a calculus.

Injury to the rectum and rectal fistula. Opening the rectum whilst separating it from the vagina is a serious disaster. The accurate closure of such a hole is difficult, the sutures are very apt not to hold, and severe infection of the operation area is almost certain.

If the patient survives, spontaneous closure of the fistula almost always occurs.

Injury to the great vessels. Small lateral perforations of the external iliac vein can be closed by ligature without harmful results.

An injury necessitating complete occlusion of the vein is very serious. A similar accident to the common iliac vein is a disaster, and the patient is very unlikely to recover.

Ligature of both hypogastric arteries as a preliminary proceeding has already been referred to.

The most serious arterial complication is thrombosis of the external iliac artery. I have seen three such cases. It is probably due to injury of the artery during the removal of the iliac glands conjoined with very feeble heart action, the result of shock.

If the patient survives, more or less extensive gangrene of the leg is almost certain.

A thrombus may spread from a ligatured hypogastric artery into the common iliac artery. This is the drawback to preliminary ligature of the former vessel.

Septic infection of the operation area. More or less extensive infection of the large cavity left under the new peritoneal floor is probably of constant occurrence, and accounts for the fever commonly observed during the second week of convalescence. It is to be minimized by cleansing the growth and vagina as far as is possible before commencing the operation. In most of the advanced cases unfortunately streptococcal infection of the growth and vagina has already occurred, and to sterilize the vaginal mucosa is impossible. The insertion of gauze packing at the termination of the operation, as advised by Wertheim, undoubtedly assists drainage by delaying the closure of the upper end of the vagina.

Very serious suppuration may occur under the new peritoneal floor, which may terminate in death or only be recovered from after a long period of high fever and wasting.

In such cases the upper end of the vagina should be kept open by occasionally passing the finger through it into the sub-peritoneal cavity beyond.

Peritonitis. Peritonitis has been a comparatively rare cause of death in the cases that have come under the author's experience. When it

does occur it is secondary to infection of the sub-peritoneal space already mentioned.

In many of the advanced cases salpingitis will be found when the abdomen is opened. This may range from simple thickening and adhesion of the appendages to hydrosalpinx, pyosalpinx, or tubo-ovarian abscess.

The presence of diseased tubes makes the operation much more difficult on account of the adhesions.

Suppuration or sloughing of the abdominal wound is not uncommon, the infecting organisms being derived from the vagina; extensive sloughing may occur in the deeper planes of the abdominal wound without any appearance of such on the skin, beyond the escape of a small quantity of dark-coloured sero-pus between the superficial stitches.

In all such cases the wound should be completely opened up and treated by frequent application of peroxide of hydrogen.

The best method of preventing infection of the parietal wound is to cover its edges with thin sheet rubber in the manner already described.

RADICAL EXTIRPATION BY THE VAGINAL ROUTE (SCHAUTA'S OPERATION)

The radical vaginal operation consists in a wide extirpation of the uterus and vagina and their adnexa from below.

It has been extensively practised by the originator with good results, but it has the drawback that it is impossible by this means to remove the iliac glands, or even to know that they are affected before the operation is practically concluded.

It is nearly as difficult as the abdominal operation, though the primary mortality is smaller, because the patients suffer less from shock.

In the writer's opinion it is inferior to the abdominal operation, but it is sometimes to be preferred, namely in very obese patients or in those who by reason of age or constitutional weakness may be deemed unfitted to undergo the alternative proceeding.

The steps of the operation are as follows:

Previous preparation. This is similar to that already described on page 152, but inasmuch as the vagina is removed entire and closed, it is less important to effect a thorough cleansing of the growth.

Anæsthetic. Chloroform is preferable in most cases for the reasons given on p. 151.

This operation is far more suitable for spinal anæsthesia than the abdominal procedure.

Position. The lithotomy position.

Closure of the vagina. The vagina and growth having been thoroughly cleaned by the application of some strong antiseptic, the former

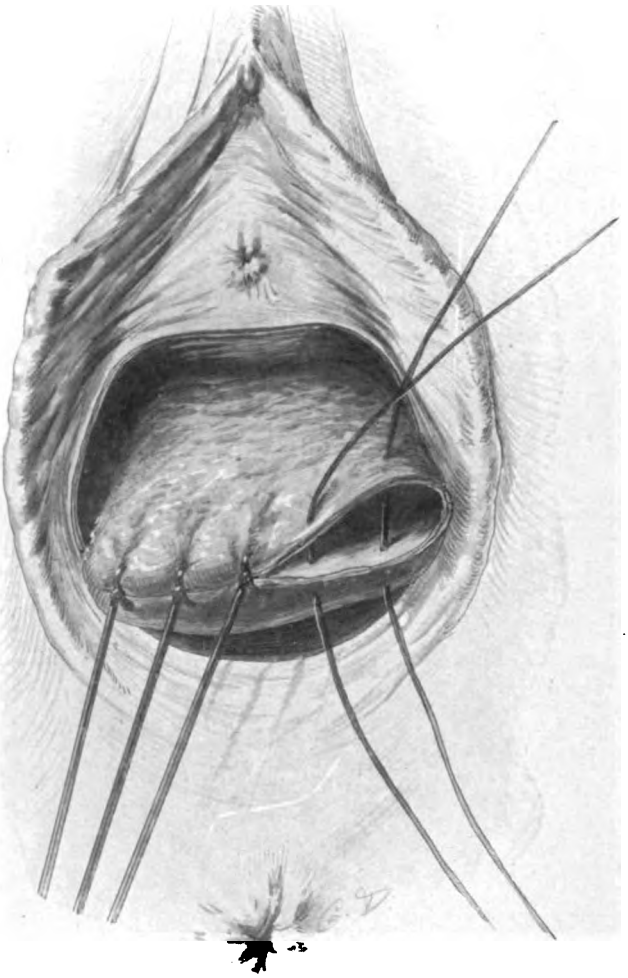

FIG. 69. RADICAL EXTIRPATION BY THE VAGINAL ROUTE. *Separation and closure of the lower end of the vagina.*

is packed with gauze. The lower end is then dissected free all round and closed by sutures, the ends of which are left long to act as tractors (Fig. 69).

Separation from the rectum. The posterior vaginal wall is now separated for its whole length from the rectum.

The para-vaginal incision. By means of a scalpel an incision is made starting in the left para-rectal tissue high up, continuing through

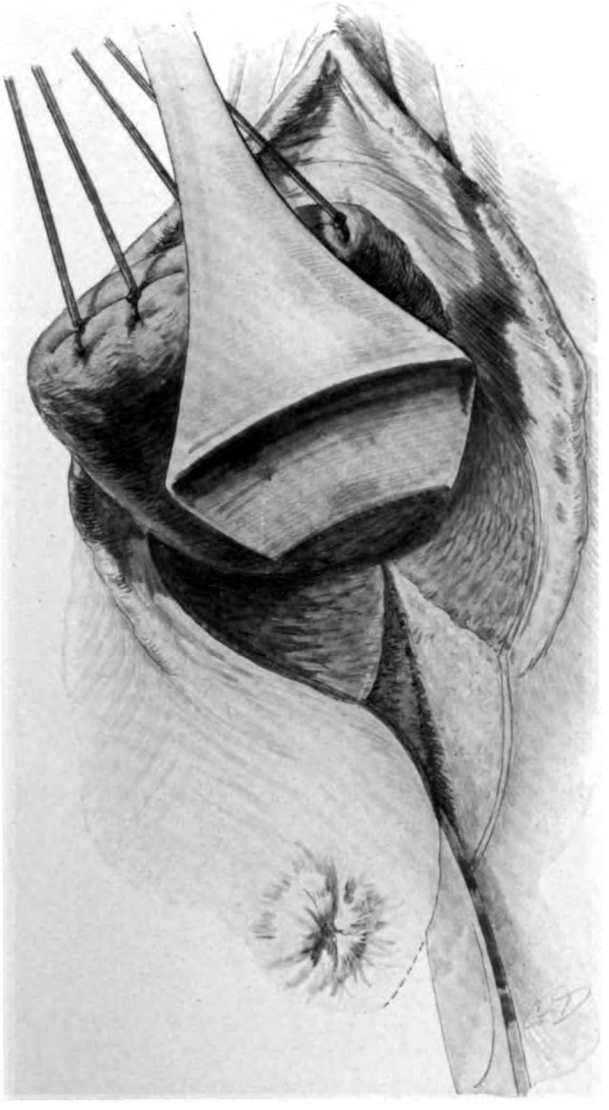

FIG. 70. RADICAL EXTIRPATION BY THE VAGINAL ROUTE. *Making the para-vaginal incision after separation of the vagina from the rectum.*

the left levator ani, and appearing on the skin just to the left of the anus, from whence it is carried backwards in a curve nearly to the coccyx.

This incision enormously increases the room in which the operator has to work.

It produces much hæmorrhage which should immediately be controlled.

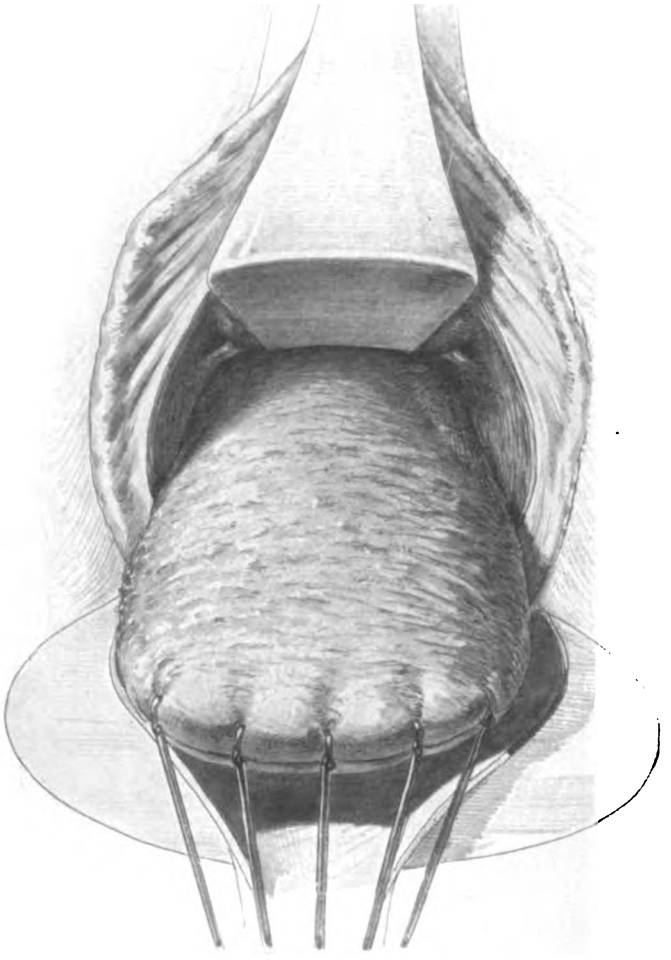

FIG. 71. RADICAL EXTIRPATION BY THE VAGINAL ROUTE. *Separation of the vagina from the bladder and exposure of the ureters.*

Separation of the urethra and bladder. The uretha and bladder are now separated from the anterior vaginal wall.

Lateral separation of the vagina. The lateral walls of the vagina

are now separated by division of the para-vaginal tissue as far outwards as possible.

There is usually free bleeding which must be controlled by forceps.

Exposure of the ureters. The anterior dissection is now continued until the termination of the ureters in the bladder is plainly visible.

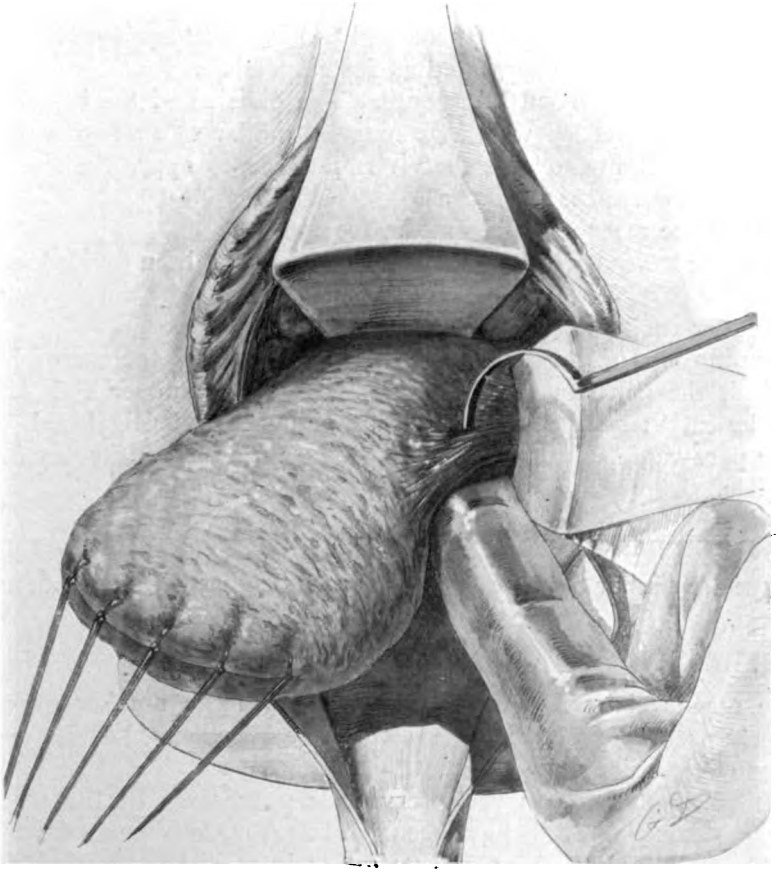

FIG. 72. RADICAL EXTIRPATION BY THE VAGINAL ROUTE. *Beginning the ligature of the tissues lateral to the vaginal vault and cervix.*

This is the most difficult part of the operation (Fig. 71).

A broad expansion of very vascular fibro-cellular tissue runs on either side, backwards and laterally towards the vaginal vault.

These bands require division and bleed freely.

The ureters having been seen, are pushed laterally as much as possible

by the fingers, and a broad retractor is then inserted to keep both ureters and bladder out of the way.

Opening the peritoneal cavity in front. The peritoneal cavity is now opened by snipping through into the utero-vesical pouch.

Opening Douglas's pouch. The detached vagina having been pulled forwards, the peritoneum at the bottom of Douglas's pouch is now divided.

The finger should then be introduced and if the appendages be found adherent they should be separated as far as possible.

Division of the broad ligaments. The division of the broad ligaments is now proceeded with in a manner similar to that of a simple vaginal hysterectomy, except that it is possible to apply the ligatures much further outwards (Fig. 72).

The uterine artery should first be secured.

When the lower half of the para-metric tissue has been divided, access to the upper part of the broad ligaments is facilitated by anteflexing the uterus under the bladder.

Termination of the operation. The removal of the uterus being completed, the peritoneum may be closed over the upper end of the wound by catgut sutures, and all oozing points must be ligatured.

The para-vaginal incision should now be closed by sutures as far as is possible.

CAUSES OF DEATH AND COMPLICATIONS OF THE OPERATION

These are similar to those described when dealing with the abdominal operation.

ULTIMATE RESULTS

The results claimed by Schauta in a very large number of cases are nearly as favourable as those claimed by Wertheim, but his operability-rate is considerably lower.

In this country it has been very little practised. In the writer's small experience the results have been good as regards primary mortality, but not so good as the abdominal operation in regard to freedom from recurrence. The period of convalescence is a long one, and the wound may suppurate badly or even slough.

CHAPTER II

TREATMENT OF CARCINOMA OF THE BODY OF THE UTERUS AND OF CHORIO-EPITHELIOMA

CARCINOMA of the body of the uterus is treated by removal of the entire uterus, together with the appendages and the upper part of the broad ligaments.

It is not necessary or proper to carry out so radical a procedure as that for carcinoma of the cervix because the lymphatic tracts liable to be permeated in carcinoma of the body are different from those affected in carcinoma of the cervix. In the former case they run upwards in the ovario-pelvic folds and communicate with the lumbar and aortic glands. A sufficient extirpation can be carried out by performing a total hysterectomy, without subjecting the patients to the risks of a much more severe procedure from which they would gain no commensurate benefit.

The uterus may be removed either by the abdominal route or by the vaginal route. As the technique of these operations is described elsewhere it is unnecessary to repeat it here. The abdominal route is the best, in all but very stout or very feeble patients. Whichever method is adopted, the cervical canal should first be sutured to prevent the escape of carcinoma cells during the operation.

The ultimate results of the operation are much better than in the case of cervical disease. Probably at least 75 per cent of those recovering from operation remain free from recurrence, provided surgical interference is not carried out in cases in which the growth has obviously spread beyond the confines of the uterus.

Palliative operations. Cauterization by heat has been used as a palliative operation in extensive involvement of the uterus by carcinoma. The degree of temperature should not be excessive, for the tissue should be cooked rather than charred. Advocates of this procedure believe that by carefully graduating the degree of temperature it is possible to destroy carcinoma cells at some distance from the surface without destroying the normal cells close to the surface involved. Care should be exercised to protect the vagina, bladder, and rectum. This procedure is probably inferior to radium treatment, which is considered at some length in another chapter.

Chorio-epithelioma. Chorio-epithelioma may appear in two forms, one highly malignant and the other semi-benign. Our inability

at the present time to differentiate these forms makes it extremely difficult to give a prognosis as to life after operation. In an individual case we are justified in exercising every endeavor to eradicate the disease, in spite of our knowledge that many cases are highly malignant and that permanent relief cannot be expected. A few patients with evident metastases have recovered, with spontaneous disappearance of the metastatic foci.

The disease spreads by way of the blood vessels, so that extensive dissection of the lymphatic tissue is not necessary. Evident metastases in blood vessels have disappeared after removal of the primary disease. The disease ordinarily develops rapidly, but cases are on record in which the disease has remained latent for many years. While it ordinarily develops in the uterus, several cases have been reported of primary growth in the tube, and in these cases the disease is exceptionally malignant. If the diagnosis has been made early and there has been little manipulation of the uterus the prognosis is fairly good. Teach reports 189 cases of which 100 were operated upon. All but one of the 89 not operated upon, died; while of the 100 patients subjected to operation, 24 remained well for over a year and 13 for over two years.

As soon as the diagnosis is made an abdominal panhysterectomy should be performed. Hirschmann and Cristofoletti emphasize the necessity of excision of the deep pelvic veins for the purpose of removing the tissue along which metastasis occurs. Vineberg insists that one should not refuse to operate even in the face of most unpromising local conditions, since extensive infiltrations are usually due to venous involvement and this has been known to disappear after operation. Vaginal nodules should be excised when they appear.

If the diagnosis is made during an intra-uterine examination or curettage for supposed hydatid mole one may perform a vaginal hysterectomy immediately.

SECTION VII

PERITONIZATION

BY

FRANK W. LYNCH, A.B., M.D., F.A.C.S.

Professor of Obstetrics and Gynæcology, University of California Medical School; Obstetrician and Gynæcologist, University of California Hospital, San Francisco.

CHAPTER I

PERITONIZATION

PERITONIZATION may be defined as plastic surgery whose object is to maintain an intact, smooth, serous covering within the abdominal cavity. It is based upon study of the healing of intraperitoneal wounds and is concerned with the production and avoidance of adhesions.

Peritonization aims primarily to prevent adhesions by smoothly inverting abrasions under cover of their serous margins. When the injured or diseased areas are of such size or character as to be unsuitable for this method, they may be made extraperitoneal by covering them in such a manner that the resulting adhesions are not likely to become harmful.

FORMATION OF ADHESIONS

During the early processes of repair of peritoneal injury, an exudate of fibrin takes place as a physiologic effort to encapsulate the point of injury. The formation of adhesions has been studied by Hertzler, who observed parts of the processes through a glass window sewn into a dog's abdominal wall. When the intestinal wall was irritated by the point of a needle, there resulted a primary increase in intestinal peristalsis, which was soon followed by a decrease. An exudation of serum first took place, together with changes in the endothelial cells. The exudated serum soon coagulated and formed fibrin, especially at the edges of the process. At the same time there was an extravasation of polynuclear leucocytes, and a few hours later round cells collected in the fibrin mass. Coincidentally the fibers of the basement membrane began to loosen and the different fibers became entangled with those of the opposing layer of peritoneum. The fibrin formed at the beginning remained and served as a scaffolding for the subsequent process.

Adhesions result if much fibrin is exuded and the character of peristaltic movement permits firm attachment to the contiguous peritoneal surfaces. Vigorous peristalsis may prevent the formation of adhesions over small areas of peritonitis by constantly pulling loose the points of attachment. The adhesions vary in structure with age and type, ranging from the fibrinous exudate, which merely serves to agglutinate opposing surfaces, to vascularized bands of definite scar tissue which firmly unite them.

Since they are the result of nature's effort at repair, they are primarily protective. When the need for their presence has passed, they remain as a menace to the health and safety of the individual, since they do not

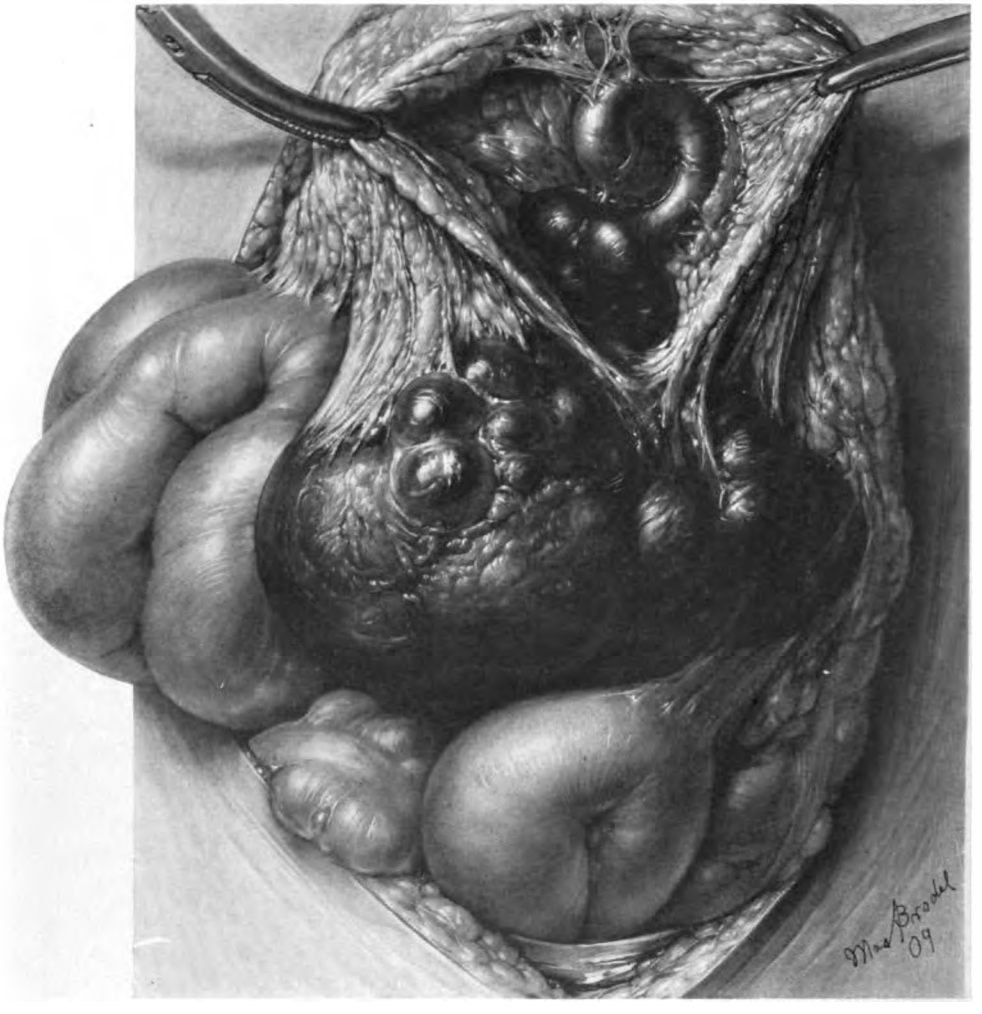

FIG. 73. NATURE'S METHOD OF WALLING OFF A PERITONITIS. Protective adhesions about a degenerating parasitic myoma. (*Richardson.*)

disappear unless sufficiently thin and so situated as finally to break under the pull continuously exerted by peristalsis. The thicker and denser adhesions, by reason of their length and strength, do not usually give way

but become pulled out into fibrous cords which offer the constant threat of intestinal obstruction. When adhesions actually break apart, they tend to retract toward their point of origin and eventually become overgrown and covered by the peritoneal membrane.

Adhesions are normal sequelæ of peritonitis and result from infection, chemical or physical trauma, or any of their combinations. Injury to the serosa cells suffices for a peritonitis.

The density of the resulting adhesions varies with the cause, extent, and depth of the injury, the activity of peristalsis, as well as local and general immunity. There is a direct ratio between the extent of fibrin formation and the character of the resulting adhesions. The immunity varies considerably, since it is not the same for all species of animals nor even for individuals of the same species. The densest adhesions result from trauma in the presence of infection.

Adhesions resulting from infection. Characteristic examples of these are seen in Figures 73 and 74. Adhesions may involve any of the abdominal structures. The omentum usually completes the cover of the inflammatory focus.

Adhesions resulting from chemical trauma. Adhesions from this source are usually indistinguishable, without bacteriologic investigations, from those following infection. With turpentine one may produce abscess formation identical with that due to staphylococcus infection save there are no bacteria in the former. The cell picture and gross anatomical appearance are identical. Ether, iodine, vaseline, lanolin, albolene, and many other substances occasionally advocated for preventing adhesions in man are uniformly the cause of dense adhesions in animals (Cubbins and Abt).

Adhesions following mechanical trauma. Injury to tissues during operation and the presence of foreign bodies during and following operation account for the majority of adhesions after surgically clean cases. The separation of pre-existing adhesions is usually followed by their return because of the raw surfaces resulting from their division. Infection or chemical irritation from disinfectants used in preparation of the skin may act in conjunction. Injury to endothelium is the essential factor for a local peritonitis, but serous abrasions are not invariably followed by adhesions. This statement is borne out by many laboratory workers (Kelterborn, Dembousky, Duschinsky, Vogel, Strauss, Corbett, and others), who tend to minimize the importance of even considerable physical trauma as a uniform cause of adhesions. Thus one may massage the peritoneum of a dog with a sterile toothbrush until bleeding occurs without absolute certainty of their formation, provided that the manipulations are of short duration and carried out under sterile conditions.

Laboratory observations, however, cannot be transferred directly to surgery without many restrictions. While the formation of adhesions is not invariable in these experiments, or even the rule, many animals operated upon show dense bands of scar tissue as a result. Trauma in combination with inhibition of peristalsis is followed invariably by intestinal adhesions. The restriction of peristalsis favors their production by af-

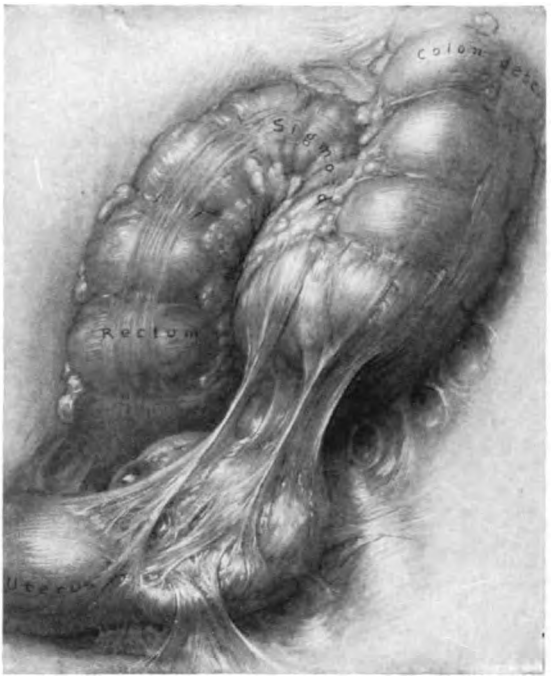

FIG. 74. NATURE'S METHOD OF WALLING OFF A PERITONITIS. Protective adhesions about a tubo-ovarian abscess. (*Royster.*)

fording an opportunity for the agglutinization of the superimposed abrasions. Otherwise the irritant, if infectious or chemical, is forced along the intestinal margins, diluted by exuded serum, until factors favorable for the formation of adhesions are permitted to obtain. Gravity acts only in conjunction with peristalsis. In surgery, on the contrary, we aim at the certainty of avoiding accidental adhesions. Operations on man are usually done in infected fields. Prolonged trauma, moreover, appears to cause more adhesions than an equally slight injury more quickly performed.

The effect of more continued trauma from foreign bodies is proven by experimental and clinical observations. Friction from abdominal growths or displaced organs occasionally causes adhesions. All suture material produces adhesions, and although some would acquit catgut and silk of this accusation these structures may be found encysted after operation. Linen produces dense adhesions, as do chromic and iodized catgut, possibly because of the chemicals which have been used in their preparation. Even hot saline gauze, used for packs during operation, is irritating and produces visceral congestion, serum exudation, and occasional flakes of fibrin. The intestine nearly always shows the imprint of the gauze after a long operation. It is difficult to realize the enormous amount of serum that is secreted around a pack during operation since the gauze is already wet and the excess fluid escapes observation. When a moist rubber dam that has been used for packing is removed, it is followed by the escape of an enormous amount of serum. Sterile gauze left in the abdomen after operation becomes encysted in a zone of dense adhesions since the fibrin quickly invades its meshes. Drains, therefore, should be restricted to very definite indications.

Occasionally retroflexed uteri, without evidence of uterine or tubal infection, present fibrin on the fundus of the organ, as if from friction with the distended rectum or with an ill-fitting vaginal pessary. Similar changes may occur on a prolapsed ovary or ovarian tumor without any evidence of previous inflammation.

Chemical or physical trauma may enter in combination in the formation of adhesions, as in cases with fibroids in which fine adhesions develop about the otherwise normal tube and ovary (friction, pressure, and disturbance of circulation); or in cases in which adhesions accompany dermoids and other large ovarian tumors. They also follow interference with the blood supply, as in torsion of pedicled structures (in which degenerative changes may enter into combination). Hæmatomata in the mesentery also predispose to adhesions (Strassman). Rupture of the aseptic urinary bladder causes adhesions. The fact that dense inflammatory bands are more frequent following operations in the lower than the upper intestinal tract is due doubtless to the greater chance for infection in the lower bowel.

Adhesions are more prone to develop after injury to the nerve supply in the parts whose innervation has been disturbed. Thus Quain cut the intercostal nerves on one side of a dog's abdomen and massaged the parietal peritoneum of both sides with a sterile toothbrush. Adhesions formed uniformly only on the side in which the nerves were cut. Corbett confirmed these observations in a duplicate set of experiments. He showed, moreover, that defects in the parietal peritoneum did not

become covered again with endothelium after section of the overlying intercostal nerves; and that when nerve branches had been cut in right rectus incisions adhesion formation was limited to the denervated area of the parietal peritoneum.

PREVENTION OF ADHESIONS

The need for proper peritonization has become apparent since surgery has been developed to treat pathological abdominal conditions that are essentially chronic in nature, and which constitute a menace to the health rather than to the life of the individual. It was not apparent while abdominal surgery was restricted largely to life-saving measures distinctly emergency in character. Study of the ultimate results of abdominal surgery in many chronic conditions has shown that the margin between success and failure is often so narrow as to depend in large part upon technique. The surgeon is forced to bear in mind the possibility that his operation, because of limitations of technique, may merely substitute one bad condition for the other, i.e., that resulting adhesions may vitiate the good accomplished by the primary features of the operation.

While the factors which contribute to prevent adhesion formation are mainly local and concerned with technique, there are certain general factors that deserve consideration from the standpoint of preserving immunity. Anæmia, with its lowered resistance, may turn the scale for adhesion formation. Since blood for transfusion is generally obtainable, there is no excuse for operating on patients with low hæmoglobin percentage except as an emergency. Operations should be done without unnecessary delays and as quickly as is consistent with the work to be done. The patient should be as flat as is possible for proper exposure since the high Trendelenburg positions are usually unsafe and unnecessary.

The temperature and humidity of the room should concern the surgeon, especially in long and difficult cases. The question of lights in the operating room may also be worthy of consideration, since it is possible that the heat and glare of a very bright direct light is not without reaction.

The possibility of air infection always merits consideration. Masks covering both nose and mouth are highly essential, as well as caps which completely cover the hair. Visitors should remain seated while the abdomen is open, and should wear masks.

The incision, when possible, should avoid injury to the nerves of the abdominal wall, since the association of adhesion formation and nerve injury has already been emphasized. Because of the likelihood of irritation from the chemicals used in preparation of the field of operation, exposure of the skin should be avoided.

To reduce trauma of the peritoneum to a minimum, sponging should be employed as little as possible. It is often unnecessary and is always attendant with injury to the peritoneal endothelium. Blood may often

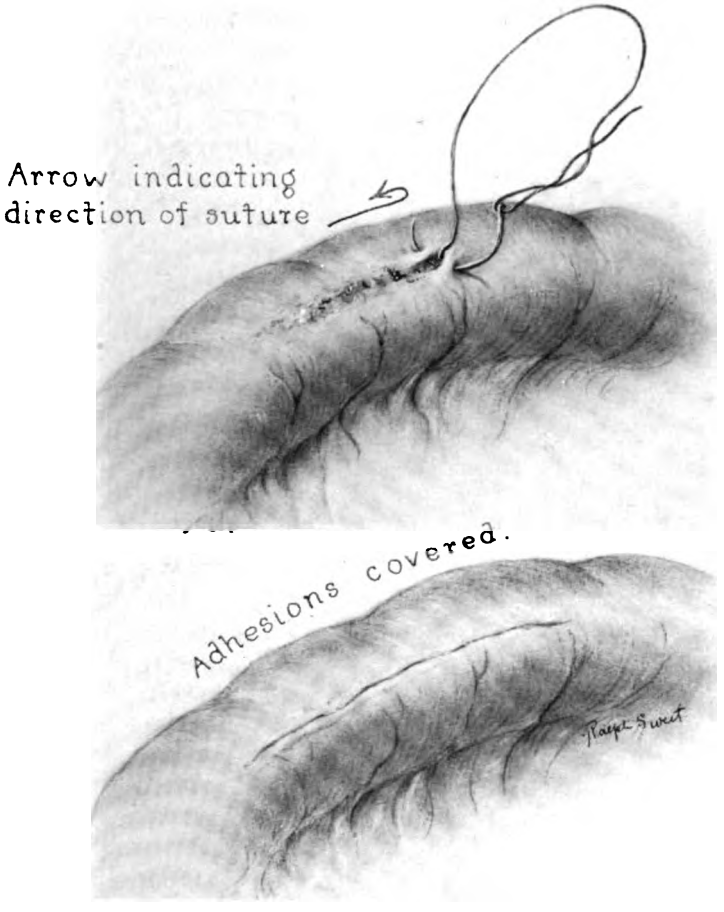

FIG. 75. TECHNIQUE FOR BURYING KNOTS IN PERITONIZATION.

be removed with the gloved hand. Self-retaining retractors permit wide exposure and enable one to work without dragging visceral structures against the retractors and out upon the skin. Since the position of this

instrument is fixed, it probably causes less trauma than hand retractors, which are difficult to hold at uniform pressure and in one place. When the latter are necessary, they should impinge upon the material used for packing, rather than the abdominal wall.

Unfortunately one of the common causes of postoperative adhesions is the trauma incidental to the attempt to remove diseased tissue which is surrounded by a wall of inflammatory reaction. Bowel may be torn and raw surfaces created which are most difficult to cover. Extensive abrasions of the bowel may necessitate resection for their treatment. Adhesions of any part of this viscus to the parietal peritoneum, omentum, bladder, broad ligament, uterus, tube, ovarian tumor, etc., had best be so

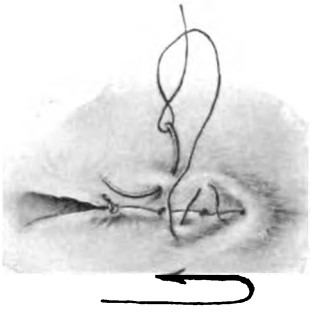

FIG. 76. REPAIR OF INJURY TO THE INTESTINAL MUCOSA.

separated as to leave part of them upon the bowel. This tissue may be treated at one's leisure after good exposure has been obtained. With a careful technique, intestinal resection will rarely be necessary and only when one has exhausted all other means for treating the bowel complication. To illustrate, when the bowel is adherent to the abdominal wall or uterus, the line of incision should not divide the adhesion, unless it is lax or easily distinguishable, but be so made that part of the abdominal wall or uterus is cut away with the gut rather than the reverse. The tissue adhering to the bowel may usually be turned in or cauterized.

Pre-existent adhesions should not be separated unless one is certain that the condition can be improved. Entero-enteric adhesions should not be disturbed unless traction or angulation is present. Often when the omentum is firmly attached to a fixed structure it had better be amputated than separated, since the adherent omentum may be turned back as a flap to cover the injured areas.

There are four methods by which we may treat raw surfaces within the peritoneum which have been created during operation:

1. By infolding them under peritoneal flaps by sutures.

2. By charring them with a cautery so that healing may take place under the char.

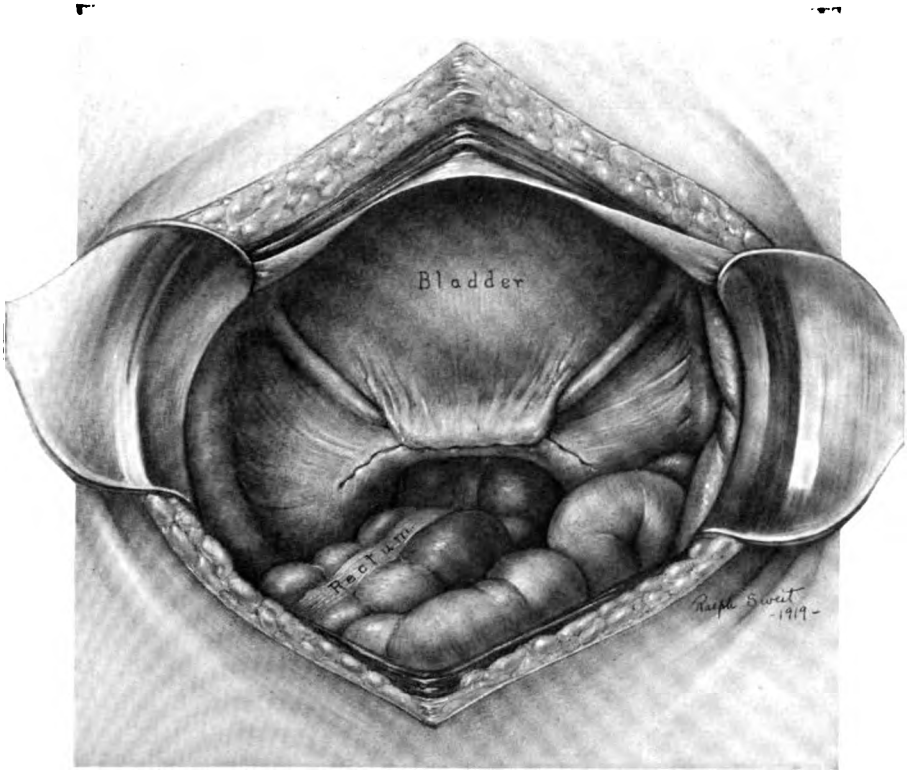

FIG. 77. PERITONIZATION AFTER PANHYSTERECTOMY.

3. By covering them with grafts of omentum, mesentery, or other structures presenting peritoneal surfaces.

4. By covering them with peritoneal flaps formed of neighboring structures.

Infolding raw surfaces by sutures. This technique for the purpose of making injuries and abrasions extraperitoneal was first developed by Goffe when he turned back the bladder flap on the stump of supravaginal hysterectomies. The closure of smaller abrasions was first taught by A. Martin, of Berlin, and has been continued chiefly by his American

pupils. It should be used whenever one may obtain free flaps without undue strain, or whenever it will not markedly constrict the lumen of the intestine, if the abraded areas lie upon the gut. The need for such a procedure is self-evident and would require no further comment were

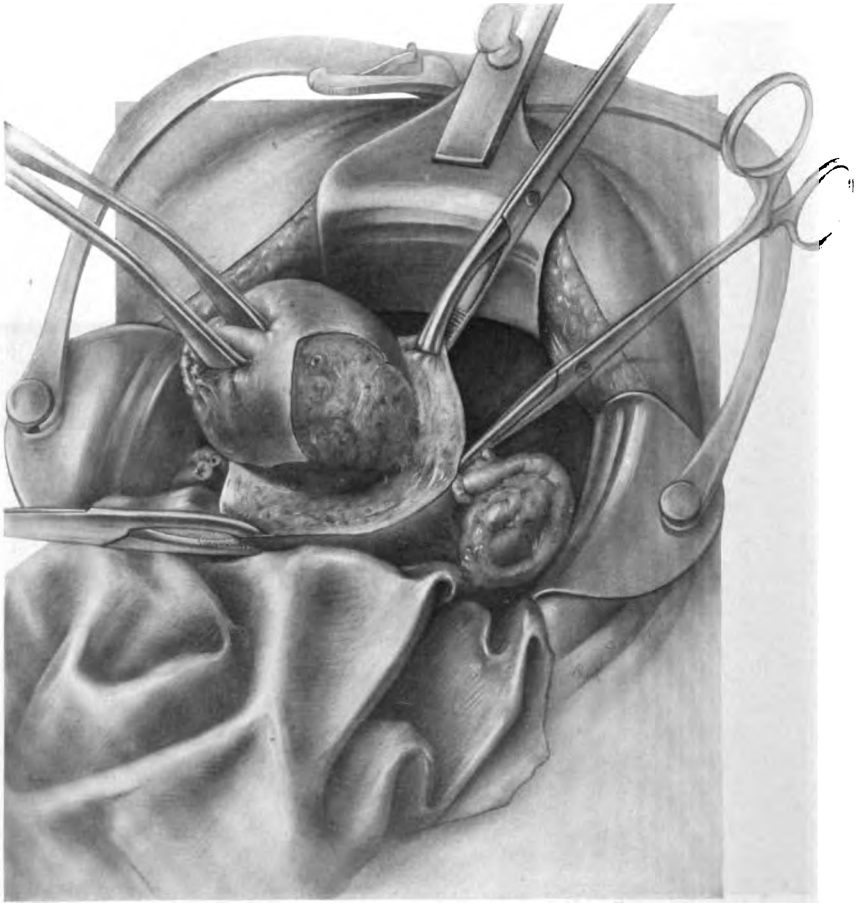

FIG. 78. TECHNIQUE OF DEFUNDATION. The intestines are held back by rubber dam.

not interrupted sutures so commonly employed for this purpose in surgical technique.

All suture material is irritating, some more so than others. Knots are doubly irritating. It has long been known that two peritoneal flaps will become adherent without requiring scarification or other trauma to

produce an exudate if they are first held firmly in place by sutures. The trauma incidental to the suturing, as the handling of tissues, the needle holes, the prolonged irritation of the cells by the suture material overlying them, etc., suffices to produce an exudate capable of agglutinating the tissues.

It seems most logical, therefore, to use continuous sutures of blandest material for peritoneal covers, and to bury all unnecessary knots. When supporting sutures of denser or permanent material have been used, we should infold their knots before proceeding with the covering.

Silk and plain catgut have been found to be the least irritating of suture material. Catgut has the advantage that is it quickly absorbed, while silk may lie encysted for many years before it disappears. Silk, moreover, in the presence of infection often causes sinus formation.

With a fine curved intestinal needle and No. 00 catgut one may infold small abrasions on the bladder peritoneum, broad ligament, mesentery, gut (Fig. 75), or stomach, with a minimum of resulting injury. Free pedicles invariably require inversion.

Peritoneal plastic repair by suture obtains its best opportunity in closing the bases of the broad ligament laid open by the removal of the uterus, tubes and ovaries, since the remaining peritoneal flaps are usually sufficiently lax to permit a perfect closure. The covering suture is not designed to withstand strain, hence we should fasten the bladder peritoneal flaps into place by interrupted sutures before starting the cover. All bleeding vessels are ligated and the vaginal stump is properly supported. A small curved intestinal needle is threaded with half a tube length of No. 00 plain catgut. The closure begins on the right side; the stump of the right ovarian vessels is inverted and the knot buried (Fig. 77) to avoid the formation of adhesions with the ileum. The raw edges of the peritoneum are thus made extraperitoneal. The closure now proceeds downwards and across the pelvis. The knots of the sutures which have been laid to ensure the fixation of the bladder flap are inverted, and the suture is continued up the left broad ligament. The stump of the left ovarian vessels is finally turned in and the knot tied so that it will underlie the sigmoid. Two knots only are used and the first is inverted, so that a minimum of suture material presents to invite adhesions with the intestines. The peritoneal surfaces should be united well above the cut edges so that the raw margins are entirely extraperitoneal (Fig. 77).

The technique for supravaginal hysterectomy varies in no essential particular.

When the uterus only is removed by supravaginal operation, the stumps of the tubes and ovaries and the round ligaments should be buried under a peritoneal flap in a similar manner. The technique for burying

knots is shown in Figure 75. The sutures should be placed so there is a minimum of suture material within the peritoneal cavity. One should not lock the sutures since this leaves the maximum amount of suture material against the serous surfaces.

Fundal resection of the uterus (Figs. 78, 79, 80) would be a more popular operation did it not, like myomectomy, usually leave raw margins at the conclusion of the operation. Raw edges in fundal resections may usually be covered with the round ligament, after which these ligaments may be folded upon the anterior surface of the uterine stump after the plan of the Coffey suspension. It is our experience that adhesions frequently follow suture of the round ligaments, hence only the very margins of these structures should be used for covers. Occasionally if a perfect closure cannot be obtained in this manner, the vesico-uterine plica of peritoneum should be freed and impressed into service.

Myomectomies and cæsarean sections are usually followed by many adhesions because interrupted sutures are commonly employed in closure. The majority of surgeons use only interrupted supporting sutures and attempt to make them do for covers. Continuous sutures in layers are better for either operation since they give more even closure of the cut surfaces of the uterus. If Pagenstecher linen is used to approximate the uterine peritoneum in the cæsarean operation, it should be followed with No. 00 plain catgut, in a continuous Lembert suture (Fig. 81). Pagenstecher linen is too irritating to leave in contact with the peritoneum.

Accidental perforations of the uterus when small should be closed by suture, and in case the serosa is not well inverted or the suture material is much in evidence, a small detached omental flap may be used as a cover.

The appendix is usually amputated after a circular Pagenstecher or chromic gut suture has been inserted for the stump's inversion. The ends of this suture are commonly used to tie the mesenteric stump down over the wound. It is our belief that adhesions are the rule after this technique and that intestinal obstruction is far from uncommon. The following technique adds but a few moments to the operation. A Pagenstecher purse string is inserted, the appendix is amputated and the stump inverted. The margins of the cæcum immediately adjoining the site of the appendix are next inverted with a continuous, fine catgut suture to back up the purse-string suture and to bury the irritating knot. The cut edges of the mesenteric stump should be turned under and against the cæcum or the ileocæcal fold with the same suture (Fig. 82, *a*, *b*, *c*) with a minimum of trauma, since experimental work tends to confirm our clinical observation that adhesions are common after mesenteric suturing.

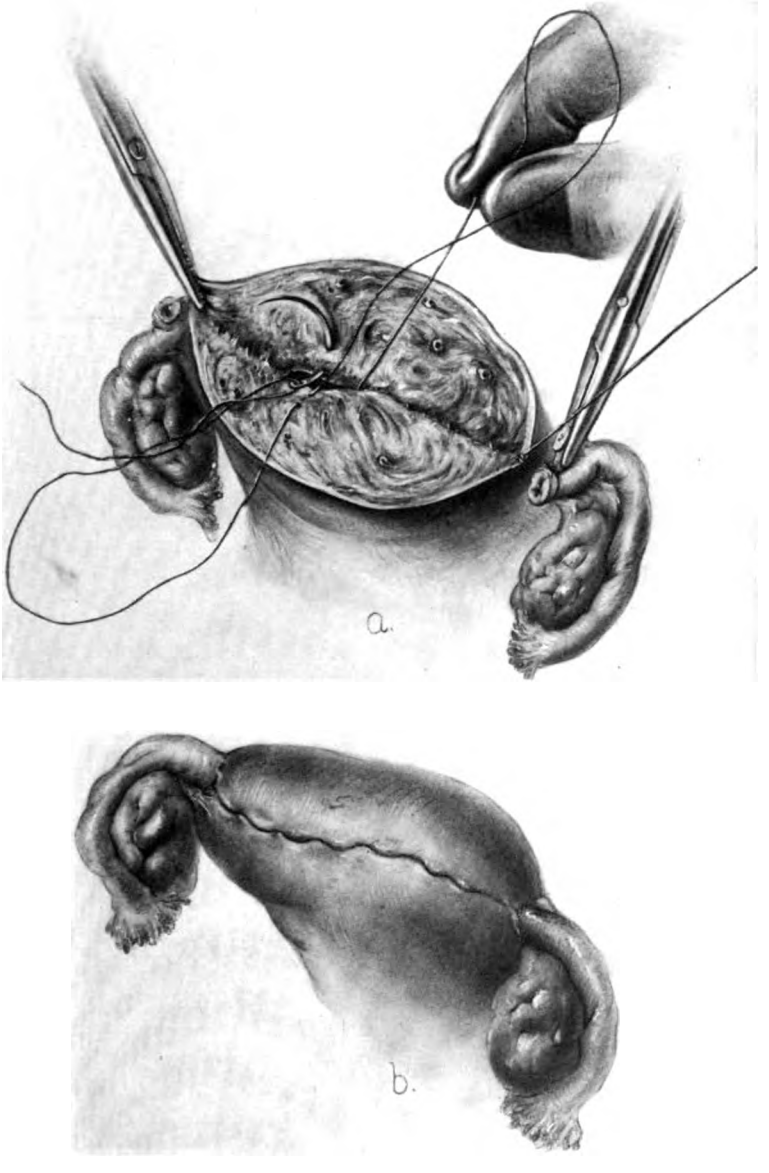

FIG. 79. TECHNIQUE OF DEFUNDATION. Obliteration of the raw surface of the uterus.

Frequently it is necessary to amputate parts of the omentum which have attached themselves to inflammatory areas and have become diseased. The omentum in such cases is usually clamped, cut through, and

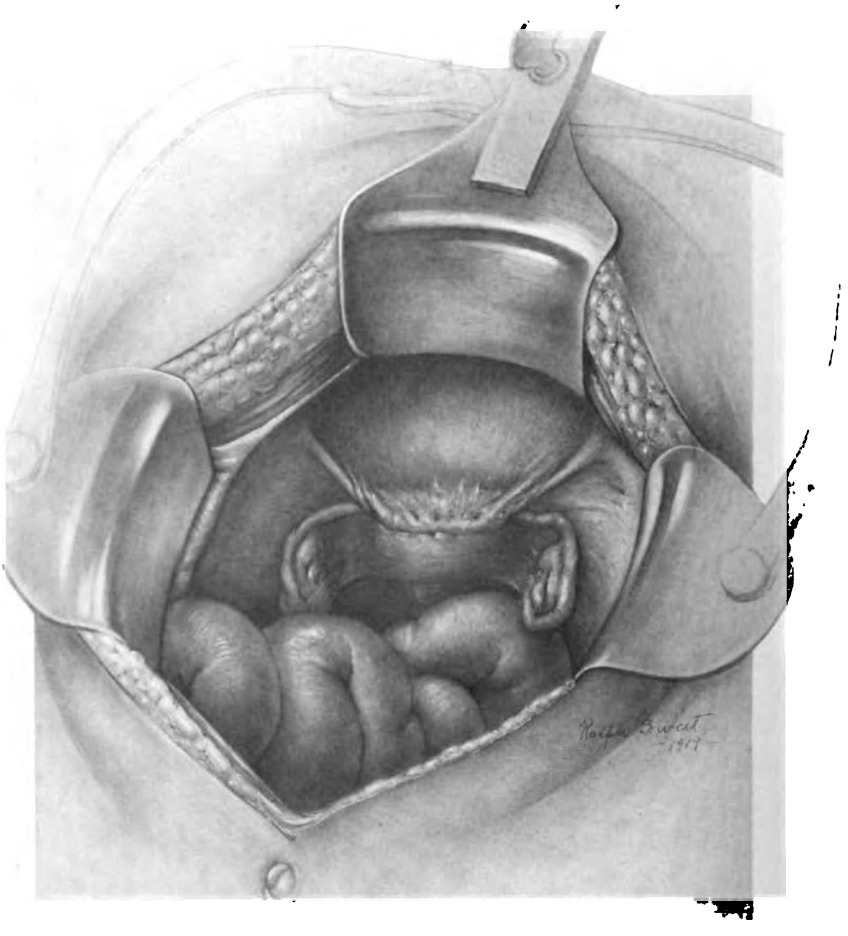

FIG. 80. TECHNIQUE OF DEFUNDATION. Appearance at the completion of operation.

ligated without further attempts to cover it. Since no abdominal organ approaches the omentum in its mobility, there is every chance that its raw edges will find some surface to which they may adhere. Neuhof and Wiener, Rubin, and others have proven, moreover, that the omentum may become adherent by any raw surface and not only by its free edges

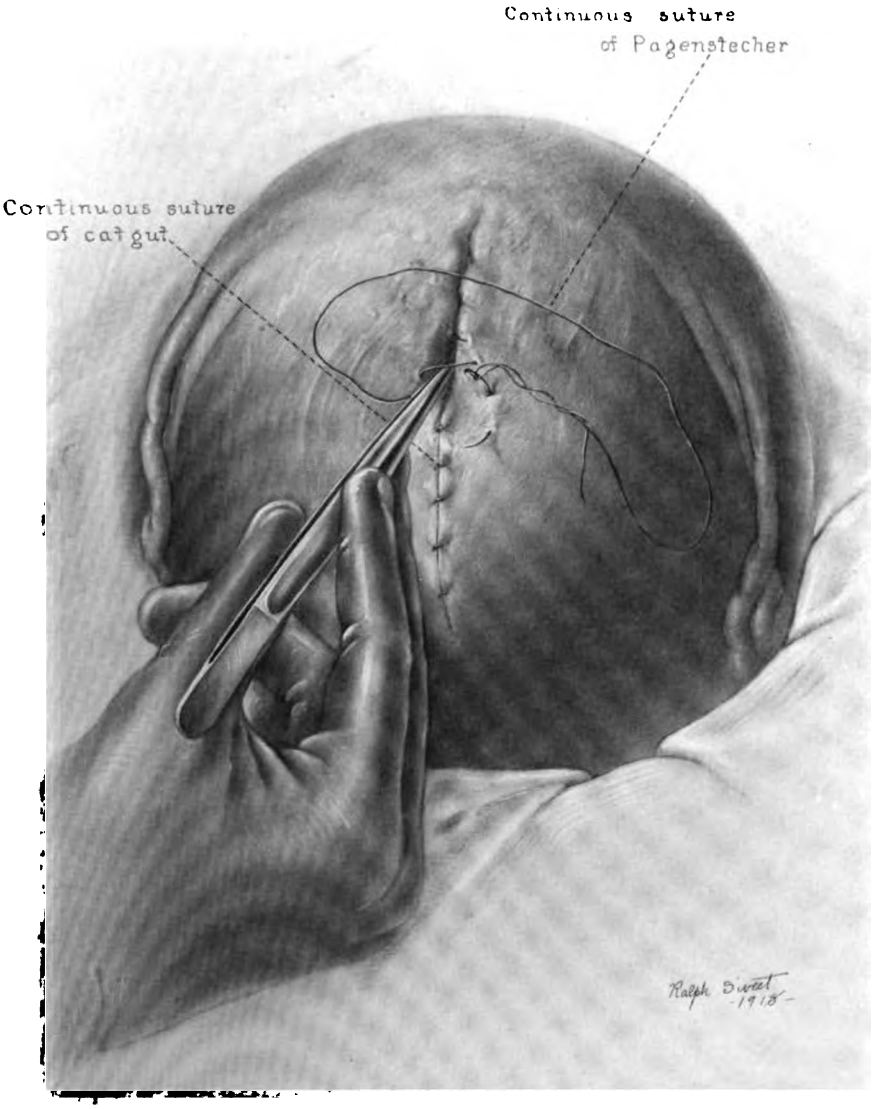

FIG. 81. CLOSURE OF THE SEROUS SURFACE OF THE UTERUS AFTER CÆSAREAN SECTION.

as was formerly believed. We should concern ourselves, therefore, with covering all the abrasions on the omentum and turning its edges in, just as we would cover any other stump of tissue remaining in the peritoneal cavity. When the omentum is to be resected, the vessels should be tied off with fine sutures, the raw edges turned back upon the omentum and

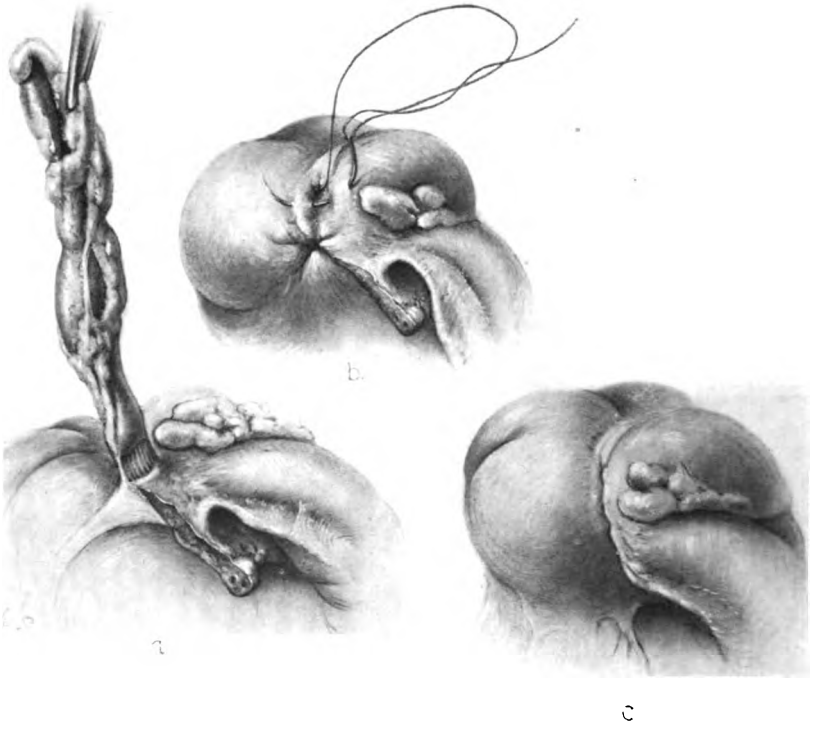

FIG. 82. PERITONIZATION FOLLOWING REMOVAL OF THE APPENDIX.

buried with a continuous, fine, plain catgut suture. Raw areas upon the omental surfaces should also be turned in.

The Webster suspension is one which has given the best results in the anatomic correction of retrodisplaced uteri. Yet the advancement of the uterine end of the round ligament is both the strong and the weak point of the operation, since the new site of fixation upon the posterior aspect of the uterus is exposed to the chance of intestinal or ovarian adhesions. This chance is minimized, however, if the mesentery of the

round ligament (anterior layer of the broad ligament) is pulled up and over the newly fixed ligaments as a cover to protect the ovaries or intestine from irritation by the non-absorbable sutures which are absolutely essential for fixation. The free margin of the round ligament can also be used for the same purpose (Fig. 83, *a*, *b*, *c*).

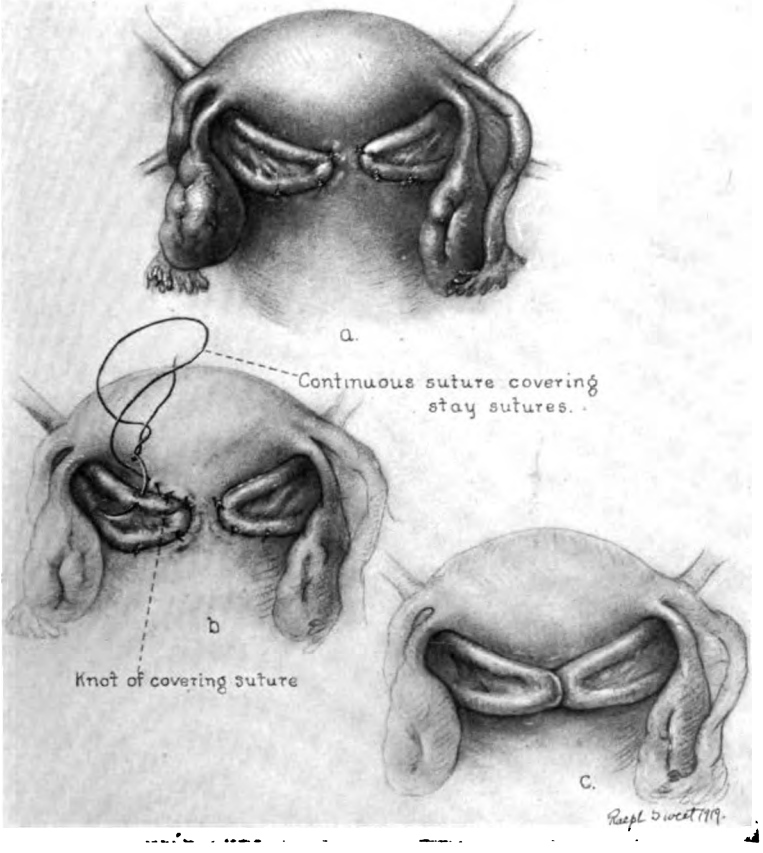

FIG. 83. PERITONIZATION FOLLOWING SUSPENSION OF THE UTERUS BY WEBSTER'S METHOD.

The Webster method enables one to avoid leaving raw surfaces when we remove one tube and ovary and allow the uterus to remain. The round ligament is fixed in place by non-absorbable sutures. The mesentery of the round ligament is pulled over the attached ligaments and sewn into place on the uterus by a running mattress suture which infolds the raw surfaces just as a French seam (Fig. 84, *a*, *b*, *c*).

A fine continuous suture of plain catgut should be used to complete the closure in stomach or bowel resections, or anastomoses.

The closure of the parietal peritoneal cavity is most important since nearly all surgeons agree that omental adhesions follow the usual closure. Gut, moreover, is frequently adherent to the scar. A proper closure is shown in Figure 85. Many have objected to the inclusion of much peritoneum in a single bite of the suturing needle on the ground that the delicate tissue tears through in the strain attendant upon retching and vomiting.

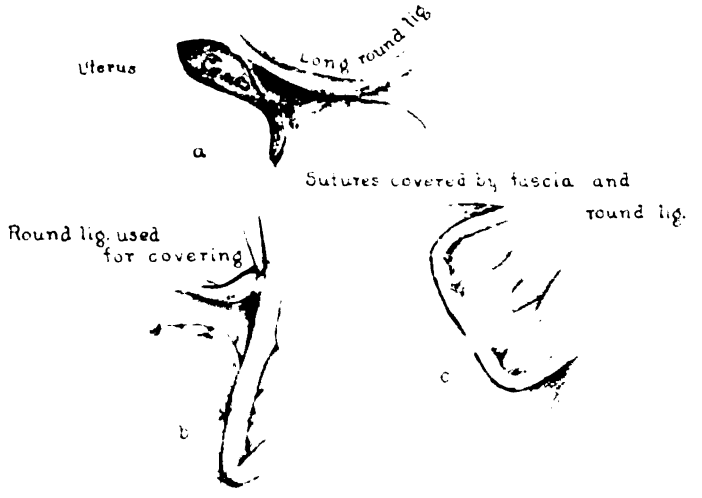

FIG. 84. PERITONIZATION FOLLOWING SUSPENSION OF THE UTERUS, COMBINED WITH REMOVAL OF THE TUBE AND OVARY.

The value of this closure has been shown experimentally by Neuhof and Wiener. We have proven it to our complete satisfaction from observations in secondary operations and autopsies, since adhesions have rarely been met with.

Cauterization. The cautery has been long used in surgery to burn through pedicles and to check the oozing of blood from raw surfaces, when packing failed and ligation was impossible. It has usually been believed that such treatment was not followed by adhesions, since the granulations were protected from exposure and irritation by the charred surfaces until they became covered by the newly formed endothelium. Vogel, as the result of his work in 1902, concluded that this held true

only for deep charring, and that superficial cauterization caused adhesions. More recent investigations have confirmed his conclusions.

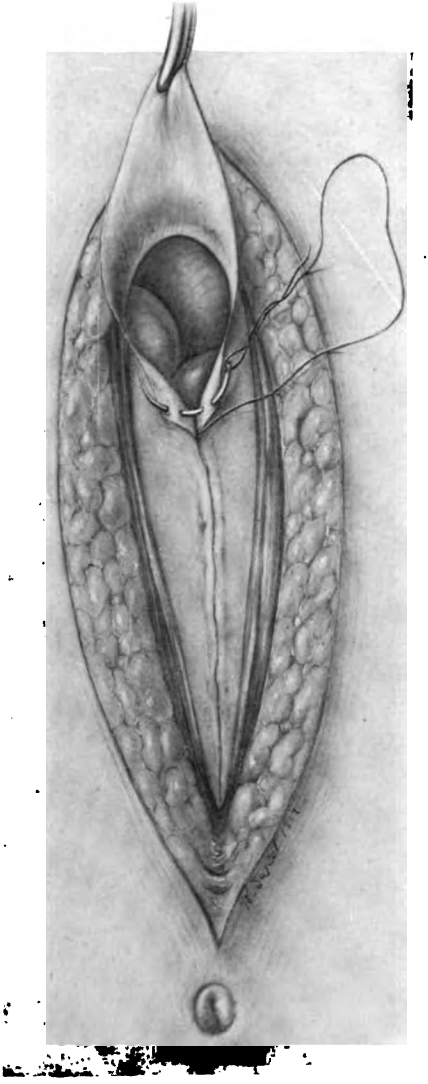

FIG. 85. PROPER METHOD OF PERITONEAL CLOSURE.

Within the last few years the cautery has been widely used for cutting through and thoroughly charring infected bleeding surfaces, although some, as Murphy, claimed that such measures used for infected

pedicles were most likely to cause infection. It has been popular for the amputation of the appendix.

There is not a wide field for the cautery in abdominal surgery save as a substitute for the knife in selected cases, since the majority of abrasions permit of closure or omental grafting. Oozing, raw surfaces occasionally require cauterization when they cannot be controlled by packing, and do not permit of ligation.

The cautery may be used properly for charring tags of separated adhesions and occasionally for separating adhesions, especially for treating a Jackson's membrane. It is preferable to knife resection of the ovary, which is almost invariably followed by adhesions. It should not be used to char the intestine deeply.

Omental grafts. The value of omental grafts was first emphasized by Senn, who proved the value of detached flaps by experimental study and applied them in the human to strengthen the line of sutures in intestinal resection. Until quite recently omental grafts have not been much used because subsequent work advanced the opinion that they were at best temporary in character, were soon absorbed, and that, in the event of infection, they merely added fuel to the fire, since they had lost in amputation both circulation and resistance. Their employment was restricted largely to act as a buttress in threatening intestinal perforations in typhoid, thrombosis of the mesentery, etc., when the area was too large to infold without a chance of causing stenosis of the intestinal lumen.

Non-detached flaps have been more widely employed to make harmless visceral adhesions, or at least to determine to some extent where they shall occur. This procedure has been more successful in the upper abdomen than in the pelvis, since adhesions in the latter situation frequently give rise to pain or dragging sensations because of the pull exerted upon the stomach. Non-detached flaps have been utilized after cholecystectomy to prevent union of the stomach with the liver, to cover and buttress perforations in the duodenum which could not be sutured in a perfectly satisfactory manner, to reinforce carcinomatous areas which appear to be in danger of perforation from distension, and to aid in checking bleeding from oozing surfaces. Non-detached grafts, nevertheless, are but adhesions, and present the objections offered by adhesions, even though their site is chosen. They may, however, occasionally be the best type of closure, even though there is always present the possibility that a loop of bowel may find its way through the omental loop and become strangulated.

While many, as Webster and his school, have long used detached omentum as grafts for closure of peritoneal abrasions too large to suture safely, their value was not absolutely determined by animal experimen-

tation until quite recently when Sweet, Chaney and Wilson, Davis, Finton and Peet, and others studied the fate of free omental grafts in various experimental conditions. Finton and Peet, especially, have shown that thin detached grafts survive unchanged for many months when used under sterile conditions, and that unless the graft is thick and contains large deposits of fat, there rarely follow adhesions save in event of infection or hæmorrhage (Figs. 86, 87). Thick grafts should not be used. The graft, moreover, is likely to prevent the spread of a general infec-

FIG. 86. OMENTAL GRAFT. Microscopic appearance five months after the implantation of a free omental graft over the suture line in an artificial perforation of the intestine. (*Finton and Peet.*)

FIG. 87. OMENTAL GRAFT. Microscopic appearance six months after the attachment of a free omental graft over the suture line closing a slit in the intestine. (*Finton and Peet.*)

tion, even when fastened by approximating sutures over infected intestinal punctures or the cut edges of bowel anastomoses. In this type of case, it acts merely as a mechanical patch which becomes infiltrated by the infection, and is ultimately encysted by adhesions from the omentum and other surrounding structures in much the same way that a perforated appendix is at times walled off by contiguous structures.

Detached omental grafts find a wide field for their usage. They are a great aid in gynæcologic surgery, since they occasionally make possible conservative operations. Sometimes they serve to cover in a satisfactory manner broad ligament abrasions made while freeing an adherent ovary.

The ovary may be but slightly diseased and the patient willing to take her chances of a secondary operation through her desire for children. If the tube has been but little affected or is suitable for resection, pregnancy may be possible if one can prevent the return of the adhesions. Grafts may be used to cover raw surfaces on a uterus which has been retroflexed and bound down by adhesions, or in myomectomies which are not smoothly covered by the usual approximations, or in completing the closure of a uterus perforated during curettage.

They aid greatly in covering the mesenteric stump after extensive intestinal resection, and, after gall-bladder operations, in repairing abrasions of stomach or duodenum that cannot be sutured in a satisfactory manner. They may serve to cover the stump of the cystic duct, or in recovering areas of parietal peritoneum which have been destroyed by inflammatory adhesions, or the incisions of previous operations.

The omentum for detached grafts must be thin and of sufficient length so that the sacrifice of its tissue will not impair its physiologic function. Otherwise attached grafts only should be attempted. In rarer cases, peritoneal flaps may become available for closure. They may be taken from the parietal peritoneum, broad ligament, or other available serous surfaces.

The technique for using detached grafts deserves careful attention. Thin free edges of omentum are most suitable for grafting. These may be kept warm in the peritoneal cavity after amputation while the cut surfaces of the omentum are neatly covered. The site for transplantation need not be mechanically irritated. It should be fairly dry, since Finton and Peet have found that adhesions tend to follow transplantation on bleeding surfaces. Only the edges of the graft should be handled and with the greatest care to avoid unnecessary trauma. The graft should be firmly attached with a minimum of interrupted sutures since, if detached, the sutures are rolled up by the omentum and become involved in adhesions. The raw edges should be tucked in and buried. This may best be done by first suturing one edge with interrupted sutures of No. oo plain gut, after which the flap is turned back so as to cover the knots and sutures. The last approximating knots and sutures must lie exposed in the peritoneal cavity. They therefore, should be the finest which can be tied firmly in very small knots. When grafts are used to cover intestinal abrasions or resection incisions, they should not be fixed to the mesentery if it can be avoided. Finton and Peet have shown that in their series of such cases the mesenteric attachment was usually the only seat of adhesions.

The use of other abdominal structures as flaps. The pelvis may be cut off from the abdomen and be made extraperitoneal by sutur-

ing the free edge of the sigmoid loop across the pelvis to the anterior peritoneum. If the uterus and adnexa have been removed, it should be sewed to the broad ligament and bladder peritoneum. If the uterus remains, the sigmoid may be sewed to the broad ligament peritoneum and

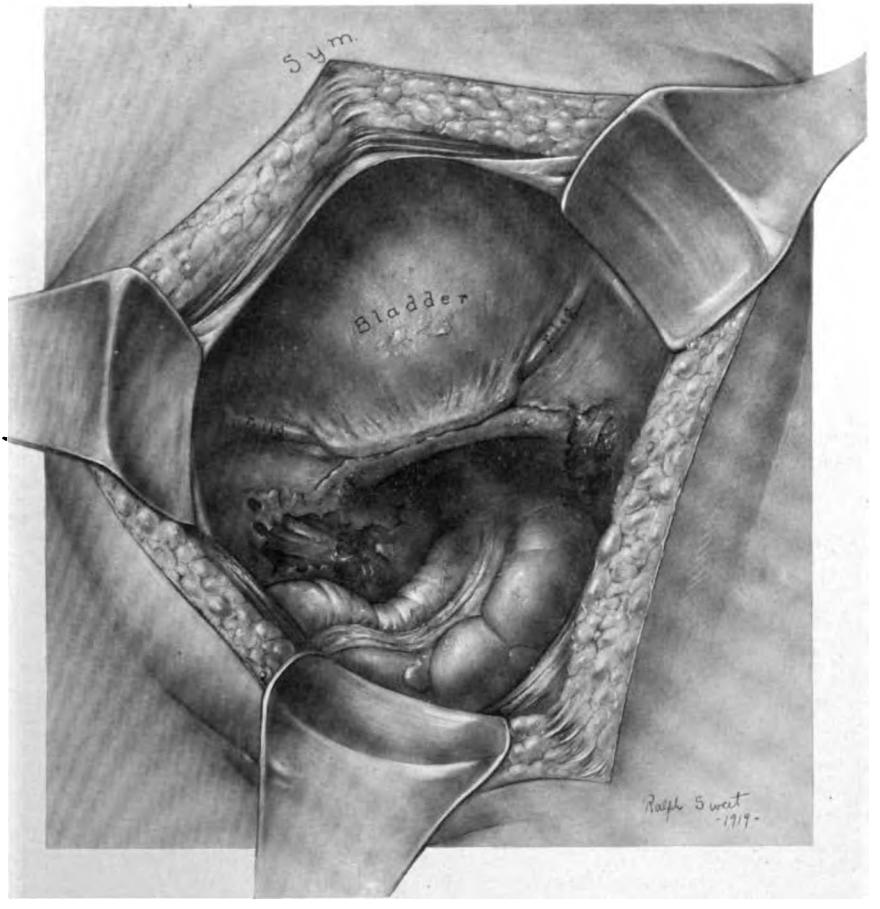

FIG. 88. PELVIC PERITONEUM AFTER REMOVAL OF THE UTERUS AND ADHERENT PUS TUBES.

base of the uterus. Occasionally the cæcum may be used in the closure, after the appendix has been removed.

The sigmoid has long been so used by a few men for such closure, yet the procedure has not as yet become universal. Snegireff and Quénu urged its adoption in 1899, and Webster, Summers, Murphy, and

others in this country have described its advantages. It has also formed the theme of discussion in gynæcologic congresses. No case of obstruction has been observed to follow in many hundreds of cases.

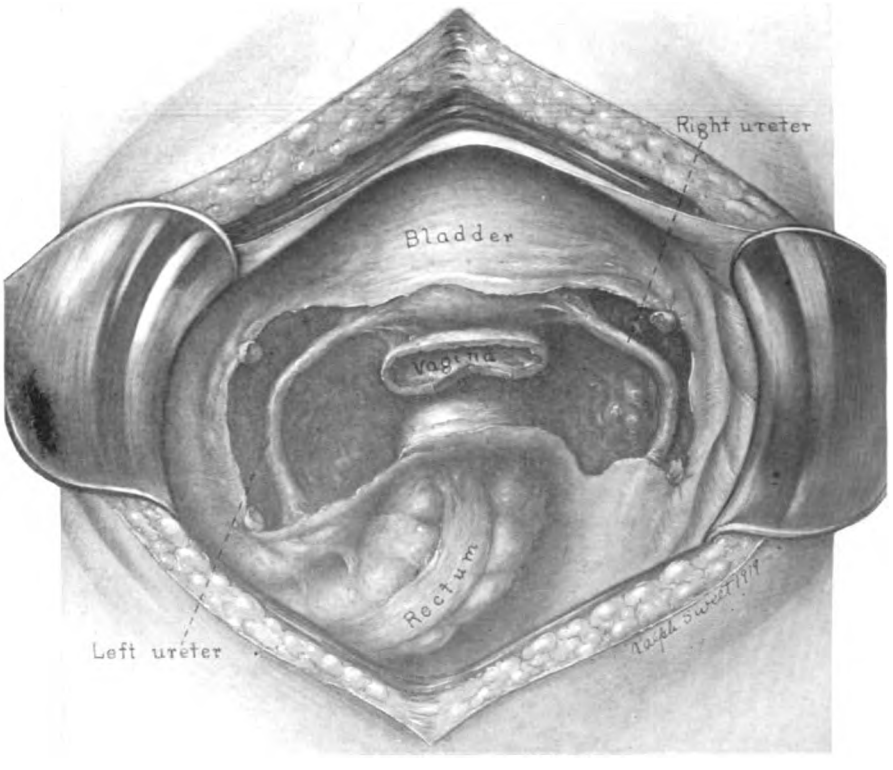

FIG. 89. PERITONIZATION AFTER PANHYSTERECTOMY. Raw surfaces left following the removal of a cancerous uterus.

This technique is indicated when there result after pelvic operation raw areas which are too large to cover by suture (Fig. 88), or which are not suitable for grafting, or which demand vaginal drainage because of infection. It is especially indicated when dealing with widespread pelvic infections of tuberculous, streptococcic, or gonococcic origin. It is most suitable for closing the wide areas of denudation which follow a proper removal of cancer of the uterus (Figs. 89, 90, 91, 92) or the

rectum. Since the freely movable sigmoid will probably be used by nature to complete the walling-off process, there is every reason for causing a chosen line of adhesion. We prevent by such means the possibilities that the sigmoid may become fixed in a kinked position, and subsequently cause obstruction, that the ileum may prolapse upon the

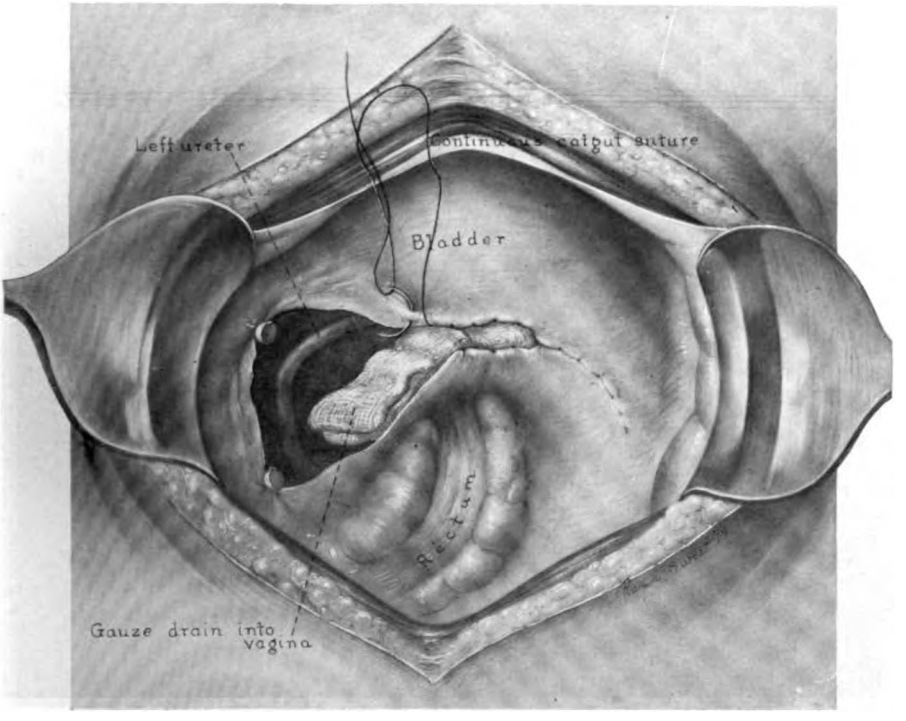

FIG. 90. PERITONIZATION AFTER PANHYSTERECTOMY. Suture of the anterior and posterior peritoneal flaps to the corresponding vaginal margins.

raw edges and there adhere, or that infection may extend upward and invade the abdominal cavity. Suture of the sigmoid helps us to leave smooth surfaces within the abdominal cavity.

Other portions of the bowel may also be used as flaps. The ileum immediately adjoining the cæcum is often involved in right-sided inflammatory pelvic adhesions. The abrasions created by its removal may sometimes be best covered by suturing them to the cæcum, after removing the appendix in such a manner that constriction of the lumen may not result.

A senile uterus may often be sewed in a retroverted position to aid in the closure after the removal of cancer of the rectum.

Chemical methods for preventing adhesions. Quite recently many men have been attracted to the study of the treatment of peritoneal

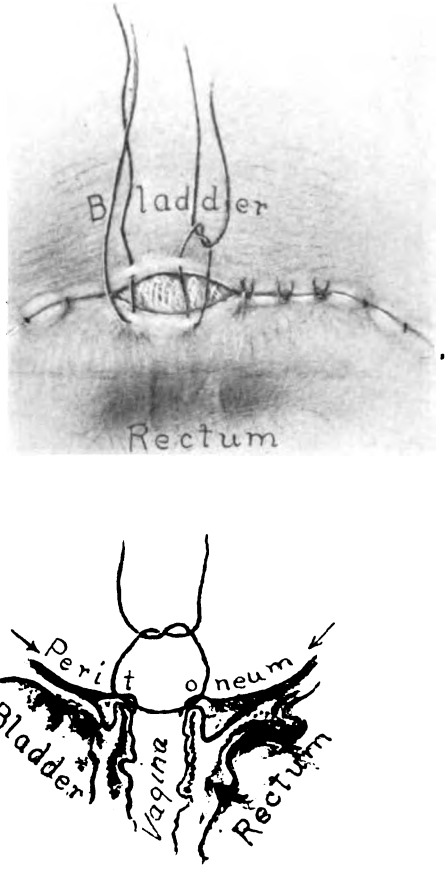

FIG. 91. PERITONIZATION AFTER PANHYSTERECTOMY. Closure of the peritoneal cavity by interrupted sutures.

infections by chemicals in the hope of combating the infection without exciting more adhesions. Good results, however, are wanting, as they are with similar treatment of deep-lying infections in other parts of the body.

Peritoneal adhesions are nature's method of preventing the direct extension of peritoneal infection. They result in all cases which are able to react to the presence of infection. Unless the chemicals overcome the infection, prevention of adhesions must result in disaster.

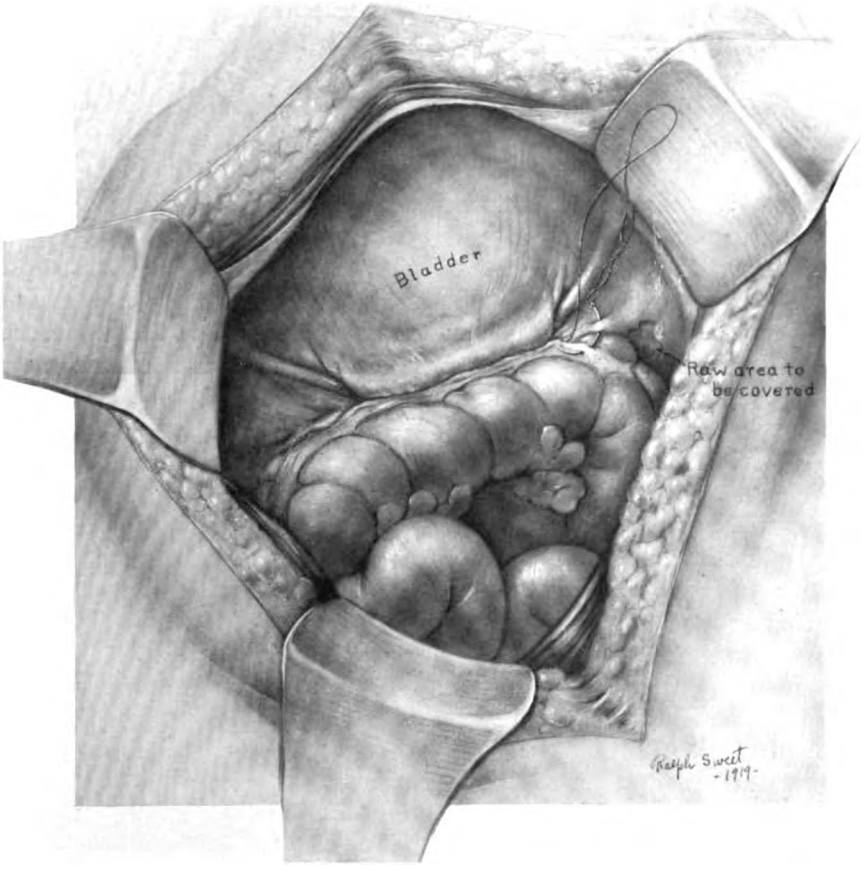

FIG. 92. PERITONIZATION AFTER PANHYSTERECTOMY. Suture of the sigmoid colon over raw areas.

Various antiseptics have been used experimentally without result other than to augment both the peritonitis and adhesions. Ether alone has seemed to be a possible exception. Favorable reports of its use in man have been made by de Tarnowsky, Dergnanc, Waterhouse, Philip, Tartois, and Lundholm. In animals, however, ether is an almost certain

cause of adhesions, and clinical application should not be attempted until further experimental investigations have been carried out.

More rational experimental work has been done with supposedly non-irritating materials with the hope of preventing adhesions following operative trauma in the absence of infection. Many have found, however, that vaseline, lanolin, albolene, and paraffin oil are irritant and cause numerous peritoneal adhesions. There is a possibility that olive oil is not irritant, but there is as yet not sufficient evidence to warrant its adoption in surgery.

A more rational treatment for preventing adhesions in the absence of infection is Pope's use of sodium citrate solution. This investigator found that, in rabbits it appeared to prevent adhesions from operative trauma. He states, "it is not assumed that citrate solutions will prevent adhesions where large denuded areas of the peritoneum are exposed. . . . that these laboratory results seem applicable only as a mild preventative during abdominal operations which ordinarily tend to leave more or less agglutination and troublesome postoperative adhesions." He does "not suggest that large quantities of the solution be left in the abdominal cavity," but "that the usual operating room solutions of normal salt have added to them 1 or 2 per cent of citrate of soda."

Pope's work has been confirmed by some, but denied by Sweet, Chaney and Wilson, Strauss, and others, who did not, however, invariably work with sterile technique nor with identical percentages of the solution. The work was done on dogs, whose peristalsis is much more vigorous than that of rabbits. Sweet, Chaney and Wilson state that the solution is apt to retard the healing of the wounds.

Since Pope's original work, men have ceased to leave salt solution in the abdominal cavity after operation. His method does not yet appear ready for universal adoption because of the conflicting evidence. The field for its employment will be narrow if one avoids unnecessary trauma in surgery and takes proper care to peritonize abrasions.

SECTION VIII

OPERATIONS FOR DISEASES OF THE OVARY

BY

SIR JOHN BLAND-SUTTON, F.R.C.S. (Eng.), Lieutenant-Colonel R.A.M.C.(T.)
Surgeon to the Middlesex Hospital

CHAPTER I

OVARIOTOMY

Ovariotomy signifies the removal through an abdominal incision of cystic and solid tumours of the ovary, and parovarian cysts.

The history of this operation is of great interest to surgeons because it was the forerunner, so to speak, of all abdominal gynæcological operations; they followed as a natural consequence on the establishment of ovariotomy, and operations on the abdominal viscera generally are to be regarded as an extension of pelvic surgery.

It is usual to state that ovariotomy was first performed by Ephraim McDowell, of Kentucky, 1809: this is of historical interest only, for it had no effect whatever in drawing attention to the feasibility of removing ovarian cysts: it was in fact a still-born operation. The pioneers of this operation were undoubtedly Baker Brown and Spencer Wells in London, Thomas Keith in Edinburgh, and Clay in Manchester. These surgeons brought the operation out of a ' slough of despond ' and placed it on firm ground. Spencer Wells and Keith were fortunate later in their work in receiving guidance from Lord Lister's discovery of antisepsis: this, combined with the introduction of the short ligature, firmly established the operation.

The improvement in securing the pedicle has played an important part in the development of ovariotomy. McDowell tied the pedicle, but left the ligature hanging out of the wound. Doran, who has written an excellent review of this matter, ascribes the intraperitoneal method of dealing with the pedicle to the systematic advocacy of Tyler Smith. The method has been followed by brilliant results.

Baker Brown used to sear the pedicle with a cautery, and this method was adopted with great success by Thomas Keith. The method of ligature is so simple and safe that the cautery for this purpose has been long abandoned.

The operation. The preliminary preparation of the patient is described on p. 3. The following instruments are sufficient for the performance of ovariotomy, oöphorectomy, and hysterectomy: a scalpel, 12 hæmostatic forceps, 2 dissecting forceps, 2 pairs of scissors with blunt ends, 2 fenestrated forceps, a volsella, 6 curved and 2 straight needles, and silk thread (Nos. 2, 4, and 6) wound on glass or metal spools. A

Sims's speculum and a glass catheter are often useful. The Trendelenburg position is not necessary for the removal of large ovarian tumours, but it is of great advantage in removing small cysts, especially when they adhere to the floor of the pelvis. In cases where the abdomen contains free fluid, ascitic or due to the bursting of a cyst, or pus, it is a wise precaution to conduct the early stages of the operation with the patient in the horizontal position, otherwise the tilting will cause the fluid to gravitate towards the diaphragm. As soon as the fluid has been removed the pelvis may be raised if it be likely to facilitate the operation.

In the early days of ovariotomy it was the custom to tap the cyst, or in the case of multilocular tumours, to force the hand into the mass and break down the septa of contiguous loculi and allow the viscid material to escape. These devices were recommended because it was regarded as a measure of safety to extract the cyst through a small abdominal incision. Occasionally it is possible to withdraw the wall of a large single-chambered parovarian cyst, after tapping, through an incision 7 cm. in length. When the tumour is multilocular, or malignant, or full of grease or pus, it is difficult and extremely dangerous to tap it, as the material may infect the peritoneum either with septic matter or with malignant particles, and end disastrously.

For many years I have abandoned the use of clumsy trocars of all kinds and remove the tumour entire, although it may require an incision from the xiphoid cartilage to the pubes. These large incisions heal quickly, and are not more prone to hernia than the short incisions. This is the only way of ensuring the safety of the peritoneum from being contaminated by the harmful, and often malignant, contents of the cysts. In dealing with burst cysts a free incision enables the surgeon thoroughly and gently to clean the peritoneal cavity.

Access to the pelvis by the abdominal route is usually obtained by an incision in the linea alba between the umbilicus and pubic symphysis. This is known as the median sub-umbilical incision. When the tumour is very large the incision may be extended upwards above the umbilicus, even to the xiphoid cartilage. The disadvantage of an abdominal incision is the liability of the scar to yield and lead to a ventral hernia, a sequel not completely obviated by any known complex method of suture.

Some surgeons advocate an incision a little to one side of the median line, through the fibres of the rectus muscle. This should be condemned because the terminal portions of the nerves supplying the muscle are divided and this leads to its atrophy, and, in itself, is a predisposing cause of an intractable form of hernia.

With the hope of obviating post-operative hernia a transverse incision has been devised. It is made about 6 cm. above the symphysis and

involves the skin, subcutaneous tissue, and the anterior sheath of both recti. The attachment of the sheath to the linea alba is divided with scissors, and the abdomen is then opened by a median incision. The chief advantage claimed for this incision is the avoidance of post-operative hernia. There may be a sentimental advantage in the fact that when the wound is healed the scar left by the operation is concealed by the pubic hair.

In dealing with very large cysts a median incision is invariably employed. Occasionally, difficulty will be encountered on reaching the peritoneum, for, if the cyst has been infected, the peritoneum and cyst-wall may be firmly adherent and even inseparable. In these circumstances it is a wise plan to extend the incision upwards and enter the abdominal cavity well above the tumour. It is also worth while to bear in mind that when the tumour adheres to the abdominal wall it is extremely probable that a coil of intestine may be adherent also. When a tumour is impacted in the pelvis it may push the bladder upward into the abdomen; in such an event this viscus runs great risk of being opened by the surgeon when making the incision. When there is doubt concerning the position of the bladder, an assistant should introduce a sound into it through the urethra.

In a typical case, when the peritoneum is opened the surgeon at once recognizes the bluish-grey glistening surface of the ovarian cyst, and gently sweeps his hand over it in order to ascertain its relations and to learn whether the cyst-wall be free from adhesions. It is of the utmost importance to be satisfied as to the nature of the tumour, especially when the operator follows the unsatisfactory practice of tapping, for if he plunge a trocar into a uterine tumour, or into a pregnant uterus, he will involve himself in anxious difficulty. Decomposing fluid, tenacious mucus, or blood-stained fluid may obscure the parts, and should be sponged away: they indicate a ruptured cyst, a malignant tumour, or a twisted pedicle. Much free blood may be due to the bursting, or abortion, of a gravid tube. When the surgeon has satisfied himself that the cyst or tumour is free to be removed he lifts it out of the abdominal cavity, and if in this process the wall be so thin that it is likely to burst, or actually leaks, the weak spot may be freely incised with a knife over a convenient receptacle.

Adhesions. Although the surgeon may have had reasons to suspect the presence of adhesions, frequently he finds none, and on other occasions when he least expects them there are many. The most frequent adhesions are omental, and fortunately they are the least important: they should be detached and tied with thin silk. Adherent epiploic appendages require the same treatment. Intestinal adhesions require care

and patience. When the intestines are adherent by strands and bands, these may be cautiously snipped with scissors; when the adhesions are sessile and soft the gut may be gently detached by means of a moist dab; but if very firm it may be necessary to dissect off a piece of cyst wall and leave it on the gut. The vermiform process requires especial care, for it may be mistaken for an adhesion and divided. When intestines are accidentally opened in the course of an ovariotomy they require the most careful attention. Wounds in the colon may be safely sutured. Holes in adherent small intestine may sometimes be sutured, but if the gut has been extensively involved it may be necessary, and often judicious, to resect a few centimetres and join the cut ends by a circular enterorrhaphy.

Adhesions to the parietal peritoneum are as a rule easily detached with the finger. The most serious adhesions are those which occur in the depths of the pelvis, involving the uterus, bladder, or rectum, and the separation of these may entail such accidents as wounds opening the rectum or bladder, and injury to the ureters and iliac vein. The treatment of such accidents will be considered later.

The pedicle. When the tumour is withdrawn from the belly the pedicle is easily recognized: the uterine tube serves as an excellent guide to it. The pedicle consists of the uterine tube and adjacent parts of the mesometrium containing the ovarian artery, ovarian plexus of veins, lymph vessels, nerves, and the ovarian ligament. When the constituents of the pedicle are unobscured by adhesions, the round ligament of the uterus is easily seen and need not be included in the ligature.

In transfixing the pedicle the aim should be to pierce the mesometrium at a spot where there are no large veins, and tie the structures in two bundles, so that the medial contains the uterine tube, a fold of the mesometrium, and occasionally the round ligament of the uterus; whilst the lateral consists of the ovarian ligament, veins, the ovarian artery, and a larger fold of peritoneum than the inner half.

Pedicles differ greatly; they may be long and thin, or short and broad. Long thin pedicles are easily managed. The assistant gently supports the tumour, whilst the operator spreads the tissues with his thumb and forefinger, and transfixes them with the pedicle needle armed with a long piece of silk doubled on itself. The loop of silk is seized on the opposite side and the needle withdrawn. During the transfixion care must be taken not to prick the bowel with the needle. The loop of silk is cut so that two pieces of silk thread lie in the pedicle. The proper ends of the thread are now secured, and each is firmly tied in a reef-knot; for greater security the whole pedicle may be encircled by an independent ligature, taking care that it embraces the pedicle below the point of

transfixion. (I use No. 4 plaited silk for transfixing the pedicle, and a piece of No. 6 silk for surrounding it.)

After the operator has gained some experience in this simple mode of tying the pedicle, he may, if he thinks it desirable, practise other methods.

After securely applying the ligature the tumour is removed by snipping through the tissues on the distal side of the ligature with scissors. Care must be taken not to cut too near the silk, or the stump will slip through the ligature; on the other hand, too much tissue should not be left. The stump is examined to see that the vessels in it are secure and allowed to retreat into the abdomen. Should it begin to bleed it must be caught with forceps, drawn up, re-transfixed, and tied below the original ligature.

Occasionally a pedicle will be so broad that it is unsafe to trust to this simple form of ligature. Broad pedicles will require three or more ligatures. When several ligatures are required it is important to remember that the ovarian artery lies in the lateral fold of the pedicle and the uterine artery at the medial end, and it is often possible to secure these vessels separately with a thin piece of silk. The pedicle can then be secured with a series of interlocking ligatures. This method is known as the 'mass-ligature.' Many surgeons are dissatisfied with it, and secure the pedicle in the following manner:—

The tumour is raised in order to make the pedicle taut; the peritoneum covering it is incised in order to expose its vessels; these are caught with forceps and the tumour detached. The vessels are tied separately with silk or catgut. The cut edges of the peritoneum are then sewn over the stump. This method diminishes the risk of hæmorrhage from slipping of a ligature.

When an ovarian tumour has undergone axial rotation and has tightly twisted its pedicle, the ligature should be applied to the torsioned area; a single ligature is then sufficient.

It is impossible to frame absolute rules for ligaturing the pedicle. In this, as in all departments of surgery, common-sense must be exercised, and at the present day, when ovariotomy is practised so widely, no one would think of performing this operation without assisting at one, or watching its actual performance by an experienced surgeon.

Having satisfied himself that the pedicle is secure, the surgeon examines the opposite ovary, and if obviously diseased it should be removed. Any blood or fluid in the recesses of the pelvis is sponged up. Whilst employed in this way the surgeon gives instructions to have the dabs and instruments counted. When the operator limits the number of dabs to six he can easily have them displayed before him.

It is the custom with most surgeons before suturing the wound to make a careful survey of the abdominal organs. This systematic examination leads to the discovery of many accidental complications of ovarian cysts; some are curious only, but others are of importance in the future conduct of the case.

Suture of the abdominal incision. The following method gives very satisfactory results:—

The peritoneum, sheath of the rectus and the edge of the rectus abdominis, skin, and fascia are carefully approximated by interrupted sutures of silk (size No. 4), sterilized by being boiled for an hour and inserted with the hands covered with sterilized rubber gloves. This is known as the through-and-through method of suture; the distance between each suture is rather less than two centimetres. Before the silks are tied, interrupted sutures of silk (No. 2) are used to bring the fascia together; these are introduced at intervals of three centimetres, or less when the abdominal walls are very thin. Before introducing these sutures the surgeon washes his gloved hands in a solution of perchloride of mercury (1 in 5,000). When the main sutures are tied the skin edges are carefully approximated by a continuous suture of thin silk. A wound sutured in this way heals quickly and soundly. Some of the sutures are removed on the eighth and the remainder on the tenth day. The excessive use of buried sutures in the abdominal wall is a cause of post-operative thrombophlebitis and pulmonary embolism (see p. 19).

In the mere description of ovariotomy little attention is given to the complications of the operation arising from variations in the character of the cysts; these influence the procedure in many important particulars. Some tumours of the ovary are as solid as uterine fibroids, others are merely thin sacs filled with fluid of nearly the same specific gravity as water. Many contain a material of the consistence and colour of jelly, a few are filled with blood; some are crammed full of soft dendritic warts; dermoids are stuffed with sebaceous matter, or filled with oil; occasionally a cyst contains pus. As the results of ovariotomy depend in some measure on the nature of the cysts or tumours, it will be useful to offer some remarks on the chief varieties.

Suppurating ovarian cysts. Suppuration of an ovarian cyst is a recognized, though rare, complication of this disease; it seems somewhat difficult to understand how ovarian cysts become infected, enclosed as they are in air-tight cavities and having no communication with other organs. Many years ago I satisfied myself that the principal sources of infection are the uterine tube, the intestine, the vermiform process, tapping and puncture by foreign bodies. To these we must add infection

by the blood-stream in systemic diseases of infective origin, such as typhoid fever.

Typhoid infection of an ovarian cyst. It has been known for many years that ovarian cysts may be infected with the *Bacillus typhosus.*

In 1907, I removed a large plum-coloured ovarian cyst from a woman who had been treated for typhoid in India a year previously. I suspected that the cyst contained pus and removed it with great care. Mr. Frank E. Taylor obtained from the pus in this cyst a bacillus in pure culture which in its morphological, tinctorial, cultural, and serum-agglutinating properties was definitely proved to be *B. typhosus.* The patient's serum gave the agglutination test with typhoid bacilli.

In a more remarkable case, I removed a suppurating and leaking ovarian dermoid in which the *B. typhosus* had probably existed in the cyst sixteen years.

It is worth mention that among the ovarian tumours infected by the *B. typhosus* many of them were dermoids. Coe, in reporting an example, suggests that the sebaceous material forms a favourable medium for the development of this bacillus.

The presence of the typhoid bacillus as a saprophyte in a suppurating ovarian cyst, many years after a woman had passed through an attack of typhoid fever, ceases to astonish us now we know that it can live in the gall-bladder many years. In the remarkable case described by Dean it was demonstrated in the gall-bladder twenty-nine years after an attack of typhoid fever. There is one gratifying aspect in the surgical treatment of ovarian cysts infected with the typhoid bacillus—the majority of the patients survived ovariotomy and remained in good health.

The most remarkable example of suppurating ovarian cyst which has come under my notice occurred in a woman who had an ovarian cyst, as big as a Jaffa orange, incarcerated in the pelvis by a uterus which contained several fibroids. The cyst burst during removal, and, in the course of detaching it from the rectum to which it adhered, I found a fish-bone projecting from the rectum into the cavity of the ovarian cyst. The uterus was removed with the ovarian cyst. The pelvis was drained by means of a tube in the vagina. The patient recovered.

Paterson operated on a girl aged ten years expecting to find an appendix abscess, but found a suppurating ovarian cyst, a rare condition in girls, but in this instance it was probably caused by hairpins which were found impacted in the vagina.

Axial rotation of ovarian cysts. This is a matter of extreme interest to the surgeon, for when an ovarian tumour of moderate size

rotates and twists its pedicle, in the form known as acute axial rotation, it gives rise to the severe symptoms common to a strangulated hernia, minus stercoraceous vomiting. Even fæcal vomiting does not always negative the existence of acute axial rotation of an ovarian tumour, for a loop of bowel is sometimes involved in the twist.

It is a matter which surprises the surgeon when he opens the abdomen expecting an acutely inflamed, or a perforated vermiform process, or an obstructed intestine, but finds a black mass which he gradually recognizes as an ovarian cyst which has twisted its pedicle.

A rarer complication is an ovarian cyst which has suddenly increased in bulk, and become tender, painful, and produces all the clinical symptoms of a twisted pedicle. On opening the abdomen, there is no evidence of axial rotation. The surgeon should examine such a cyst carefully, for these signs are sometimes due to free intracystic bleeding.

Cyst-adenoma. (*Multilocular glandular cyst.*) This is a common variety, and some of the largest examples of ovarian cysts are of this type. Cystic masses filled with gelatinous stuff sometimes weigh eighty, one hundred, or more pounds. In their simple form these cystic masses are innocent, but there are varieties which exhibit malignant characters in a peculiar way. It happens occasionally that a loculus bursts, and the peculiar gelatinous contents of the cyst, which to the naked eye resembles jelly, escape into the belly, and as the glandular elements in the cyst-wall continue to secrete, this material accumulates and distends the abdomen. The surgeon opens the abdomen with the expectation of removing a tumour, and to his surprise finds the belly filled with gelatinous material: one who is acquainted with the condition immediately introduces his hand into the pelvis, finds the tumour, withdraws it, ligatures the pedicle, and removes as much as possible of the jelly and completes the operation. It is useless to attempt the removal of this gelatinous material by irrigation. On one occasion I removed from a woman's belly three gallons of inspissated jelly of this kind secreted by an ovarian cyst-adenoma no bigger than a coco-nut. Thirteen years later she was in good health. In contrast to this the following facts are important:—

I removed from a woman, aged 51, a cyst-adenoma the size of a football. Two years later she came under observation again with a tumour in the opposite ovary which had burst and filled the belly with gelatinous stuff. Six years later she came again to me with the abdomen enormously distended with jelly: after this had been removed, I noticed that the peritoneal investment of the intestines and the organs generally were beset with a multitude of minute nodules. On microscopic examination these nodules contained active epithelium like that found in the cyst-adenoma. These engrafted nodules had furnished the jelly.

The woman reported herself three years later and was in good health. I then lost sight of her after observations extending over 13 years.

It occasionally happens that the vermiform process becomes distended with gelatinous material indistinguishable from that found in ovarian cyst-adenomas. Sometimes the distended process ruptures and the gelatinous material escapes into the abdomen, sometimes in large quantity. On three occasions I have found a vermiform process stuffed and distended with colloid material in women who had bilateral ovarian cyst-adenomas. These gelatinous cysts of the ovaries occur most commonly after the age of 40. They are usually bilateral. Among the pioneers of ovariotomy the effects produced by the extravasation of the gelatinous material on the omentum led them to describe the condition as colloid of the omentum, or colloid cancer. Among other names applied to it is Pseudomyxoma of the Peritoneum. Now we know the source of the material these fanciful names may be dropped with advantage.

Ovarian dermoids. These common tumours of the ovary leak occasionally, spontaneously, from thinning and slow rupture of their walls, or the cyst-wall is sometimes burst by violence. This allows the sebaceous material which such cysts contain, as well as the shed hair and epithelium, to accumulate within the abdomen. The surgeon will be puzzled when he encounters the condition for the first time. Lucy described a remarkable example: An ovarian dermoid leaked and so filled a woman's belly with sebaceous paste that it pitted as if it were plastic clay when pressure was made upon it with the finger. He removed, at the operation, eleven pounds of pultaceous sticky stuff. A number of cases have been reported in which the epithelial material extruded into the abdominal cavity from ovarian dermoids has engrafted itself on to the peritoneum, so that when the surgeon opened the abdomen he was surprised to find the intestines and omentum beset with nodules, many of them furnished with a tuft of hair. These 'epithelial weeds' differ from secondary cancerous nodules in remaining as grafts on the peritoneum, they do not penetrate the underlying tissues, nor display invasiveness which is such a marked attribute of the cancerous nodule.

To dissemination of this kind I applied the term epithelial infection. In a recent case described by Randall and Laurence the leakage occurred from a hole caused by tapping the dermoid.

A much more serious condition faces the surgeon when he attempts to remove a malignant ovarian teratoma. These occur in infants, girls, and young women. The metastatic nodules contain epithelium, neuro-epithelium, skin, cartilage, nerve-ganglia, medullated nerves, &c. These

tumours are very malignant, recur rapidly after removal, and destroy life in a few months.

It is believed by some writers that organs like mammæ sometimes found within an ovarian dermoid may become the seat of malignant disease. Of this there is no proof, but ovarian dermoids, like other forms of ovarian cysts, may become the seat of implanted cancer (see p. 219).

Ovarian fibroids. Tumours occasionally arise in the ovary which in their naked-eye and microscopic characters are indistinguishable from the common form of the hard uterine fibroid: they undergo similar degenerative changes, become cystic, and calcify. Ovarian fibroids are encapsuled tumours, and present smooth contours. They may be unilateral or bilateral, the former is more common. They are occasionally complicated with hydroperitoneum, and, except in this circumstance, they rarely produce any very obvious impairment of health. An ovarian fibroid has been observed as early as the nineteenth year, even at this early age it was calcified, and as late as the seventy-third year. A calcified ovarian fibroid has been known to obstruct labour (Soutar). There is every reason to believe that a fibroid may arise in the ovary long after the menopause; this distinguishes the ovarian from the uterine fibroid.

In 22 cases under my own care the youngest patient was 27, and the oldest 73. In one patient the tumour had a twisted pedicle, and in another the tumour complicated pregnancy. In three patients the tumours were bilateral and in two of them I removed the uterus also; they made satisfactory and permanent recoveries.

One of the difficulties connected with solid ovarian tumours, especially those called fibroids, has been the absence of after-histories concerning those patients who have been submitted to operation. This defect has been removed by the publications of Doran, Briggs, and Fairbairn. I followed up ten of my patients. Nine were alive at intervals varying from one to six years after the operation. One died three months after ovariotomy from a chronic affection of the lung and pleura.

The results of careful inquiries into the after-history of patients who have had ovarian fibroids removed, clearly prove that these tumours are as innocent as the common varieties of uterine fibroids. The immediate result of the removal of such tumours is excellent, even when they are associated with hydroperitoneum. The ovarian fibroid was formerly regarded as a sarcoma.

Sarcoma of the ovary. The ovaries, like other paired organs, are prone to become the seat of sarcoma in early life. Some years ago I collected a hundred recorded cases of ovariotomy in girls under 15 years

of age. Of this series, 41 were simple cysts or adenomas; 38 were dermoids; and 21 sarcomas. This, however, is far short of the real proportion of sarcomas, because there are many records in which no operation was undertaken, the descriptions being based on post-mortem examinations.

The mortality among ovarian sarcomas in children submitted to operation is very high. In the collection of records referred to above, 7 of the 21 patients died, and of the 14 which recovered, I ascertained that 4 died with recurrence within a year of the operation. The youngest child on record who has been operated upon for sarcoma of the ovary was aged 33 months. She died a few hours after ovariotomy (Hoffman).

There is need of some new records in relation to sarcoma of the ovary in women. The careful observation which enabled the solid tumours of the ovary—ovarian fibroids—to be removed from the sarcoma group vitiates the older records. Previously all solid ovarian tumours were called sarcomas.

Papillomatous (papilliferous) cyst. This is an important species of ovarian cyst, because it often puzzles the beginner in pelvic surgery. In the early stage the papillomatous processes are strictly confined within the cyst, but as they grow, bud-like processes perforate the cyst-wall, irritate the peritoneum, and lead to hydroperitoneum. Sometimes the cyst is so stuffed with dendritic growths that the walls of the cyst burst, and the tumour has the appearance of a luxuriant cauliflower. Fragments of the epithelial processes are dispersed through the abdomen and infect the peritoneum.

It sometimes happens that the amount of free fluid in the abdomen is so great, that the surgeon, finding a luxuriant sprouting mass in the pelvis, hastily comes to the conclusion that the tumour is malignant, and closes the abdomen under that impression. This is unfortunate, for the removal of these papillomatous masses is, as a rule, attended with great advantage to the patient.

In 1906 a young woman was admitted into the Cancer Wards of the Middlesex Hospital with her abdomen so enormously distended with fluid that there was a cystic protrusion at each femoral ring, the inguinal canals, and the umbilicus. There was a recent median scar in the abdominal wall below the umbilicus. The patient had been operated upon by a gynæcological surgeon of repute, but he did not remove the cysts. The patient's condition was deplorable, so I reopened the abdomen and removed the papilliferous masses with the ovaries. She made a good recovery, left the hospital, and renewed her work as a dressmaker. She died five years afterwards with some obscure intra-thoracic condition.

One of the most remarkable examples of papillomatous cysts on record is described by Pye-Smith: A woman was tapped for hydroperitoneum between August 1884 and April 1894, 299 times. She was readmitted into Guy's Hospital for her 300th tapping and died. At the post-mortem examination a papillomatous cyst was found in connexion with each ovary. These cysts could have been easily removed. The peritoneum was beset with warts. Even when the peritoneum is covered with warts operative interference does good, and the sprouting epithelial processes disappear after the main masses are removed.

I have removed many papillomatous cysts with good consequences during the past twenty-five years and most of them have made complete and durable recoveries. In a few cases I have removed the uterus also. In two cases the growth recurred in the pelvis five years after the primary operation. I operated again and found a large cyst as big as a coco-nut unconnected with the pelvic structures. In each instance it was easily enucleated and the patients recovered.

The most remarkable case in my series is the following: I removed from a woman a pair of papillomatous ovaries and the uterus. There was an abundant hydroperitoneum, and the pelvic portion of the peritoneum was beset with soft dendritic warty masses. The patient recovered, but came under my care six years afterwards with a soft tumour growing from the right side of the sternum, level with the second intercostal space. The tumour was soft and movable. The tumour was as big as a ripe plum. I excised it and found the lump to be cystic and stuffed with soft papillomatous processes such as occurred in the ovaries. On careful examination I failed to find any other evidence of recurrence in the abdomen or thorax.

Pozzi has reported a case in which a papillomatous mass recurred in the pelvis 20 years after bilateral ovariotomy for this disease. He holds the opinion that it is a great advantage to operate on recurrent tumours of this kind, as it is attended with distinct advantage to the patient even when the tumour cannot be completely removed.

The experience of surgeons in connexion with papillomatous cysts of the ovaries teaches that the presence of free fluid in the belly in association with a pelvic tumour, although a suspicious, is not always a sinister sign, and it is wise to give the patient the benefit of an operation. Papillomatous cysts sometimes attain a great size without bursting.

I removed an enormous example from a spinster, aged thirty-three. The tumour had been noticed for fifteen years, and at last it became so cumbersome that she insisted on its removal. She had been allowed to retain it so many years under the impression that it was a cystic uterine fibroid. The tumour was exposed by incision extending from the ensiform cartilage to the pubes. It could not be extracted entire even

through this long incision, but after two gallons of fluid had been run off the tumour slipped out. It proved to be a unilocular papillomatous cyst weighing seventy pounds and the cyst-wall was covered with dendritic warts. The opposite ovary contained a papillomatous cyst, and in addition each ovary was occupied by a dermoid as big as an orange. The patient recovered, and was in good health eight years afterwards, and free from any evidence of recurrence.

Carcinoma of the ovary. When a woman is attacked by cancer in the gastro-intestinal tract, gall-bladder, breast, or uterine tube, the cancerous cells permeate the adjacent tissues and escape into the abdominal cavity, and floating in the peritoneal fluid find their way into the pelvis. If the woman be so unlucky as to have an ovarian cyst or dermoid in the pelvis, the cells deposited on the cyst-wall will engraft themselves and grow into blocks of cancer. Many large solid tumours of the ovary, unilateral and bilateral, which exhibit the structure peculiar to cancer and formerly regarded as arising primarily in the ovary, are in truth secondary to cancer in some other organs. The relationship of the ovarian masses to the primary cancer is demonstrated by the fact that the minute structure of the tumour in the ovary varies according to the situation of the primary tumour. Malignant metastatic masses of this kind are known as Implantation Cancer. The subject is of great importance to the surgeon, for when he undertakes an operation for the removal of solid or semi-solid tumours of the ovary, especially when bilateral, and accompanied by vomiting, it is incumbent on the surgeon to make a careful examination of the gastro-intestinal tract and the gall-bladder. In many of these cases a cancerous focus will be found at the pylorus, in the cæcum, or sigmoid colon. Implantation cancer of the ovary secondary to a cancerous breast is sometimes a mass as big as the patient's head.

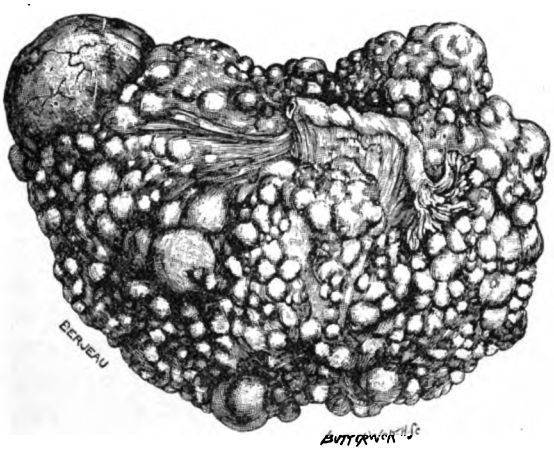

FIG. 93. SECONDARY CANCER OF THE OVARY. An ovary converted into a solid mass of cancer secondary to a focus in the sigmoid colon: it weighed 5 lb. Two-fifths size.

On opening an abdomen and finding one or both ovaries enlarged by

metastatic cancer, it is the duty of the surgeon to make a careful search for a primary focus, and if it be inoperable, it would be unwise to continue the operation. Occasionally the implantation masses are so big and cause so much distress that it adds to the patient's comfort to remove them. When the primary focus is a small contracting cancer in the colon, especially in the sigmoid colon, or near the ileo-colic valve, it may be easily missed.

A study of the after-results of ovariotomy shows that many patients have died some months after the operation from intestinal obstruction. The new knowledge indicates that many were, in all probability, primary cancers overlooked in the course of the ovariotomy.

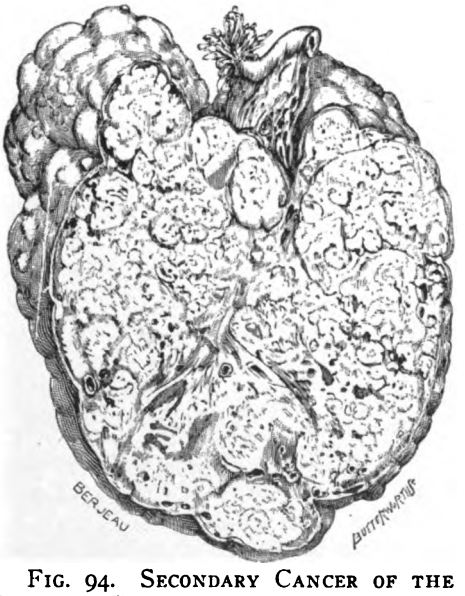

FIG. 94. SECONDARY CANCER OF THE OVARY IN SECTION. This is a section of the ovary represented in the preceding figure. Half size.

Cysts of the broad ligaments. Occasionally the surgeon on opening the abdomen finds that the cyst or tumour is situated between the layers of the broad ligament. Sessile cysts of this kind are removed by what is known as enucleation. The peritoneum overlying the cyst is cautiously torn through with forceps until the cyst-wall is exposed; then by means of the forefinger the surgeon proceeds to shell the cyst out of its bed, taking care not to tear the capsule or any large vein in its wall; it is also necessary to exercise the greatest care to avoid injury to the ureter. It is not uncommon, after enucleating a cyst in this way, to find the ureter lying at the bottom of the recess. (For treatment of an injured ureter see p. 32.)

When the enucleation is completed the walls of the capsule are carefully examined for oozing vessels which require ligature. The capsule can often be closed in such a way as to bring its walls into apposition and thus obliterate its cavity; it then requires no further attention. When there is much oozing the capsule is treated on the plan known as marsupialization. The edges of the capsule are brought to the lower angle of the abdominal wound and secured with sutures, and a drain, either of gauze or a rubber tube, is introduced, and the remainder of the wound closed in the usual manner.

Enucleation is usually accompanied by more loss of blood than simple ovariotomy; this, and the prolonged manipulation, is often responsible for severe shock.

Spurious capsules. It is necessary for the surgeon to remember that an ovarian cyst, and especially an ovarian dermoid, is sometimes invested by a spurious capsule. It is now well known that slow effusions of blood, tuberculous exudations, hydatid cysts, and ovarian cysts become enclosed in capsules of fibrous tissue formed by the organization of the peritoneal exudation which their presence excites. These capsules are often so firm, and so completely encyst the fluid exuded into the pelvis in cases of tubal tuberculosis, that such encapsuled collections of fluid resemble, and are often mistaken for, ovarian cysts. It is also necessary to mention that true ovarian cysts project from, but never invade, the layers of the broad ligament. From time to time cases are reported in which ovarian cysts, especially dermoids, have been found between the layers of the broad ligament: such are in all probability instances in which a false capsule has formed around the cyst, and the surgeon committed an error of observation in regarding it as a layer of the broad ligament.

Incomplete ovariotomy. The surgeon may start an operation and, after opening the abdomen, may find many adhesions, yet he feels that the removal of the tumour is possible. He sets to work and overcomes many of the difficulties, but finds at last such extensive pelvic adhesions that it is imprudent to proceed further. In such cases he evacuates the contents of the cyst and stitches the edges of the opening in the cyst to the margins of the abdominal wound, and drains the cavity. This mode of dealing with a cyst is usually termed 'incomplete ovariotomy.'

An incomplete ovariotomy is a very different operation from an enucleation. The cavity left after enucleation closes completely, but when the wall of the ovarian cyst or adenoma is left the tumour gradually grows again, or it may suppurate so profusely that the patient slowly dies exhausted. There are few things sadder in surgery than the slow, miserable ending of an individual who has been subjected to an incomplete ovariotomy.

Anomalous ovariotomy. In a few instances, generally under an erroneous diagnosis, surgeons have removed ovarian tumours through an opening other than the classical one known as the median sub-umbilical incision. Under the impression that the tumour was splenic, an ovarian tumour of the right side has been successfully removed through an incision in the left linea semilunaris (R. W. Parker). An ovarian tumour, supposed to be a renal cyst, has been successfully extracted through an incision in the ilio-costal space (Le Bec). Strangest of all, a small

ovarian dermoid has been removed through the rectum under the impression that it was a polypus of the bowel (Stock, Peters).

Hysterectomy after bilateral ovariotomy. After the removal of both ovaries for cysts or tumours, the uterus is a useless organ: it is fast becoming the practice under such conditions to remove it. There is much to be said in favour of this procedure, especially if the uterus be large and flabby, because it tends to fall backwards into the pelvis. In such circumstances it is better surgery to remove it than to perform hysteropexy. The risk of intestinal obstruction after bilateral ovariotomy is greater than after hysterectomy. Cases are known in which cancer has attacked the uterus years after bilateral ovariotomy and oöphorectomy (see p. 140).

Repeated ovariotomy. Very many cases are known in which women have been twice submitted to ovariotomy. Thus it is the duty of the surgeon when removing an ovarian tumour to examine carefully the opposite ovary. So many examples are known of women who have borne children after unilateral ovariotomy (twins and even triplets) that this alone is sufficient to prohibit the routine ablation of both glands.

A second ovariotomy is not attended with more risk than a first ovariotomy. The abdominal incision must be made with extra caution, because intestine may be adherent to it and runs a risk of being wounded. In some instances the cicatrix is very thin, and the surgeon cutting through it is liable to cut the intestine before being aware that the knife has entered the abdomen.

Some surgeons recommend that in a second ovariotomy the opening may with advantage be made a little to one side of the original incision.

Cases have been reported in which patients have been thrice submitted to ovariotomy: in such instances it is probable that one of the tumours was a sessile broad-ligament cyst.

Pregnancy after bilateral ovariotomy. It is an interesting fact that several cases have been carefully reported in which women who have had bilateral ovariotomy have subsequently become pregnant. This event has been explained by assuming that in some of the patients a portion of at least one ovary has been left. This meets with more favour than the idea of the existence of a supernumerary ovary. The cases have been collected by Doran.

Ovariotomy at the extremes of life. Cysts and tumours arise in the ovary during intra-uterine, and at all periods during extra-uterine life, even in extreme old age: they also attain such dimensions in infants and old women as to demand the aid of the surgeon, and with excellent results. Many years ago I collected the recorded cases and

tabulated one hundred instances in which ovariotomy had been performed in infants and girls under fifteen years of age. These tumours fall into three groups:

Simple cysts and cyst-adenomata	. .	41 with	3 deaths.
Dermoids	. . . . .	38 "	5 "
Sarcomata	. . . . .	21 "	7 "

In the case of simple cysts, adenomata, and dermoids, the results are encouraging. It is possible that some of the cases described as sarcomata belonged to the deadly group now known as malignant teratomata.

Ovarian tumours sometimes attain large dimensions in children, and Keen reported a case in which he removed an ovarian tumour from a girl which weighed 44 kilograms: the girl weighed 27 kilograms after the operation. An ovarian cyst with a twisted pedicle has been found in a fœtus at birth (Otto von Franque).

The subjoined table shows cases in which ovarian tumours have been removed from infants under three years of age. It is often stated that Professor Chiene performed ovariotomy on an infant of three months. This is an error; it was an ovary occupying the sac of an inguinal hernia.

OVARIOTOMY IN INFANTS.

	Reporter.	*Age.*	*Result.*	*Nature of Tumour.*	*Reference.*
1	D'Arcy Power	4 months	R.	Dermoid	*Trans. Path. Soc.*, xlix. 186.
2	MacGillivray	11 months	R.	Cyst	*Lancet*, 1907, i. 1487.
3	Roemer	1¾ years	R.	Dermoid	*Deutsche Med. Woch.*, 1883, ix. 762.
4	Péan	2 years	R.	Dermoid	*Clin. Chir.* 1887–8, 8th series.
5	Hooks	2½ years	D.	Dermoid	*Am. J. of Obst.*, 1886, xix. 1022.

Ovariotomy in old age. In 1891 I was able to find twenty-two records of successful ovariotomy in women over seventy years of age. Since that date Howard A. Kelly and Mary Sherwood made a collective investigation, and succeeded in obtaining notes of one hundred cases of ovariotomy performed on women over seventy years of age: the death-rate amounted to 12%.

The subjoined table concerns itself with ovariotomy performed on women after the age of eighty years, and the results are remarkable, notwithstanding the circumstance that these women of eighty years and upwards must have been blessed with a stronger constitution than their contemporaries.

OVARIOTOMY IN WOMEN OF EIGHTY YEARS OF AGE.

	Reporter.	*Age.*	*Result.*	*Reference.*
1	Owens	80	R.	*Brit. Gyn. Soc. Journal*, iv. 88.
2	Richardson	80	R.	*Brit. Med. Journ.*, 1894, i. 523.
3	Heywood Smith	81	R.	*Lancet*, 1894, i. 1618.
4	Spencer	82	R.	*Brit. Med. Journ.*, 1893, ii. 1271.
5	Homans	82	R.	*Bost. Med. and Surg. Journ.*, 1888, 454.
6	Edis	81	R.	*Brit. Med. Journ.*, 1892, i. 860.
7	Bush	84	R.	Ibid., 1894, ii. 67.
8	Remfrey	83	R.	*Trans. Obstet. Soc.*, xxxvii. 152.
9	Kraft	84	R.	*Hospitalstidende*, Copenhagen.
10	Owens [1]	87	R.	*Lancet*, 1895, i. 542.
11	Thornton	94	R.	*Trans. Obstet. Soc.*, xxxvii. 158.
12	Bland-Sutton	85	R.	Middlesex Hospital.

Mortality. The death-rate after ovariotomy is hard to estimate, especially as surgeons differ widely in their mode of classifying the tumours. In the simple and uncomplicated forms of ovarian cysts and tumours the operation should be almost free from risk. Many surgeons, excluding malignant conditions, have had lists of a hundred operations with no deaths.

In order to afford some notion of the relative frequency of the various cysts and tumours classed as ovarian, I made a list of one hundred consecutive examples which I removed at the Chelsea Hospital for Women:

Fibroids	2	Dermoid	15
Sarcoma	2	Papillomatous cyst	2
Carcinoma	1	Parovarian	5
Simple Cyst	45	Tubo-ovarian	3
Cyst-adenoma	25		

The case of carcinoma was an implanted cancer; the primary tumour arose in the pyloric region of the stomach, both ovaries were implicated, The three cysts classed as tubo-ovarian were probably large examples of hydrosalpinx: one was so big that it came in contact with the liver.

In order to estimate the risks of ovariotomy fairly the nature of the tumour must be considered. In the preceding edition of this book the general mortality of ovariotomy was given in the following terms:

'If all kinds of tumours are included, a 5% mortality in experienced hands would be regarded as a good result. In general hospital work it is probably as high as 10%. With less experienced surgeons who do not perform many pelvic operations the death-rate will vary from 10 to 15%.'

[1] A second operation on patient No. 1 in the list.

In order to make matters more precise I examined the surgical and gynæcological reports of the Middlesex Hospital for 1909, 1910, and 1911. During that period 120 operations were performed under the general heading of ovariotomy. The tumours are given in the subjoined table, which shows also the number of deaths from operation.

		Deaths.
Simple cysts and cyst-adenomas	93	3
Dermoids	12	0
Ovarian fibroids	4	0
Papillomatous cysts	2	0
Parovarian	1	0
Malignant	8	2
	120	5

The perusal of such a list can only give a general idea of the results of ovariotomy. Some of the cysts had burst: several had twisted their pedicles: many of the cysts were bilateral, entailing the removal of both ovaries, and in a few cases the uterus also. The malignant tumours were in all probability metastatic carcinomas. Apart from these conditions, the table furnishes evidence of the success attained by a number of surgeons differing in experience and ability, working together under similar conditions in a general hospital in London, which receives acute as well as chronic cases of ovarian disease.

The risks and after-consequences of ovariotomy are set forth in pp. 13 *et seq.*

References

Doran, A. On Complete Intraperitoneal Ligature of the Pedicle in Ovariotomy. *St. Bartholomew's Hospital Reports,* 1877, xiii. 195.

——Pregnancy after the Removal of Both Ovaries for Cystic Tumour. *Trans. Obstetrical Society,* 1902, xliv. 231.

Bland-Sutton, J. On Secondary (Metastatic) Carcinoma of the Ovaries. *Brit. Med. Journal,* 1906, i. 1216.

——On Cancer of the Ovary. Ibid., 1908, i. 5.

——On Typhoid Infection of Ovarian Cysts. *Universal Medical Record,* 1913, iii. 385.

Le Bec. Ovariotomie double; un des kystes enlevé par la région lombaire, l'autre par le devant de l'abdomen; adhérences totales; guérison. *Gaz. des Hôpitaux,* 1887, 290.

Soutar, H. S. Calcified Ovarian Fibroid obstructing labour. *Proc. Roy. Soc. of Med.,* 1913, Obstetrical Section, vi. 335.

Stocks. Prolapse of an Ovarian Cyst. *Brit. Med. Journal,* 1857, ii. 487.

Paterson, H. J. Suppurating Ovarian Cyst in a girl, aged ten years, probably infected from hairpins impacted in the vagina. *British Journal of Children's Diseases,* 1911, viii, 295.

Peters, H. Ovariotomie per anum. *Wiener Klin. Wochensch.,* 1900, xiii. 110.

CHAPTER II

OÖPHORECTOMY

Oöphorectomy signifies the removal through an abdominal incision of an ovary and uterine tube for affections mainly inflammatory.

The evolution of this operation is of great interest to surgeons. Removal of the ovaries as a surgical operation was introduced independently by Hegar in Germany and Battey in Georgia, for the relief of pelvic pain and dysmenorrhœa, in 1872. In the same year Lawson Tait performed his pioneer operation and removed an ovary and tube for the relief of pain due to disease of the ovary. Subsequently he advocated bilateral oöphorectomy for the purpose of inducing an artificial menopause in women with uterine fibroids. From these beginnings the operation began to be performed for the relief of a variety of conditions connected with the generative organs, such as—

Pyosalpinx and tubo-ovarian abscess, hydrosalpinx, tuberculous ovaries and tubes, sarcoma and carcinoma of the uterine tubes, gravid uterine tubes, ovarian abscess, ovarian pregnancy, prolapse of the ovary; finally bilateral removal of the ovaries has been practised for the relief of inoperable cancer of the breast.

Bilateral oöphorectomy is occasionally performed for osteomalacia (a rare disease in Great Britain), as it arrests pain and the excessive output of phosphates in the urine, which is a marked feature of this affection. This extension of the operation we owe to Fehling of Bâle (1887).

Time and experience have considerably modified surgical opinion in regard to oöphorectomy. Removal of the ovaries is no longer practised for the relief of hæmorrhage due to fibroids: it is easier, safer, and affords greater relief to the patient to remove the uterus. When dysmenorrhœa is so severe as to need radical operation, hysterectomy is the only certain method, with conservation of at least one ovary. The removal of both ovaries in certain forms of insanity is now abandoned, and this is true of bilateral oöphorectomy for the relief of mammary cancer.

In other directions the operation has undergone extension, for in some chronic diseases of the uterine tubes it is difficult completely to extirpate the affected tissues without removing the uterus. These will be considered in describing the actual operation.

Apart from the many modifications in the details of the operations,

some surgeons prefer to remove the ovaries and tubes through an incision in the vaginal fornix. This is known as Colpotomy, or Vaginal Cœliotomy.

Some writers attempt to subdivide the various modifications of oöphorectomy and apply to them special terms: for example, the removal of the ovary and tube would be termed salpingo-oöphorectomy. Removal of the tube would be called salpingectomy, and the excision of the ovary, oöphorectomy. This terminology may be precise, but it is certainly clumsy. A few writers designate these operations as 'removal of the uterine appendages'; this phrase, though comprehensive, is neither precise nor elegant.

Operation. The patient is prepared in the same manner, and the same instruments are required, as for ovariotomy. In these operations the Trendelenburg position is of the greatest advantage.

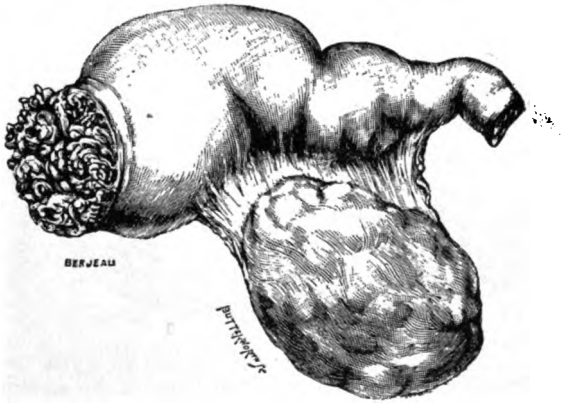

FIG. 95. AN INFECTED UTERINE TUBE. The cœlomic ostium of the tube is unoccluded and is in the process of slowly engulfing the fimbriæ. Removed from a woman in the acute stage of salpingitis. Three-quarter size.

In a case of prolapse of the ovary, or a gravid tube or ovary in the earliest stages, the operation presents no difficulty and can be carried out with the ease and safety of the simplest ovariotomy; but there are many cases where the tubes and ovaries contain pus and are distended into cysts as big as a fist, or even as large as the patient's head, which are adherent to bowel, uterus, bladder, indeed everything with which they come in contact; this renders their removal tedious and exacting for the surgeon and dangerous to the patient. Although a suppurating ovarian cyst adheres to surrounding organs, its removal is simpler than in the case of a large pyosalpinx, because the uterine tube is intimately enclosed within the folds of the broad ligament, and these connexions serve to bind it firmly in the pelvis.

In undertaking the removal of enlarged tubes the surgeon's first duty is to expose the parts by a free incision, and then carefully isolate the intestines and upper parts of the abdomen with dabs in order to prevent them from being contaminated with pus. He will quickly recognize, in the majority of cases, that he has to deal with tubal disease, be-

cause the distended uterine section of the tube will lie on the more globular lateral portion of the tube and assume the familiar shape of a chemical retort. With the fingers the adherent omentum and bowels are carefully detached, and the adhesions between the distended tube or ovary and the rectum are carefully broken through with the finger, and the parts withdrawn from the pelvis. With great care it is usually possible to do this without bursting the tube. When the tube bursts in the process of removal it is useful to swab it up with some strips of gauze and thus keep the 'dabs' clean for the final stages.

As soon as the diseased parts are extracted, a dab is pressed into the pelvis to check the oozing: the pedicle is clamped with forceps and the tube and ovary detached.

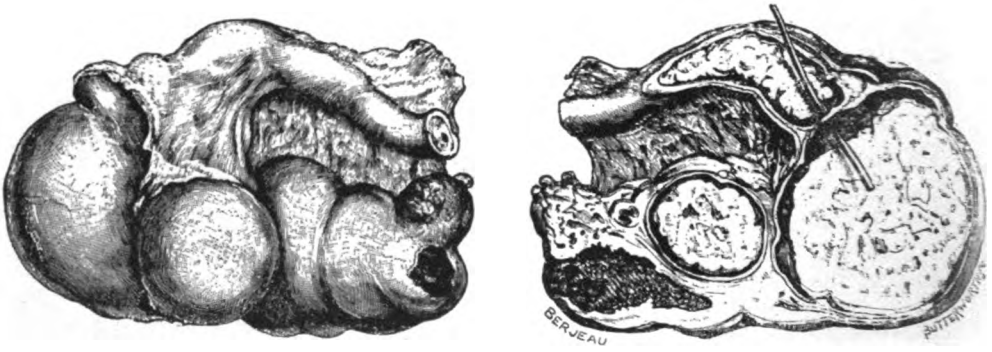

FIG. 96. A TUBERCULOUS UTERINE TUBE AND OVARY: ENTIRE AND IN SECTION. Caseous matter has exuded through the cœlomic ostium of the tube and become encapsuled. Natural size.

It is the common practice in dealing with inflamed and septic ovaries and tubes to transfix and ligature the pedicles as in a simple clean ovariotomy. The consequences of this practice are not satisfactory, for the pedicles being infected often give rise to trouble. because the silk acts as a seton, an abcess forms which may burst through the abdominal wound, the rectum, or the bladder, and leads to the establishment of a sinus which persists for many months until the ligature is extruded. There are several methods of avoiding this: for example, the arteries in these broad pedicles may be ligatured separately with thin silk, and the edges of the peritoneum drawn together by two or three mattress sutures (Fig. 49, p. 107).

When the uterine tube is thickened quite up to the uterine extremity, it may be exsected from the uterus: in such a case the uterine artery will be tied and the flaps at the uterine end can be brought into apposition by a mattress suture.

In acute salpingitis the abdominal ostia of the tubes are open and pus can be seen leaking from them. In chronic cases the ostia are closed. When dealing with a case suspected to be acute salpingitis the surgeon must remember that his diagnosis is not infallible, and though the signs appear to indicate leakage from an infected tube, the trouble may be due to rupture of a gravid tube or an ovarian cyst, perforation of an infected vermiform process, or a calculus impacted in the lower segment of a ureter.

It is the common practice in cases of acute pelvic peritonitis when the uterine tubes are found enlarged and pus leaks from their abdominal ostia, to remove them. Since it has been established that gonococcal peritonitis is rarely fatal, I have tried milder measures. Instead of removing the ovaries and tubes, I wash them with warm sterile water and also the recesses of the pelvis, and then drain with a rubber tube for a few days, perhaps a week. The immediate results of this method are excellent.

The operative difficulties in chronic salpingitis are caused by adhesions of the tubes and ovaries to adjacent viscera. The most serious complication in removing a large pyosalpinx, especially on the left side, is a firm adhesion to the rectum; this may be occasionally anticipated when the patient gives a clear history of one or more sudden discharges of pus from the anus. An accidental tear of the rectum through comparatively healthy tissues may be repaired by interrupted sutures, but when the injury is in tissues altered by chronic suppuration, the only course open to the surgeon is to drain with a wide rubber tube, and it is surprising as well as gratifying to know that a fistula of this kind, low in the rectum, will often close in a week or ten days. It is important to bear in mind that an undetected tear into the rectum, if the abdomen be closed without drainage, will, in all probability, lead to fatal peritonitis.

It has happened that a surgeon in removing a pyosalpinx tore a hole in the rectum; he was unaware of the accident, and a few hours after the operation ordered 10 ounces of saline solution to be injected into the bowel. This fluid passed through the rent in the gut direct into the pelvis with fatal consequences.

After removing the diseased parts and securing the large vessels directly concerned in the pedicles, attention is directed to the oozing from the torn tissues in the floor of the pelvis. Any vessel which is bleeding should be ligatured with thin silk, and then the recesses of the pelvis may be firmly plugged with a dab wrung out of hot water: this is a valuable measure of hæmostasis. This dab is removed in two or three minutes, and any vessel which is bleeding quickly seen and ligatured.

In cases where the enucleation of adherent and inflamed tubes leaves

large raw and slightly oozing surfaces in the pelvis, drainage is a wise precaution. After a trial of a variety of measures for this purpose I find the simplest to be a narrow rubber tube reaching to the bottom of the pelvis and emerging at the lower extremity of the abdominal incision. It is rarely required for more than forty-eight hours. Some surgeons are opposed to drainage, and one writer compares it to 'defending oneself against the sparks of Vulcan with an umbrella'; his mortality is high.

In simple cases the incision is closed according to the method described on p. 212; but after the removal of suppurating ovaries and tubes it is better to unite the wound by a single layer of sutures through all the tissues of the abdominal wall: buried sutures in such conditions nearly always give trouble.

BACTERIOLOGY OF THE UTERINE TUBE IN RELATION TO OPERATIONS

A large amount of labour has been expended on investigating the bacteriology of infective diseases of the uterine tubes. The chief varieties of micro-organisms found in them are the gonococcus, streptococcus, the tubercle bacillus, and very rarely a streptothrix.

The gonococcus attacks mainly the mucous membrane of the tubes and is more destructive to function than to life; extensive pelvic operations are often performed for damage it causes to the uterus and tubes, sometimes in the acute, but more often in the chronic stages of the infection.

Thrombosis and pulmonary embolism are not sequences of gonorrhœal infections. The gonococcus causes great irritation of tissues, and produces masses of adhesions but does not coagulate blood.

The streptococcus and the colon bacillus are occasionally found in old-standing cases of pyosalpinx and are usually secondary infections. When the streptococcus occurs primarily in a pyosalpinx the condition is a sequel of septic puerperal infection of the uterus, or of an operation. The streptococcus flourishes best in loose connective tissue, invades blood-vessels and lymph-vessels. It is a virulent micro-organism especially destructive to life.

The colon bacillus finds its way into distended tubes when they adhere to adjacent coils of bowel, especially the rectum.

Tuberculosis of the tubes is usually a descending infection and the tubercle bacillus finds its way into the tubes in an indirect way. The infection, in many cases, is primary in the intestine, the peritoneum becoming infected from intestinal ulcers or the bursting of a tuberculous

gland. The infective material is carried by the lymph currents of the abdomen into the mouths of the uterine tubes.

Actinomycosis (Streptothrix infection). This disease attacks the uterine tubes and also the ovary. A critical consideration of the published cases supports the contention that the disease is secondary in these situations and that it spreads to the tube and ovary from the intestinal tract and especially the vermiform process. In all the reported cases the intestines were firmly adherent to the infected tube. The clinical features of the disease and the microscopic appearances resemble tuberculous salpingitis.

One of the earliest observed examples of actinomycosis of the uterine tube was described by Zemann (1883). Since then more than a score of cases have been observed in Europe. Risel and Wagner have collected the literature.

RISEL. *Zeitschr. für Geburtsh. und Gyn.*, 1905, lvi. 155.
WAGNER, C. *Surg. Gyn. and Obstet.*, 1901, x. 148.
ZEMANN. *Med. Jahrbücher*, 1883, 477.

Abdominal hysterectomy after bilateral oöphorectomy and ovariotomy. After the complete removal of the ovaries and tubes the uterus is a useless organ, and when the 'appendages' have been removed for inflammatory lesions, acute or chronic, it may become a troublesome organ. In some instances a uterus devoid of its appendages has been attacked by cancer. In a few instances in which patients have undergone bilateral oöphorectomy, or bilateral ovariotomy, successful conception has followed the operation (see p. 222).

The most annoying consequences which follow bilateral oöphorectomy for salpingitis, acute or chronic, are hæmorrhage, pain, or a purulent discharge. Every surgeon with an ordinary experience of this class of surgery has probably had to remove the uterus on several occasions as a sequel to bilateral oöphorectomy. Many surgeons, when they find the appendages so hopelessly diseased that they must be removed, perform subtotal hysterectomy at the same time. My own practice in this matter is to perform subtotal hysterectomy when it is necessary to remove the uterus as well as the appendages in chronic disease; and total hysterectomy when it is deemed advisable to remove the uterus with the appendages in acute infective conditions. The reasons for this modification are obvious, because in chronic conditions there is little liability for the stump to become infected, for experience teaches that though the distended tubes contain pus in chronic cases, yet on bacteriological examination this pus is sterile. In the acute cases the pus swarms with micro-organisms—bacillus coli, staphylococcus, and occasionally streptococcus;

these infect the stump, set up suppuration, infect the ligatures, and establish a chronic sinus. To cure this condition it is necessary to remove the stump by the vaginal route.

In cases of tuberculous infection of the uterine tubes it is not necessary to remove the uterus unless it is obviously implicated by the disease. In several patients I have left an ovary without any subsequent ill consequences.

Mortality. In order to estimate the risks of oöphorectomy it is necessary to classify the heterogeneous conditions for which this operation is required. In the majority of cases the chief cause is inflammatory (septic) affections of the uterine tubes; other causes are tubal and ovarian pregnancy, and prolapse of the ovary. Tubal pregnancy is considered in a separate chapter, and as prolapse of the ovary is so often associated with retroflexion of the uterus it is dealt with in the chapter on Hysteropexy.

In order to give some notion of the relative frequency of the infective conditions of the tubes and ovaries usually classed in Hospital Reports as 'diseased uterine appendages,' I chose one hundred consecutive operations from my case reports at the Chelsea Hospital for Women. They are classed thus:

Salpingitis	49
Pyosalpinx	31
Hydrosalpinx	10
Tuberculous	8
Ovarian abscess	2

In order to give some idea of the risks of unilateral and bilateral oöphorectomy, I gathered the following facts from the Hospital Reports, prepared by the Registrar. During the years 1903–7 (both years inclusive) the staff performed the operation of oöphorectomy for diseased uterine appendages on 287 women. Of these four died. During the thirteen years I have filled the post of surgeon to this hospital I have performed on an average twenty oöphorectomies yearly for the diseased conditions set forth in the above table. I lost one patient during the whole of this period, and that was in 1902. The chief risks of oöphorectomy for inflammatory conditions are undetected injury to bowel, especially the rectum, and septic peritonitis when the streptococcus is present in the tubes in acute cases.

Operation for primary cancer of the uterine tube. This disease is rarely diagnosed before operation. The treatment adopted in the cases first reported was oöphorectomy, but in the majority of

patients the disease quickly returned and destroyed them in a few months.

It subsequently became the practice to remove the uterus as well as the tubes and ovaries, but a quick recurrence in these circumstances is the rule.

The really favouring factor in the case is the condition of the cœlomic ostia of the tubes. When these remain open, the cancerous cells escape freely and implant themselves on the pelvic peritoneum and adjacent organs. In very rare instances the cœlomic ostia are occluded: in this happy circumstance a fairly long freedom from recurrence may be hoped for.

The relation between the condition of the abdominal ostium of the uterine tube and the recurrence of cancer is illustrated by the following cases:—

A woman, fifty-seven years of age, had a large submucous fibroid in the uterus and cancer of the left tube. At the operation the abdominal ostium was not only patent, but the carcinoma protruded through it and nodules of growth could be seen on the wall of the rectum at the point where the tube rested on the bowel. The patient recovered from the operation and enjoyed good health for eleven months, then signs of recurrence became manifest and she died a few weeks later.

A woman, forty-nine years of age, had a large fibroid in her uterus and a uterine tube stuffed with cancer, but the abdominal ostium was completely occluded. The uterus, ovaries, and tubes were removed. The patient subsequently re-married and was in good health three years later.

Primary cancer of the uterine tube is often bilateral and its association with fibroids of the uterus unusual. A cancerous tube may lead to complications with an ovarian cyst. Our knowledge of primary cancer of the uterine tube has grown up within the last twenty years, and some of the recorded cases puzzled the reporters because the disease was associated with a cyst, sometimes of large size.

The specimen represented in Fig. 97 is instructive; it is an ovarian cyst complicated with cancer of the corresponding uterine tube. The cyst is as big as a coco-nut. The ampulla of the tube is stuffed with cancer, but the ostium is patent and a 'stream' of cancerous material has flowed over the wall of the cyst. In addition, the cancerous material has infiltrated the wall of the ovarian cyst. The patient recovered from the operation, but a year later she had an extensive recurrence.

The fact that cancerous cells retain their vitality in the peritoneal fluid, and are able to engraft themselves on the intestines, uterus, ovary, and parietal peritoneum, is an interesting fact. Glendinning has made some valuable observations in relation to cancer of the gastro-intestinal

tract infecting the tubes. I removed two ovarian cysts infected with cancer; the primary focus of the disease was in the stomach. To the naked eye the uterine tube appeared normal, but, on microscopic examination, cancerous particles were found by Glendinning free in its lumen; the subepithelial and plical folds were extensively infiltrated with cancer. From a careful consideration of this and some similar cases, Glendinning came to the not unreasonable conclusion that the uterine tube was

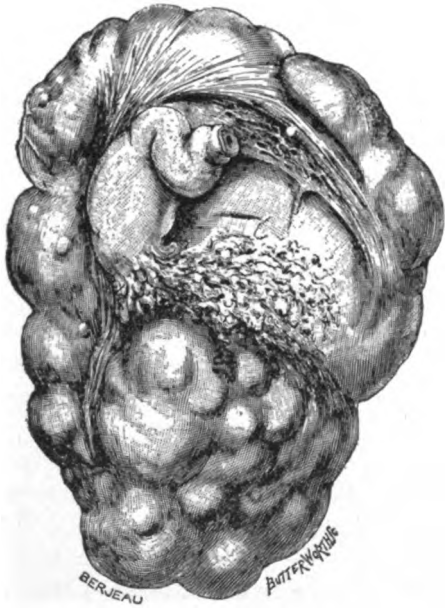

FIG. 97. PRIMARY CANCER OF THE UTERINE TUBE. An ovarian cyst associated with primary cancer of the corresponding tube. The cœlomic ostium of the tube is open and the cancerous material has leaked out on to the cyst-wall. Half size.

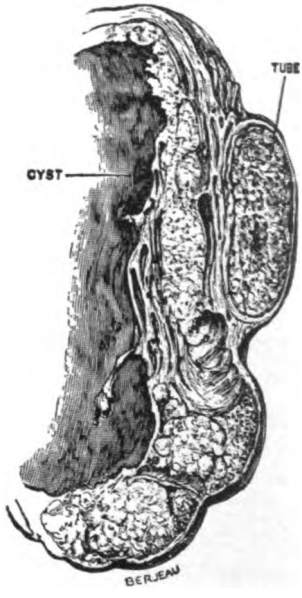

FIG. 98. A SECTION OF PRIMARY CANCER OF THE UTERINE TUBE. This is the cyst-wall and cancerous tube represented in the preceding drawing: it shows the cancerous infiltration of the cyst-wall. Half size.

infected by cancerous cells swept into it through the abdominal ostium, engrafting themselves on the mucous membrane and subsequently penetrating to the deeper tissues.

These facts have even a deeper significance. Cancer of the uterine tube is often bilateral, and it is a disease which gives bad results to operative interference. The observations mentioned above permit the inference that some cases of unilateral and bilateral cancer of the uterine tubes are really examples of implanted cancer, and the primary focus may be situated in the gall-bladder, stomach, or some part of the colon.

CHORION-EPITHELIOMA OF THE TUBE AND OVARY

This malign disease attacks the uterine tubes. Rossier in describing a case collected those previously reported. The symptoms of this disease resemble those of tubal pregnancy: these subside and there is a period of quiescence followed by rapid increase in the size of the tumour, accompanied by pain and severe constitutional disturbances. Operative treatment of the disease is attended by a high mortality and, in those who recover, quick recurrence and death is the rule. Bazy, in describing an unsuccessful case, reviews the results. Phillips has recorded a happy exception (1911).

Fairbairn has described an example of primary chorion-epithelioma of the ovary (1909). The woman was reported to be in good health two years after the operation.

BAZY, L. Carcinome placentaire ou Chorio-épithéliome malin de la Trompe. *Annales de Gynéc. et d'Obstét.*, 1913, x. 207.

DORAN, A. A Table of Over Fifty Complete Cases of Primary Cancer of the Uterine Tube. *Journ. of Obst. and Gyn. of the Brit. Empire*, 1904, vi. 285.

——Primary Cancer of the Fallopian Tube. Ibid., 1910, xvii. 1.

FAIRBAIRN, J. S. Primary Chorion-epithelioma of the Ovary. Ibid., 1909, xvi. 1.

FONYÓ, J. Über das primäre Tubenkarzinom. *Zentb. f. Gynäk.*, 1913, No. 36, 1317.

GLENDINNING, B. The Spread of Carcinoma by the Uterine Tube. *Arch. of Middlesex Hosp.*, xix. 82.

PHILLIPS, M. H. A case of Chorion-epithelioma of the Uterine Tube. *Journ. of Obstet. and Gyn. of the Brit. Empire*, 1911, xx. 299.

ROSSIER, G. Ein Fall von Chorion-epithelioma malignum der Tube infolge Extrauterin-Schwangerschaft. *Arch. für Gyn.*, 1912, Bd. xcvii, 1913. Fehling Festschrift.

SECTION IX

OPERATIONS UPON THE UTERINE TUBES

BY

W. BLAIR BELL, M.D., B.S. (Lond.)
Gynæcological Surgeon, with charge of Out-patients, Royal Infirmary, Liverpool

CHAPTER I

GENERAL CONSIDERATIONS CONCERNING OPERATIONS ON THE UTERINE TUBES

GENERAL INDICATIONS FOR OPERATION

OPERATIONS on the uterine tubes are performed in the treatment of the following conditions:—

1. Abnormalities;
2. Displacements;
3. Ectopic gestation;
4. Infections;
5. Neoplasms.

GENERAL POINTS IN TECHNIQUE

Method of access. In all operations on the uterine tubes access should be obtained by means of laparotomy. The vaginal route should not be used for operations on the tubes, although it is sometimes advisable to drain a tubal or peritubal abscess through the posterior vaginal fornix previously to an operation being carried out on the tubes themselves.

Some gynæcological surgeons do operate by the vaginal route, but in the opinion of the writer this is a bad practice and is not in the best interests of the patient, since the proper method of dealing with the lesion present can often be decided only when a full view of the pelvis has been obtained.

The preparations for operation, both in regard to the patient and to the details connected with the performance of it, are those ordinarily employed for abdominal procedures (see Sec. I. Chap. I).

Preliminary operative details. When the patient is fully anæsthetized the surgeon makes a median incision extending from just below the umbilicus to the symphysis pubis, and opens the abdominal cavity in the ordinary way. If the intestines be found adherent to the pelvic organs they should be gently separated with a gauze dab, or, when necessary, by putting the bowel on the stretch and cutting through the adhesions with scissors. The patient is then placed in the Trendelenburg position and the intestines are carefully packed off with a sheet of thin

rubber [1] which has been kept warm in hot saline solution. If necessary a gauze pack can be used subsequently against the rubber. A clear view of the pelvis is thus obtained.

If the tubes be adherent, as is always the case with infections, it is necessary first of all completely to free them and the ovaries, which will also be involved. Sometimes this is a very difficult matter, especially when the disease is of old standing.

In some cases it may be necessary to bisect the uterus in order to get at the adherent tubes from below, as recommended by Howard Kelly (see p. 252).

In the majority of cases, however, the operator is able without undue difficulty to 'deliver' the tubes and ovaries in the following manner:—

After the separation of any adherent bowel the fundus uteri is identified. In the worst type of case the posterior portion of the pelvis which lies behind the uterus and broad ligaments will be completely filled in with the adherent structures. The operator has therefore to make an opening for himself, and this is most easily accomplished if he force his index finger down the back of the uterus and keep the palmar surface of the finger against that organ. The hole thus made is widened from side to side until several fingers can be inserted.

The operator is now in a position to deal with the tubes and ovaries, which are adherent to the back of the broad ligaments. It is better first to deal with the right side, and then with the left which may be complicated by adhesions to the rectum. Passing three fingers into the wide hole at the back of the uterus the operator with the tips of his fingers scrapes the adherent tube and ovary from the back of the right broad ligament, and collects the organs as they are freed into the palm of his hand. The appendages are thus unfolded, as it were, from the back of the broad ligament.

Sometimes, of course, the vermiform process will be found in the pelvis on the right side and require to be freed previously to removal. As a rule this is easily accomplished.

The left tube and ovary are next separated in a similar manner, care being taken carefully to insinuate the forefinger between the rectum and the adherent appendages. If the bowel be torn it must be repaired immediately with catgut.

In milder infections the inflammatory process is limited to the neighbourhood of the tubes, and the pelvis is not filled in with exudate

[1] For some years the writer has used for packing off the intestines a sheet of rubber 60 inches by 12 inches, of the same thickness as that of a thin rubber glove. The endothelium of the peritoneum is not damaged by the smooth rubber as it is by gauze.

and adherent structures, so that it is a simple matter straightway to unfold the adherent appendages from the broad ligament in the manner described.

As a rule the bleeding from the raw surfaces is not great in infective lesions, and only a few points require to be caught and tied. Sometimes it is necessary to under-run with a needle and suture bleeding points which cannot be caught in the forceps. It is dangerous to leave clots in the pelvis lest they should become infected. With malignant disease the bleeding may be very troublesome, but must always be carefully arrested.

Suture and ligature materials. Catgut should be used for ligature of pedicles and isolated vessels, also to coapt surfaces when only temporary support is required during the process of healing. Fine twisted silk should be used when permanent fixation or the shortening of ligaments is required.

CHAPTER II

CONSERVATIVE OPERATIONS

DILATATION OF THE UTERINE TUBES

DILATATION of the uterine tubes is an operation which is performed to enlarge the lumen when this is slightly constricted.

Indications. This operation is but rarely performed, for there are no means whereby a slight congenital constriction or kink can be diagnosed.

In a few cases, however, of primary sterility the tubes have been investigated and found slightly stenosed or kinked, and dilatation has been carried out with successful results.

Technique of operations. Instrumental dilatation. The free margin of the mesosalpinx is seized in compression forceps and the tube to be dilated is put on the stretch. A small probe is then carefully passed through the abdominal ostium and on into the uterus. Great care must be exercised lest a false passage be made or the tube torn: any laceration of the lining membrane would probably be followed by atresia at the injured spot. Subsequently larger probes are passed until the operator is satisfied that there is no longer any obstruction.

This method has not been employed in a sufficient number of cases to justify any statement being made as to its value.

Pneumatic dilatation. This method has been employed by Hastings Tweedy, to whom the writer is indebted for a private communication on the subject. The free extremity of the mesosalpinx is seized in compression forceps and the fimbriated end of the tube exposed. The nozzle of a syringe containing sterile air is now inserted through the abdominal ostium and the piston of the syringe pushed home. By this means the tube is temporarily dilated, but according to Tweedy is liable to contract again.

No series of cases or the after-results have yet been published, so that it is impossible to say how far this procedure is justifiable or effective.

SALPINGOSTOMY

Salpingostomy, as its name implies, is an operation whereby an artificial ostium is made in the uterine tube.

Indications. This operation is performed, in circumstances to be mentioned directly, in order to cure the condition of sterility which is

associated with occlusion of the abdominal ostia. This, in fact, is the only indication for this procedure. It follows, therefore, that to justify the operation the patient must be in the child-bearing period of life, and that the local condition must be such that the artificial orifice will remain patent and the tube be functional otherwise.

With regard to the local condition, salpingostomy is only justifiable when the uterine end of the tube is patent. Consequently the operation

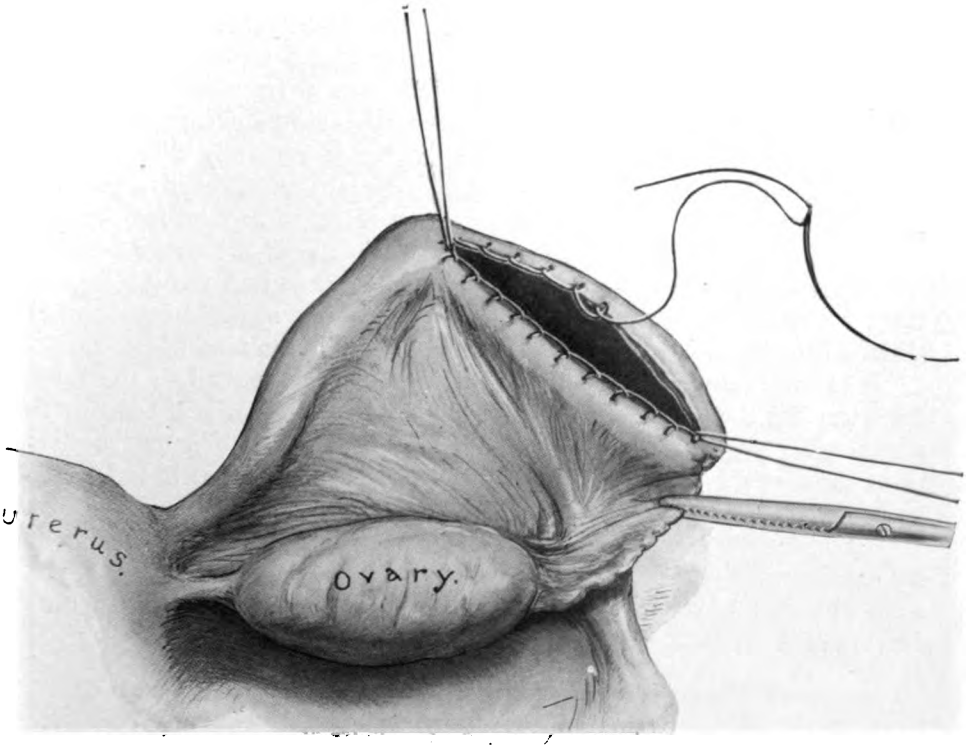

FIG. 99. SALPINGOSTOMY.

should rarely be performed for primary salpingitis, for in such circumstances the tube is frequently occluded at both ends and a hydrosalpinx or pyosalpinx is present or in the process of formation.

If, however, the infection has spread to the pelvis from the vermiform process the tubes may be buried in adhesions and the abdominal ostia sealed, while the uterine openings of the tubes remain patent, for, as a rule, in these cases there is no infection of the lining membrane of

the tubes. The operation in such circumstances is carried out after removal of the vermiform process.

Technique of operation. The tube is carefully freed from adhesions and all bleeding completely arrested. This is a most important point: any blood in the neighbourhood of the artificial opening may give rise to further adhesions and close the orifice just made.

The tube is now brought out of the abdominal incision and put on the stretch by being held at the distal end or at the free edge of the mesosalpinx in a pair of compression forceps. The occluded end of the tube then is incised, and a probe or director passed into the lumen and on through the tube to the uterus, to make sure there is a free passage and no constriction which would prevent the ultimate success of the operation. If there be a slight stenosis this is carefully dilated with probes in the manner already described. Next, one blade of a pair of fine scissors is inserted along the probe or director, and an inch and a half of the distal end of the tube split open along the upper border. A temporary guy ligature is now placed at each end of the incision in the tube, and the lining membrane is sutured by means of a blanket stitch with very fine catgut to the muscular wall of the tube (Fig. 99).

It is rarely necessary to excise any portion of the wall of the tube, for after the stitching is completed the artificial ostium will be seen to gape owing to the retraction of the circular muscle fibres. Similar procedures are subsequently carried out on the other tube, if it be also sealed at the abdominal ostium.

The tube and ovary of the same side are finally fixed to the brim of the pelvis in the manner to be described directly. If no adhesions form, a functional tube will be obtained and a previously sterile woman may be rendered fertile.

FIXATION OF THE UTERINE TUBES

Indications. The tubes may be fixed in some more normal position when they are prolapsed with the ovaries into the pouch of Douglas with or without retroversion of the uterus. If the uterus be retroverted also, then the cure of the tubal prolapse will form part of the operation for dealing with the displacement of the uterus. Prolapsed tubes may be free or adherent. The indications for operation when the tubes are free are pain in the back and dyspareunia, symptoms which are due to the associated ovarian prolapse rather than to the displacement of the tubes. The ovaries, however, cannot be satisfactorily dealt with unless the tubes also are suspended in a normal position. The indications for fixing the tubes when adhesions are present are the symptoms already mentioned together with sterility. The operation is usually

only performed in the latter class of case when the infection spreads to the pelvis from the vermiform process. The fixation may in these

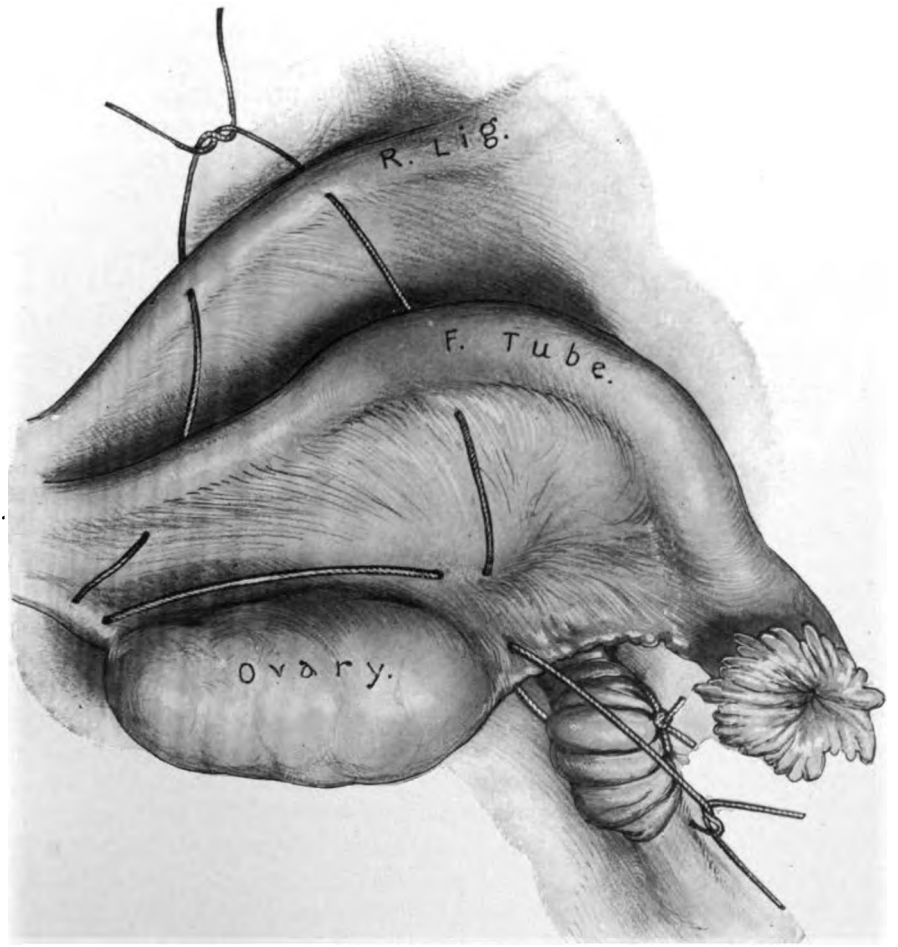

FIG. 100. SUSPENSION OF THE OVARY AND FALLOPIAN TUBE. The suture which puckers the infundibulo-pelvic ligament should only pick up the peritoneum, in order to avoid interference with the ovarian vessels. For the same reason the ligature which attaches the pole of the ovary to the infundibulo-pelvic ligament should not pass round this ligament, but through its peritoneal covering.

circumstances follow the removal of the vermiform process and the performance of salpingostomy.

If the tubal infection be primary, fixation is rarely indicated, for some form of salpingectomy will probably be required.

Technique of operation. The following is the method adopted by the writer. The tube and ovary are first completely freed. The edge of the mesosalpinx is then seized in compression forceps, and the infundibulo-pelvic ligament is shortened by passing a running stitch of fine silk through its peritoneal covering from the pelvic brim to the free border of the mesosalpinx, and tying the two ends of the thread together. Next the ovary is attached by the free border of the mesovarium to the shortened infundibulo-pelvic ligament at the brim of the pelvis. If the ovary be heavy and the mesovarium and mesosalpinx be much stretched, the ovary should also be fixed by a fine silk mattress suture which attaches the mesovarium to the mesosalpinx and the mesosalpinx to the round ligament of the same side (Fig. 100). In this way the tubes and ovaries are fixed above the raw pelvic surfaces, and remain free if the source of the infection be removed.

CHAPTER III

ERADICATIVE OPERATIONS

THE tubes are removed in the treatment of the following conditions: Infections, new growths, tubal pregnancy, torsion, hæmatosalpinx, hernia, and ectopia.

There are various methods employed according to the condition present, so that it will be necessary to describe the simplest procedures first and afterwards the more extended operations that may be advisable.

It must be remembered, however, that the indications mentioned are only relative and not absolute, and depend on the conditions found. Further, removal of the tubes is sometimes only part of larger operations with which we are not concerned here.

SALPINGECTOMY BY SIMPLE LIGATURE

Indications. This method should only be employed in tubal pregnancy where the operation has to be performed rapidly, in torsion of the tube, in ectopia, and in hernia of the tube when it is considered advisable to remove the tube instead of returning it to the abdominal cavity.

Technique of operation. After the affected tube and corresponding ovary have been freed and delivered through the abdominal incision a double thread is carried through the mesosalpinx on a pedicle needle. One half is tied round the tube as near to the uterus as possible, and the other round the free edge of the mesosalpinx. Whenever possible the stump of the tube should be buried in the broad ligament, a procedure which does away with the possibility of a raw surface to which bowel may become adherent. The chances at some subsequent date of an ovum finding its way through the stump of a tube which is left exposed are too remote to need consideration.

Usually in the conditions mentioned the ovary will be removed at the same time for reasons which need not be given here. This involves a slight modification in the operation. The double thread is passed through the broad ligament below the ovary. One half is tied near the uterus to include the tube and ovarian ligament, and the other to include the broad ligament up to the infundibulo-pelvic ligament (Fig. 101).

SALPINGECTOMY BY EXCISION

Indications. This operation is employed in undisturbed tubal pregnancy, in innocent new growths of one tube, and sometimes in infections; but, as will be mentioned directly, the writer has recently devised a better method for dealing with infections involving the tubes.

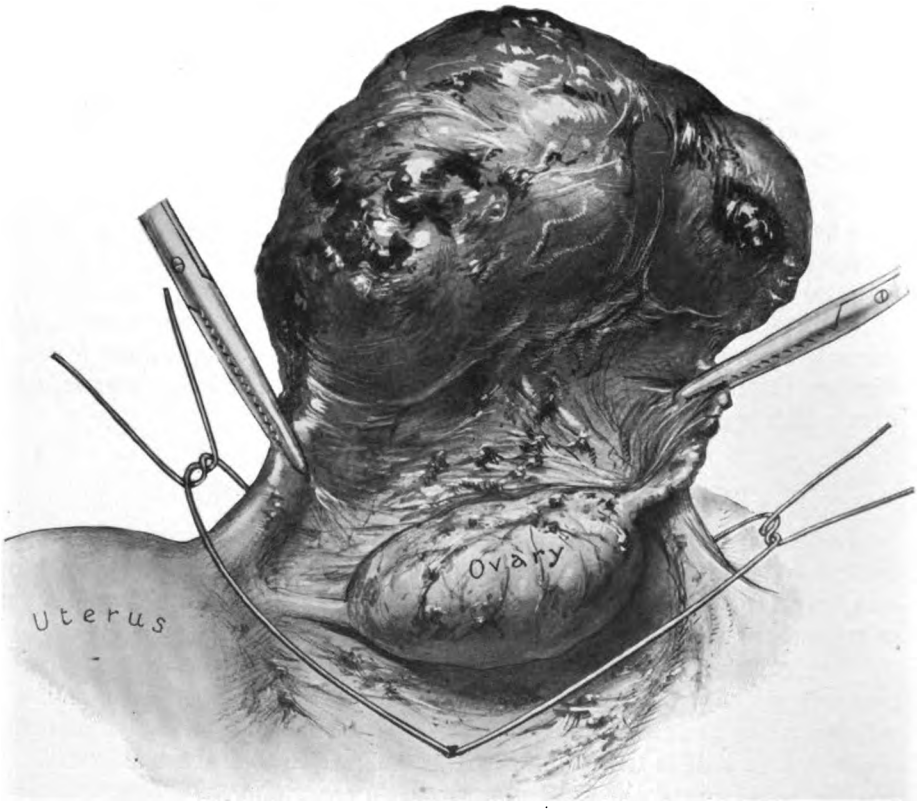

FIG. 101. SALPINGO-OÖPHORECTOMY. A method employed when rapid removal is necessary in cases of tubal gestation.

Technique of operation. The free edge of the mesosalpinx, along which the ovarian fimbria lies, is seized with a pair of compression forceps and cut through. The mesosalpinx is now divided up to the uterus with scissors, bleeding vessels being caught in compression forceps as they are divided.

The tube is now quite free except for its attachment to the uterus and may be removed after simple ligature, which will include the main arterial supply from the uterine artery; or by a wedge-shaped excision

of the uterine cornu (Fig. 102). After the tubes have been removed in this way all bleeding points are carefully ligatured, and the cut edges of the mesosalpinx are sewn together. Finally the wound in the uterus is closed with a few deeply-placed catgut sutures.

In tubal pregnancy it is not really necessary to excise the tube from the uterus, but it makes a neater operation.

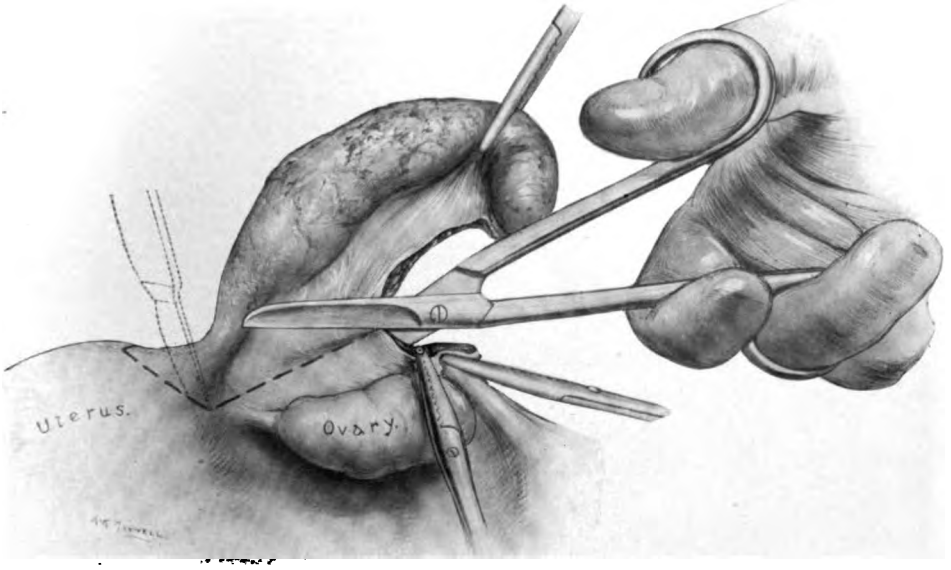

FIG. 102. SALPINGECTOMY WITH CONSERVATION OF THE OVARY.

ACROHYSTERO-SALPINGECTOMY

Indications. This procedure has recently been employed by the writer for infections of the tubes in young women where it is possible to save an ovary.[1] The essential feature of the operation consists in the removal of the fundus uteri together with both tubes and one ovary.

In these cases this procedure has the following advantages over the other forms of salpingectomy just described, which have hitherto always been employed either alone or with supravaginal hysterectomy: (1) Since the fundus is always infected removal of it is desirable to prevent the patient subsequently suffering from menorrhagia, as she frequently does after removal of the infected tubes alone. (2) If only the fundus and not the whole body of the uterus be removed, and one ovary be left, menstruation continues subsequently.

[1] Prof. Beuttner of Geneva has independently employed the same procedure. *Lancet*, 1913, Aug. 16, p. 483, and Aug. 23, p. 597.

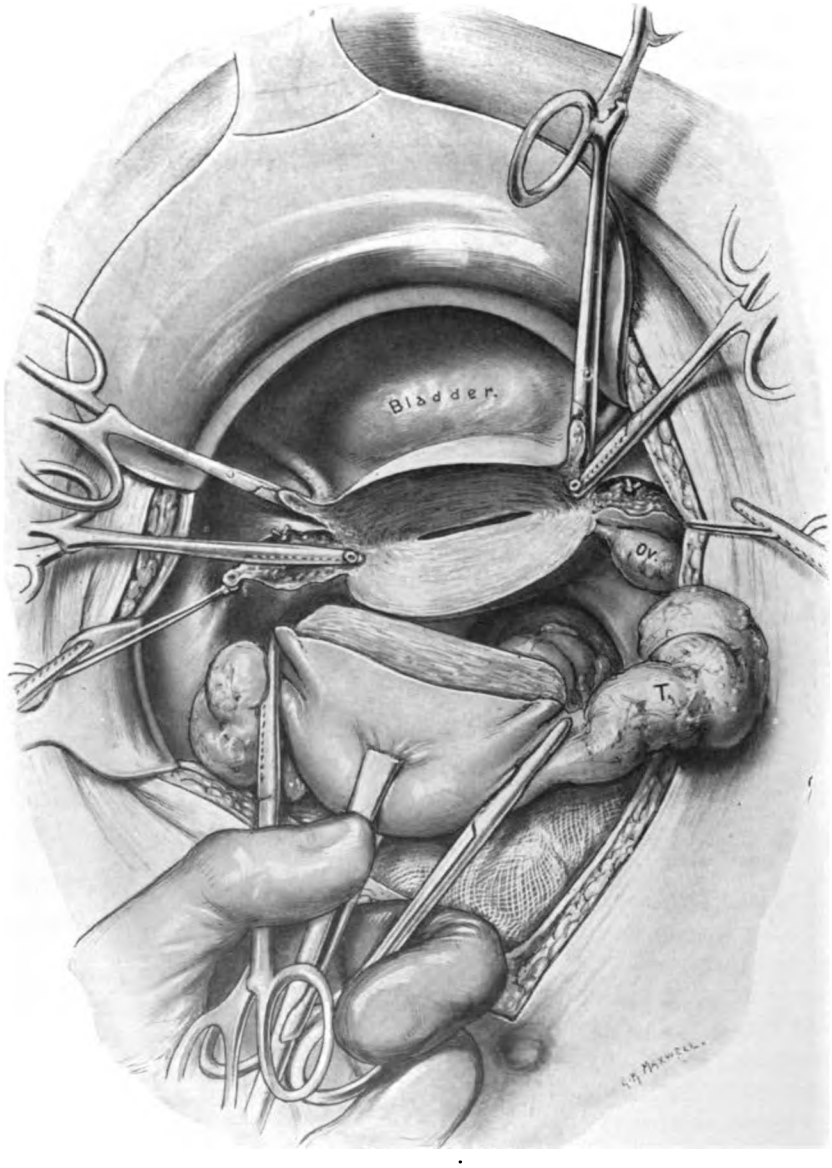

FIG. 103. AUTHOR'S OPERATION OF ACROHYSTERO-SALPINGECTOMY. The stage in the operation is shown at which the tubes, one ovary, and the fundus of the uterus have just been removed.

Technique of operation. After all adhesions have been broken down the operator excises the tubes and one ovary by cutting through the broad ligament on one side, and through the mesosalpinx on the side on which the ovary is to be left. Then, instead of excising only wedge-shaped portions of the cornua of the uterus, he excises the fundus uteri by anterior and posterior incisions directed from above downward and inwards. The ascending branches of the uterine arteries are caught at the side of the uterus below the angle made by the meeting of the incisions (Fig. 103). A wedge-shaped opening in the uterus remains with anterior and posterior flaps which are then sutured together to form a stump of the uterus containing some endometrium. The method of suture consists of the insertion of three or four mattress catgut sutures to coapt the deeper portions of the uterine wound and arrest the bleeding. The cut edges of the mesosalpinx on one side, and of the broad ligament on the other are then sewn together, and all ligatured stumps inverted between the two layers of peritoneum, with a continuous fine catgut suture, which also, as it passes from one side to the other, accurately coapts the peritoneal surfaces of the uterine wound.

Subsequently the uterine ends of the round ligament are sutured with fine silk to the top of the uterine stump, and the ligament of the remaining ovary is attached also by a fine silk suture to the round ligament of the same side to prevent the ovary from falling into the pouch of Douglas.

HYSTERO-SALPINGECTOMY

Indications. This operation, which includes the removal of the tubes with the uterus, completely or supravaginally, is employed in cases of retained menses in the uterus and tubes, in infections and in malignant new growths of the appendages.

As already pointed out, the operation of acrohystero-salpingectomy is to be preferred in salpingitis in young women when one ovary can be saved. But when both ovaries are removed because they are badly infected, or because the age of the patient is such (forty-five years and upwards) that it is not necessary to save an ovary, then, of course, it is useless preserving any endometrium, and supravaginal or complete hysterectomy should be performed. Similarly when there is a malignant new growth of the tubes or ovaries, both tubes, both ovaries, and the uterus should be removed.

Technique of operation. In an ordinary case in which there are no adhesions, or when they are only of moderate density, the commencement of the operation is carried out in the same manner as in acrohystero-

salpingectomy, but both ovaries are removed with the tubes, and instead of excising only the fundus uteri the operator removes the supravaginal portion or the whole uterus, and completes the operation of hysterectomy in the ordinary way (see p.105).

In some cases of salpingitis, however, it is almost impossible to separate the adhesions from above without doing considerable damage to the rectum and pelvic walls. In these cases the uterus may be bisected, as recommended by Howard Kelly, from above downwards through the fundus, which is held by a volsella attached to each cornu. When the cervix is reached, each half of the uterus is amputated at this level by an incision running at right angles to the longitudinal one bisecting the uterus. A volsella forceps is now placed on the lowest portion of one half of the uterus. The operator then drags on the forceps in an upward and outward direction and exposes the uterine artery, which is seized in a pair of compression forceps. The round ligament and the tube on the same side are clamped, and one half of the uterus is removed. The same procedure is then carried out on the other side.

Sometimes the fundus is retroflexed, buried in adhesions and inaccessible. In such cases the cervix may be defined behind the bladder and divided. Next, the uterus is bisected from below upwards by passing the blade of a strong pair of scissors into the uterine cavity and first splitting up the anterior wall of the uterus and subsequently the posterior. Each half is then removed in the way described above. After removal of the uterus in one of these two ways, the pelvis is opened up and the appendages can be detached from below, as a rule without very great difficulty owing to the planes of adherence being exposed and to the greater amount of room provided.

DANGERS AND DIFFICULTIES OF OPERATIONS ON THE UTERINE TUBES

Both the dangers and difficulties are proportionate to the skill and experience of the operator.

The immediate dangers should be practically nil. The remote dangers are merely those of any abdominal operation.

In septic cases, of course, there are a few added risks, viz. the risks attendant on an abdominal infection, e.g. extensive peritonitis, thrombosis, embolism, septicæmia, pleurisy, cystitis, and other rarer complications. But, as a rule, the pus found at operation in cases of primary salpingitis is sterile, and drainage is unnecessary. If the operator refuse to operate on cases in an acute or subacute state there will be practically no mortality from this source. When there is a large acute peritubal

abscess it should be drained through the posterior vaginal fornix, and the tubes removed subsequently by the abdominal route.

In the very rare cases in which drainage is necessary after laparotomy this should be carried out through a stab wound on one or on both sides outside the rectus muscle. By this means infection of the central wound, and the risk of a hernia subsequently can usually be avoided.

The difficulties of the operations are chiefly in connexion with adhesions and their separation. This may be specially difficult when the lesion is tuberculous. Injuries to bowel must be repaired immediately, but with tuberculous lesions a fæcal fistula—a most serious matter in these cases—almost always follows. Owing to the tendency to the formation of fæcal fistula drainage should never be employed in such cases. In an ordinary septic case, the bowel when torn can be effectively repaired, but drainage is practically never necessary.

SECTION X

THE OPERATIONS FOR ECTOPIC GESTATION

BY

R. D. MAXWELL, F.R.C.S. (Eng.)
Assistant Obstetric Physician, to the London Hospital; Physician to Queen Charlotte's Lying-in Hospital

CHAPTER I

THE OPERATIONS FOR ECTOPIC GESTATION

THE operative treatment of this relatively common affection will depend very largely on its variety and the special evolution of the pregnancy: speaking generally, one may divide the fate of the ovum into several broad groups from the point of treatment.

1. *Early rupture* of a tubal sac, usually in the vicinity of the isthmus, when the patient's life is imperilled and prompt operative interference is called for.

2. *Tubal abortion,* where the symptoms are seldom so severe, frequently trifling, and neglected by the patient, who thinks she has had an early uterine miscarriage. Many of these cases do not require operative treatment: we know that many recover without it.

3. *Persistence of the pregnancy to between the third and fourth months,* when symptoms supervene suddenly. As a general rule, these cases represent primary ruptures of interstitial pregnancies, rudimentary cornual pregnancies, or secondary rupture of broad ligament pregnancies.

4. The very rare group of *ectopic gestations met with in the later months or approximately at full term.* No single operator has met with a sufficient number of these cases to enable him to formulate with precision definite lines of treatment, and in consequence there is considerable variance of opinion as to the precise time at which operations in this group should be carried out and the technique that should be adopted.

The sites of ectopic gestation calling for urgent operation will be ovarian, tubal, tubo-uterine or interstitial, intraligamentary and rudimentary cornual pregnancy.

THE OPERATION FOR EARLY RUPTURE OF THE GRAVID TUBE

All local physical signs may be, and indeed most frequently are, absent in this common variety. The diagnosis is first and last based on the classic signs and symptoms of internal hæmorrhage in a parous woman.

The common history is for several attacks of acute pain associated with fainting to have taken place before admission to hospital, where

often the patient is received in a moribund condition. Laparotomy with a view to hæmostasis is urgently indicated. If the case be desperate, not a minute more than necessary should be lost. Local anæsthesia of the belly-wall may expedite matters; in some successful cases no anæsthetic at all has been administered. A single application of a 2% alcoholic solution of iodine suffices to secure asepsis of the belly-wall.

Technique of the operation. The patient should be kept flat on her back. The Trendelenburg position merely invites the settling of large clots in the upper abdomen and possible delay in their removal at the end of the operation. The diagnosis is confirmed as the slate-blue peritoneum comes into view. A 4-inch incision should be made in the median line; the longer the incision (within limits), the quicker the operation. No time should be wasted in evacuating the fluid blood and larger clots that well up, but the left hand should be plunged down in the median line so as to grasp and identify the fundus uteri and elevate it if possible to the wound-level above the effused blood. This will bring the isthmic portions of both tubes into view, for the gestation sac lies more probably here than elsewhere in the upper genital tract. Inspection of the sac is often necessary, for its small size (not greater than a pea in some cases) will escape detection by the gloved finger-tips. A pressure forceps is next placed one on each side of the gestation sac to control the medial ovario-uterine anastomosis and the lateral ovarian arterial supply, and the patient is at once secured from further loss of blood. It is a great mistake of technique to clear the operation field of blood by soaking it up with swabs and removing clots before effecting hæmostasis. In this way a few valuable ounces of blood may be sacrificed and a few equally precious minutes lost. The immediate bleeding being temporarily controlled by forceps, its permanent arrest is best secured by salpingectomy, with careful control of the medial blood-supply of the tube. It should be remembered that the patient is pulseless and complete cessation of hæmorrhage may appear to have taken place after the main blood-supply has been controlled; further oozing may, however, take place later when the blood-pressure rises, from the raw area left after the tube has been removed by snipping along the mesosalpinx close to its insertion in the tube. This area is therefore best controlled by a fine continuous whip-stitch suture. Larger clots can now be hurriedly removed and the belly closed as quickly as possible.

In no circumstances, where the corresponding ovary has not been encroached on by the gestation, should it be removed.

As long as the patient has a perceptible pulse on leaving the operating table (on which she should not have been for more than twenty minutes), there is every probability of her being out of danger in a few hours.

As a rule, in an hour's time the happy effect of salines and brandy per rectum is shown by the increasing warmth and improving volume of the pulse of the patient, and a good prognosis may be given. The convalescence of these patients is as a rule uninterrupted. A frequent transient rise of temperature up to 101°–102° on the second to the fourth day need not cause fears of sepsis. It is probably an expression of the absorption of fibrin ferment from the effused blood. Where the pregnancy is ovarian in site, operation is as a rule easy, the mesovarium alone requiring ligature. In many of the recent specimens the tube has

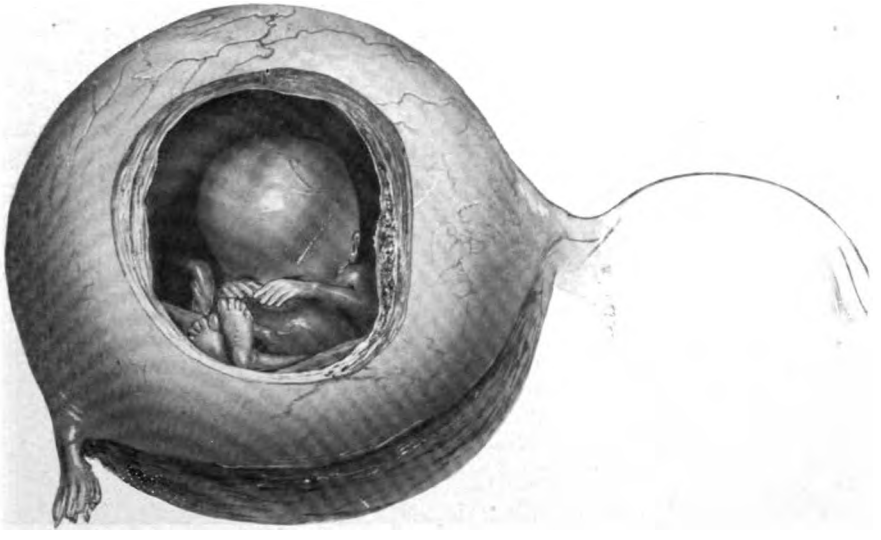

FIG. 104. TUBAL GESTATION PROLONGED TO AN UNUSUAL DURATION (4TH MONTH) WITHOUT RUPTURE OR ABORTION.

been preserved, and unless it has been encroached on by the sac it should invariably be spared.

An embarrassing situation may be met with where the tubal gestation sac is situated directly on the insertion of the tube into the uterine cornu, and as a result of rupture the tear may have extended on to the cornu. Here the ordinary ligature on the medial or uterine aspect of the sac is not applicable. Even if a small portion of the cornu can be seen medial to the sac, it is too near the site of rupture for safe ligature, as the softened tissues allow the ligature to cut through with the slightest tension, and transfixing sutures merely invite fresh oozing. It is best in these circumstances to excise a small wedge-shaped area from the cornu with the tube and close the triangular area left by two or three sero-muscular sutures tied firmly without jerking; for it must be re-

membered that the gestation sac leads to softening of all the tissues in the immediate vicinity.

As regards operation before rupture has taken place, this seldom falls to the lot of the operator, but it should be his duty, if he arrives at that diagnosis, to carry out an exploratory laparotomy. In a recent case of the author's in hospital this diagnosis was tentatively made, based on amenorrhœa and extreme pelvic pain. Pelvic examination was easy, and the uterus and appendages could be felt with ease without anæsthesia. No abnormal tubal physical signs were detected, and in consequence appendicitis was suggested and the case transferred to a colleague. Two days later he operated and removed a right gravid tube with a leaking sac the size of a walnut. There is little doubt that the first examinations conducted had caused a slight leak in the sac, and this point must be borne in mind where bimanual examinations are made in a suspicious case, for not infrequently symptoms of grave hæmorrhage rapidly supervene on the examination.

OPERATIONS FOR ECTOPIC GESTATION IN WHICH GRAVE SYMPTOMS ENSUE BETWEEN THE THIRD AND FOURTH MONTHS.

This chiefly concerns (*a*) secondary ruptures of broad-ligament gestation sacs, (*b*) rudimentary cornual pregnancies, and (*c*) interstitial pregnancies.

(*a*) *Secondary rupture of broad-ligament pregnancies at the third to fourth month.* In these cases there is always more disorganization of the appendages, and anatomical relations are not so easily identified. The source of the hæmorrhage cannot readily be localized: it may present itself as a large oozing area on the floor and side of the pelvis or lateral uterine wall.

The belly is to be opened promptly: the affected appendages are easily recognized, and as a rule a fœtus (at least 2 to 3 inches in length) quickly comes into view, since it has escaped from the rent in the sac-wall. The affected broad ligament should be elevated to the wound-level and as much of the placental tissue and fœtal envelope removed as possible. This as a rule comes away easily. There now remains a large oozing area to be controlled. If the hæmorrhage is very severe, the main blood-supply of the area should be controlled by ligature of the ovarian artery at the infundibulo-pelvic ligament and the uterine anastomosis at the cornu. A swab rung out of hot saline solution may be in the meanwhile packed down on the pelvic floor. If bleeding still continues after the main blood-supply has been secured, search for its source should be continued lower down in the wound: it may be coming

from the uterine artery on the wall of the uterus or more laterally on the pelvic floor; all small bleeding points must be controlled. It is seldom necessary to pack the floor of the pelvis with gauze in these relatively early cases, but experience alone will teach the operator what degree of oozing or what extent of raw oozing surface he can safely leave when he closes the abdomen. Temporary pressure, during the late stages of the operation, with swabs wrung out of hot saline solution at a temperature of 115° F. is, as a rule, effective.

In some of the more severe cases where oozing from a large surface in the floor of the pelvis is formidable and the operator feels it unsafe to close the abdomen without further attempts to arrest it, he can open the posterior fornix from the vagina and bring out the end of a gauze drain which has been packed down firmly over the bleeding area.

(*b*) *Rudimentary cornual pregnancy.* This variety of ectopic gestation is seldom recognized before urgent symptoms of bleeding show themselves, and the diagnosis is as a rule established only after laparotomy. The deviation of the normal half of the uterus to its corresponding side is seldom absent and should suggest the condition to the surgeon. (See Fig. 105.) The diagnosis would rest upon the presence of a soft cystic para-uterine gestation sac. The uterus may be recognized as a solid organ not proportionably increased to a size corresponding to the period of amenorrhœa. Hegar's sign would not be obtained on grasping it bimanually; as a rule the sound will rightly not have been employed in these cases, since intra-uterine pregnancy is almost inevitably diagnosed. Uterine pregnancy complicated by an ovarian cyst (possibly twisted) simulates the condition exactly and is the chief differential diagnosis.

Bleeding from the decidua of the unimpregnated uterus again confuses the clinical picture. The hæmorrhage that ensues on rupture of these sacs is literally that from a ruptured uterus. A large number of the museum specimens are obtained from the dead-house and attest the severity of the bleeding unless surgical interference is of the promptest.

Where operative interference is timely the technique is extremely simple. The para-uterine sac (as seen in Fig. 105) is connected on its mesial aspect with the uterus by a thin fibro-muscular septum, for the most part bloodless. The blood-supply lies wholly on the lateral aspect of the sac and reaches the sac through a mesometrium. This can be easily secured by a couple of clamps and the sac removed without further blood loss, since the vascular supply (ovarian and uterine arteries) is at once secured. In the case illustrated in Fig. 105 the patient owed her life to dense adhesions of bowel and omentum forming a spurious

capsule roofing in the leaking sac from above. Symptoms of leakage had existed for about twenty-four hours before admission, and but for these adhesions a rapidly fatal inundation of the peritoneal cavity with blood would have ensued.

(*c*) *Interstitial pregnancy.* In these cases the sac is so intimately in relation with the uterus that a conservative operation (preservation of the uterus) cannot be effected. The most rapid form of removal of the uterus—supravaginal hysterectomy—is the treatment recommended.

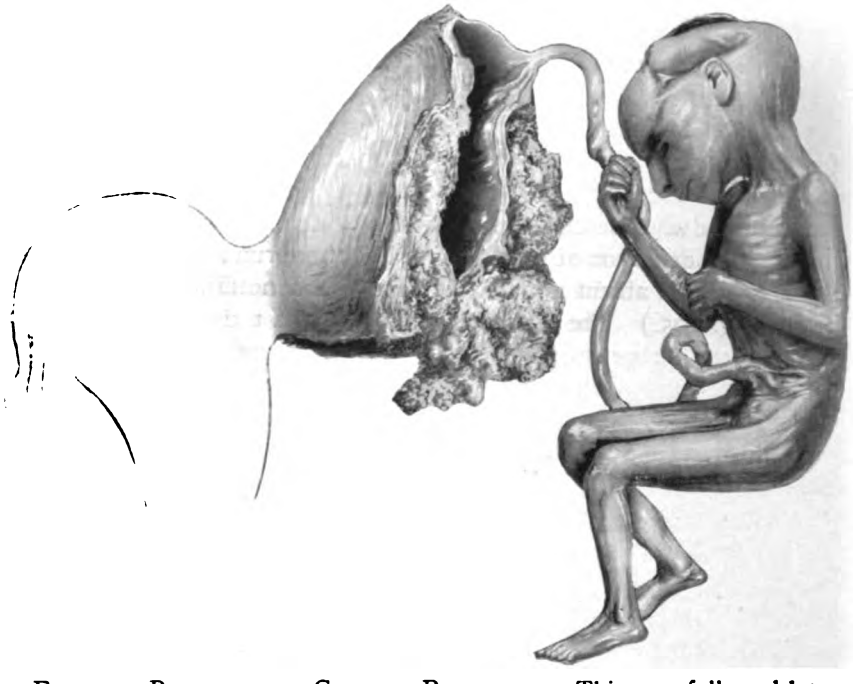

FIG. 105. RUDIMENTARY CORNUAL PREGNANCY. This was followed later by normal pregnancy and labour in the uni-corn uterus.

In the case illustrated in Fig. 106, the surgeon has been fortunate enough to operate before rupture of the sac. The indications were, very severe pain, in the presence of signs and symptoms of pregnancy, with a tender mass in relation to the uterus, thought to be either a twisted ovarian cyst or a tubal gestation.

This variety of gestation sac, situated as it is in the uterine wall, is capable up to a very considerable degree of hypertrophy and dilatation of its walls. Diagnosis of this variety of gestation sac is made by inspecting the relation of the round ligament after the belly has been opened. The round ligament is inserted directly on to the sac. These

pregnancies are frequently continued without untoward results up to the fourth month of gestation, when thinning and rupture of the sac inevitably take place. The rupture may proceed in two directions, either into the uterine or peritoneal cavity, and frequently in both directions.

Bleeding is necessarily severe from the ruptured uterus and fatal consequences the rule.

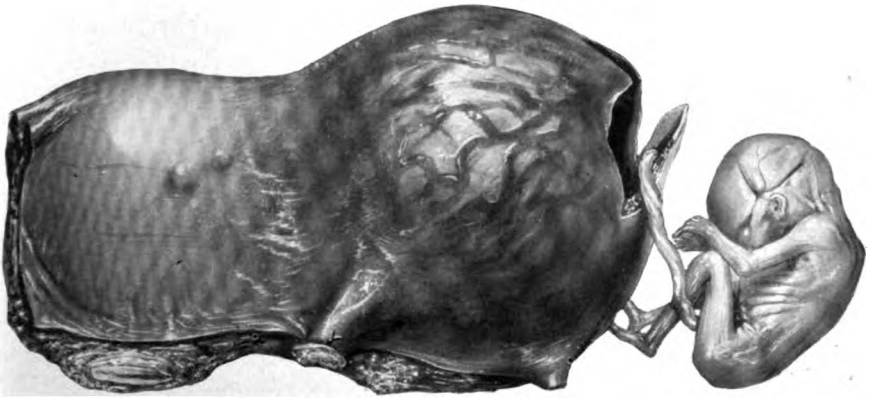

FIG. 106. INTERSTITIAL PREGNANCY.

OPERATIONS FOR ECTOPIC GESTATION IN THE LATER MONTHS OF PREGNANCY

It is here that there is the greatest divergence of opinion as to the time when operative interference should be undertaken. Should the operator delay with a view to obtaining a viable child at term by laparotomy? Should he operate at once with a view to avoiding the risks of delay, which are great, for grave hæmorrhage may at any moment ensue from the placental site if it lie superior to the fœtus? Should he await the onset of full term and spurious labour with the consequent death of the fœtus and the avascularization of the placenta, which will reduce the risks of hæmorrhage during operation and facilitate the immediate removal of the placenta? The records of these cases prove that no definite general pronouncement can be made on these points, for everything will depend on the situation of the placenta, the nature of its vascular connexions, and whether the placenta is 'dead' or 'living,' facts which can alone be determined after the belly has been opened. Thus if the placenta be situated below the fœtus and intimately connected with the pelvic floor or its lateral walls, when separated its oozing site

is amenable to firm packing with gauze from above. If, on the other hand, the fœtus be developing in the broad ligament as a retro-peritoneal pregnancy with the placenta situated above the fœtus, in the course of development it will continually be dislocated and acquire fresh adhesions to and an intimate blood-supply from the bowel (both small and large). These are the cases where immediate separation of a 'living' placenta (after removal of the fœtus) is wellnigh impossible owing to the danger of wounding gut, while leaving it behind invites an infection from the contiguous bowel which is the greatest source of danger next to fatal hæmorrhage.

Weighing all these points against each other, and accepting the evidence of statistics, it would appear that delay in operation is not justifiable, that laparotomy should be undertaken at once without regard to the viability of the fœtus, and that every effort must be made to remove the living placenta with avoidance of injury to delicate contiguous structures such as bowel. As far as possible main blood-vessels must be ligatured before effecting the placental separation. This will obviously be an easier matter where the placental side is pelvic, but may be impossible where the main placental blood-supply is mesenteric. In these cases the operator has often been forced to leave the placenta *in situ* after the sac has been 'marsupialized,' its edges being sewn to the edges of the abdominal wound with the view to localizing the almost inevitable sepsis that will attack the disintegrating placenta.

OPERATIONS FOR TUBAL ABORTION

Generally this form of termination of ectopic pregnancy (tubal abortion) occurs when the ovum is lodged in the outer (cœlomic) half of the tube, and the closer to the ostium the ovum is embedded, the greater the ease and the greater the probability of its complete expulsion.

Hæmorrhage takes place in several situations at this stage, the more severe being due to an internal laceration of the tube, the blood effused round the ovum bursting back again into the lumen of the tube which the ovum had previously quitted on embedding itself. If this hæmorrhage completely surround the ovum it will be stripped all round its periphery from the tubal site and find its way back through the internal site of rupture into the lumen. Hence it is propelled towards the ostium by a combination of reverse tubal peristalsis and pressure behind it of outpoured blood. If the rent in the inner lining of the tube be not too severe, and the ovum completely aborted or extruded from the ostium, there is every reason to believe that the bleeding will cease spontaneously.

The other plane of hæmorrhage is situated in the chorio-decidual

spaces of the fœtal envelope: sometimes the hæmorrhage into the fœtal tissues is limited to this area, the amniotic cavity is preserved though encroached on, and when the mole is opened it presents the typical nodular appearance known as the 'Tuberose sub-chorionic hæmatoma mole' (Bland-Sutton).

Pelvic hæmatocele. Blood thus escaping from the ostium in the course of tubal abortion accumulates at the lowest level of the peritoneum in Douglas's pouch, where it is rapidly encysted from the general cavity by adhesions of omentum and small and large bowel to the fundus and back of the uterus. With increasing tension due to slow continuous oozing from the ostium, the roof of the sac may give way and the collection of blood cease to be encysted. This result may sometimes be seen to have taken place where the patient has been examined bimanually prior to the operation; investigation should therefore be conducted as carefully as possible.

Peritubal hæmatocele. The blood escaping slowly from the ostium may sometimes coagulate without forming adhesions to contiguous viscera, and form a rounded elongated mobile tumour simulating an ovarian cyst or hydrosalpinx. This tumour is formed by coagulated blood and its outer layers are composed of dense laminated fibrin, the central core, where the bleeding is more recent, being softer and composed of fluid.

Para-tubal hæmatocele is the name given to a similar collection of coagulated blood where the hæmorrhage is proceeding from a rent in the tube and a blood-tumour is formed alongside the tube. It is a rare condition.

Differential Diagnosis. The most difficult differential diagnosis is the early stage of a subacute attack of perimetritis and in a doubtful case every possible attempt should be made to exclude this affection. This is of the highest importance to the welfare of the patient where an attack of perimetritis so often undergoes wellnigh complete resolution with restoration of function, operative interference during a first attack being contra-indicated. Much assistance can now be rendered by testing the patient's blood for the presence of Abderhalden's delicate peptone reaction which is specific for pregnancy. The technical difficulties of this test are being overcome, and most of the pathological laboratories will shortly be able, we hope, to pronounce with confidence on the presence or absence of pregnancy. Pyrexia frequently accompanies both perimetritis and tubal abortion, and may prejudice the diagnosis in favour of the inflammatory cause. It is essential that thorough investigation of the lower genital tract should be carried out with a view to the detection of signs of previous ascending infection. Thus the urethra, the

bulbo-urethral ducts (Bartholin's ducts) and the cervical mucosa should be carefully examined, and in doubtful cases a 'smear' prepared with a view to detecting the presence of the gonococcus.

Physical signs of pelvic hæmatocele. By the abdomen, in a typical case of a fairly large effusion of blood, the small unappreciably enlarged uterus can be made out as a nodular mass pressed close against the hypogastric wall a couple of inches above the pubes (the uterus has been pushed forwards and upwards by the large collection of blood-clot below and behind in Douglas's pouch); on vaginal examination the cervix is drawn up almost out of reach of the finger-tip, while the posterior fornix is depressed by a soft semi-fluctuating swelling (the lower pole of the blood coagulum). This displacement of the cervix associated with a depression of the posterior fornix and posterior vaginal wall resembles strongly the physical signs of incarcerated gravid uterus. The recognition of the uterus above and in front settles the diagnosis.

Indications for operation. It has been stated that the difference between the expectant attitude and operative interference in this affection is that between three months enforced rest and three weeks in bed after a laparotomy. This statement would seem to imply that after operation the patient would resume an active life within a month—a post-operative history which is neither probable nor advisable. The balance of opinion is very much in favour of operation. In support of this view are the following:—

(*a*) There is always an uncertainty as to whether the ovum has ceased to grow or still retains its active powers of invasion unimpaired.

(*b*) The pregnancy may be an intra-ligamentous one with probabilities of later secondary rupture.

(*c*) Possibilities of development of malignant properties of the fœtal epiblast (chorio-epithelioma).

(*d*) The integrity of function of the opposite tube may be gravely impaired; the plastic peritonitis engendered on the pelvic floor may lead to closure of the ostium of the non-gravid tube with subsequent sterility. For this reason operation in a primigravida would be more strongly recommended.

Against these points one must not lose sight of the fact that a large number of these cases recover without operation; were there more definite records of parity following the expectant treatment we could pronounce more confidently on this point.

Apart from these general *reasons* operation may be said to be specially indicated in the following circumstances:—

(*a*) *Where pain is severe and unrelieved by ordinary measures,* this implies increasing tension in the sac caused by continued oozing.

(*b*) *Where increasing pallor and raised pulse-rate point to continued bleeding.*

This will usually point to failure of encystment of the collection or a leakage from the roof of the sac which may be associated with rapid onset of grave signs of hæmorrhage.

(*c*) *Where the level of the roof of the hæmatocele is slowly rising in the hypogastric area and attains more than two or three fingers' breadths above the pubes.* This obviously points to a large collection of blood with continued oozing.

(*d*) *Where the collection of blood is large enough to produce such a degree of pressure on the neck of the bladder and urethra as will lead to retention of urine.*

(*e*) *Signs of pyrexia or toxic symptoms accompanied by local changes in the hæmatocele pointing to its infection from the bowel.* This complication is, however, very rarely seen.

Technique of operation. Should the vaginal or abdominal route be selected? There is much to be said in favour of the former route though it is by no means frequently practised at the present time. Its disadvantages are the limited information it provides as regards the condition of the opposite appendages. Very much in its favour is its ease and the rapid convalescence that follows a favourable case.

Vaginal route. All that is required is local disinfection of the vagina and an incision in the posterior fornix.

The posterior lip of the cervix is seized with a volsella, which is drawn forwards and upwards, thus putting the posterior vaginal wall on the stretch. The vaginal muscosa is now picked up with a toothed forceps 1 inch below the fornix, and between this forceps and the vaginal portion of the cervix the mucosa is incised in the median line with scissors in a horizontal direction for 1 inch. The peritoneum of the floor of Douglas's pouch now comes into view and is similarly incised, and the opening, if necessary, enlarged with the finger. Firm dark blood-clot escapes, and the cavity can be drained for three days by a stout rubber drainage tube, or if oozing is severe, packed with gauze, which can be wholly removed in the same number of days. The immediate results of this posterior colpotomy are remarkably successful, the sole criticism against its routine use being the inability accurately to inspect the condition of the opposite appendages except in very exceptional cases.

Abdominal route. After opening the abdominal cavity, the upper margin of the hæmatocele roofed in by omental and bowel adhesions is easily seen below and behind the uterus but often roofed in by the uterus itself.

The plane of cleavage in this area of adhesions can as a rule be

recognized at once. The index finger is gently inserted along it, keeping close to the posterior uterine wall: as soon as the separation of adhesions along the roof is effected, black blood-clot wells up and reveals the encysted cavity whose floor is Douglas's pouch. The cavity is opened up as widely as possible and search made for the affected tube. The side of the gestation sac can generally be seen from above by the dilatation of the affected tube, which is as a rule raised with ease from the pelvic floor, and inspected. The ovum is often seen in the act of escaping from the dilated ostium. More often the tubal ostium is patulous, the ovum having been expelled from the tube. Next, see if the corresponding ovary can be identified free of the gestation sac: if so, it must be preserved: if encroached on and disorganized, it must be removed with the tube. Salpingectomy alone must, however, always be aimed at.

After removal of the affected tube, examine the opposite tube. Its ostial fringes may be adherent and the lumen occluded as the result of the reactionary pelvic inflammation induced by the irritation of the effused blood. Before closing the abdomen the operator should always, therefore, satisfy himself of the functional integrity of the remaining tube, and if necessary restore its patency either by reopening its ostium or carrying out the operation of salpingostomy. It is to be hoped that in the future there will be records of even more conservative technique than this in favourable cases. Where the ovum has completely escaped from the ostium, where there is little damage to the tube, and where there is no further bleeding from the tube under inspection, there is every reason to believe that freeing adhesions and removing the blood-clot is all the surgeon need do, for the tube in all probability is capable of regaining its normal function.

SECTION XI

THE OPERATIVE TREATMENT OF UTERINE DISPLACEMENTS

THE OPERATIVE TREATMENT OF CYSTOCELE, UTERINE PROLAPSE, AND LACERATIONS OF THE PERINEUM

BY

THOMAS J. WATKINS, M.D., F.A.C.S.
Professor of Gynæcology, Northwestern University Medical School; Attending Gynæcologist, St. Luke's Hospital, Chicago

THE OPERATIVE TREATMENT OF RETRODISPLACEMENTS

BY

ARTHUR H. CURTIS, B.Sc., M.D., F.A.C.S.
Clinical Professor of Gynæcology, Northwestern University Medical School; Attending Gynæcologist, St. Luke's Hospital, Chicago

OPERATIONS FOR INVERSION OF THE UTERUS

BY

REUBEN PETERSON, A.B., M.D., F.A.C.S.
Professor of Obstetrics and Gynæcology, University of Michigan Medical School; Obstetrician and Gynæcologist-in-Chief, University Hospital, Ann Arbor

CHAPTER I

OPERATIVE TREATMENT OF CYSTOCELE, UTERINE PROLAPSE, AND LACERATIONS OF PERINEUM

In a cystocele the chief lesion is the injury to the fascia of the anterior vaginal wall, which may vary greatly in extent and variety. The reason

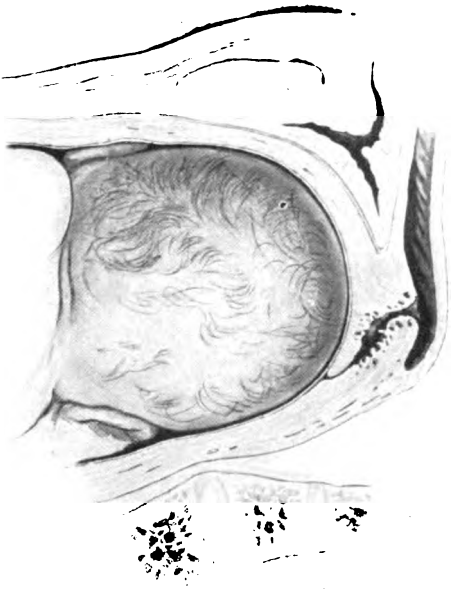

Fig. 107. Displacement of the Bladder and Urethra During Labor. The cervix is not yet dilated or retracted.

for this is easily appreciated by an examination of Figures 107 and 108. Figure 107 shows the displacement which takes place in the anterior vaginal wall and bladder during childbirth. Figure 108 shows the amount of displacement of the bladder and urethra after the child's head has escaped through the cervix and the cervix has retracted. It will be seen that the pathology consists chiefly in the separation of the anterior vaginal

wall from its normal attachment. The fascia may be split, attenuated, or completely separated from the bony pelvis. Figure 112 illustrates a typical case of hernia of the bladder with the formation of a distinct ring by the pillars of fascia. Figure 113 illustrates a partial reduction of the hernia of the bladder.

FIG. 108. CHANGE IN THE POSITION OF THE BLADDER AND URETHRA AFTER RETRACTION OF THE CERVIX.

Urethrocele is a downward displacement of the urethral canal. As its fascial attachments are stretched or torn the urethra rotates underneath the lower border of the pubes; the amount of displacement is proportionate to the degree of injury. Figure 109,*a* illustrates the displacement. The urethra has not separated from the pubes but its relation to the pubes has been changed. Figure 109,*b* shows the urethra pushed backward into its normal position. One can recognize the changed relation of the urethra to the labia minora; instead of a convexity, as shown

in Figure 109,*a*, a concavity occurs over the body of the uretha. Both facts should be kept in mind in the treatment of urethrocele.

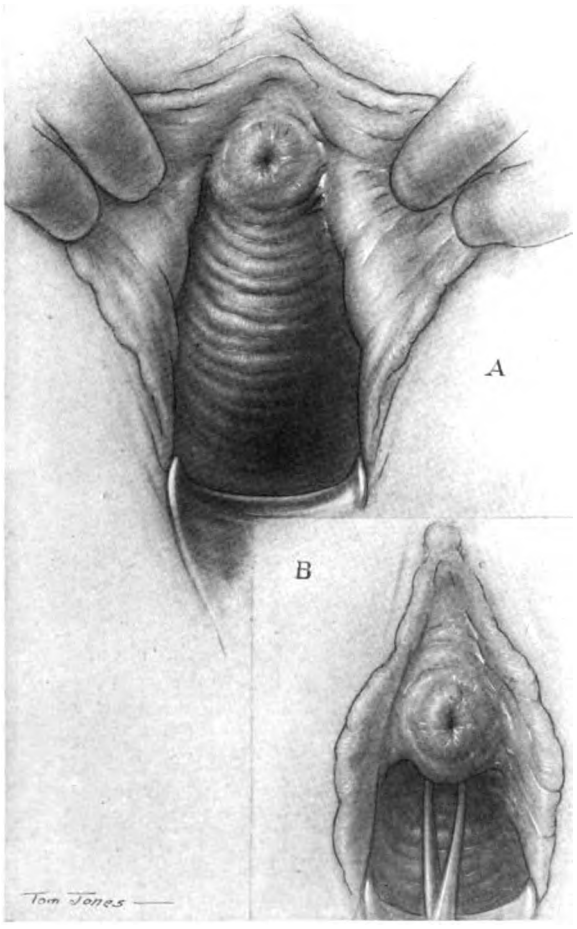

FIG. 109. URETHROCELE. In the lower figure the displaced urethra is returned to its normal position.

The choice of operative procedure depends upon numerous factors, but chiefly upon the extent of the lesion and the age of the patient. The relative indications will be given under the individual operations.

Transposition operation. The patient is prepared as is usual for plastic gynæcological surgery. Tincture of iodine, one-half strength,

is used for the preparation of the vaginal mucosa and adjacent skin surfaces. Great care should be exercised that the entire vaginal mucosa is painted with iodine. In most cases it is necessary to expose the vagina

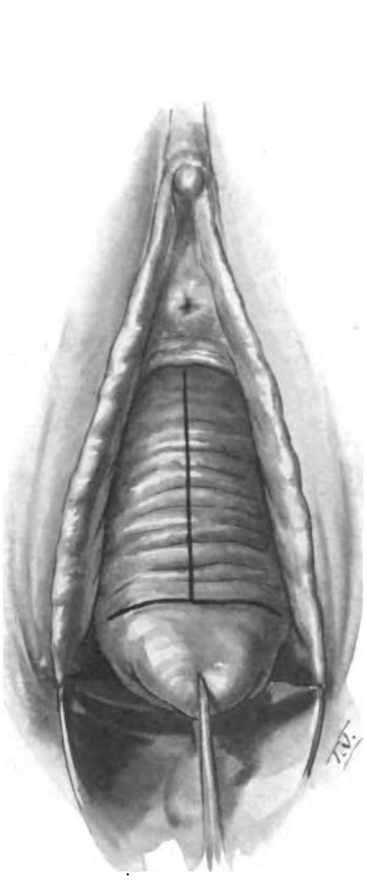

FIG. 110. TRANSPOSITION OPERATION. Lines of longitudinal and transverse incisions.

FIG. 111. TRANSPOSITION OPERATION. Separation of the bladder from the anterior vaginal wall.

thoroughly by means of a vaginal speculum, and by grasping the cervix with a bullet forceps in order to bring into view all the invaginated membrane. When this is done there is still danger of skipping certain areas unless great care is exercised. Very thorough preparation of the

vaginal mucosa is important because of the great danger of infection when extensive vaginal operations are performed.

In cases of leukorrhœa of long standing, with considerable vaginal discharge, pre-operative disinfection of the vagina by two-hourly instilla-

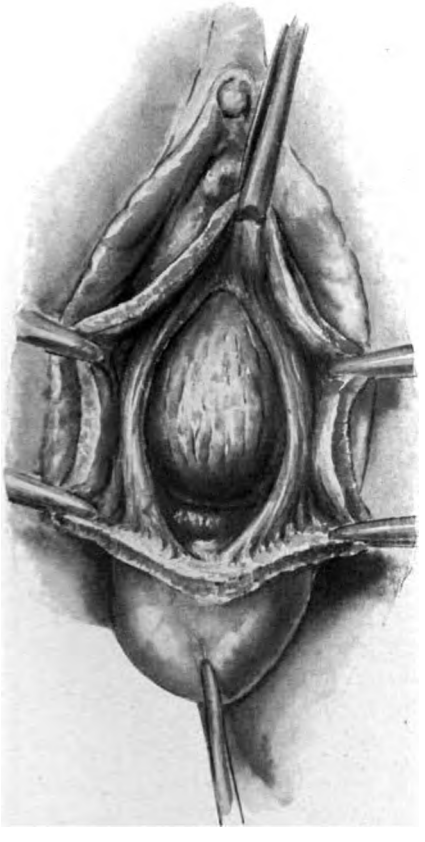

FIG. 112. TRANSPOSITION OPERATION. Dissection showing the fascial ring through which the bladder tends to herniate.

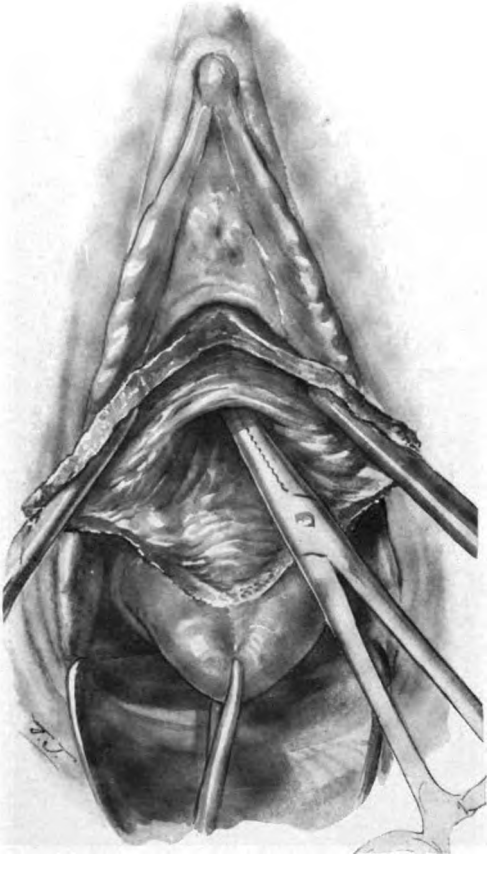

FIG. 113. TRANSPOSITION OPERATION. Partial reduction of the hernia of the bladder.

tions of Dakin's fluid, or irrigation with potassium permanganate solution three times daily may well precede operation. While the organisms present in the vagina are usually of low virulence, a widespread cellulitis may follow the implantation of bacteria over extensive raw areas.

With the patient in the lithotomy position a curettage is performed, if necessary for diagnostic purposes, but usually not otherwise. Separation of the vagina from the bladder is done by blunt dissection, as illustrated in Figure 111. With a little experience and care the fascial plane which separates the vagina from the bladder is easily found and followed. The advantage of this separation is that it is quickly done and

FIG. 114. TRANSPOSITION OPERATION. Separation of the bladder from the cervix.

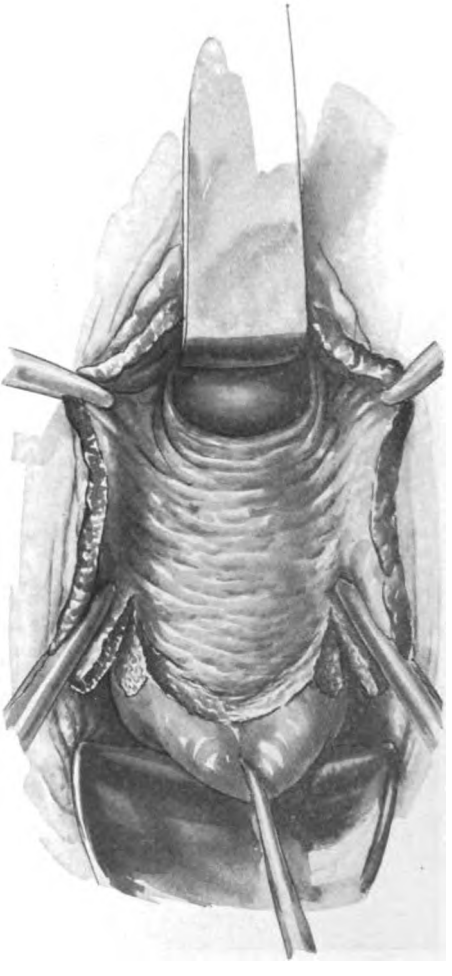

FIG. 115. TRANSPOSITION OPERATION. The fundus appearing through the opening in the peritoneum.

there is very little injury to the blood vessels. It should extend downward sufficiently far thoroughly to expose the triangular fascia about the urethra and to permit the removal of the hypertrophied mucosa which may be present about the urethra. The amount of separation will vary with the size of the cystocele. Care should be used, however, not to carry the separation too far laterally as it will then result in an unnecessary

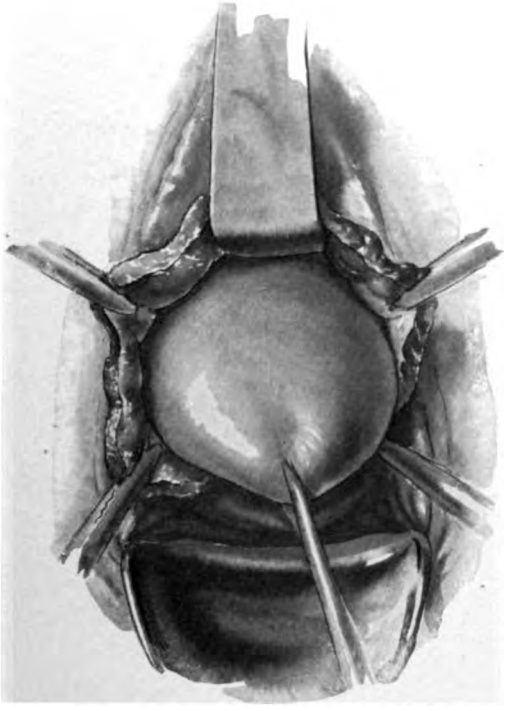

FIG. 116. TRANSPOSITION OPERATION. The fundus pulled down into the field of operation.

amount of bleeding. An 8-inch forceps should be placed upon the edge of one of the vaginal flaps and the fascia separated from the mucosa by blunt dissection. This fascia, as illustrated in Figure 112, is to be utilized later in closure of the hernial opening.

Separation of the bladder from the cervix is also accomplished by blunt dissection with Mayo scissors (Fig. 114). The fascial plane is easily found by the use of a moderate amount of care and the separation is quickly and safely accomplished. The point of the scissors should

always be directed away from the bladder to guard against injuring this structure. If a fairly well formed vesicocervical ligament is encountered in the median line, it should be severed. One can easily determine by palpation when the bladder has been sufficiently separated from the

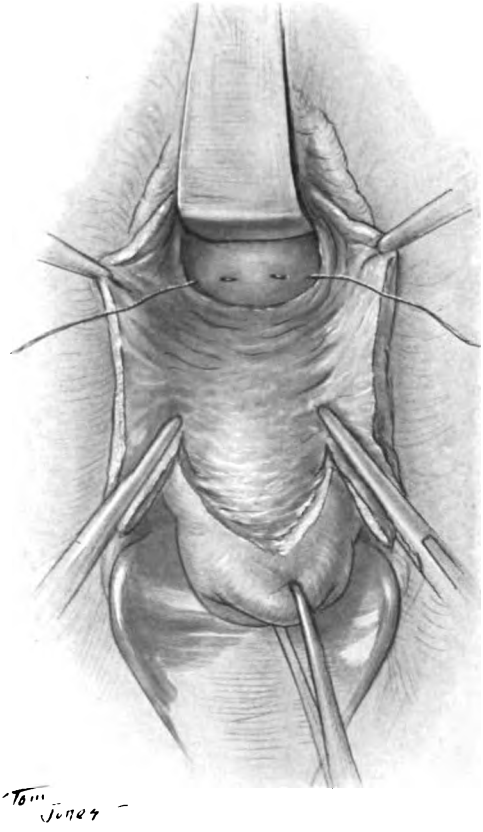

FIG. 117. TRANSPOSITION OPERATION. Suture placed through the fundus of the uterus.

cervix, for when the peritoneum is reached the tissues between the finger and cervix lose their feeling of fixation.

The facility with which incision of the peritoneum can be accomplished varies much in individual cases and with the technique that is used. Care should be taken not to dissect off the peritoneum too widely until it has been opened, otherwise it may be pushed up so high as not to be easily accessible.

In delivery of the body of the uterus the important features are to be certain that the opening is sufficiently large to allow the body of the

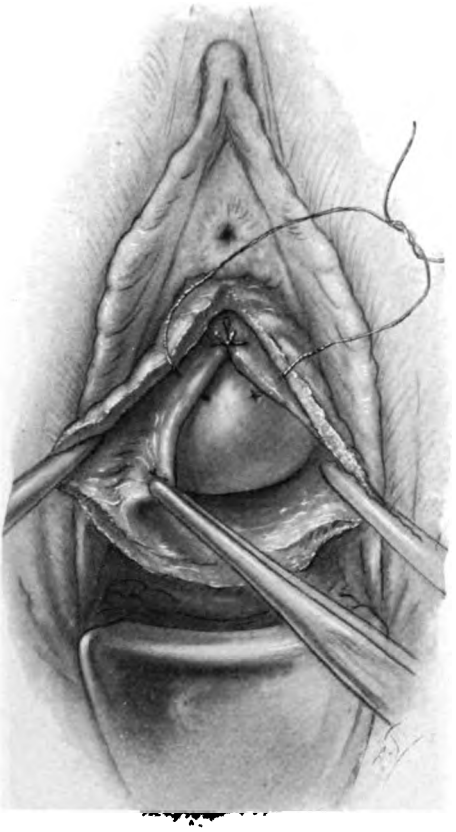

FIG. 118. TRANSPOSITION OPERATION. Suture of the pillars of fascia to the fundus.

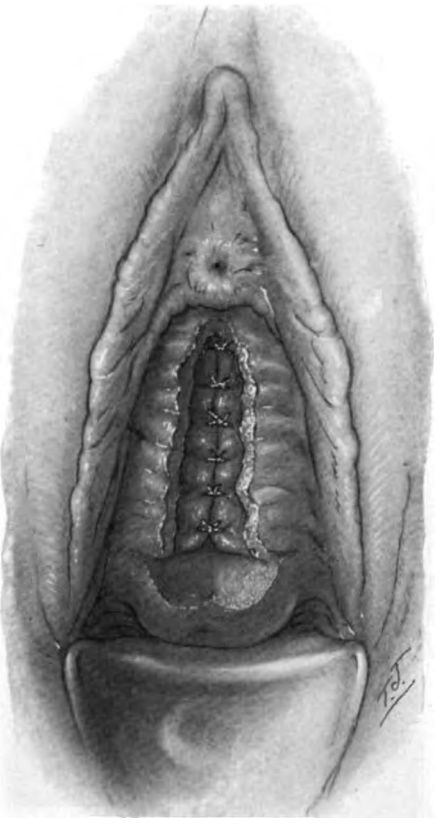

FIG. 119. TRANSPOSITION OPERATION. Fascial suture completed; anterior lip of the cervix partially excised.

uterus to be delivered readily; and to be sure that the fundus is grasped before delivery is attempted, as the diameters of the fundus are much less than the diameters of the anterior uterine wall. Delivery will also be made difficult by the presence of peritoneal adhesions or by other diseases of the ovaries and tubes.

Closure of the hernial opening is accomplished by suturing the pillars of fascia of the anterior vaginal wall to the uterus and bringing them together in the median line (Fig. 118). The amount of fascia which is

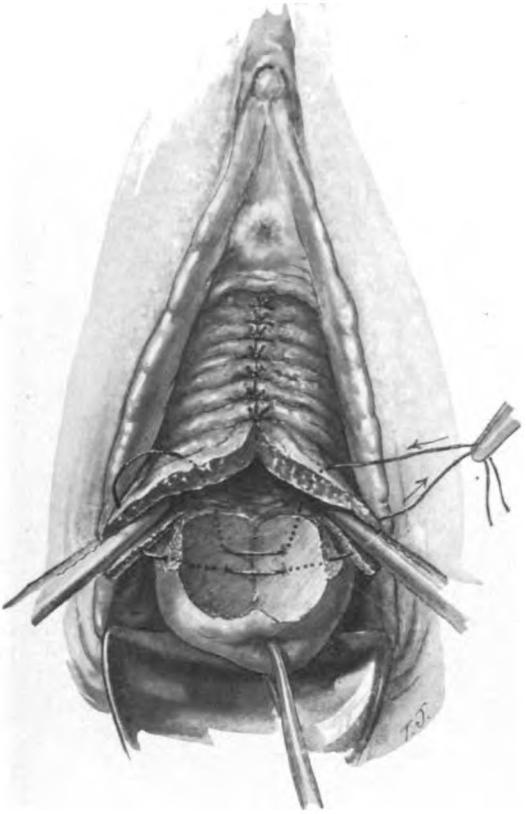

FIG. 120. TRANSPOSITION OPERATION. Suture of the anterior cervical lip.

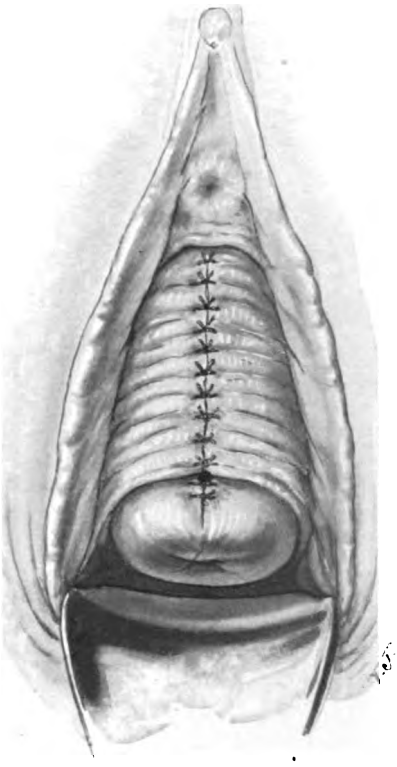

FIG. 121. TRANSPOSITION OPERATION. Incision closed with interrupted sutures.

obtainable is a continued source of surprise, and can be ascertained only by picking it up freely with forceps. The sutures should be so inserted that there will be no place for the bladder to herniate between the fundus and the pubes, and that no excessive amount of pressure will be exerted upon the urethra. This is generally accomplished by passing the first suture through the uterus on the line of the fallopian tubes. The first

suture should exert enough tension upon the fascia to restore the urethra to its normal location; this can be determined by noting the amount of fixation of the urethra which it accomplishes. It should render the urethra comparatively firm, which is its normal condition.

Interrupted sutures of catgut, or figure-of-8 sutures, constitute the inner line of union and allow good drainage of the wound. Figure 119

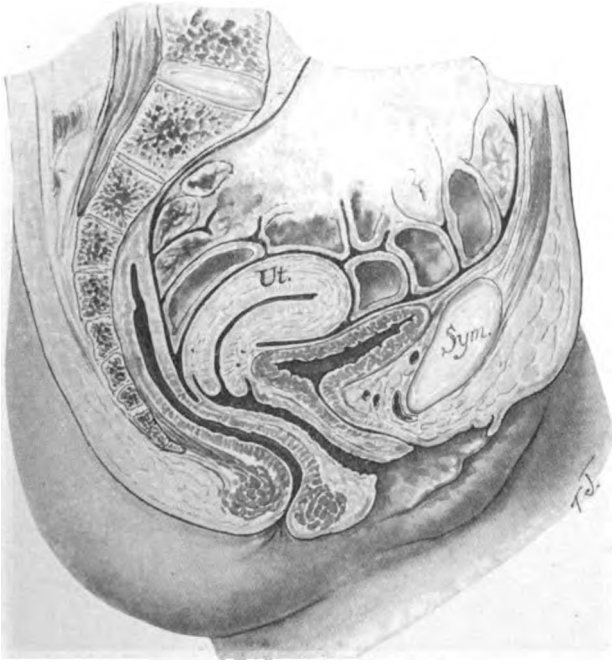

FIG. 122. SAGITTAL SECTION OF NORMAL PELVIS.

shows the completed suture of the fascia to the uterus. Each of these sutures should grasp the uterus so as to leave no space in which blood can accumulate and become infected by vaginal bacteria.

The anterior lip of the cervix is generally excised, as the excision leaves a smooth surface and forces the cervix upwards and backwards. The mucous membrane flaps are trimmed so as to remove all redundant tissue and make a smooth line of approximation. The mucosa is closed by ordinary interrupted sutures or by submucous sutures. Figure 123 shows the relative position of the uterus, bladder, and urethra after the

transposition operation is completed and after perineorrhaphy has been performed.

Examination of Figure 123 will show that the uterus is not tilted forward as much as would be expected. It also shows that the stretched out base of the bladder is not pinched but is left comparatively stretched, the

FIG. 123. SAGITTAL SECTION OF PELVIS FOLLOWING TRANSPOSITION OPERATION AND PERINEORRHAPHY.

importance of which has been well expressed in the writings of Dr. J. Riddle Goffe.

Certain precautionary measures in transposition operations are especially important. The very large uterus should not be transposed without removal of part of the uterine body. In cases of extensive prolapse of the uterus the tissues of the broad ligaments should be invariably separated in part from the cervix and attached together in front of the cervix. Much hypertrophy or elongation of the cervix should be corrected by amputation.

Figure 123 does not show any excision of the anterior lip of the cervix, a feature which at times is not necessary where senile atrophy

has occurred. It is almost invariably necessary to do a perineorrhaphy, the technique of which will be described later.

The transposition operation is especially well adapted to cases after the menopause where there is marked cystocele without much enlargement or prolapse of the uterus. The operation is advised during the child-bearing period only in cases where the lesion is extensive and where there is little or no probability of more pregnancies. In such cases it is necessary to render the patient sterile, as the operation would complicate pregnancy and labor. This may be done by excision of a small part of each tube near the uterus and by careful closure. Ligation is not sufficient, as was demonstrated years ago by Dr. Emil Ries.

It is often necessary to modify the operation to meet individual conditions which will be discussed under the various operative procedures.

Vaginal fixation of the round ligaments. This procedure has many of the features of the vaginal fixation of the round ligaments which was developed many years ago for the treatment of retrodisplacements of the uterus.

The technique is much like that employed for the transposition operation except that the round ligaments are delivered and fixed instead of the fundus of the uterus. The fixation should be so regulated that sufficient traction will be exerted upon the fascia to which the ligaments are attached to restore the urethra to its normal location, and to cure the urethrocele which is almost invariably present. Enough of the ligament should be included to ensure a decided anterior position of the uterus. The fixation is preferably made with linen. In closing the wound care should be used not to attach the fascia to the uterine wall except for a short distance above the peritoneal reflection from the uterus to the bladder, as adhesions beyond this point might complicate pregnancy and labor. It is customary to excise some of the anterior lip of the cervix (Fig. 124).

This operation is especially well adapted to cases of cystocele and uterine prolapse with retrodisplacement for patients in the reproductive age, for during this period the amount of prolapse is not very extensive. Without retrodisplacement the ligaments are generally not sufficiently long to be utilized for fixation without causing undue tension upon them.

Advancement operation. This is a modification of the transposition operation in that the pillars of the fascia are sutured to the anterior wall of the uterus without delivery of the body of the uterus. Attachment is made to the uterus about one-half inch above the line of reflection of the peritoneum from the uterus. The attachment should be beyond the "pivotal point", so that the tendency for the uterus will be to tilt forward. Otherwise, the uterus tends to become tilted back-

wards and pulled downwards, with a consequent shortening of the anterior vaginal wall. The fascia should be sutured as in other instances, so that the urethra will be drawn back and fixed in its normal location.

This operation is adapted to the treatment of a large percentage of cases of cystocele and uterine prolapse in women during the reproductive

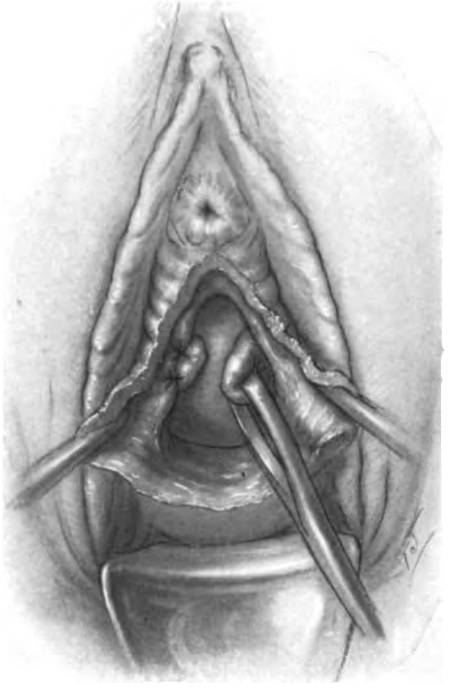

FIG. 124. VAGINAL FIXATION OF THE ROUND LIGAMENTS.

age. One encounters comparatively few cases at this age where the displacement cannot be satisfactorily relieved by such an operation. It does not interfere with pregnancy or labor. It is very often combined with shortening and displacement of the broad ligaments and cervical amputation.

After exposure of the pillars of the fascia the broad ligaments are clamped with an 8-inch forceps on either side. The broad ligaments are incised between the forceps and the cervix, the extent of the incision varying with the individual requirements. Care should be exercised that

the bladder is thoroughly separated on either side so as to avoid injury to the bladder and ureters. A section of the anterior lip of the cervix should usually be excised as shown in Figure 119. The suture unites the two free ends of the broad ligaments in front of the cervix. By shortening the broad ligaments and displacing them in front of the cervix, and as a

FIG. 125. AMPUTATION OF THE CERVIX. Deep bilateral incisions completely expose the diseased tissue.

FIG. 126. AMPUTATION OF THE CERVIX. Excision of the anterior lip in such a way as to leave a considerable amount of cervical mucosa.

result of the plastic operation on its anterior lip, the cervix is displaced upwards and backwards.

Shortening and displacement of the broad ligaments can be carried out with great advantage in all cases where there is much prolapse of the uterus. It very materially extends the use of the operation of vaginal fixation of the round ligaments and of the advancement operation, as by this combination these operations can be made effective for the cure of rather extensive cases of displacement during the reproductive period.

Amputation of the cervix uteri. Amputation of the cervix is often necessary as an adjunct to other operative procedures for the cure

of cystocele and uterine prolapse since in a large percentage of such cases there is an hypertrophy and elongation of the cervix. Amputation of the cervix always adds materially to any operative procedure for prolapse, except for the danger of stenosis following amputation, and the possible interference with labor in case of pregnancy.

Only in exceptional cases, in which the hypertrophy and elongation of the cervix is extensive, is high amputation necessary. Usually excision of the anterior lip is sufficient, though a wedge-shaped piece may be excised from the posterior lip in conjunction with the excision of the anterior lip.

Either lip is grasped (Fig. 125) and a deep bilateral incision is made which should extend beyond the part that is to be excised. Such an incision helps to make the parts accessible and to expose the diseased tissues. It may be made with or without cuffing the cervix. The amputation is made by taking a V-shaped piece out of either lip of the cervix (Fig. 126), but it is highly desirable to leave a generous flap of the cervical canal so as to guard against stenosis. After amputation both lips of the cervix are sutured with catgut (Fig. 127). The operation is completed by inserting one or two sutures on either side to close what may be left of the initial bilateral incisions (Fig. 128).

There is little danger of making the flap which includes the cervical canal too long, as it always retracts. There is always danger of this not being made long enough to avoid stenosis. The transverse suture in either lip should be passed superficially through the vaginal mucosa and deeply through the uterine flap, so that the mucosa will be pulled into the cervix instead of the cervix being everted.

We believe this operative procedure should generally be limited to cases past the child-bearing period.

Excision of part of the body of the uterus. After delivery of the body of the uterus as previously described, the broad ligament is clamped on either side with an 8-inch forceps and as much of the uterine body excised as may be desired. After excision, ligatures replace the forceps, and the uterine wall is closed with interrupted catgut sutures. Before closure it is always advisable to use alcohol or tincture of iodine freely on the uterine wall, as these cases are very susceptible to infection from vaginal bacteria. After the wound is closed the remaining part of the uterus is sutured in much the same manner as is done in the transposition operation. It is especially important in these cases to use interrupted instead of continuous sutures, and not to place them so close together as to interfere with drainage. Care should be exercised regarding hæmostasis.

The author has in exceptional cases excised all of the uterus except

enough of the posterior wall of the cervix to form a firm rest for the bladder. In very extensive cases of prolapse of the uterus this method is preferable to total hysterectomy, as it leaves a better support for the bladder than hysterectomy, and in cases of infection and suppuration the ultimate result is almost certain of being good if enough of the cervix is utilized for bladder support. With infection and suppuration fol-

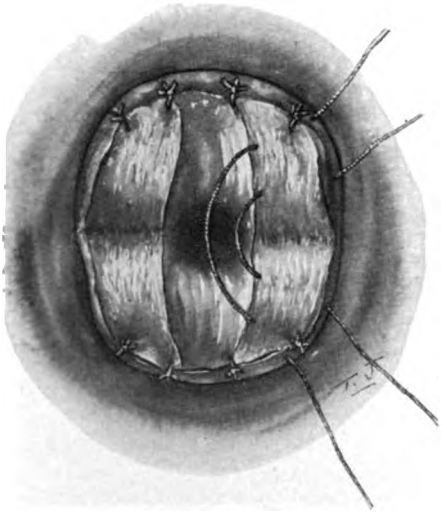

FIG. 127. AMPUTATION OF THE CERVIX. Suture of the raw surfaces.

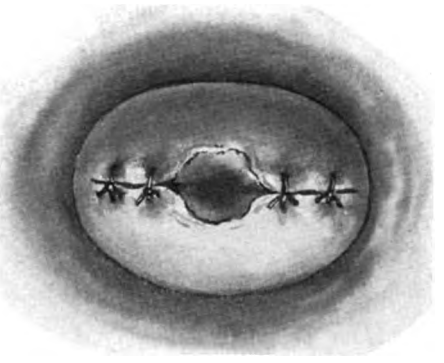

FIG. 128. AMPUTATION OF THE CERVIX. Suture completed.

lowing a complete hysterectomy there is little or no assurance against recurrence of the cystocele.

Vaginal hysterectomy. Figures 129-132 illustrate Charles H. Mayo's operation for extensive cases of cystocele and uterine prolapse. The technique is easily comprehended from a study of the illustrations.

Great care should be exercised that complete hæmostasis is obtained. To ensure this it is often advisable to unite the free ends of the broad ligaments by continuous catgut suture after the forceps have been removed. The broad ligaments are then sutured to the pillars of the fascia in the anterior vaginal wall and the mucous membrane wound closed.

The Mayo operation has a possible advantage over extensive excisions of parts of the uterus in that the danger of infection may be lessened. The operation is best utilized where the broad ligaments are sufficiently long so that they are readily sutured together back of the forceps (Fig. 131).

After-treatment. The important feature in the postoperative treatment of patients who have undergone pelvic operations is attention to the bladder, as a large percentage of these cases have a chronic cystitis and many of the operations of necessity produce considerable traumatism of the bladder wall. The catheter is not used if the patient is able

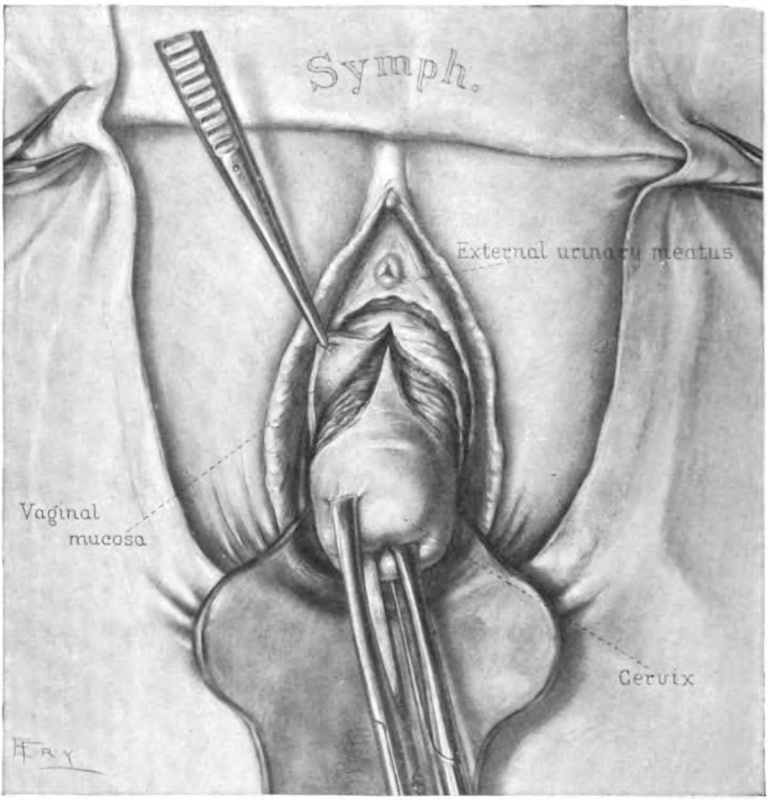

FIG. 129. VAGINAL HYSTERECTOMY. Primary pear shaped incision. (*C. H. Mayo.*)

to void urine and if no acute bladder symptoms develop. If acute symptoms develop a distended bladder is always suspected. If the patient is unable to void urine she is catheterized, and the procedure repeated as often as necessary for relief. A solution of four drams of 0.125 per cent silver nitrate is instilled into the bladder, or, if this causes irritation, a saturated solution of boric acid is used.

In the catheterized cases we use Dr. A. H. Curtis' method of testing daily for residual urine until we are certain that the bladder is emptying

itself satisfactorily. As soon as this stage is reached catheterization is stopped unless there are bladder symptoms.

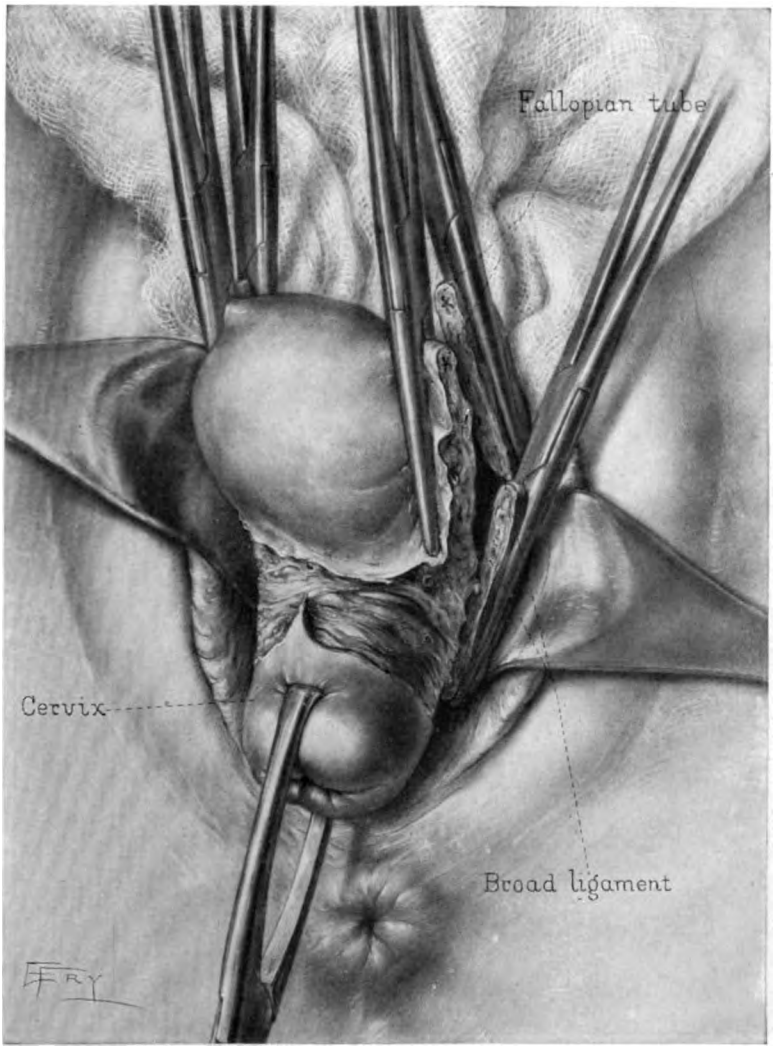

FIG. 130. VAGINAL HYSTERECTOMY. Excision of the uterus and clamping of the broad ligament. (*C. H. Mayo.*)

No internal douches are used. Instillation of Dakin's solution is employed if the vaginal secretion becomes offensive.

The after-treatment of the occasional cases that develop infection with

fever is extremely important. It consists in elevating the head of the bed, placing an icebag over the lower abdomen and wet boric dressings

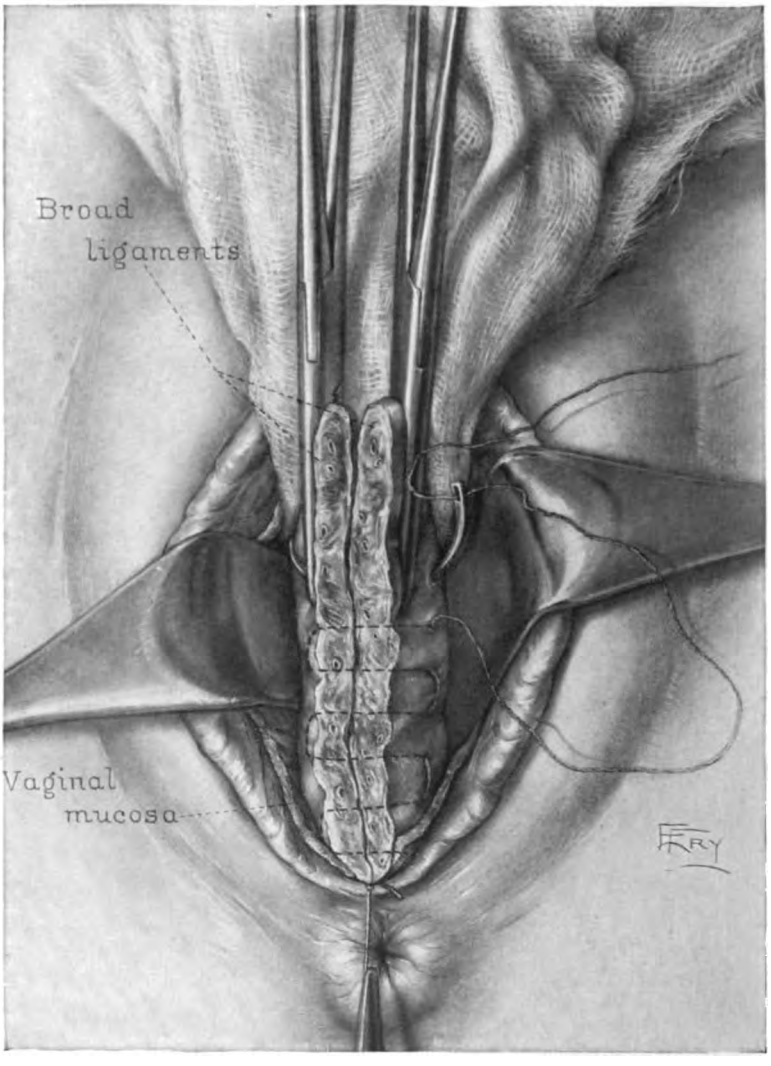

FIG. 131. VAGINAL HYSTERECTOMY. Approximation of the broad ligaments by a running mattress suture. (*C. H. Mayo.*)

over the vulva. With this treatment the fever soon subsides with little or no impairment of the operative result. The common method of removing sutures and establishing drainage in such cases is usually ob-

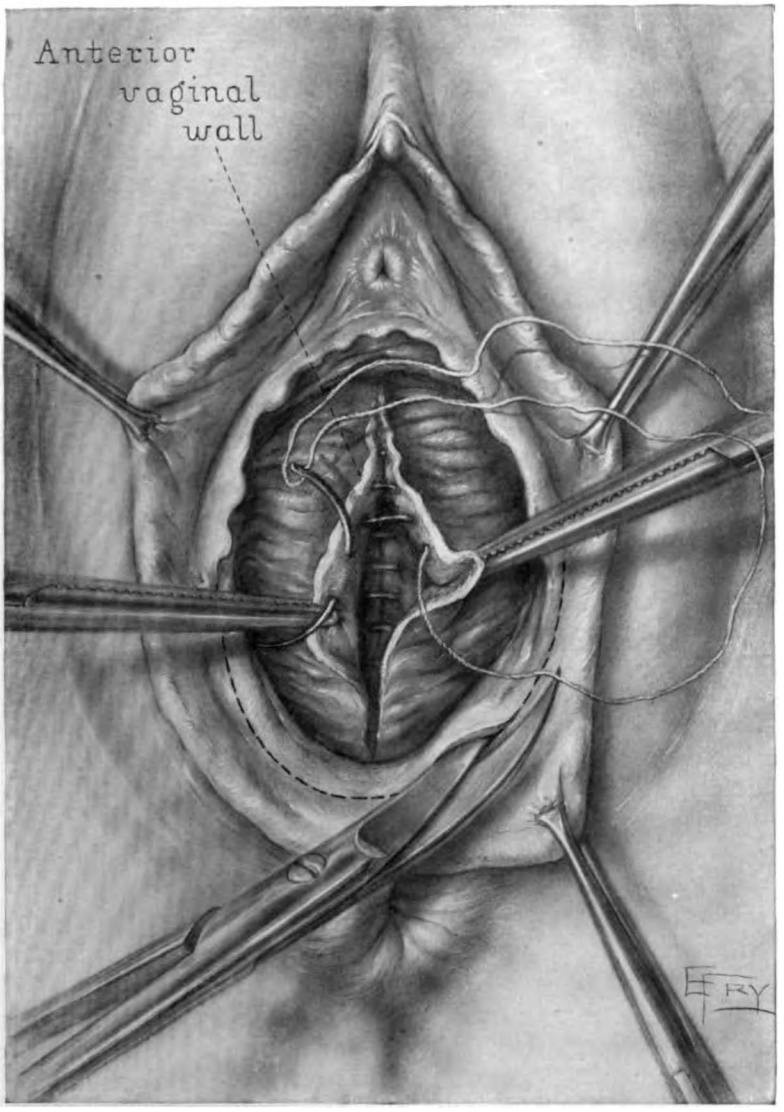

Fig. 132. Vaginal Hysterectomy. Incision of the perineal region; closure of the anterior vaginal wall. (*C. H. Mayo.*)

jectionable, as it is apt to cause extension of the infection and vitiate the result, and in the average case will not shorten the duration of the fever.

It has been our experience that the occasional case with infection obtains a satisfactory ultimate result with the above treatment. We believe it important to emphasize again the value of very thorough iodine preparation before operating and the free use of iodine or alcohol in cases of extensive operations. With this precaution infection should occur but infrequently, especially if interrupted sutures are used and not placed so close together as to interfere with wound drainage.

Patients are allowed to sit up as soon as they desire to do so, which is generally between the fifth and the tenth day. They are occasionally gotten up earlier to void urine. Otherwise treatment is the same as is generally employed following plastic pelvic operations.

With the transposition operation recurrence of the cystocele is impossible if the operation is correctly done. The result upon the urethrocele should also be certain. Vesical symptoms will occasionally persist for a time and should receive attention until the inflammation of the bladder has disappeared. The incontinence of urine which is frequently present in variable degrees in many of these cases is generally cured. I have had two cases where the result as regards continence has not been satisfactory although the anatomic result seemed to be perfect. I have also had one case that continued to have frequent urinations without any apparent cause, so far as we were able to determine.

Prolapse of the uterus after these operations should seldom, if ever, occur. In a few cases where it has occurred in our experience we believe it has been due to poor judgment in the selection of the procedure used, or to defects in the technique employed.

PERINEORRHAPHY

Perineorrhaphy will be considered under three divisions: (1) For relaxed pelvic floor; (2) for complete laceration of the perineum; (3) for high rectocele.

Perineorrhaphy for relaxed pelvic floor. This lesion is generally one of injury to the levator ani muscle and its accompanying fascia. The common form consists in laceration and attenuation of the muscle and fascia lateral to the vaginal canal, i. e., the pubic portion of the levator ani. It is not uncommon for the muscle and fascia to be separated from its bony attachments, but the most important factor is the stretching of the muscle and fascia that occurs during labor, and the incomplete involution thereafter.

All perineorrhaphies of this type are based upon the principles of

repair devised by Emmet and Hegar. These principles consist in restoration of the normal length of the levator ani muscle and fascia by lateral sutures, as advocated by Emmet, or in uniting the injured muscle and

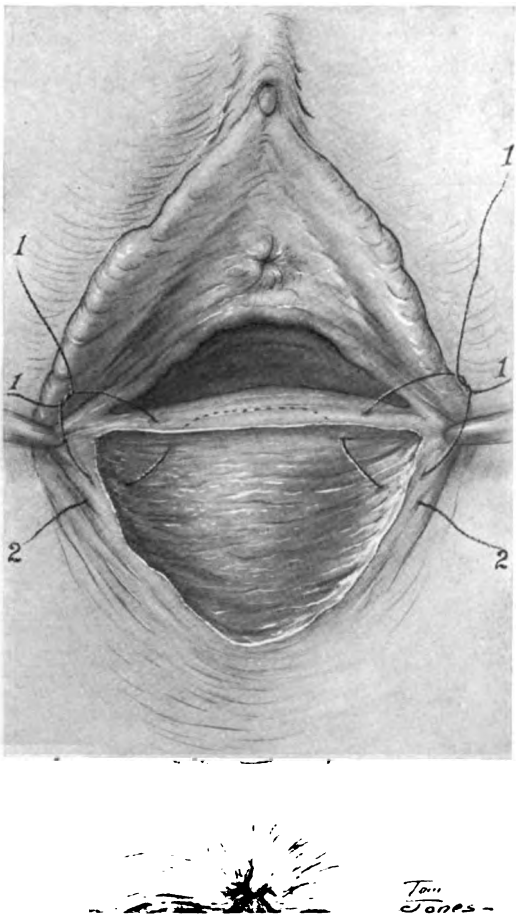

FIG. 133. PERINEORRHAPHY. Denudation of the mucosa to the border of the levator ani. (*The Surgical Clinics of Chicago.*)

fascia in the median line between the vagina and rectum, as advocated by Hegar. Some of the operations comprise both of these principles and are therefore to be preferred.

The denudation is made by removing the mucous membrane in strips with scissors or by blunt dissection with scissors. We prefer the former,

as we believe that there is less traumatism, that the bleeding is less, and that a better surface is left for suture. The denudation should extend as high as possible without danger of producing atresia of the vagina. It should always extend sufficiently high on either side to permit of easy

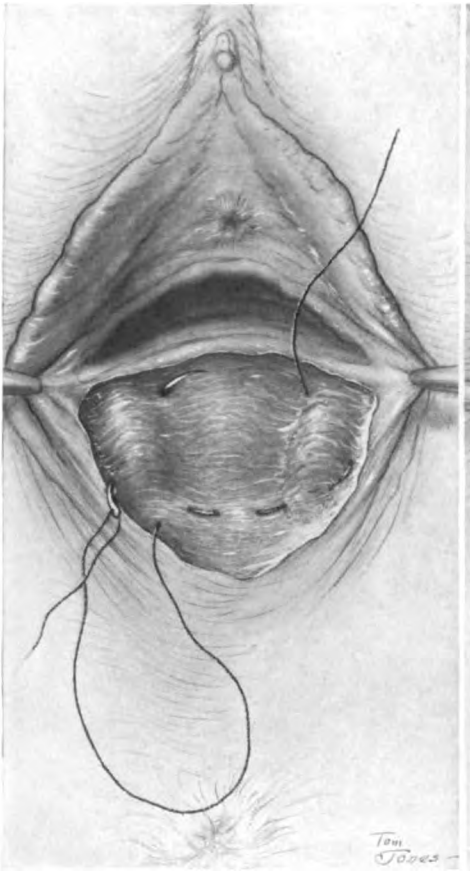

FIG. 134. PERINEORRHAPHY. The first purse-string suture in position. (*The Surgical Clinics of Chicago.*)

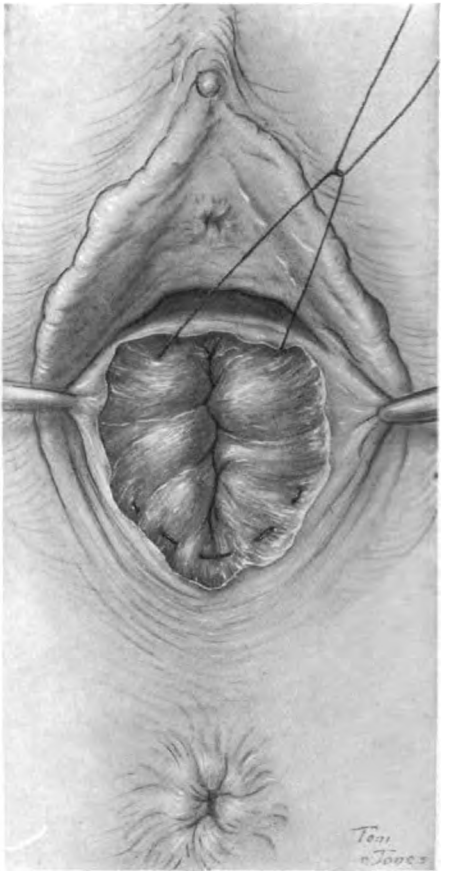

FIG. 135. PERINEORRHAPHY. The first purse-string suture tied and the second inserted. (*The Surgical Clinics of Chicago.*)

suture of the uppermost part of the levator ani muscle. The extent and appearance of the denudation is illustrated in Figure 133.

The first suture is passed through the upper part of the levator ani muscle on the left side, catches the base of the triangular ligament in

numerous places, and is passed out through the corresponding portion of the levator ani muscle and fascia on the opposite side. This is temporarily left untied until the upper part of the wound is sutured. Subcutaneous sutures are now passed along the upper edge of the denuded area (Fig. 133). These should ensure complete closure of that part of the wound. The first suture is then tied. The rectocele should be carefully inverted before the suture is tied to guard against its being included in the suture. This suture utilizes the triangular ligament for closure of

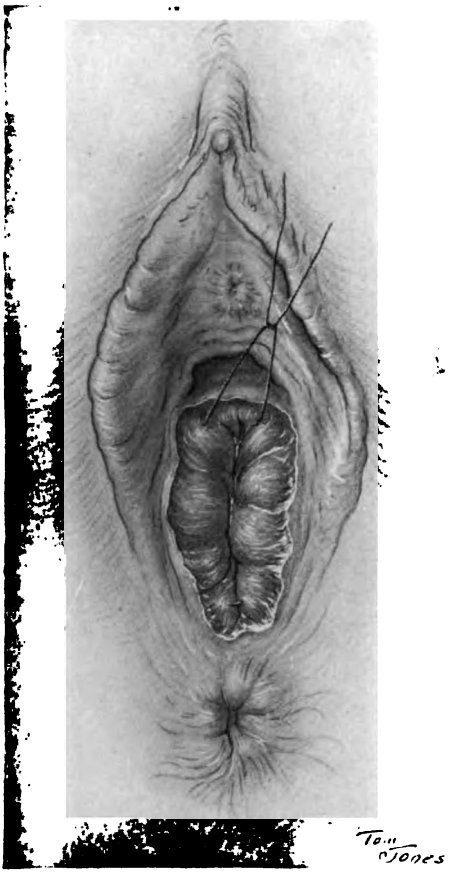

FIG. 136. PERINEORRHAPHY. The third purse string suture used in extensive tears. (*The Surgical Clinics of Chicago.*)

FIG. 137. PERINEORRHAPHY. Closure of the wound by a subcuticular suture. (*The Surgical Clinics of Chicago.*)

the hernial opening through which the rectum protrudes. It should be placed so that it makes accurate approximation with very slight tension on the ligament.

The second suture is inserted (Fig. 134) obliquely and rather deeply

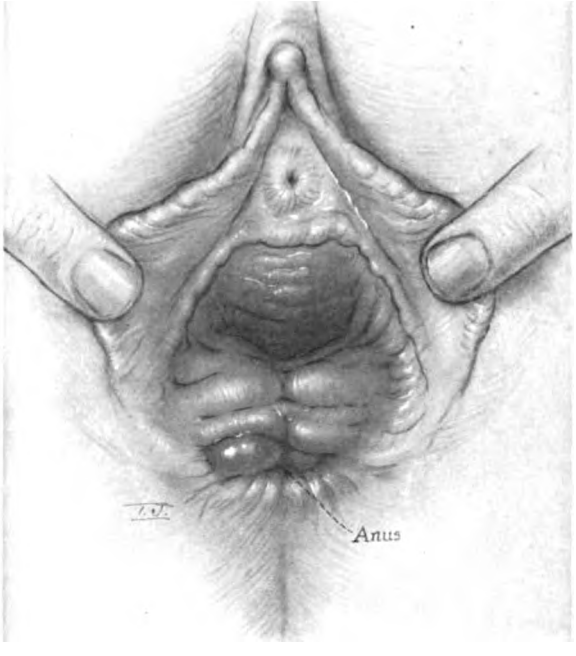

FIG. 138. COMPLETE LACERATION OF THE PERINEUM.

at the upper part, so that when tied it displaces the perineum in the direction of the pubes.

Additional circular sutures are employed in a like manner until the wound is completely closed. By making all the sutures submucous and subcutaneous there is less pain and less danger of infection than when the sutures pass through the mucous membrane and skin.

Criticism has been made that the method of closure of the hernial opening by means of the triangular ligament produces a rigid perineum,

but this has not been our experience in utilizing this procedure for some years. The operation is not well adapted to the treatment of a high rectocele which occurs between the levator ani muscle and the cervix. This type of case will be considered later.

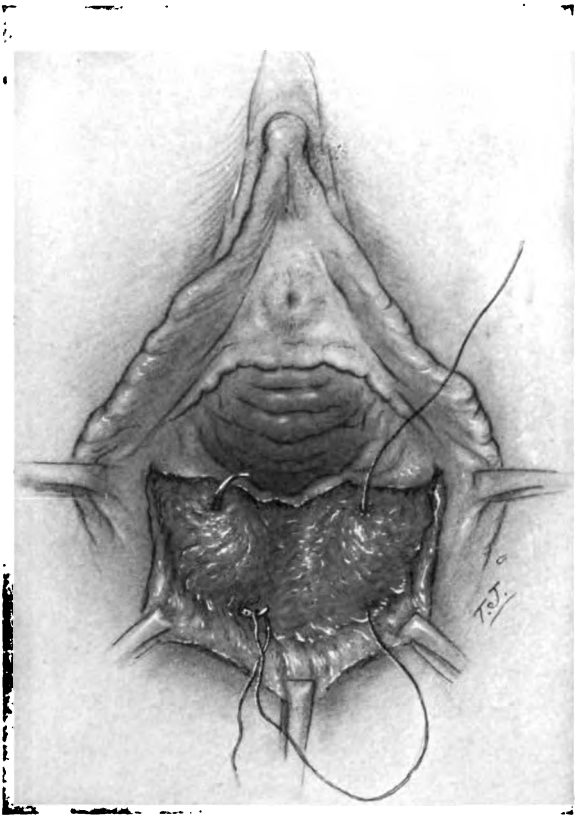

FIG. 139. PERINEORRHAPHY FOR COMPLETE LACERATION OF THE PERINEUM. Suture grasping the separated ends of the levator ani.

An occasional case will develop a slight infection with some separation of the wound, but this should not materially affect the therapeutic result.

These patients require very little after care. No internal douches are employed. Instillations of Dakin's solution are used if there is an odor that disturbs the patient. A very thin dressing is kept over the wound as thick dressings stimulate perspiration and keep the wound moist. The patient is allowed to sit up as soon as she desires to do so.

Perineorrhaphy for complete laceration of the perineum. Figure 138 illustrates a typical case drawn from life. The tear quite commonly extends even farther through the rectovaginal septum. The

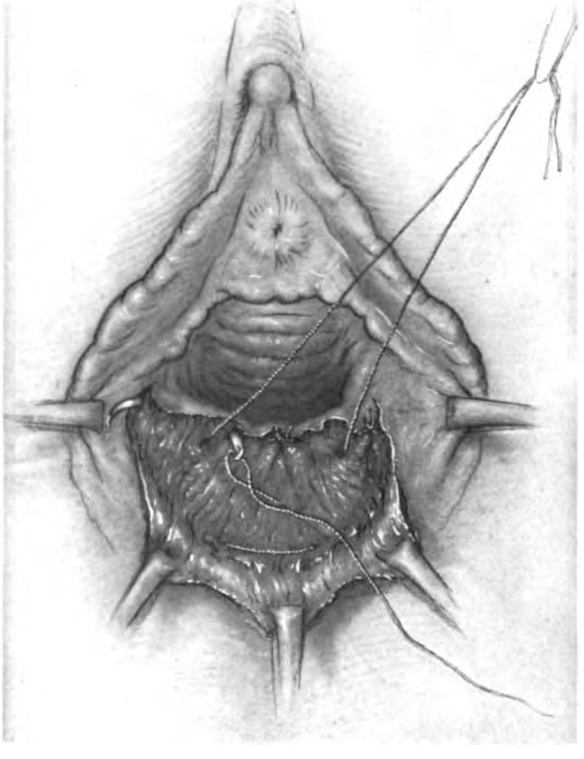

FIG. 140. PERINEORRHAPHY FOR COMPLETE LACERATION OF THE PERINEUM. A submucous suture being inserted to close the upper part of the wound.

retraction of the torn sphincter is often greater than is shown in the illustration. The extent of the retraction can be determined by the extent of the puckering of the skin about the anus, and by the depressions which occur at the site of the torn ends of the sphincter.

The lesion is repaired by the flap method which was described a long time ago by Collins Warren. Dr. Howard Kelly later independently devised the flap operation and made it generally known to the profession.

A transverse incision is made through the mucosa from one-half to one inch beyond the upper border of the tear. The mucosa is dissected away so that a flap is formed as appears in Figure 139. Care should be used to separate all the fixed tissue down to the rectum in the midline,

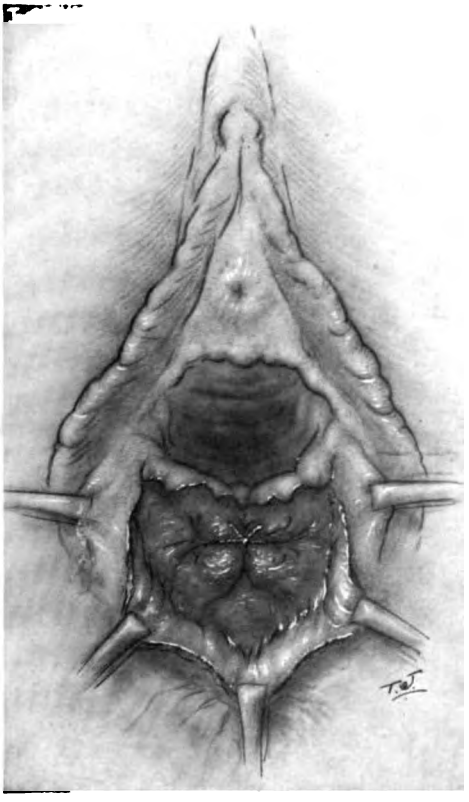

FIG. 141. PERINEORRHAPHY FOR COMPLETE LACERATION OF THE PERINEUM. Appearance of the wound after insertion of the deep sutures.

so that the upper part of the tear comes down to the skin surface without traction. This is easily accomplished irrespective of the extent of the tear. It is also essential to separate all the firm tissue down to the rectal mucosa so as to facilitate the approximation of the torn ends of the muscle. Care should be used to not make the flap too thin, as otherwise the blood supply may not be sufficient and sloughing may result. In Figure 140 the levator ani and the fascia are approximated in the midline. This suture is left untied temporarily. The upper part of the wound is

closed in a manner similar to that described in the perineorrhaphy operation.

Figure 141 shows the first suture cut and tied, and the upper part of the wound closed. It should be noted that the rectum is covered by

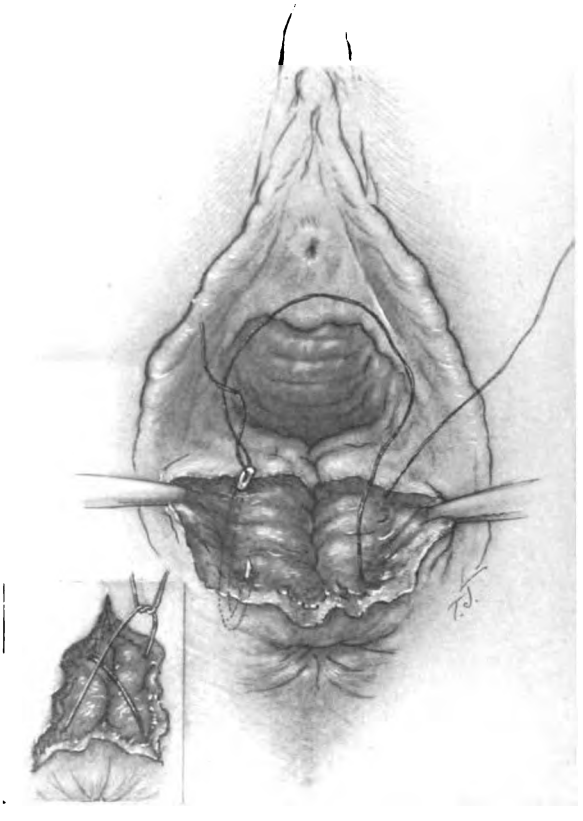

FIG. 142. PERINEORRHAPHY FOR COMPLETE LACERATION OF THE PERINEUM. Insertion of circular sutures which include the levator ani.

firmly approximated tissues and that the wound has become appreciably smaller. A second mattress or circular suture is now introduced (Fig. 142). This extends more deeply into the levator ani muscle and fascia and also dips down into the sphincter muscle. The insert (Fig. 142) shows the second suture being tied. (Note the change in size and shape of the

wound.) Figure 143 shows the submucous and subcutaneous suture which completes the operation. This may be placed as illustrated or may be a submucous and subcuticular suture. Figure 144 shows the

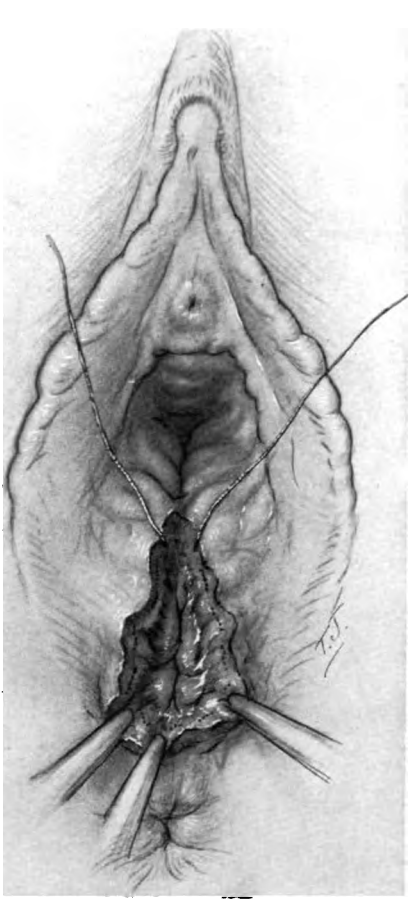

FIG. 143. PERINEORRHAPHY FOR COMPLETE LACERATION OF THE PERINEUM. Insertion of the subcutaneous suture for closure.

FIG. 144. PERINEORRHAPHY FOR COMPLETE LACERATION OF THE PERINEUM. Closure completed.

operation completed, the appearance of the vaginal outlet and of the restored pelvic floor. The distance of the wound from the anal aperture should be carefully noted.

After the first two sutures are inserted subsequent sutures should include some of the flap so that the latter becomes progressively smaller. It may be necessary to trim the flap slightly to obtain a smooth line of union.

The important advantage of the flap operation is that the danger of a

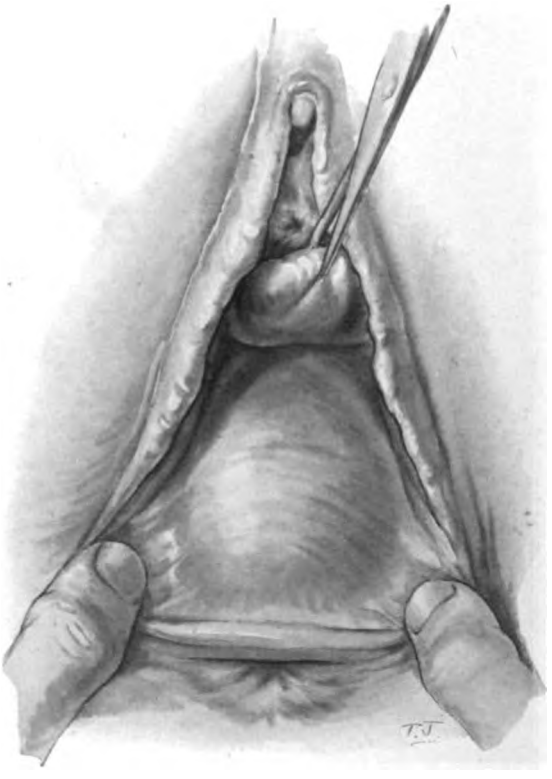

FIG. 145. HIGH RECTOCELE. The cervix is drawn downward with a tenaculum. (*The Surgical Clinics of Chicago.*)

resulting rectovaginal fistula is eliminated. The danger of infection of the wound is minimized as it is well removed from the anus. Enemas can be used without fear of injury of the wound. The amount of pain following the operation should be little or no greater than results from simple perineorrhaphy. There is no danger of a resultant stricture at the anus.

Separate exposure and suture of the muscle are not advocated, as we are convinced that better results are obtained if this feature is eliminated.

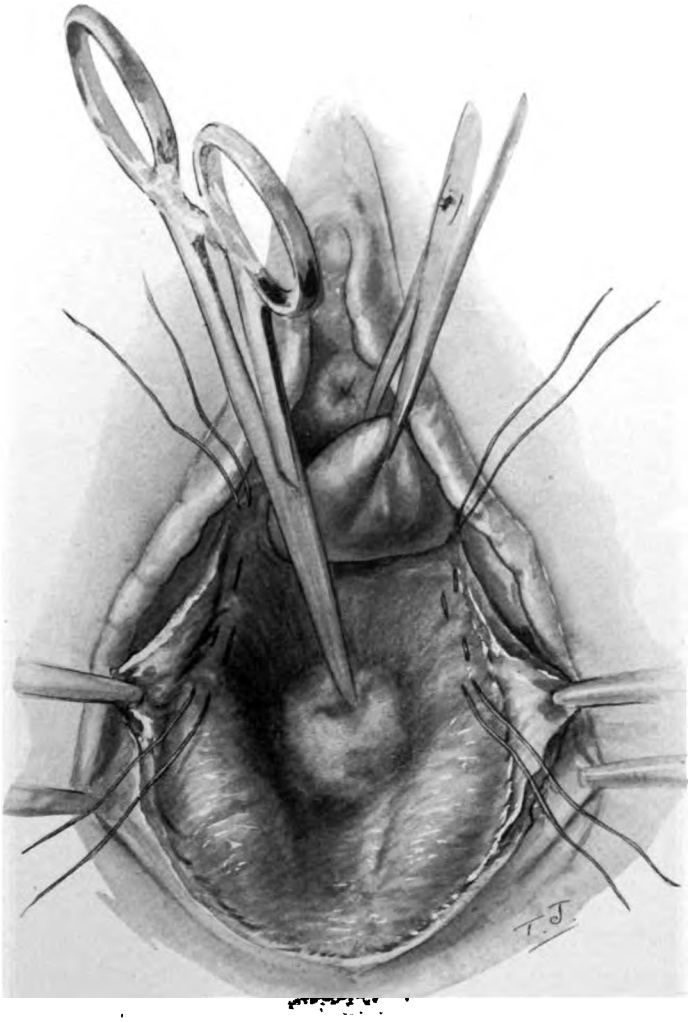

FIG. 146. OPERATION FOR HIGH RECTOCELE. Denudation completed; two sutures on either side unite the bases of the broad ligaments to the rectovaginal fascia. (*The Surgical Clinics of Chicago.*)

Dissection and suture of the muscle are apt to prove disappointing as the sutures frequently cut through with resulting retraction. As all union is connective tissue union there can be no special advantage in separate

suture of the muscle. The connective tissue over the retracted ends of the sphincter ani makes a strong surface for suture, and a little more or less connective tissue between the approximated muscle is of minor im-

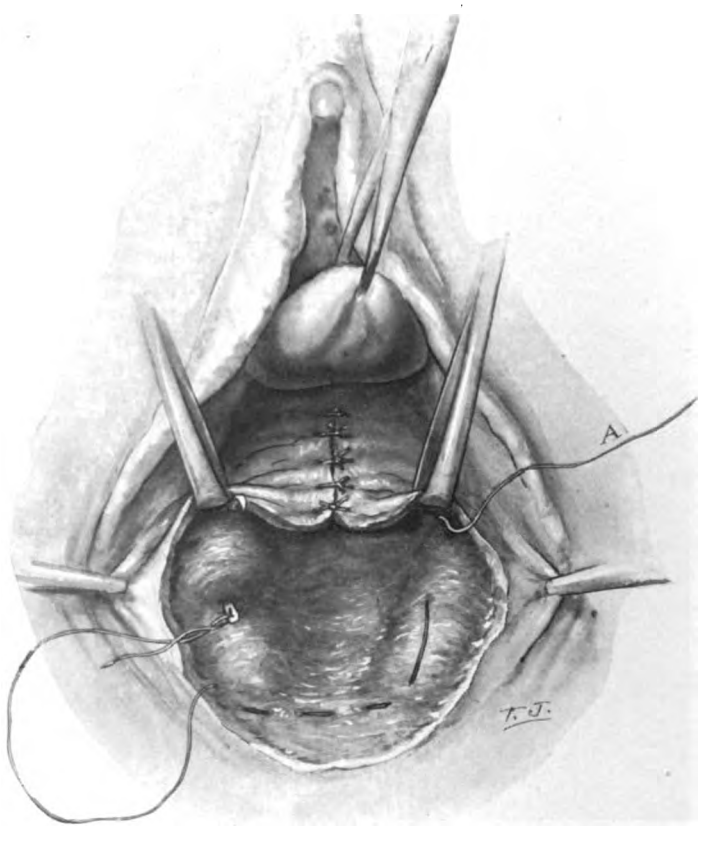

FIG. 147. OPERATION FOR HIGH RECTOCELE. Upper part of the vaginal canal united by suture; purse string suture for reducing the hernia of the rectum being inserted. (*The Surgical Clinics of Chicago.*)

portance as union at best is a fibrous tissue union. The sphincter muscle is a part of the levator ani muscle. As a consequence the first part of the suture that draws the levator ani muscle together higher up partially restores the sphincter muscle.

In extensive cases we believe it valuable to reinforce the suture that

involves the sphincter muscle by the insertion of one or two silkworm gut sutures. These can be inserted during the progress of the operation and tied after the operation is completed, or can be inserted after the catgut suture has been put in place.

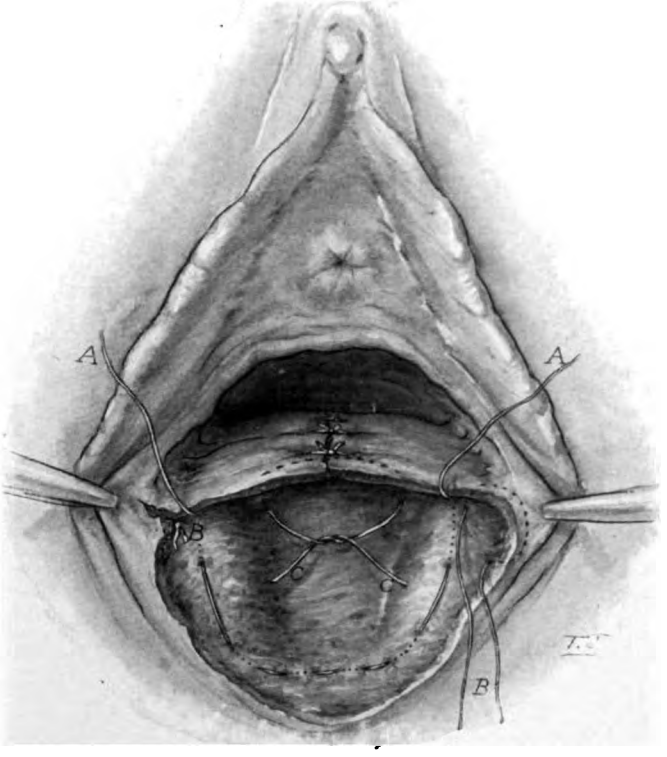

FIG. 148. OPERATION FOR HIGH RECTOCELE. Sutures for completing closure being inserted. (*The Surgical Clinics of Chicago.*)

In cases of extensive retraction of the sphincter muscle, suture of the muscle is facilitated by extending the incision of the skin downward in the direction of the muscle, as was advocated in the Tait flap-splitting operation.

The after-care of these patients is the same as in simple perineorrhaphy. If any silkworm gut sutures are used they should be left in place until they commence to cut the tissues.

The results of this operation are not quite as certain as in simple perineorrhaphy, as there is more traumatism and some danger of slough-

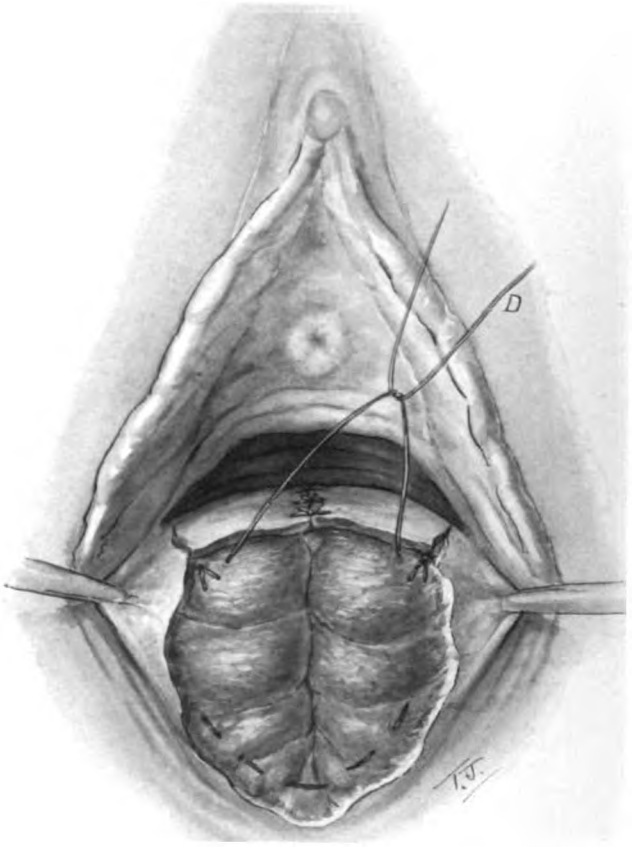

FIG. 149. OPERATION FOR HIGH RECTOCELE. Hernial ring completely closed; superficial purse string sutures being inserted. (*The Surgical Clinics of Chicago.*)

ing of the flap. This danger is lessened by making the blunt dissection wide enough to obtain an approximation without much tension, and by making a rather thick flap, especially at the sides in order to ensure an adequate blood supply.

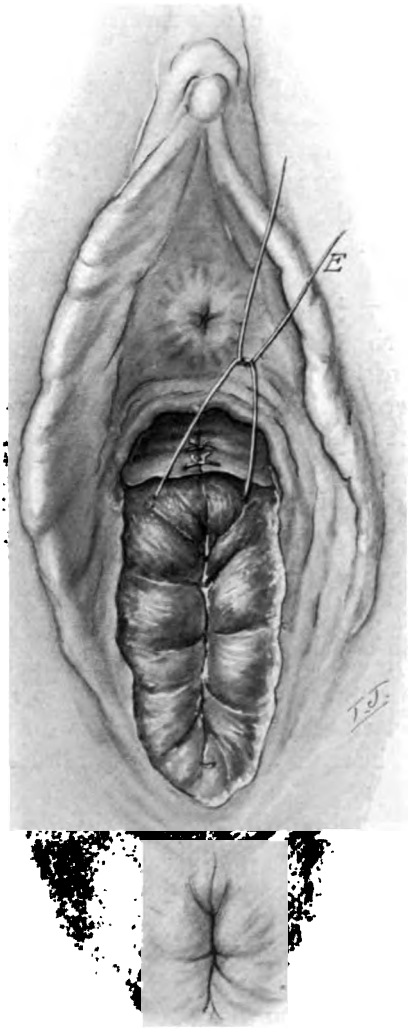

FIG. 150. OPERATION FOR HIGH RECTOCELE.' Insertion of final submucous suture. (*The Surgical Clinics of Chicago.*)

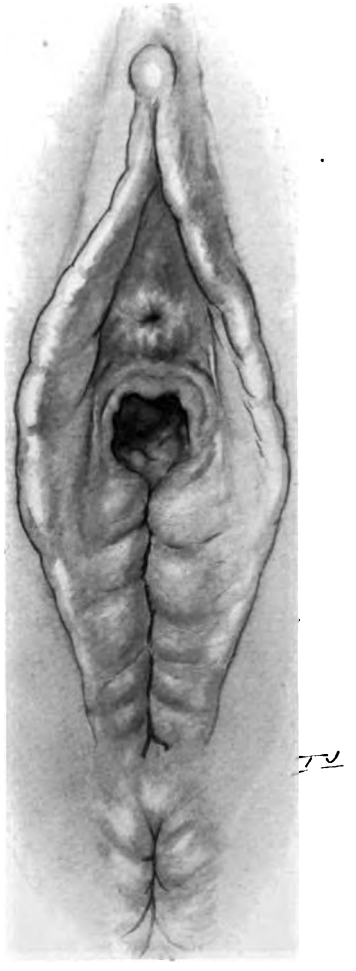

FIG. 151. OPERATION FOR HIGH RECTOCELE. Closure completed. (*The Surgical Clinics of Chicago.*)

Perineorrhaphy for high rectocele. By high rectocele is meant a pouching of the rectum into the vagina or between the cervix and the levator ani muscle (Fig. 145). It is evident that the ordinary perineorrhaphy, which involves only the levator ani and its fascia, cannot cure this condition.

The operation proposed consists in suture of the pubic portion of the levator ani to the broad ligament at either side of the cervix, and the approximation of such tissues as can be brought together in the median line. The success of the operation depends largely upon the length of the broad ligament; that is upon the possibility of apposing these two structures without unduly drawing down the cervix and shortening the vaginal canal.

The denudation is made as shown in Figure 146. Care should be used to free the rectum from the perirectal connective tissue, so that the rectal wall can be displaced backwards and the perirectal tissue used for support. Some separation of the broad ligaments from the cervix will facilitate the approximation of these ligaments to the levator ani muscle and the perirectal connective tissue.

The first sutures unite the bases of the broad ligaments with the rectovaginal fascia (Fig. 146). After these are tied the upper part of the vaginal canal is closed and a purse-string suture is inserted which enters at the upper border of the levator ani on the left side, approaches the bases of the triangular ligament, and makes its exit at a corresponding point on the right side (Fig. 147). When tied this suture closes the hernia of the rectum. Before this suture is tied, however, two subcutaneous sutures (Fig. 148,*b*) are inserted to close the sulcus on either side and a third submucous suture is inserted (Fig. 148,*c*) to render closure complete.

When these sutures are tied the rectal hernia is completely closed and the levator ani and fascia are brought prominently into view (Fig. 149). By introducing successive purse-string sutures parallel to the first (Fig. 149,*c*; Fig. 150,*e*) the perineal defect is repaired. The wound is closed with submucous and subcutaneous sutures (Fig. 151).

It is important to remember that the tissues should be well united back of the cervix so as to avoid the formation of a pouch into which the cervix may be displaced. It is also necessary to use care not to narrow the vaginal canal.

The author has utilized this procedure in only two cases. The result as regards the rectocele has been satisfactory, but the general results as regards the conformation of the vaginal canal have been somewhat disappointing.

The only other procedure which I know of for relief of this condi-

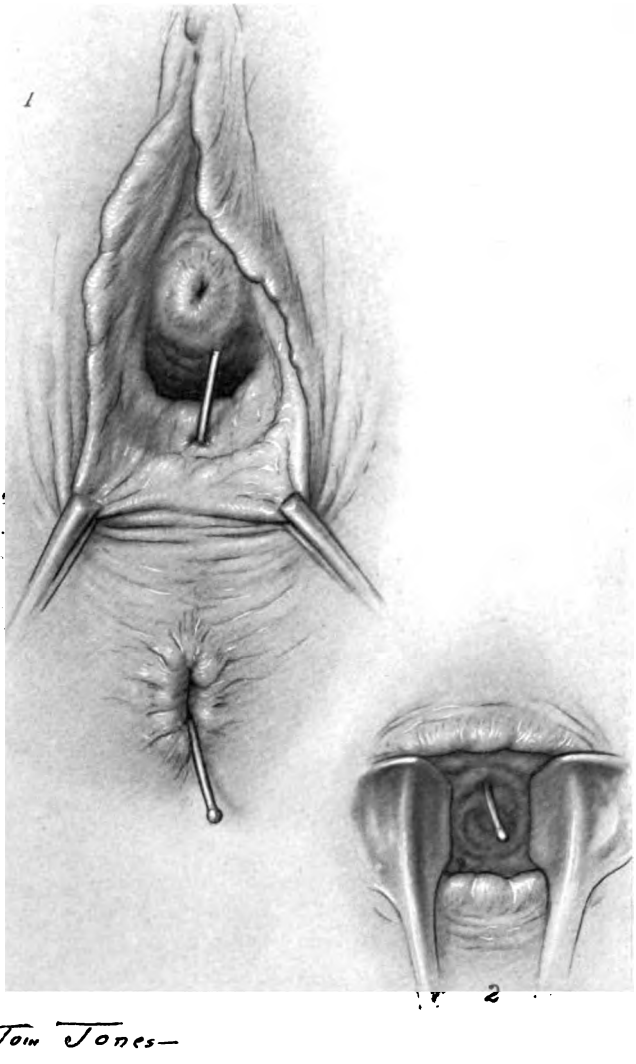

FIG. 152. RECTOVAGINAL FISTULA. (*Vernon David, The Surgical Clinics of Chicago.*)

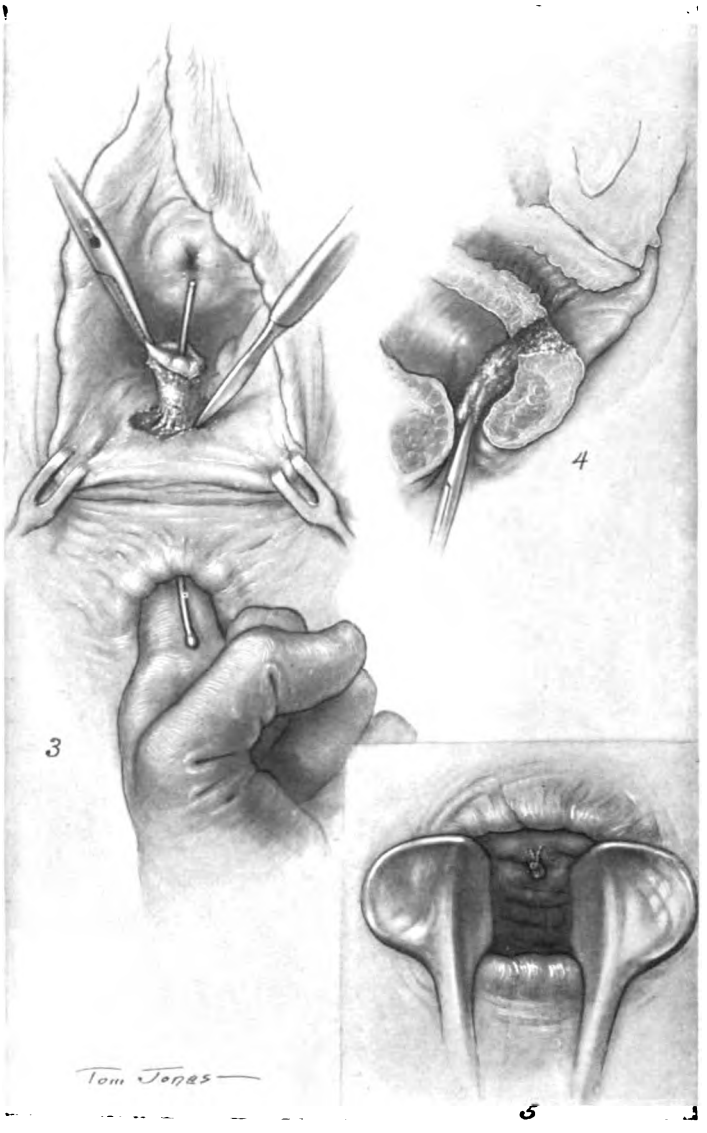

FIG. 153. RECTOVAGINAL FISTULA. Dissection and closure of the fistulous tract. (*Vernon David, The Surgical Clinics of Chicago.*)

tion without seriously affecting the vaginal canal is one described by Dr. George Noble, which consists in inverting the rectocele into the rectum, forcing it out through the anus, and amputating it.

Rectovaginal fistula. Extensive lacerations of the perineum are sometimes complicated by rectovaginal fistula. A very ingenious and satisfactory method of correcting this condition was described in the *Surgical Clinics of Chicago* by Dr. Vernon C. David. Figures 152 and 153 illustrate the steps in this operation.

The sphincter muscle and posterior vaginal wall are anæsthetized with 0.5 per cent novocaine solution and the fistulous tract dissected from the vaginal surface down to the submucosa of the rectum. The submucosa is mobilized for a distance of a half inch about the rectal opening of the fistula, and the fistulous tract inverted into the rectum. A linen ligature is tied about its base on the rectal side, and the redundant portion is excised. The vaginal defect is closed by two or three layers of interrupted catgut sutures.

CHAPTER II

OPERATIVE TREATMENT OF RETRODISPLACEMENTS

Indications for operation. Symptomless retrodisplacements of the uterus, irrespective of the degree of displacement, do not require operation. This fact is not sufficiently recognized. Furthermore, when there are symptoms, in the majority of cases they are due to pelvic infection or other pathology, rather than to the retrodisplacement itself.

In cases of replaceable uncomplicated retroversion with symptoms, the use of a pessary often demonstrates whether relief will be found in operation. Cessation of symptoms throughout several weeks, followed by their return on removal of the pessary, is evidence that a properly performed operation will effect a cure.

In other cases the pessary may not retain the uterus in position; if such patients experience relief while the uterus is held in position after manual replacement, the operative prognosis is favorable.

Added experience makes me less critical of the old school, who were ardent advocates of pelvic therapy for every case with backache. This symptom may result from constant dragging of the pelvic organs, due to relaxation of the uterine supports. It may also be due to direct pressure. Uterine pressure on the rectum, notably when the uterus is heavy or the retrodisplacement is complicated by adhesions, may indirectly cause toxic backache from absorption of intestinal contents.

Chronic pelvic infections which produce retrodisplacement often cause backache. Infectious organisms, notably streptococci, are prone to metastasize in the lumbar muscles, sacro-iliac joints, and vertebral articulations. Operation upon these cases often yields wonderfully gratifying results through removal of the focus of infection, but such patients must be studied with extreme care before operation is decided upon.

Finally, it is well not to be too sanguine over operative relief from backache, even where painstaking investigation strongly indicates that the cause is a pelvic one. Of two cases apparently analogous in all respects, one may be entirely relieved by operation, the other not at all improved.

Pressure symptoms are commonly associated with partial prolapse of the uterus. Experimental replacement of the uterus, with observation of the amount of relief afforded by holding it in place both when the patient

is recumbent and when standing, usually demonstrates how much benefit may be expected from operation.

Permanent sterility rarely if ever results from uncomplicated retrodisplacement. Operation for this cause is rarely advisable even when adhesions are present, in which cases the sterility is not overcome in more than 15 per cent of cases.

Abortion is a more common result of retrodisplacement. For the prevention of anticipated abortion, trial with a pessary should be given preference over operation. In case of subsequent abortion despite the pessary, operation may be resorted to and is usually successful.

Abnormal menstrual flow may be indirectly due to the displaced uterus; the ovaries become displaced with the uterus and tend to become congested and hyperactive. Such ovaries cause prolonged menstruation or may be otherwise harmful through elaboration of excessive internal secretion. Replacement of the uterus raises the ovaries to their normal location and relieves these symptoms.

EXTRAPERITONEAL OPERATIONS

The Alexander-Adams operation. Extraperitoneal operation offered decided advantages in the days when abdominal section was frequently complicated by peritonitis. Even now it is a procedure of lesser magnitude, with minimum postoperative pain. In recent years, however, the desire to observe the pathological condition and to make certain that all lesions are corrected, has lessened the popularity of extraperitoneal operations, of which the Alexander-Adams is the best known example. This operation should be performed only when the uterus is freely movable and other pelvic pathology can be excluded.

A three-inch incision is made parallel with Poupart's ligament, over the inguinal canal, down to the external ring. If the round ligament is not found with ease it may be located by opening the peritoneum at the internal ring. Traction is made upon the ligament, the peritoneal process is separated from it, and traction is continued until the ligament has been sufficiently delivered. A similar procedure is followed upon the opposite side. With the uterus well anterior, the ligaments are now firmly sutured to the fascia. The danger of potential hernia is avoided by careful closure of the weakened canal.

Vaginal suspension by the round ligaments. If the patient greatly objects to abdominal section, the vaginal route may be selected. It may also be preferable in the presence of a cystocele, which may be repaired at the same time. Postoperative distress is essentially less than after abdominal section.

Anterior vaginal flaps are made as in vaginal hysterectomy. The bladder is displaced upward, the peritoneal fold between the uterus and bladder is opened, and the fundus uteri caught with a volsellum. Each

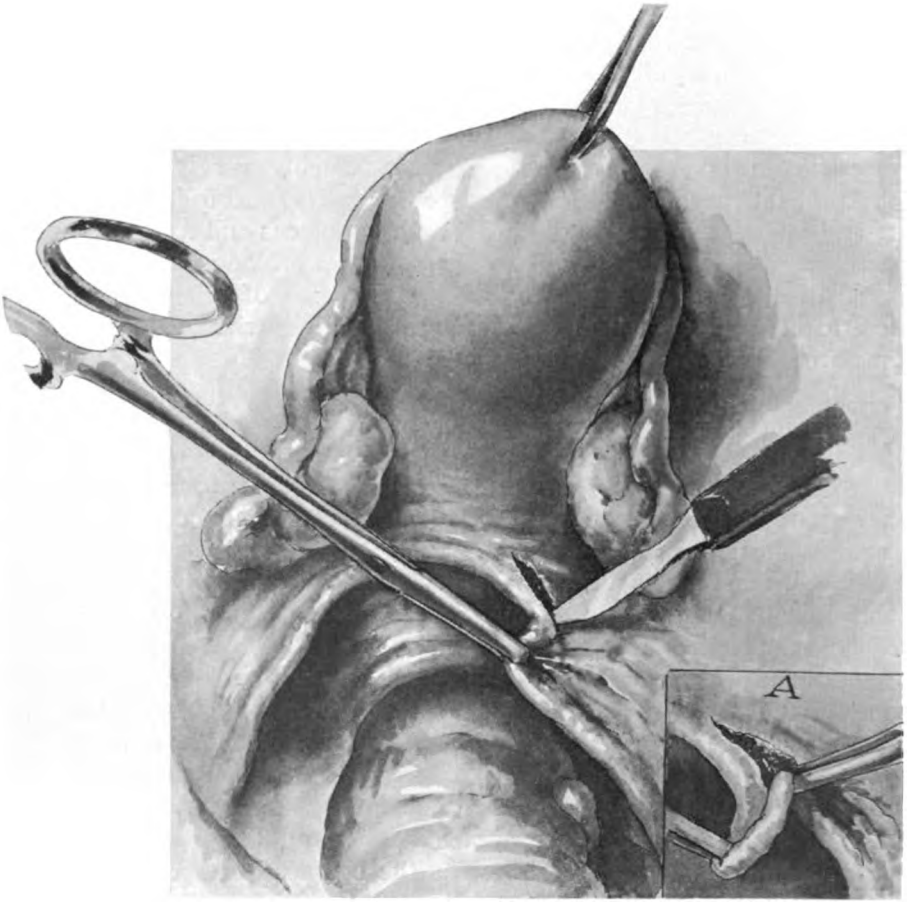

FIG. 154. SHORTENING OF THE UTEROSACRAL LIGAMENTS. Incision parallel with the ligament at its uterine end. (*After John V. Young.*)

round ligament is then grasped, held moderately taut, and sutured to the anterior vaginal wall near the upper angle of the wound. The vaginal flaps are then sutured. With the bladder maintained in an elevated position the sutures of the vaginal closure below the level of the internal os are made to include the cervix, thus eliminating the danger of cystocele.

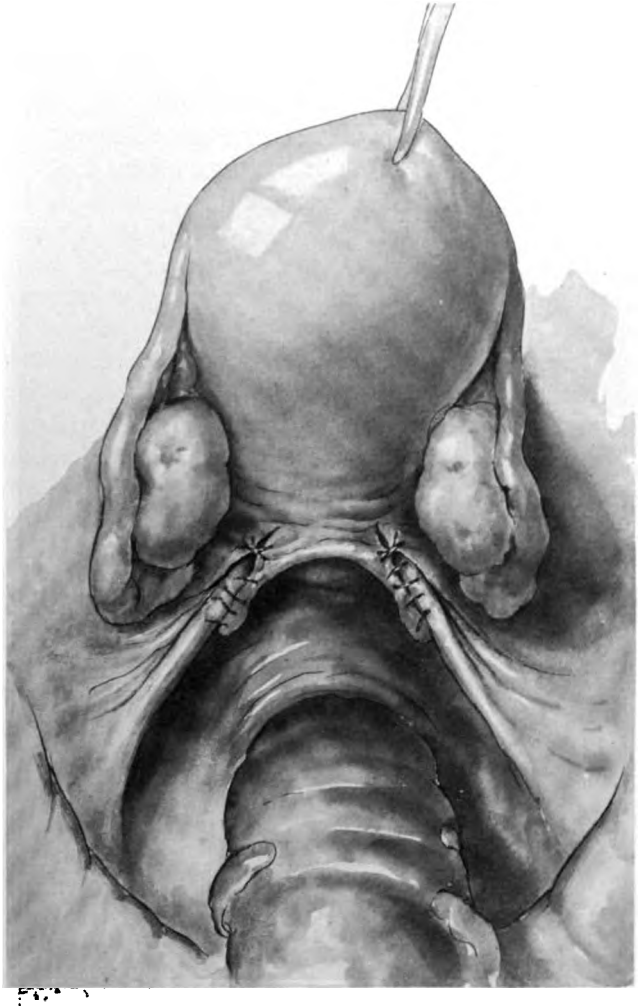

FIG. 155. SHORTENING OF THE UTEROSACRAL LIGAMENTS. The shortened ligament sutured in place. (*After John V. Young.*)

INTRA-ABDOMINAL OPERATIONS

Various types of intra-abdominal operations have many adherents, yet none has been universally adopted, an evidence that none of those yet devised is eminently satisfactory. Most popular of all are perhaps the Webster-Baldy and the Gilliam operations. Within the last few years shortening of the uterosacral ligaments has become very popular; a great

point in its favor is that this operation replaces and supports the cervix in its normal position.

In carrying out this procedure the abdomen is opened in the midline, and the fundus drawn upward and forward with a volsellum so as to render the uterosacral ligaments tense. An incision about 1½ inches in length is made on either side through the peritoneum covering the ligament (Fig. 154), and by blunt dissection the ligament is freed for an equal distance. The freed ligament is grasped with forceps and folded on itself in such a way as to cover as completely as possible the raw surface formed in the dissection. It is held in position by interrupted catgut sutures.

The present status of the entire situation may be summarized as follows: No accepted procedure gives eminently satisfactory results. It would appear best for every man to adopt one type of operation for routine use, modifying it to suit his preference and the individual requirements of the case in question. There is increasing evidence that shortening of the uterosacral ligaments is a decidedly beneficial adjunct to any one of these operations.

Amputation of the fundus. This operation, a guarantee against recurrence of retrodisplacement, is not performed frequently enough. It should always be considered in cases of retrodisplacement when the uterus can no longer serve the function of childbearing. Amputation of more than the fundus is to be avoided, for it is not unlikely that the uterus has also another function correlated with that of the ovaries. For preservation of this function, a considerable portion of the endometrium should be left.

Webster-Baldy operation. The abdomen is opened by the usual midline suprapubic incision. With the uterus held upward to assure good exposure, the broad ligament, at a point near the uterus, is punctured beneath the ovarian ligament. It is essential to select the thin place in the ligament; otherwise serious hæmorrhage may ensue. The round ligament is grasped and pulled through the opening. It is next sutured to its fellow, which has been similarly secured on the opposite side. The round ligaments are sutured to the posterior wall of the uterus, enough of the slack ligaments being brought through the broad ligament opening to assure satisfactory support of the uterus. The place of attachment to the uterus varies in individual cases from a point ¾ inch to 1½ inches from the top of the fundus. Webster uses silk suture material and spreads out the ligament in fan-shape at the point of attachment to the uterus. He advocates shortening of the uterosacral ligaments in every case.

Advancement of the bladder peritoneum upon the fundus. The Webster-Baldy operation places the body of the uterus in a position

which conforms with that of the healthy normal individual. It does not return the cervix to its normal position as is evidenced by the fact that

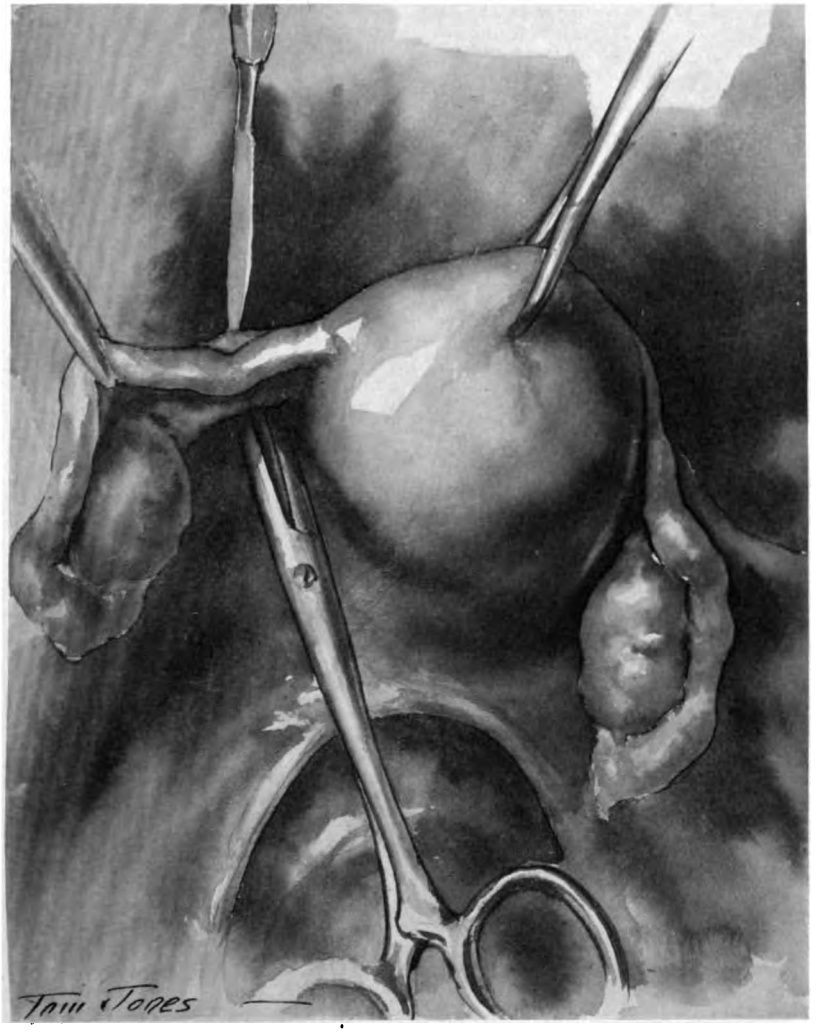

FIG. 156. WEBSTER-BALDY OPERATION. The broad ligament punctured beneath the mesovarium.

Webster himself secures additional support by shortening the uterosacral ligaments. Unfortunately, also, the majority of operators find that in

spite of careful technique a considerable proportion of cases suffer from a recurrent displacement of the fundus. The operation is therefore often

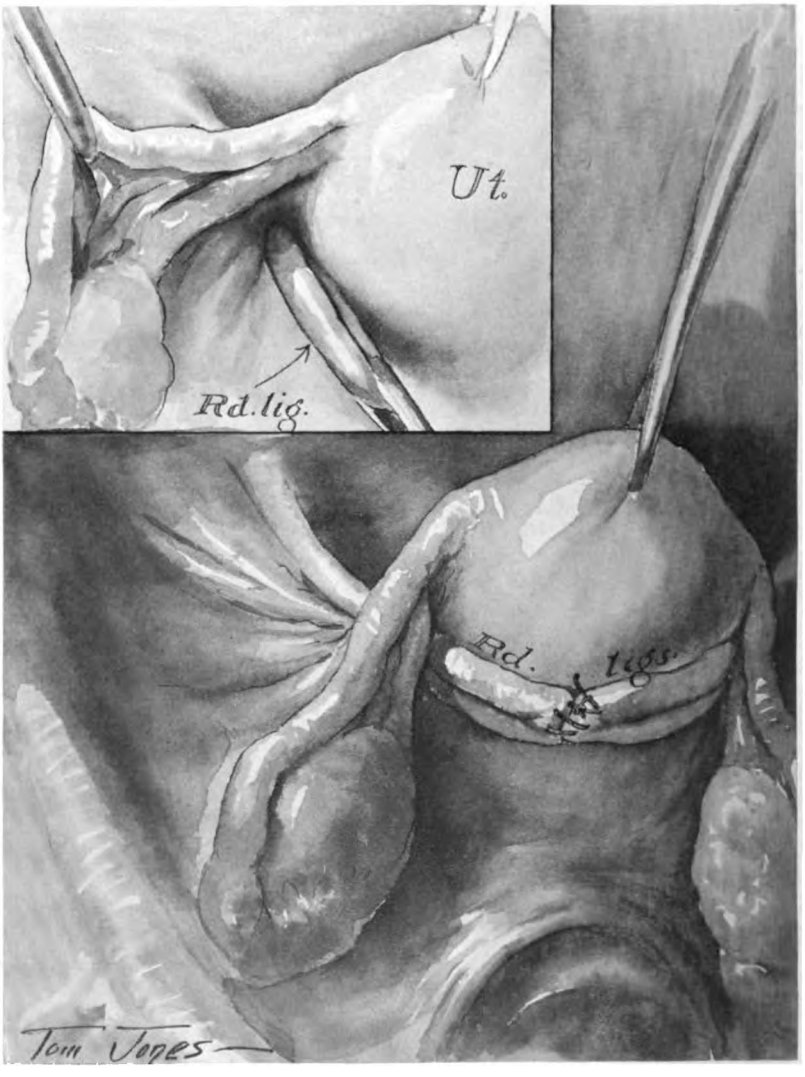

FIG. 157. WEBSTER-BALDY OPERATION. The round ligaments sutured together and anchored to the posterior surface of the uterus.

undertaken with an explanation to the patient that the trouble may recur.

For four years I have added another step to the round ligament opera-

tion, and thus far have encountered no unsatisfactory results. The vesical fold of peritoneum is well exposed to view by traction upon the fundus.

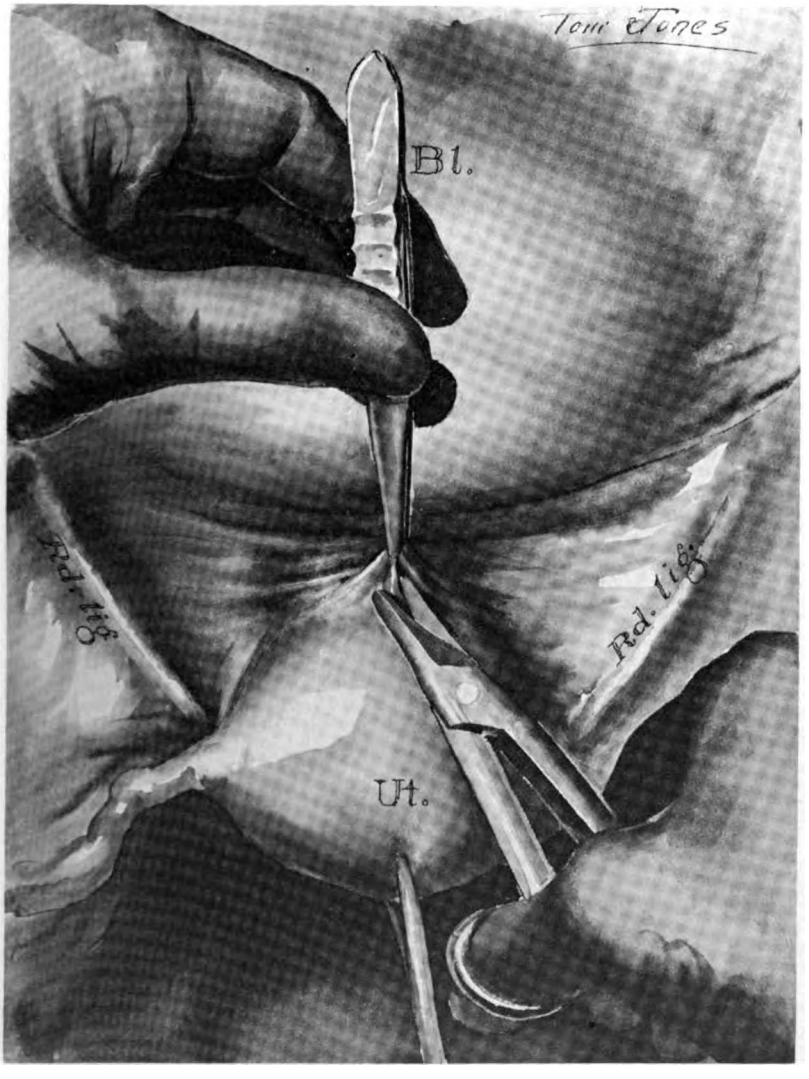

FIG. 158. ADVANCEMENT OF THE BLADDER. Incision of the anterior peritoneal covering of uterus.

This fold, seen on the anterior surface of the uterus, rises an inch or more above the top of the bladder and is very readily differentiated

from it. By blunt dissection with the scissors the fold is separated from the uterus for a width of 1½ inches, just as is done in performing

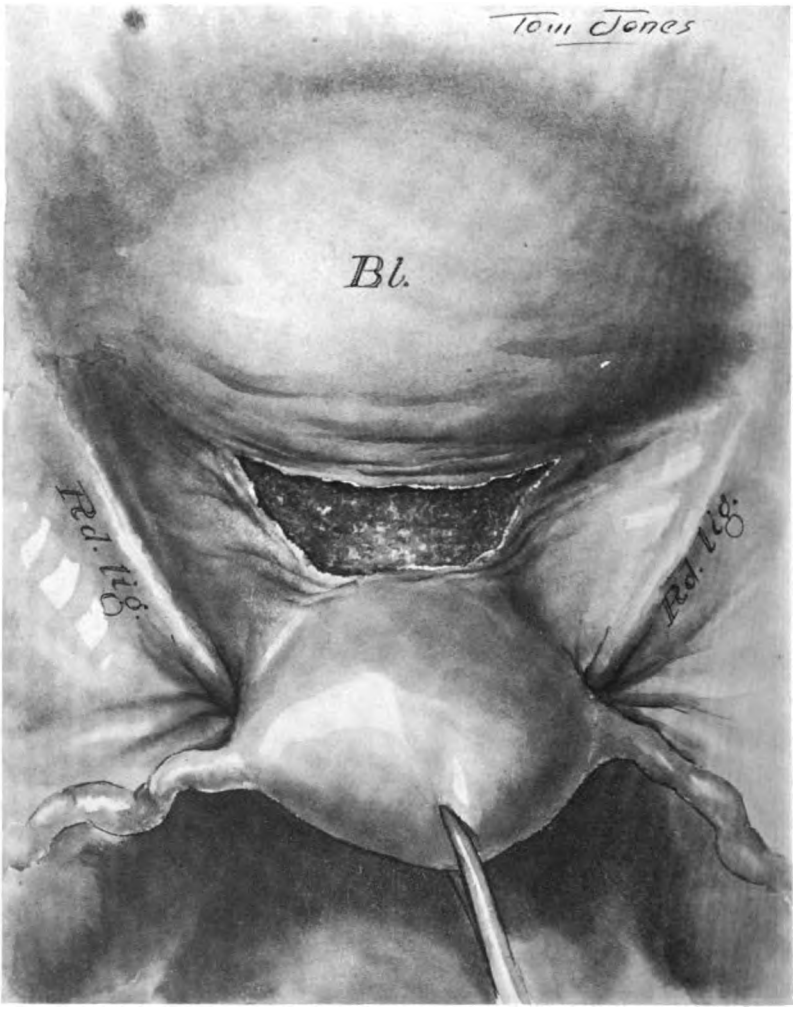

FIG. 159. ADVANCEMENT OF THE BLADDER. Separation of the peritoneum completed.

complete hysterectomy. It is then displaced upward on the anterior uterine wall to a point from 1¼ to 1¾ inches from the top of the fundus. Here it is sutured with catgut.

This procedure affords a much needed anterior support and is accomplished with very little effort. The function of the bladder is not

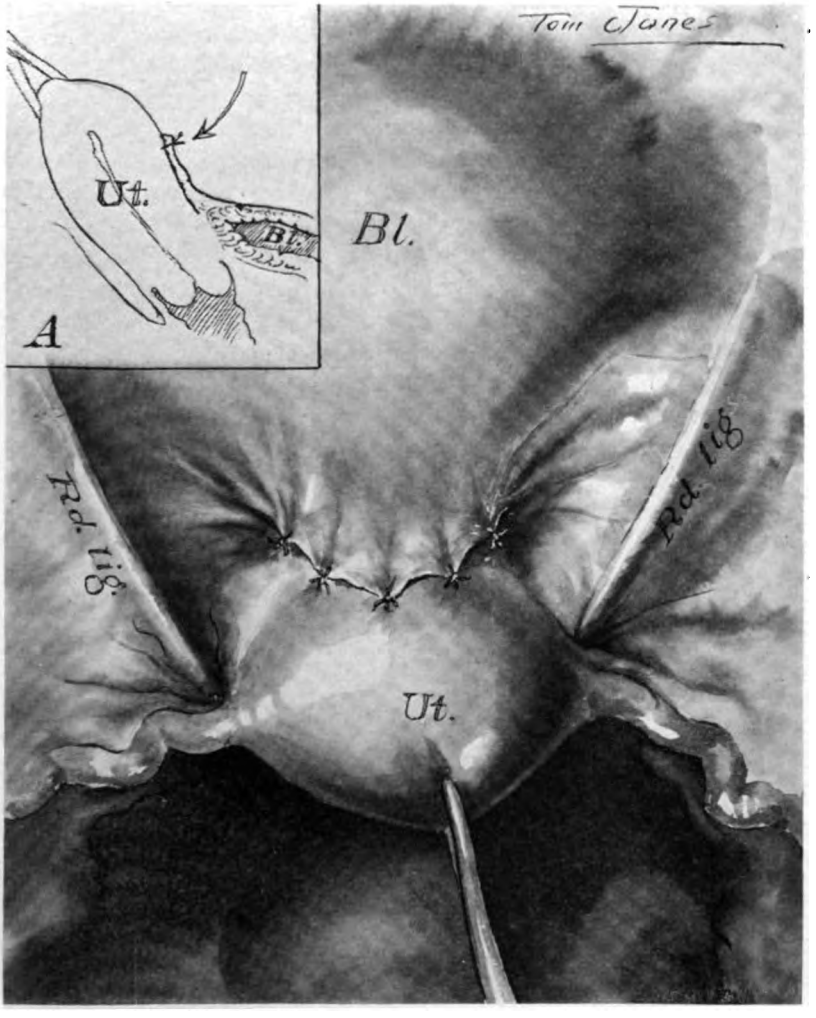

FIG. 160. ADVANCEMENT OF THE BLADDER. Suture of the advanced peritoneal fold upon the fundus.

at all interfered with, and in the event of pregnancy the enlarging uterus will develop without hindrance if the operation has been correctly performed.

Gilliam operation. This operation supports the uterus in excellent manner, but, like the Webster-Baldy operation, does not retain the cervix in normal position. It is open to the further objection that there is danger of strangulation of the intestine in the pockets formed between the round ligaments and the anterior abdominal wall.

With exposure through a 4-inch median incision, a suture is passed under the round ligaments 1½ inches from the uterus. Peritoneum, muscles, and fascia are now caught on one side near the pubis by means of a volsellum and are pulled toward the midline, while the skin and fat are stripped laterally. A stab wound is made through the deep tissues, including the fascia, 1½ inches above the pubis and 1 inch from the edge of the incision. The suture is caught, pulled through the stab wound, and fastened, when taut, with the loop just above the fascial surface.

Postoperative care. After operation the patient should lie as much as possible upon the abdomen or side. Continued dorsal posture exerts unwholesome backward tension on the freshly sutured surfaces. As soon as tenderness subsides and thorough healing is assured, the knee-breast posture should be used for a few minutes once or twice daily. Setting-up exercises are distinctly beneficial. The possibility of pregnancy should be avoided for several months. When pregnancy occurs, the support of a pessary, until the uterus rises out of the pelvis, lends an added element of safety.

CHAPTER III

OPERATIONS FOR INVERSION OF THE UTERUS

An inverted uterus, whether the condition be acute or chronic, could always be returned to its normal position were it not for the tendency of the cervix to contract and form the so-called contraction ring. This ring, being smaller than the inverted fundus, offers an obstacle to the replacement through it of the much larger body of the uterus.

No matter what may be the cause of acute inversion of the uterus, in the large majority of cases it is possible by properly applied taxis from below, with the aid of counterpressure from above, to reinvert the recently emptied puerperal uterus. This may be accompanied by profuse hæmorrhage and shock, and result in death; but mechanically the problem of restoring the uterus to its normal position is not difficult because the puerperal cervix yields readily to pressure exerted in the proper manner, and allows the fundus to be pushed upward and through it.

When for any reason the cervix does not readily yield, the acute case may be classed from a mechanical standpoint with the chronic form of inversion, where the contraction ring is always hard and unyielding and where taxis accomplishes very little—in fact almost always fails.

Taxis, therefore, as a means of reinverting the uterus, should be employed only in acute cases when other accompanying conditions warrant its trial. Attempts at restoration by taxis in the chronic form of uterine inversion have proved so ineffectual and have been so disastrous that they should be given up, and resort should be made at once to methods more in accord with modern surgery. No one today thinks of attempting to restore a retrodisplaced adherent uterus by prolonged vaginal packing and manipulation. In its place has been substituted abdominal or vaginal incision, whereby such adhesions can be released and the causative pathological conditions cared for in one operation. Manipulations to reinvert the uterus except under the conditions stated above are equally crude and unscientific and should also be relegated to the past.

TYPES OF OPERATION

The constricting inversion ring in cases of chronic inversion of the uterus may be incised through a vaginal or abdominal incision in accordance with the preference of the operator. Undoubtedly, however, the

vaginal incision is safer and therefore to be preferred for reasons to be stated below.

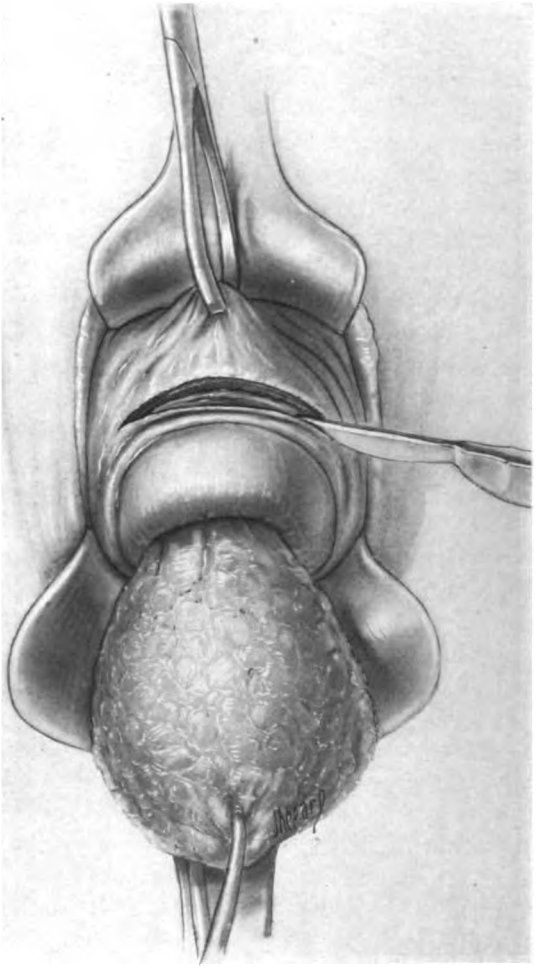

FIG. 161. ANTERIOR COLPOHYSTEROTOMY. Incision of the vaginal wall.

Anterior colpohysterotomy (Spinelli's operation). This operation consists of a transverse incision in the anterior vaginal wall, the opening of the vesico-uterine peritoneal pouch, and complete incision of the cervical and uterine walls upward. The incision must be long enough to permit reinversion of the uterus without tearing the uterine wall.

A two per cent solution of tincture of iodine should be used for disinfecting the vagina and inverted uterus in preference to soap and water, in order to avoid bleeding from the exposed uterine mucosa. This is an important step in the technique of the operation, since the

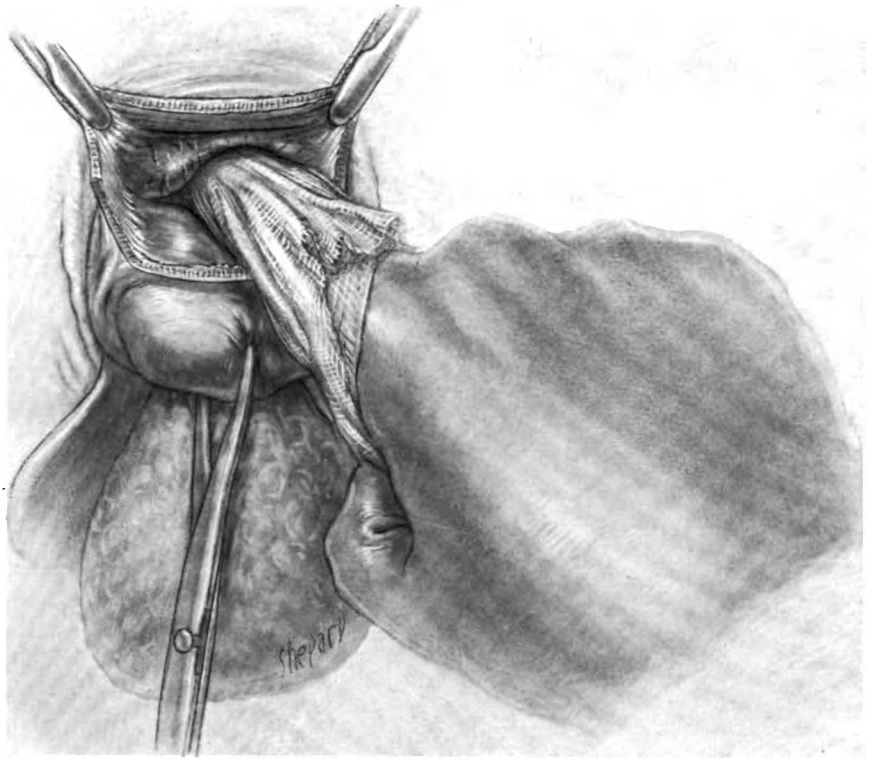

FIG. 162. ANTERIOR COLPOHYSTEROTOMY. Separation of the bladder from the cervix. (*After Crossen.*)

patient with an inverted uterus is not uncommonly anæmic from excessive flowing and in poor condition, and should be spared unnecessary loss of blood at the time of the operation. The importance of disinfecting thoroughly the entire mucous membrane, particularly the recesses of the fornices, is obvious.

The inverted uterus should be drawn downward by tenaculum forceps and the anterior vaginal wall rendered tense by upward traction (Fig. 161). The vaginal wall should now be incised transversely just above the

cervix, the bladder separated from the cervix, and the vesico-uterine peritoneal pouch opened (Fig. 162). The constriction ring with the tubes running into the inversion funnel are now plainly in view. The bladder should be held out of the way by a retractor and the cervix, steadied by a

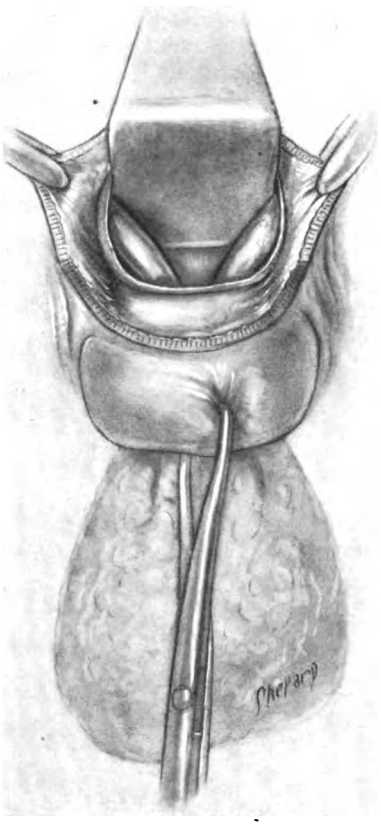

FIG. 163. ANTERIOR COLPOHYSTEROTOMY. Exposure of the constriction ring and uterine tubes. (*After Crossen.*)

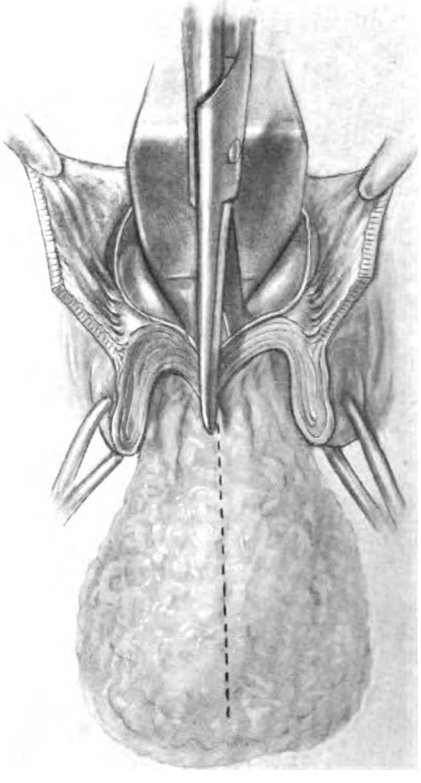

FIG. 164. ANTERIOR COLPOHYSTEROTOMY. Incision of the anterior uterine wall. (*After Crossen.*)

tenaculum on either side, divided in the median line, the finger in the inversion funnel being used as a guide (Fig. 164). The incision in the anterior uterine wall is carried upwards toward the fundus far enough to allow of reinversion without tearing the thickened uterine wall (Fig. 165). To accomplish the reinversion, whereby the peritoneal surface once

more becomes external and the mucous surface internal, pressure must be made upwards by the thumbs while the uterine walls are pulled outwards by the forefingers. Extension of the incision upwards is preferable to too forcible reposition.

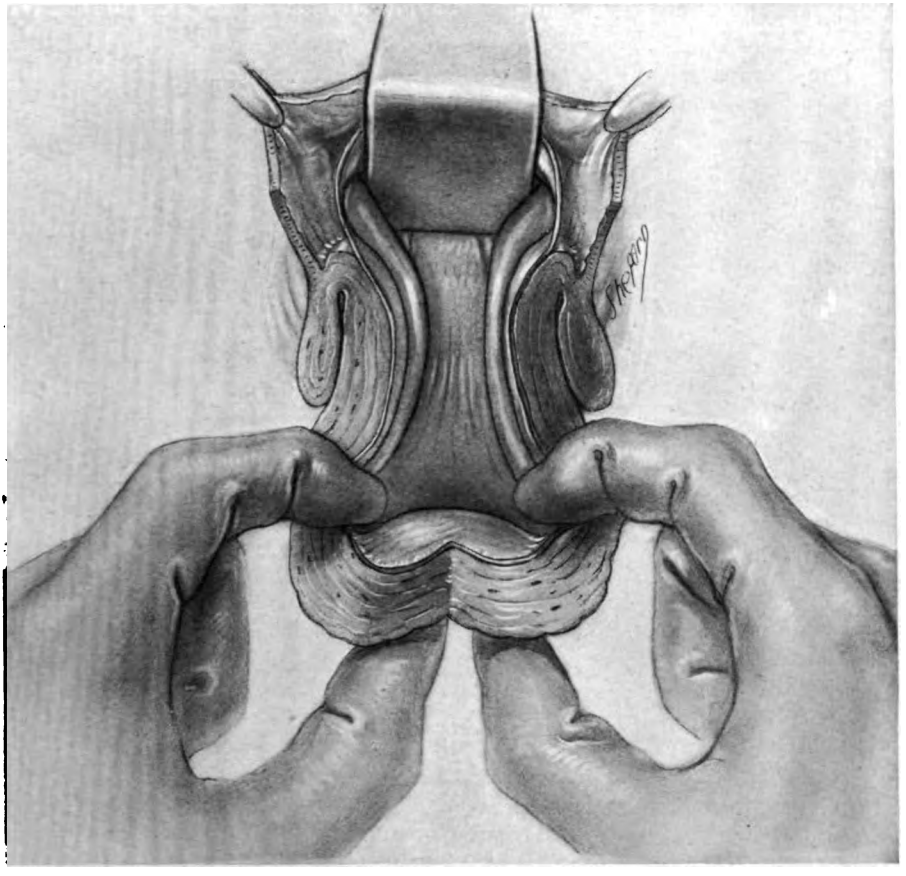

FIG. 165. ANTERIOR COLPOHYSTEROTOMY. Position of the fingers for reinversion of the uterus.

The thickened, everted uterine walls must be trimmed so that the peritoneal edges can be approximated. This can be accomplished by the removal of wedge-shaped pieces from the uterine wall, the amount of tissue to be removed depending upon the chronicity of the inversion and the resulting thickening of the uterine walls (Fig. 166).

The uterine and cervical incisions should be closed with two layers of interrupted or continuous chromic catgut sutures. The first layer should approximate the muscular uterine layers and go down to but not through the mucosa. A second row may be inserted in the muscle layers in case of hypertrophy or venous oozing. The third row should carefully approximate the edges of the incised peritoneum and the outer surface of the cervix (Fig. 167).

The fundus should be replaced within the pelvic cavity through the

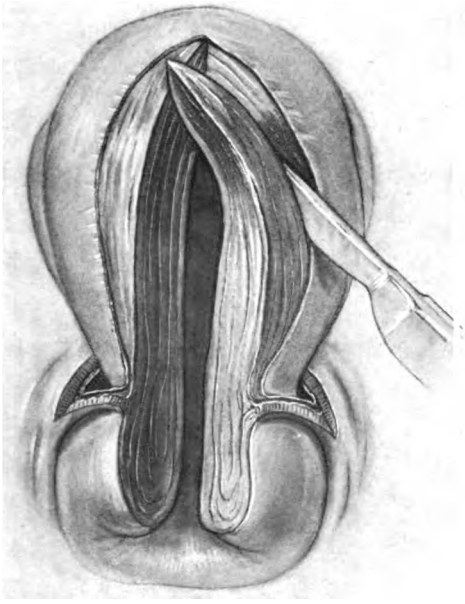

FIG. 166. ANTERIOR COLPOHYSTEROTOMY. Excision of the thickened edges of the uterine wall.

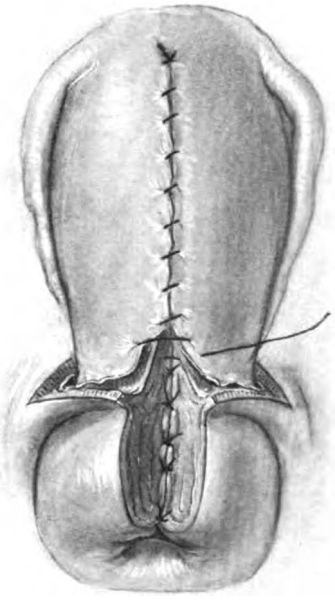

FIG. 167. ANTERIOR COLPOHYSTEROTOMY. Closure of the anterior uterine wall. (*After Crossen.*)

transverse vaginal incision. In case there be a tendency to retrodisplacement the fundus should be held forward by a shortening of the round ligaments.

The transverse vaginal incision should be closed, with the exception of a small opening for rubber glove drainage (Fig. 168).

Haultain, from his experience with these cases, prefers abdominal hysterotomy to vaginal anterior colpohysterotomy as just described. The technique of his operation is as follows: "After the usual thorough

disinfection of the skin of the abdomen and vagina, the peritoneal aspect of the pelvis is exposed by the usual median abdominal incision; the site of the inverted fundus is seen represented by a narrow transverse slit; into this a pair of ordinary dressing forceps is passed and opened as

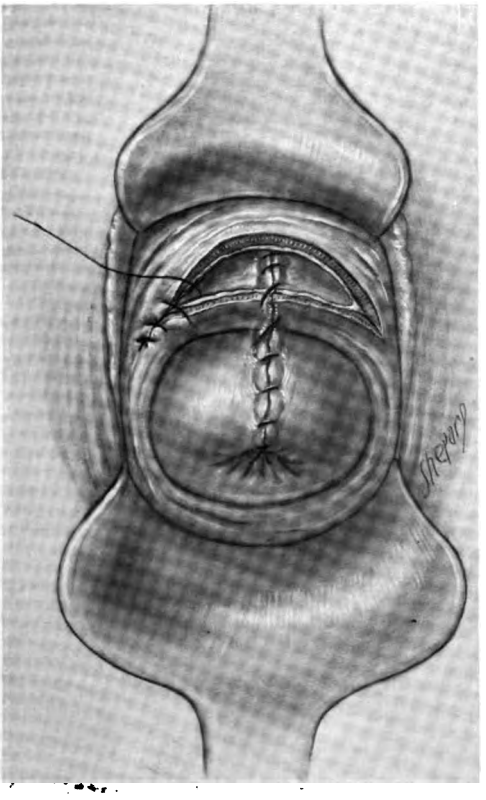

FIG. 168. ANTERIOR COLPOHYSTEROTOMY. Closure of the vaginal incision.

widely as possible to break any peritoneal adhesions in the inversion funnel (these were found in two cases). Each round ligament, as it passes into the slit, is seized by a pair of Kocher forceps and pulled upwards, while at the same time an assistant pushes the fundus uteri upwards from the vagina. By this means a thick ring, formed by the uterine walls, is seen surrounding the slit formed by the inverted uterus. This ring is divided posteriorly, the incision passing through the entire thickness of the uterine wall. By this means a partial reduction is ob-

tained by vaginal taxis and the constricting portion of the uterus is exposed; the incision is continued through this portion until a sufficient opening is formed to permit the introduction of the forefinger to a point below the fundus, after which firm, regulated pressure can be exercised upon it and reduction easily secured. The incision in the posterior uterine wall, a little over 1½ inches in length, which is now left, can readily be united by two or three deep sutures of silk or chromic catgut covered by a superficial Lembert suture of catgut."

The advantages of the vaginal over the abdominal route may be summarized as follows:

1. There is less shock following operation by the vaginal route. This is important since many patients with inversion of the uterus are extremely anæmic from excessive flowing and are in no condition for an abdominal operation.

2. There is less peritoneal contamination. The exposed endometrium where the uterus is inverted is sterilized with difficulty. When the reinversion is accomplished from below there is less danger of contaminating the clean peritoneum than by the abdominal route.

3. Experience has shown the disadvantages of being obliged to combine operative manipulations through the vagina with the abdominal technique. Such manipulations in the hands of the operator add to the dangers of peritoneal contamination; and the value of any operative technique is lessened when an important part of the operation must be entrusted to an assistant no matter how skilled.

4. If drainage is desired after the reposition has been accomplished, the way has been prepared in the use of the vaginal route for the most effective form of drainage.

SECTION XII

OBSTETRICAL OPERATIONS

BY

JOSEPH B. De LEE, A.M., M.D., F.A.C.S.

Professor of Obstetrics, Northwestern University Medical School; Obstetrician to the Chicago Lying-In Hospital and Dispensary, and to Mercy Hospital, Chicago

CHAPTER I

OBSTETRICAL OPERATIONS

VAGINAL CÆSAREAN SECTION

GAINING access to the cavity of the pregnant uterus by means of deep anterior and posterior cervical incisions, properly called vaginal hysterotomy, constitutes the operation generally known as vaginal cæsarean section.

Indications. When the cervix is closed and an indication arises for rapid delivery, and, second, when the cervix is diseased and nature is unable to overcome the obstruction, vaginal cæsarean section may be done. Under the first caption may be placed eclampsia, abruptio placentæ, hyperemesis gravidarum, uncompensated heart disease, lung disease, œdema pulmonum, asphyxia in utero due to prolapsed cord, in short, all acute complications on the part of the mother or infant. Under the head of obstructions may be mentioned cancer, stenosis, antefixatio uteri, and scars from old operations.

Early in pregnancy, vaginal cæsarean section is the simplest and quickest method of emptying the uterus but it is seldom required, since, except in cases of greatest urgency, the two-stage method of therapeutic abortion almost always suffices. In the middle trimester, it has more frequent application, but here too, the preliminary methods of dilating the cervix will usually enable us to empty the uterus in good time. Acute emergencies of the seventh and eighth lunar months are often well handled by vaginal hysterotomy. In the ninth and tenth months, most accoucheurs prefer abdominal cæsarean section, in which I agree. The latter is easier, especially in primiparæ, and there are fewer complications that may tax a poor technician's skill. When therapeutic abortion is indicated, where it is desirable to sterilize the woman also, the anterior cul-de-sac may be opened after the uterus is emptied, the tubes pulled down and exsected. In such cases the writer prefers to make a short Pfannenstiel incision, remove the ovum, sew up the uterus, and exsect the tubes. The appendix may be removed at the same time if advisable.

Conditions. Delivery from below must be possible, that is, the pelvis must be large enough, and presentation and position of the child favorable. Although some authors recommend the operation in placenta prævia, I would consider this a contra-indication, and Bumm recently

retracted his recommendation. The child must be living, unless the indication for haste on the part of the mother is imperative. The operation simply overcomes the resistance of the cervix, and it is highly important

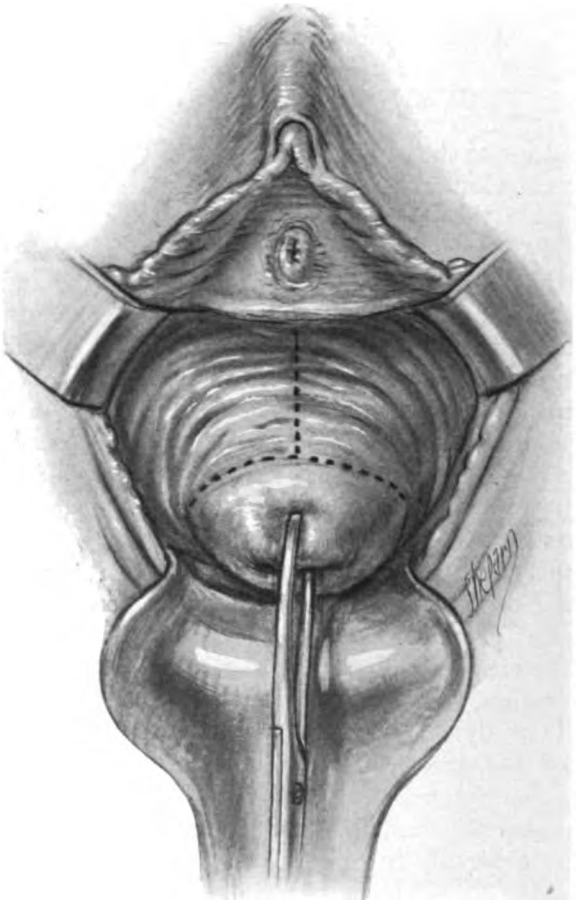

FIG. 169. VAGINAL CÆSAREAN SECTION. Line of incision.

to determine beforehand if there is an œdema of the connective tissue or excessive friability of the tissues.

Anæsthesia. General principles apply. Operation may be done under local anæsthesia, 0.5 per cent novocaine combined with morphine and scopolamine. These drugs are not used if the child is viable. Ether

is preferable in the vast majority of cases. Nitrous oxide-oxygen anæsthesia causes too much local venous congestion and oozing.

FIG. 170. VAGINAL CÆSAREAN SECTION. Freeing the bladder from the cervix.

The operation. If the parturient is close to the end of pregnancy and primiparous, it is best to make a deep unilateral episiotomy—on that side to which the occiput points if forceps are to be used; on the opposite side, if version is to be performed. This will prevent laceration

of the perineum during the subsequent delivery. If the episiotomy wound bleeds too freely, it may be sewn up temporarily, the line of suture being at a right angle to the line of incision. Dührssen insisted on the necessity, in case the child is at full term, of making both anterior

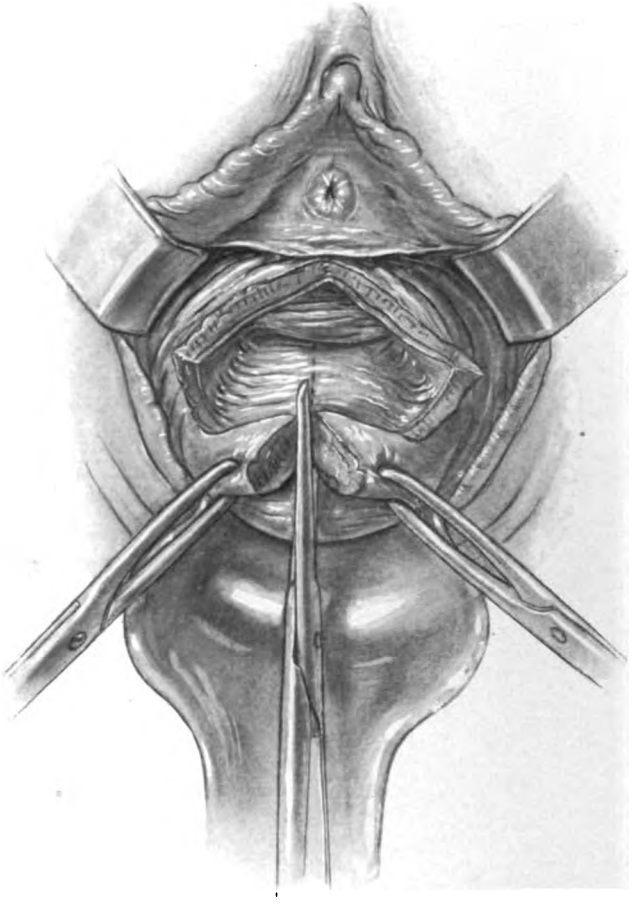

FIG. 171. VAGINAL CÆSAREAN SECTION. Splitting the cervix.

and posterior cervical incisions. Bumm finds the anterior incision, if extended, gives sufficient space. My experience accords with Dührssen's. The cervix must be in the median line. It is often twisted by the rotating presenting part to one or the other side. A short broad retractor and

two trowel retractors expose the field. A short transverse incision is made at the junction of the vagina with the cervix, which is drawn down with the volsellum forceps. This exposes the pubo-vesico-vagino-cervical fascia. With blunt-pointed scissors a median incision is made in the

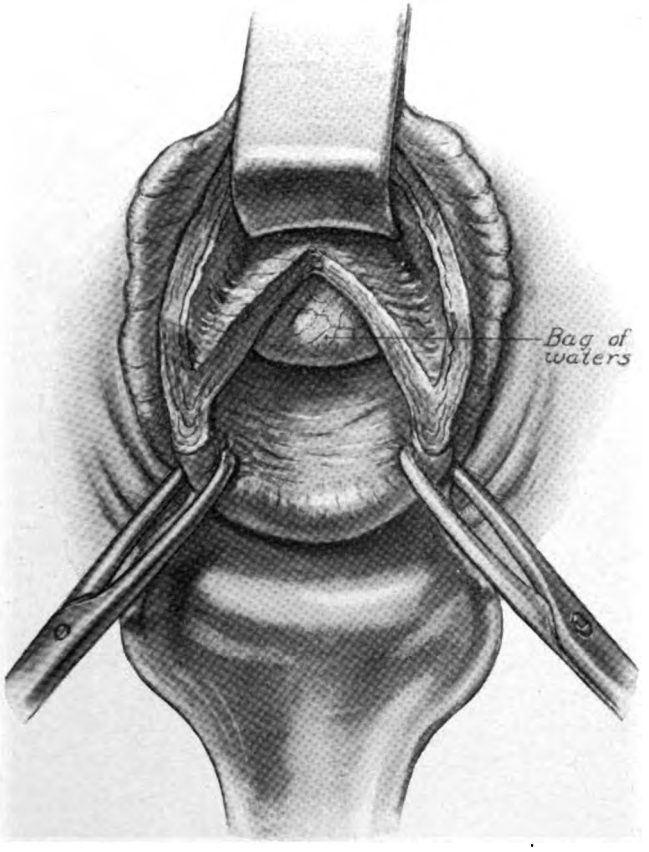

FIG. 172. VAGINAL CÆSAREAN SECTION. The cervix incised to the internal os.

vagina and fascia extending to within 2 cm. of the urethral opening (Fig. 169). The fascia must be incised as indicated, else there will be difficulty in the subsequent extraction of the fœtus. The bladder is separated from the vagina, and with a gauze covered finger pushed off the cervical wall upward and laterally (Fig. 170), but care is required not to cause hæmorrhage by tearing the veins of the broad ligaments.

The cervix is grasped by two volsellum forceps and split medially to the internal os. Figure 172 shows this section made and the bag of waters pouching in the opening. Continuing, as shown in Figure 173, the bladder

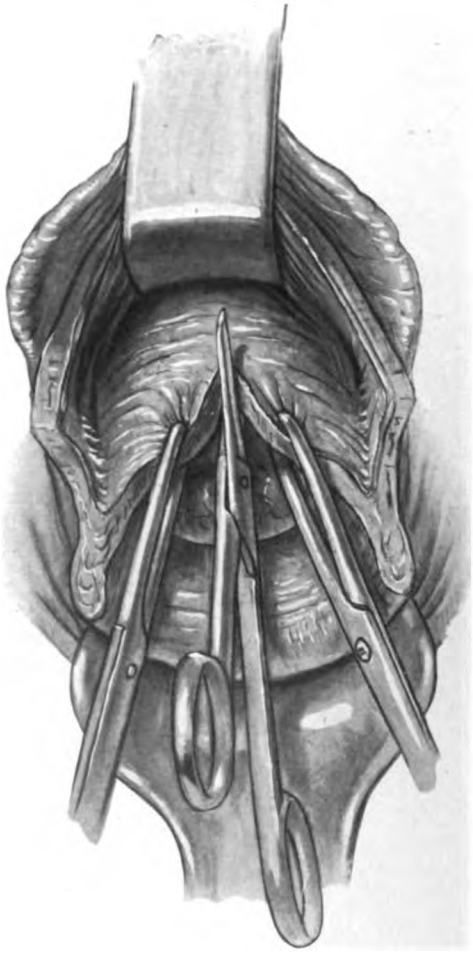

FIG. 173. VAGINAL CÆSAREAN SECTION. Incising the lower uterine segment.

is carefully stripped from the anterior uterine wall until the uterovesical fold of the peritoneum can be seen or felt at the upper end of the wound. A narrow speculum is inserted to expose the field clearly. The medial uterine incision is continued upward, the volsellum forceps being placed

on successively higher portions of the cervix and lower uterine segment, so as to pull them down into the bite of the scissors. Care should be exercised to keep in the median line and to avoid injury of the peritoneum.

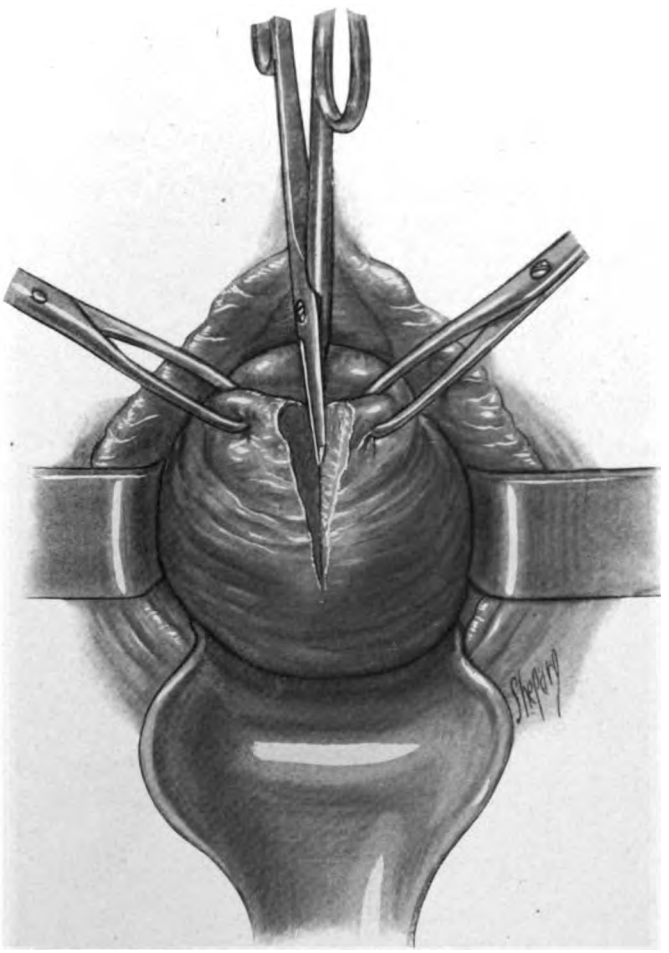

FIG. 174. VAGINAL CÆSAREAN SECTION. Incision of the posterior wall.

This is pushed off the lower uterine segment before the advancing scissors by means of the finger.

For a child weighing about 3½ or 3 pounds, an anterior incision 10 cm. in length usually suffices. One may test the size of the opening by

passing through it the fist, made about the size of the baby's head by holding in it a large ball of cotton. If more space is needed, the anterior incision may be extended upward or the posterior wall may be incised also. Dührssen makes the posterior cut first as a routine (Fig. 174).

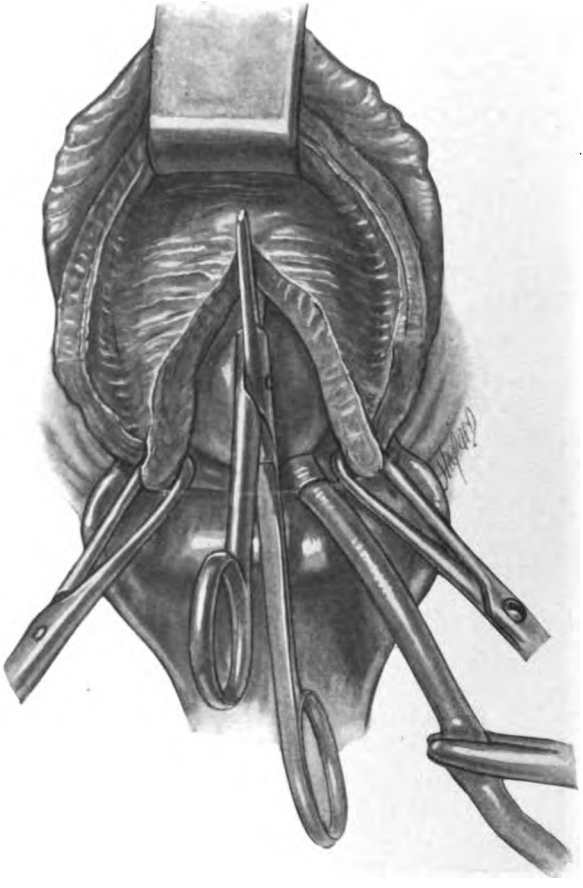

FIG. 175. VAGINAL CÆSAREAN SECTION. Using a Voorhees bag to pull down the cervix for incision.

Grasping the cervix with bullet forceps it is split to the vaginal reflection, then the peritoneum of Douglas' cul-de-sac is pushed upward and loosened at the sides, after which the lower uterine segment is divided as high as needful. Delivery is now accomplished by forceps or by version and extraction, according to preference; I prefer forceps. If

labor pains are present, hæmorrhage is not usually profuse, but if it is, manual removal of the placenta and uterine tamponade are rapidly performed, pituitrin and ergot given hypodermically, and pituitrin injected into the cut edges of the uterine muscle. A careful examination of the parturient tract is made to determine the extent of the wounds to be

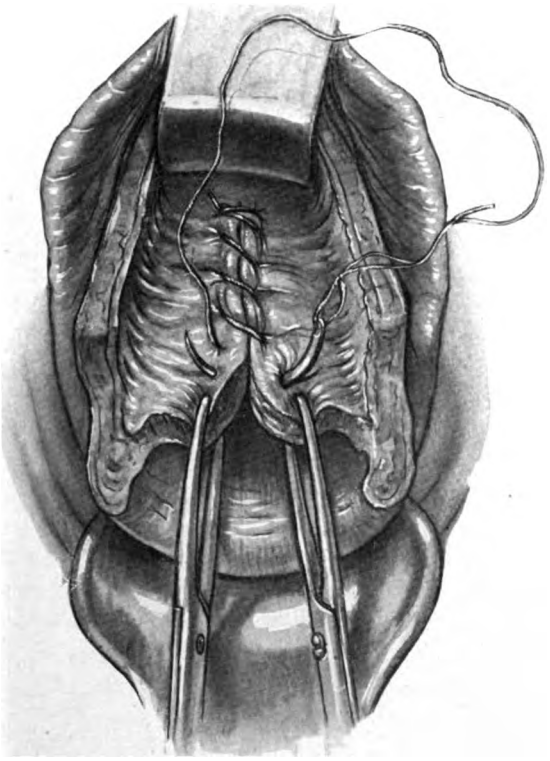

FIG. 176. VAGINAL CÆSAREAN SECTION. Suture of the anterior incision.

sutured (Fig. 176). By traction on the volsella, placed on the uterine edges, the uppermost angle of the incision is readily drawn into view; a narrow speculum placed so as to retract the bladder will assist in affording a good exposure. A continuous suture of No. 2 plain catgut, taking in the mucosa and part of the muscle, is rapidly put in, care being observed not to include the uterine packing, and over this a second layer is placed. The vesicovaginal fascia is united with No. 1 chromic catgut, after which

the vagina is closed with a running suture of No. 1 chromic gut. A strip of gauze may be left to drain the large subperitoneal space for twenty-four hours. If the posterior wall has been divided, this is sutured first, with a running through-and-through No. 2 chromic catgut suture, tied on the interior of the cervix. Finally, the perineum is repaired. The operation requires from eight to twenty minutes for the delivery of the child, and from twenty to forty minutes to repair the incisions. If, as with cancer, the uterus is to be extirpated, the anterior and posterior incisions are prolonged until the uterus is bisected, and the broad ligaments are clamped and tied, each half being removed after the method of P. Müller.

Dangers. Injury of the bladder and ureters may be avoided by proper technique, by going slowly without attempts at spectacular operating. In pushing the bladder off the cervix it must be borne in mind that, as labor progresses, the bladder is drawn up and usually to the right side. In breech and shoulder presentations the bladder is more central. Hæmorrhage is usually not marked if the uterus is divided cleanly in the median line, if the tissues at the side are spared, and the cuts do not tear further; this will not occur if they are properly placed at first. In one case the tissues were so friable that the traction ligatures and volsella pulled out, and hæmorrhage was so profuse that the vaginal route had to be abandoned. After delivery, pituitrin, ergot, and packing the uterus will stop hæmorrhage. Pulling down the uterus strongly also has a good influence. There is no reason why Momburg's constrictor may not be applied if needed at this stage. In one case the broad ligaments and pelvic connective tissue were so œdematous that the cervix could not be drawn down for incision, and abdominal cæsarean section was indicated. To gain access to the cervix when it is high up Dührssen advised a deep, paravaginal perineal incision, or deep episiotomy, and also lately, what seems to be a real improvement in this operation, the metreurynter, by means of which the cervix is pulled down and on which it is incised (Fig. 175). When the fully distended colpeurynter can come through the incision, the child can be easily delivered. Should the bladder be opened, it is to be sutured after delivery and a permanent catheter inserted. If the peritoneum is torn, it is sutured at once. In both instances drainage from below is indicated.

PUBIOTOMY

Section of the pelvic girdle, though done twice before, was thought out and invented by Sigault in 1768. It was performed very frequently in the latter part of the last century, but is now becoming obsolete. In

several clinics it still enjoys some vogue; recently Jellett recommended it, and here and there it is occasionally practiced, but it is rapidly being displaced by the newer forms of cæsarean section. Symphysiotomy or section of the joint is so seldom done that it will not be described, although

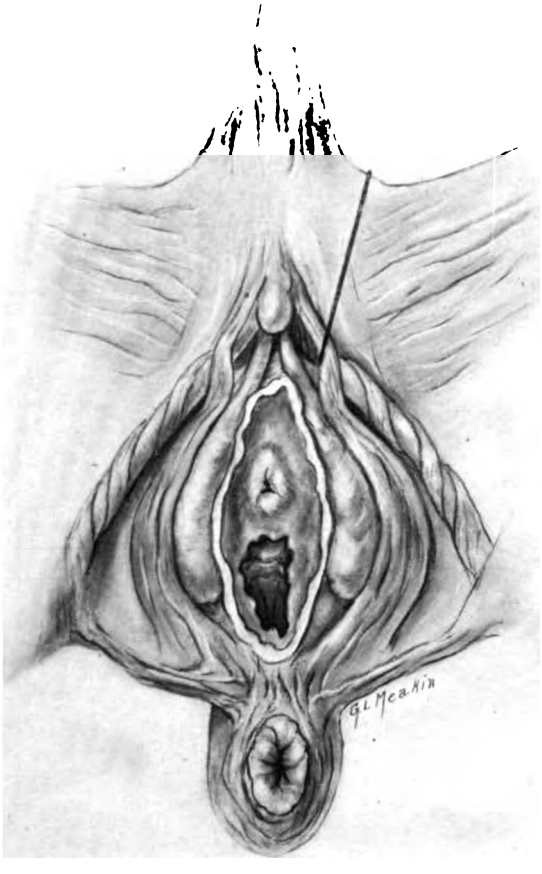

FIG. 177. THE ANATOMY OF PUBIOTOMY. Line of incision in the bone.

very recently a subcutaneous method has been advocated which may obtain some recognition.

Pubiotomy, or hebosteotomy (section of the bone alongside the joint), offers several advantages over symphysiotomy and is therefore preferred. The indications for the enlargement of the pelvic girdle are given by the necessity to obtain more room for the passage of the fœtus, i.e., con-

tracted pelvis. Oversize of the child is not generally considered a good indication because the soft parts will be torn too much by the large fœtus. Impacted face presentation and persistent occipitoposterior presentation have formed the indication in some instances, but, the writer feels, improperly, because we have better operations for obviating such difficulties.

FIG. 178. THE ANATOMY OF PUBIOTOMY. Position of the veins likely to be injured.

Conditions. (1) The pelvis may not be too small, that is, less than 7 cm. in the flat, and 7½ cm. in the generally contracted pelvis, with a child of 7 pounds; it may not be ankylosed, as by tubercular disease, advanced age, etc.; (2) the child may not be too large, especially in primiparæ; (3) the child must be in good condition and not deformed, as for example in hydrocephalus and anencephalus; (4) the maternal soft

parts may not be infantile nor rigid, hence hebosteotomy should be seldom attempted in primiparæ, especially if very young or old; (5) the mother must be in good condition and not infected, that is, there must be no fever, a slow pulse, and clean conduct of labor; (6) the cervix must be effaced and dilated; (7) the woman must be in a well-equipped obstetric operating room, with plenty of assistants, since the operation is not one to be done with makeshifts in the home.

Pubiotomy is never an operation of election. It should always be preceded by a long test of labor; i.e., the woman should be given much time in the hope that hard pains will mould the head through the pelvis. After we are convinced that nature is powerless we have the choice of two methods, the low cervical cæsarean section and pubiotomy. If the vaginal route is selected, we first make a careful trial of the forceps. If we fail with these to draw the head into the pelvis, the instrument is left in place, and the pubiotomy performed.

It will be seen that hebosteotomy is useful only in borderline cases, where the attendant, believing the child would be delivered, has waited until labor has advanced so far that cæsarean section would be too dangerous, or has even attempted delivery with the usual methods. The selection of the operation now is one of judgment of the condition of the mother and babe and of the probable outlook for both; it is, therefore, largely subjective. In shoulder and breech presentations, where, of course, we cannot await the test of labor, placing the indication becomes still more subjective and will be aided by knowledge of previous deliveries, pelvic and fœtal mensuration, the state of the soft parts, etc. I feel that pubiotomy should be restricted in favor of abdominal delivery in good cases, and the older methods should be preferred in unfavorable ones. The mortality of pubiotomy is about 5 per cent for the mother and from 4 to 8 per cent for the child, but individual operators report 38 and 40 cases without maternal death.

Operation. It is important to know the special anatomy (Figs. 177 and 178). The crus clitoridis is always torn. If the bone is sawn as shown in the diagram no large artery is encountered, but free bleeding from the venous plexuses is to be expected. It has been fatal. The ligamentum arcuatum is always torn and sometimes the vagina too, a rather unwelcome complication, which is likely to lead to infection of the bones and surrounding connective tissue. The nearness of the bladder and ureters must not be forgotten.

The operation may be done entirely subcutaneously (Bumm, Ayres, Walcher), or by a half "open" method (Döderlein). The latter is the one preferred by most accoucheurs, including the writer.

Preparations are made for a serious operation, although it is usually

not one. In rare cases hæmorrhage and lacerations occur which tax the skill of the most expert. Figure 179 shows the special instrument needed. Two trays are to be used, one for instruments for the work on the bone and the other for the vaginal work. If it is necessary to return to the wound in the joint after the hands have had to do with the parturient canal, the operator should draw on another pair of sterile gloves.

The patient lies on her back and the legs are held nearly horizontally by the two assistants. A transverse or longitudinal incision, one inch long, is made over the left pubic tubercle, down to the rectus fascia; a

FIG. 179. LIGATURE CARRIER FOR USE IN PUBIOTOMY.

longitudinal incision is made through the fascia just large enough to permit the finger to pass behind the pubis. This finger gently separates the bladder and fat from the bone, until the ligamentum arcuatum is left. The needle armed with a silk ligature, is guided by the finger around the bone, the point of the needle adhering as closely to the bone as possible. When the point has rounded the ligamentum arcuatum, it is bent sharply forward, while an assistant pulls the labium toward the right side—to bring the opening in the skin far from the flow of the lochia, and by the sliding of the tissues, to close the passage of the needle. A nick with the knife allows the tip of the dull needle to emerge; the thread is grasped and the needle withdrawn. The saw is pulled through by means of this thread, and the saw handles are attached. After the needle has been placed the bladder is to be catheterized to test its integrity; when this is assured, the sawing is proceeded with. By to-and-fro motions of the saw, the action resembling cutting a bar of soap with a string, and making short strokes, the bone is severed. In this motion the saw may not be sharply bent. Mayer advises placing the patient in the Walcher position while sawing the bone, and raising the limbs gradually, to prevent too sudden separation of the two halves of the pelvis and injury

to the soft parts between. Costa does the same, and Kerr uses the Walcher position for the delivery.

Hæmorrhage is usually free from both wounds, while and just after the bone is sawn through. The upper wound is quickly packed with hot

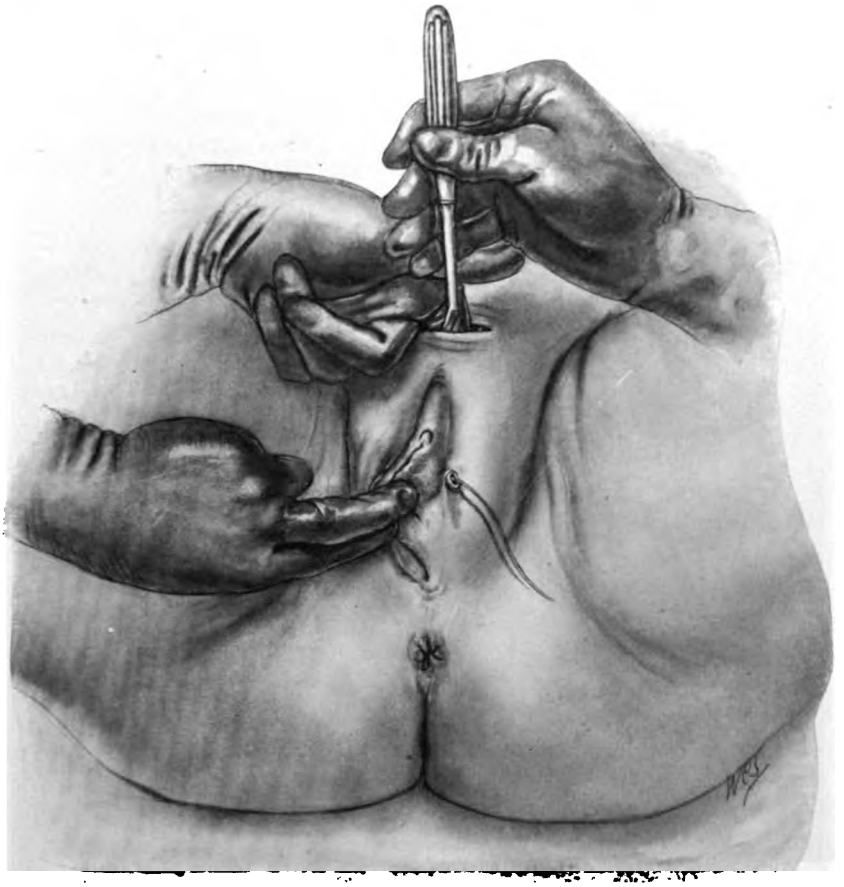

FIG. 180. PUBIOTOMY. Passing the needle around the bone.

iodoform gauze, a stitch of silkworm gut closes the lower puncture, and an assistant makes counterpressure from the vaginal surface by means of a large gauze swab. In a few minutes the hæmorrhage has usually ceased, the gauze may be removed, and the pubic wound sewed up with three deep silkworm gut sutures. The bones separate with a dull crunching sound, which is very unpleasant, at first about 2 cm., and during

extraction up to 6 cm. More separation than this endangers the sacro-iliac joints.

Some operators leave the delivery to nature or wait for a later indication, especially in primiparæ, but by the majority immediate delivery is

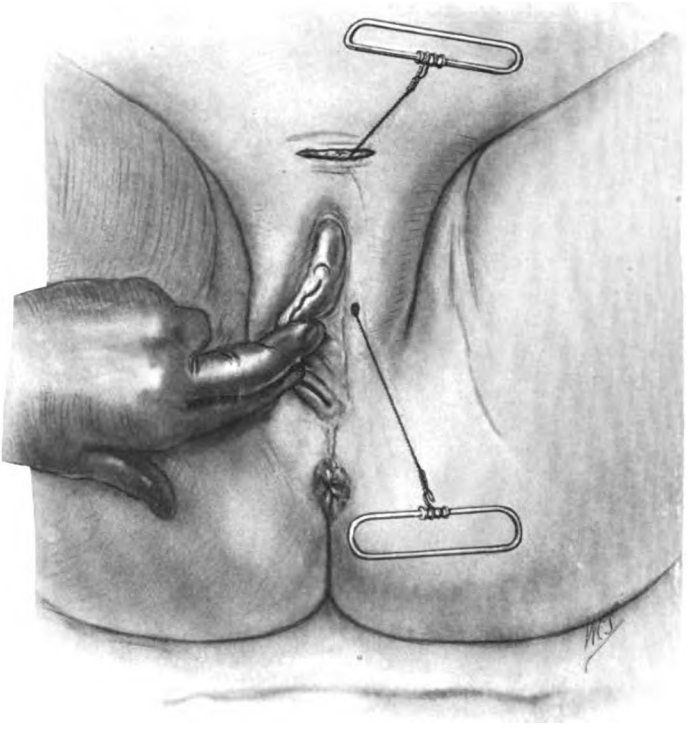

FIG. 181. PUBIOTOMY. Sawing through the pubic bone.

practiced. In primiparæ I prefer to leave the delivery to nature, as does Stöckel also.

Version is generally not advised. The head may be pressed into the inlet from above, or a few pains awaited and then the forceps applied. In primiparæ a deep episiotomy should always be made before applying the instrument, and in multiparæ also, if the introitus is small. The danger now to be avoided is rupture of the anterior vaginal, urethral

and bladder wall, hence the extraction of the child must be very deliberate and the direction of traction be downward, to relax the anterior wall as much as possible and preserve the vesicovaginal fascia. During the delivery the assistants press the pelvis together from the sides, but I believe Kerr's suggestion to use the Walcher position is better. It is highly important that the mechanism of labor be favorable; a posterior occiput or a brow presentation, therefore, should be corrected previous to the extraction. It is my practice to remove the placenta very soon, give hypophysin and ergot hypodermically, and pack the uterovaginal tract with gauze as a routine. All vaginal injuries are repaired, a clean pair of gloves put on and the pubic wound inspected and treated, if necessary. Catheterization of the bladder now determines if this organ is injured.

Complications. Hæmorrhage is easiest to control in the open symphysiotomy when clamps may be placed on the crura clitoridis and bleeding veins, but in one case I had to pack the vagina tightly and place a sand-bag on the pubis to exert counterpressure. In subcutaneous operations compression from within and without for from five to fifteen minutes almost always stops the hæmorrhage, but if it does not, delivery must be effected at once, the uterovaginal tract firmly plugged, and counterpressure from without provided. If this fails, which is very unusual, a deep suture may be placed on either side of the wound in the bone, but it is better to apply a Momburg belt for fifteen minutes, during which time bimanual compression is continued over the area of separation. If hæmorrhage recurs on loosening the belt, the pubic joint must be exposed, and the source of the bleeding searched for and quelled. If spontaneous delivery is to be awaited, a vaginal tampon is inserted, firmly compressing the site of bone section, and counterpressure from the outside made with pads and T-binder. These are all removed at the end of thirty or forty minutes, when the cessation of the bleeding is assured.

Hæmatomata do not develop so long as compression is kept up, but as soon as the woman is placed in bed, they may form (one-fifth of the cases reported), and perhaps are favored by rough handling of the patient in transporting her. If they are large and growing they must be incised and packed—an unlovely operation. If suppuration sets in, which is not unusual, early drainage is indicated.

Lacerations. Although waiting for spontaneous delivery seems to be the ideal treatment after opening the pelvis, the majority of accoucheurs are not in favor of it, even after proper trial. It is to be reserved for primiparæ, for cases of marked spacial disproportion when the cervix is not fully dilated, and where no indication for the immediate

termination of labor exists. If a vaginal tear communicates with the bone, the immense wound is closed as far as possible, and a gauze drain placed in the prevesical space and led out through the vagina. Injuries to the bladder are usually in its anterior wall, and cannot be repaired at this time. A permanent catheter is placed in the bladder and 5 grains of hexamethylenamin given four times daily. If lime salts clog the catheter it is to be removed every six hours and replaced by a new one. In order to avoid the possibility of urinary infiltration the nurse should be instructed to report immediately if the urine ceases to flow. Lacerations occur from too great or too sudden separation of the bones, and from direct injury with the needle; the soft parts may also be cut between the head and the sharp edges of the bones.

After-treatment. After the wound is dressed a broad adhesive strip is passed three-fourths of the way around the pelvis at the level of the trochanters, and the knees bound together with a towel. For the first week great care is required in handling the patient, because the bones are tender and an hæmatoma may be started. A bed arranged with a frame on which the patient may be raised for catheterization, irrigation, urination, etc., while not absolutely necessary, much facilitates the treatment and increases the puerpera's comfort. For nine days the woman should lie on her back; after this she may move about in bed. She may get up at the end of three weeks, and may walk as soon as she feels able to do so, which is usually in the fourth week.

Jellett expressly recommends attempting to prevent bony union and thus enlarging the pelvis, and believes that many women will have spontaneous deliveries thereafter.

CLASSIC CÆSAREAN SECTION

Abdominal delivery is getting to be one of the most common operations; indeed, it is performed much too often. Many men know of only one way out of a complicated obstetric situation—cæsarean section. In olden time we did too few sections; the opposite is true today. At present there are three forms of abdominal delivery, and when it is determined to remove the child from above the pelvis, the method most applicable to the particular case should be selected. We will first describe, therefore, the technique of the three operations and then discuss the application of each to actual practice.

The old, the classic, or so-called conservative section is the one most usually practiced, the incision in the uterus being made in the fundus uteri or the corpus. The operation is therefore called corporeal cæsarean section. In the new methods the incision is made in the cervix and lower

uterine segment. They, in contradistinction, might be called cervical cæsarean section. The abdomen is opened above the pubis, the peritoneum and bladder are pushed down from the distended cervix and the child extracted. In the Latzko operation, the peritoneal cavity is not opened. The bladder is pushed to one side, the peritoneal reflection is raised toward the navel, and through the bared, lozenge-shaped surface of the cervix thus provided the child is removed.

In the classic cæsarean section it is best to operate when the woman has had regular labor pains for an hour or more. Barnes (1876) advised operation just before labor began in order to avoid the disadvantages of emergency, a plan also recommended by Bar. The objections to this are: hæmorrhage from the uterus is greater, as the uterus in premature labor does not contract well; the cervix is closed and drainage poor; it is difficult to determine the exact date of term and a premature infant or premature twins may be delivered. Occasionally one finds after labor has begun that cæsarean section is not necessary. The advantages of operating before labor has begun are that everything can be gotten ready without hurry, as for ordinary laparotomy, which means much for the assistants and nurses; one can operate by daylight; the accoucheur can usually have had some rest; the bag of waters is still intact; the cord or extremities will not have prolapsed; accidents or delays in transportation, etc., are avoided. By the prophylactic administration of ergot, the injection of pituitrin, by packing the uterus with hot wet pads, brisk kneading, and compression of the aorta the hæmorrhage is controllable; by dilating the cervix, drainage of the uterus may be provided and by careful study of the cases the proper time for the operation may be determined. I often operate before labor begins. When a Porro is to be performed, the element of danger from hæmorrhage and lochial seepage is eliminated, and, therefore, the operation may be undertaken any time.

It is important to get the patient into the best possible general health beforehand. Regulated outdoor exercise, care of the bowels, and much sleep are provided. The skin of the abdomen should be cured of eczematous and other eruptions. As a routine may be recommended daily washing of the abdomen with tincture of green soap. Douches, without special indication, are forbidden, and the patient is impressed with the importance of local cleanliness, and the abstinence from intercourse or self-examination. If possible, she should be in the maternity a week or more in advance of the date set, especially if she has had a previous section. General diseases—for example, nephritis and hæmophilia—are treated as thoroughly as we know how. Gentle laxatives are used a few days before, and an enema the day of the operation.

Preparations for reviving the child should never be forgotten. Four

assistants are needed—one for the anæsthetic; one, specially trained, to resuscitate the child; one to help on the other side; and one to hand instruments, thread needles, supply sponges—duties which in most modern hospitals fall to the nurse. Another sterile assistant may be needed if the case is complicated or requires extirpation of the uterus.

Straight ether is the best anæsthetic. In two cases operated under the gas-oxygen method, the experience was not satisfactory, the venous oozing, rigidity of the abdominal walls, and straining of the patient being very troublesome. If this method is employed, the gas may not be started until the operator is ready to make the incision, and delivery must be very rapid or the child will be asphyxiated. I have done twelve cæsareau sections under local anæsthesia, with 0.5 per cent novocain infiltration.

The abdomen is prepared by shaving, washing thoroughly with tincture of green soap and hot water, with bichloride 1:1000 and with 65 per cent alcohol; just before adjusting the laparotomy sheet it is swabbed with 40 per cent of tincture of iodine in alcohol, which is washed off with 65 per cent alcohol immediately before making the incision.

Just before starting the anæsthetic an hypodermic of aseptic ergot is given and the patient catheterized. The incision is made in the linea alba; it should be about 5½ inches long, a little below the navel and a little to the left of the latter. In primary sections where there is no diastasis recti, Lennander's incision may be made. In the New York Lying-in Hospital the opening is made high above the navel. As the abdominal wall is sometimes very thin, one may not cut too deeply. It is best to make a small opening and cut the balance with scissors on two fingers inserted into the peritoneal cavity. A long sponge covered with a rubber is packed around the fundus in a horseshoe shape to prevent soiling of the peritoneum. A double volsellum forceps is attached to the uterus at each corner of the wound, and thus it is held firmly against the abdominal wall. With another knife a longitudinal incision, 5 inches long, corresponding to the abdominal one, is made half through the thickness of the uterine wall, and with lessening strokes the cavity of the uterus is opened; then, cutting between two fingers with scissors, the opening is enlarged both ways to the size of the first uterine cut. Liquor amnii gushes out while the operator searches for one foot, on which he makes the breech extraction, following minutely the classic operation, with Smellie-Veit on the after-coming head. Now a hypodermic of 1 c.cm. of pituitary extract is given. The assistant lifts the uterus gently against the abdominal wall to keep liquor amnii and blood out of the peritoneal cavity. Clamping the cord in two places and cutting between requires only an instant, the operator handing the child to an assistant who stands

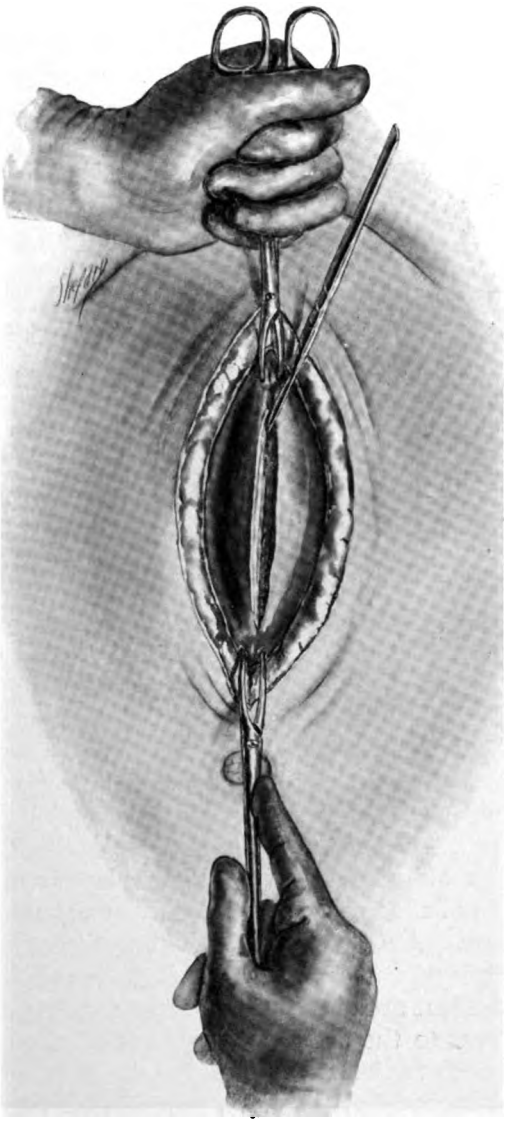

FIG. 182. CÆSAREAN SECTION. The uterus being steadied by volsella.

at his elbow bearing a large tray covered with an aseptic blanket. The placenta usually falls free into the hollow of the uterus, but the membranes must be pulled off gently and slowly to get them all. There should be no hurry unless there is too much bleeding. After the secundines are out, the interior of the uterus is wiped perfectly smooth with a gauze pad. all shreds of placenta and membranes are removed, and a clean pad is stuffed into the gaping cavity, which rapidly closes as the organ retracts and contracts. This is aided by gentle kneading and firm compression from the sides. Occasionally application of a hot wet sponge and an intramuscular uterine injection of pituitrin are required.

The most important part of the operation is the uterine suture (Fig. 183). Beginning at the upper end of the incision a row of sutures is carefully inserted just above the endometrium, so that this is not turned into the wound; the same suture is continued upward from the lower end of the incision, taking in substantial portions of the muscle. The two ends of the catgut are tied, leaving one knot. Beginning at the lower end of the incision, a third row of sutures is passed and again continued downward from the upper end of the incision so as to unite the peritoneal surface of the uterus. This suture is tied at the lower end in the second knot. For extra safety I usually put in a few interrupted superficial sutures; indeed, I often make five complete rows, in order to keep broad surfaces in close apposition until they have united. No. 2 twenty-day catgut is used. Care should be used to get accurate coaptation in the angles and to avoid too much constriction of the tissues, for fear of necrosis when the uterus contracts and tightens the sutures. The knots must be firmly tied.

Time taken to apply an accurate uterine suture is well spent. Too rapid and spectacular operating is responsible for many bad results. Operating thus one often does not see the gut or omentum at all, and little if any peritoneal toilet is required. Great care should be exercised to close the abdomen well, as hernia is favored by the overdistension of pregnancy.

Complications. Adhesions are seldom met in primary operations but, nevertheless, it is wise not to cut boldly into the abdomen. After previous sections, adhesions are the rule. The most common are of the omentum or of the uterus to the abdominal wall, or of the omentum to the uterus. Rarely, a coil of gut is attached to the uterus under the line of the incision, and still more rarely the cæcum, appendix, or sigmoid may be adherent behind and tear if the uterus is eventrated. Where adhesions are suspected, the abdominal wall should be opened at a spot free from them, and two fingers inserted to determine their location and extent. A clear space on the uterus should be quickly made, and the child and placenta delivered, after which the adhesions are dealt with according to general principles. It is best not to deliver the uterus if there are adhesions. Adherent

gut must be very tenderly handled. If the omentum can be freed from the uterus or abdominal wall without denuding it much, this should be done, but large, rough areas only invite new adhesions. If the uterus is intimately bound to the abdominal fascia, it may be best not to attempt its separation unless extirpation of the organ is to be performed or the tubes exsected. In the latter instance a segment of the uterus, together with the abdominal scar, may be excised. In a second cæsarean section the uterine

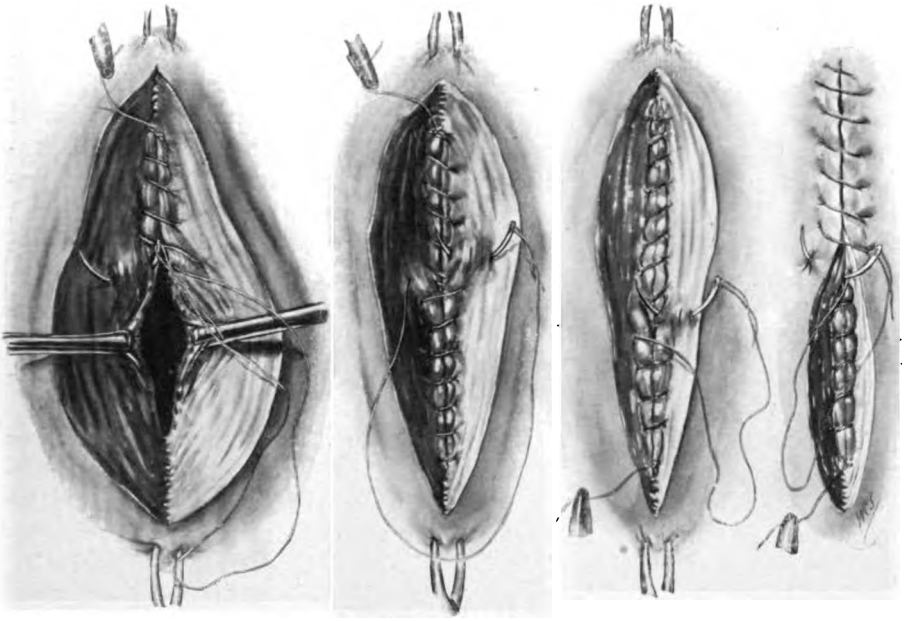

FIG. 183. CÆSAREAN SECTION. The uterine suture.

incision should be parallel to and close to the scar of the first one, and weak portions of the muscle exsected.

If a hernia in the old abdominal scar is present, the sac is to be exsected and the edges of the fascia and the recti muscles brought together anew if possible.

The placenta. In 42 of 67 cases where the site of the placenta was noted the organ was situated on the anterior wall and had to be cut to gain access to the infant. It is not possible to be sure of the location of the placenta beforehand. The course of the round ligaments converging anteriorly, and the prominence of the veins in the violaceous surface of the uterus give some indication of it. If the first cut into the muscle causes profuse hæmorrhage, anterior insertion may be suspected,

but the operation does not differ from the usual one, except that the movements must be hastened. I usually cut right through the placenta.

Hæmorrhage. Nowadays severe bleeding is rare, because we give an hypodermic of ergot before the anæsthetic is started and one of pituitary extract immediately after the delivery of the child, but if the placenta has been cut or torn there may be more blood lost than is permissible (e.g. in an anæmic woman), and the flow must be quickly staunched. In such cases another injection of pituitrin is made directly into the uterine wall and the cavity of the uterus packed with a hot wet towel. The uterus is then squeezed together and massaged until it contracts well. In an emergency the aorta may be compressed by the assistant. The pack inside is replaced by a dry laparotomy pad and the uterus quickly sewed up. The fundus may be covered with a hot wet sponge and again massaged if needful. If these measures do not quickly cause uterine contraction and cessation of the bleeding, extirpation of the uterus must be considered. The operator must not forget that the blood may escape per vaginam also and in large quantities. If it is desirable to preserve the uterus and the hæmorrhage persists, uterine tamponade may be resorted to. Since the wound has been closed, packing is inserted from below in the usual manner. On three occasions I deemed it best to tampon. Recovery followed in each case.

Infection. If the case is known to be infected, the conservative cæsarean section is contra-indicated, and if delivery must be made abdominally, either the Porro operation or complete extirpation must be practised. In cases of gonorrhœa, conservative section is very dangerous, a point emphasized by Leopold; and it is best to consider these, too, infected. There is no way of determining beforehand that the parturient canal is aseptic. Fever, fœtid discharge, tympania uteri, and unhealthy wounds at the introitus are evidences of infection of the uterus, or at least are danger signals. In border-line cases the technique must be modified. (See Extraperitoneal Cæsarean Section.) If, during an ordinary cæsarean section, a septic focus is unexpectedly opened, for example, an infected dermoid, the intestine, or an appendiceal abscess, it is best to remove the uterus and provide free pelvic drainage.

Uterine drainage. While rubbing the interior of the uterus smooth, it is a good plan to pass the finger down into the cervix, but not through into the vagina, to see if it is patulous, unless examination beforehand has shown that the os is open. If the cervix is closed by scars so that a crow's quill cannot pass, the uterus is to be amputated. A normal cervix will open spontaneously under the influence of the after-pains. If the accoucheur fears that there is not enough drainage, he may pass gauze or a tube through the cervix into the vagina. It is highly im-

portant not to catch the gauze in the uterine stitches. One fatality from this cause is on record.

After-treatment. This does not differ from that after the usual laparotomy. Cathartics are usually not administered until the sixth or eighth day, and then not unless required, the bowels being unloaded by enemata. Milk and molasses, ½ pint of each, make a very efficient clyster, which may be repeated. Sometimes chamomile tea produces a free evacuation of fæces and flatus. The baby is put to the breast at the end of from twelve to twenty-four hours.

Of the various postoperative complications, peritonitis, ileus, and uterine abscess only will be mentioned. If a beginning peritonitis is diagnosed, the patient must be constantly watched, that is, hourly observations must be made. If the pulse grows steadily faster, if the nausea increases to emesis, if the temperature rises, if the abdominal rigidity increases, with or without leukocytosis, in short, if the observer is convinced—and the time required to know seldom need exceed eight hours—that the infection is progressing, the belly is to be reopened and drained.

In the presence of a generalized peritonitis the maintenance of the general resistance by absolute rest and by the administration of fluids subcutaneously and by rectum is of the utmost importance.

Ileus and acute dilatation of the stomach occur, it seems to me, oftener after cæsarean section than after other cœliotomies. For ileus the usual methods of treatment are practiced. One that is serviceable after cæsarean section is to hang the woman inverted from the shoulders of assistants, and with the finger in the rectum push the heavy uterus up out of the pelvis; this is followed by a high colonic flushing of milk and molasses, with the patient depending. In one case an electric vibrator applied to the distended bowel seemed to help. Eserin had failed. Pituitrin is not recommended because the grinding contraction of the uterus may tear the sutures apart. The measures that have been successful in my practice in the treatment of gastric dilatation include having the woman lie on the stomach, with the foot of the bed elevated from 18 to 24 inches; gastric lavage repeated every four to six hours; massage of the stomach; and rectal feeding. Both ileus and dilatation may be caused by a tight abdominal binder, a point that I would emphasize strongly. In all probability a mild peritoneal infection is responsible for most of the cases, and bursting of the fascial suture for a few others.

Uterine abscess is to be suspected if there is a mild fever, with signs of local peritonitis or partial ileus. Usually the abscess breaks on the surface, the wound opening. With good drainage, the patient quickly recovers, but the uterus is permanently ventrofixed and the scar may give way in a subsequent pregnancy.

PORRO CÆSAREAN SECTION

In 1876 Porro, of Pavia, to avoid the dangers of hæmorrhage and of infection from the large uterus, which in those days was poorly sewed up, advised the amputation of the body of the uterus and the adnexa above an elastic ligature placed about the cervix, and the anchoring of the stump in the lower angle of the abdominal wound—an operation similar to supravaginal hysterectomy for fibroid, with extraperitoneal treatment of the stump. The operation had been suggested by Blundell in 1830. Later when Schröder dropped the sutured hysterectomy stump back into the pelvis, Isaac E. Taylor did the same for the stump after Porro's operation. Porro's radical operation did reduce the mortality of cæsarean section, and gained some vogue, but was soon replaced by the improved conservative operation of Sänger. This was called conservative because the uterus was not sacrificed.

Indications. It may be necessary to remove the uterus when myomata are present, especially if they are large or if they block the pelvis. Myomectomy may be performed in favorable cases if the woman desires more children. I did it six times with success. In osteomalacia the uterus as well as the ovaries should be removed. Uncontrollable hæmorrhage at the time of the cæsarean may necessitate amputation of the fundus. In cases of ruptured uterus, or of tears from previous efforts at delivery, if infection is present, it is best to remove the organ. In carcinoma cervicis total extirpation may be practiced. As a means of simple sterilization of the patient amputation of the uterus is hardly to be recommended, though in most cases, where performed, it has been justifiable.

There are no conditions. The best time to operate is before labor begins.

The technique is very similar to that of supravaginal hysterectomy. If the plan of operation is known beforehand, the abdominal incision should be near the pubis. After the child is delivered, two clamps are put on each broad ligament close to the uterus. Unless diseased, both tubes and ovaries are left. Both round ligaments are also clamped separately, or if they are near the tubes, or if the broad ligaments are full of varicose veins, they are included in the first clamp. After cutting to the tip of the clamps, two more clamps are placed on the broad ligaments, so as to reach below the level of the uterine arteries. They are applied close to the uterus in order to avoid the ureters. The tissue between the clamps is then incised. A curvilinear incision is then made through the peritoneum across the face of the uterus just above the bladder, extending from the cut edge of the peritoneum around one ligament

to the other, and the bladder is pushed down by the finger covered with a piece of gauze. Owing to the immense development of the veins of the broad ligament usually present, and to varicosities sometimes as large as one's wrist, it is impractical always to open up the connective tissue to

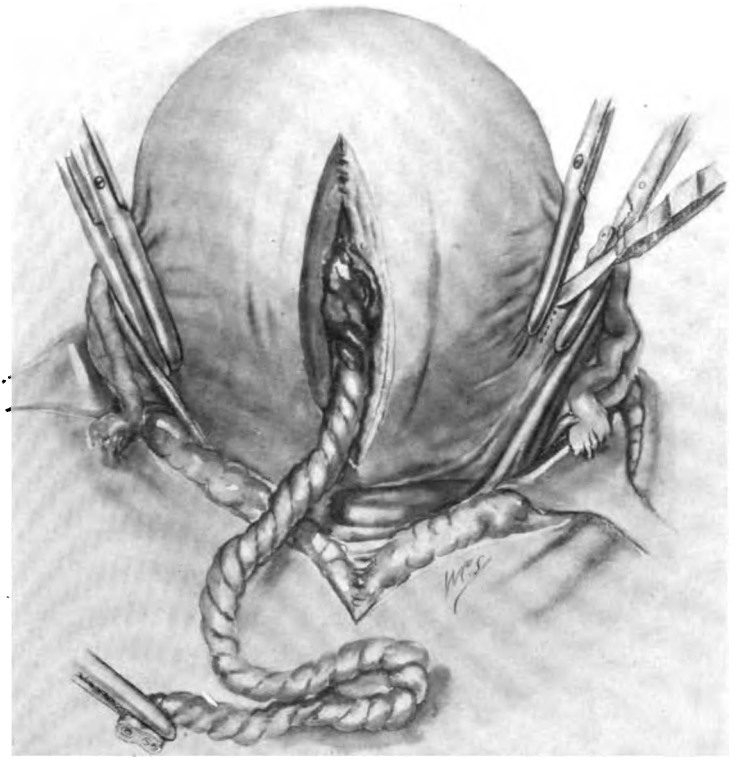

FIG. 184. PORRO CÆSAREAN SECTION. The upper half of the broad ligaments clamped.

isolate the uterine arteries, as is done in gynæcologic hysterectomies. After both broad ligaments are clamped and the uterus freed, the latter is pulled sharply forward over the pubis and cut off, beginning from behind, just above the vaginal insertion, the point being determined by palpation. It is wise to cut carefully because of the softness of the uterine tissue and its thinness near the bladder. I usually cut from the right be-

hind to the left in front, then strip the uterus from the bladder, if need be forming a new pedicle of the base of the right broad ligament, which is clamped and severed last. The ligaments are tied off under the clamps, using No. 2 hardened catgut. The large vessels are secured by separate individual ligatures. Before removing the clamps it is wise to secure

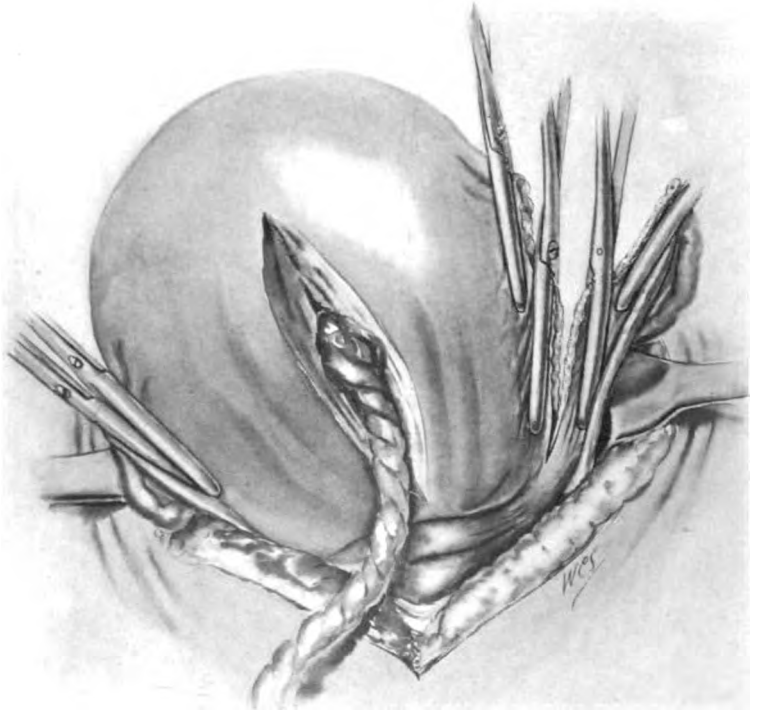

FIG. 185. PORRO CÆSAREAN SECTION. Clamps applied to the level of the uterine artery.

perfect hæmostasis, because oozing from the veins in the soft tissues may be exceedingly troublesome. A few through-and-through sutures in the stump may be required, but I usually apply them in such a manner as to turn the cut edges of the cervix against each other, leaving the cervical canal open for drainage. The peritoneum is sewed together after turning the ligated stumps in underneath it and uniting them to the cervical stump

with a few sutures. The round ligaments are to be securely fastened to the cervical stump, to prevent prolapse.

Michaelis, in 1809, recommended the removal of the whole uterus, and Bischoff, in 1880, first practiced it—in a case of cancer. The operation is much more formidable than the amputation of the fundus. The hæmorrhage from the cut vagina and bases of the broad ligaments is less easily controlled.

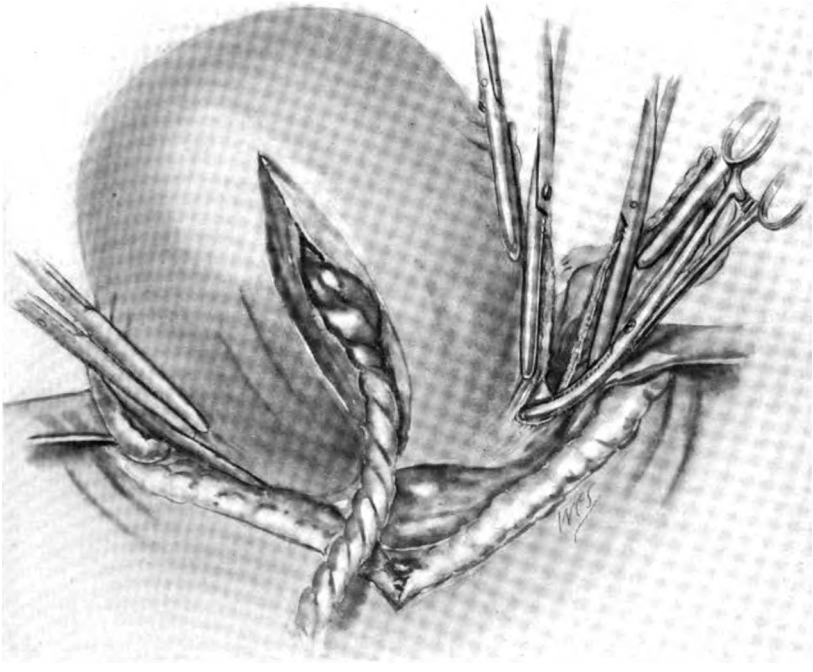

FIG. 186. · PORRO CÆSAREAN SECTION. The uterine artery clamped.

Cæsarean section, with amputation of the uterus in clean cases, and with an expert operator, has the same mortality as the conservative operation, and the morbidity is decidedly less. Recovery is prompter, less painful, and less complicated than after the ordinary cæsarean operation. The reason for this is the elimination of the large, involuting, really necrosing uterus, the clearing-out of the pelvis (less absorption), and the covering in of all raw surfaces by peritoneum. In septic cases the mortality is still high, probably near 20 per cent. It is a question if total

hysterectomy would improve the results. If, during cæsarean section in septic cases, the abdomen could be closed tightly around the unopened uterus and the latter emptied and amputated or amputated and emptied without soiling the peritoneal cavity, probably many cases of peritonitis

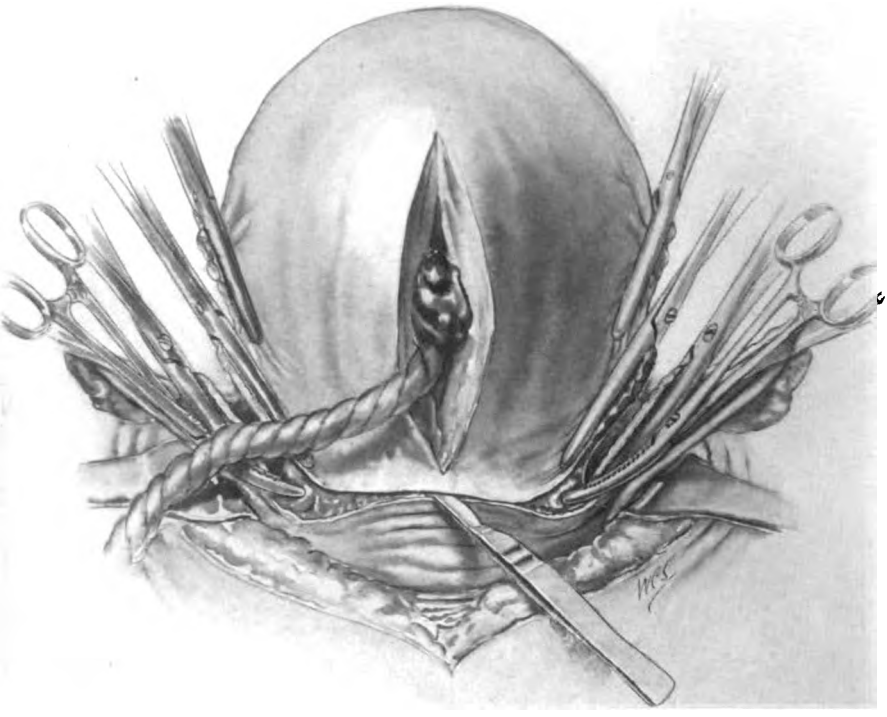

FIG. 187. PORRO CÆSAREAN SECTION. The anterior peritoneal cul-de-sac being opened.

could be prevented. With a studied technique such a result is not unattainable, having been done several times.

Sterilization with section. Should the woman be sterilized to prevent future pregnancies? Authorities differ between wide extremes, and in deciding, one must consider the dangers of subsequent pregnancies and labors, and the necessity for consecutive cæsarean sections should pregnancy again supervene.

If the woman has tuberculosis, heart disease, chronic nephritis, or any disease which in itself is a contra-indication to pregnancy, she should

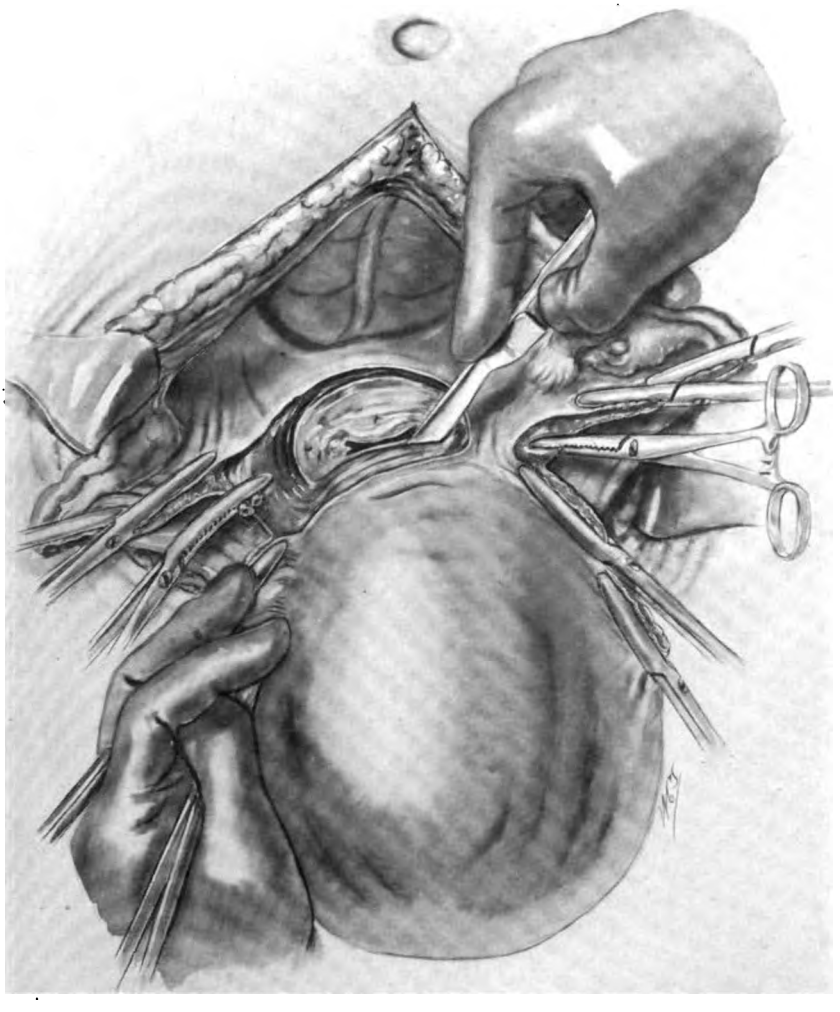

FIG. 188. PORRO CÆSAREAN SECTION. The fundus being pulled strongly over the pubis and cut off above the cervix.

be sterilized. Anyone who admits the propriety of inducing abortion for such conditions must admit the above postulate. Contracted pelvis is not included in this category.

The danger of rupture of the uterine cicatrix from previous section in subsequent labor is no indication, because we can avoid this by proper-

ly sewing the uterus, by placing the patient in a good maternity several weeks before labor, and operating before pains set in.

If the first section is done for eclampsia, placenta prævia, abruptio placentæ, prolapse of the cord, faulty mechanism of labor, or pelvic tumors (which are removable), in the absence of other indications, the woman should not be sterilized. If the woman has a large family, the

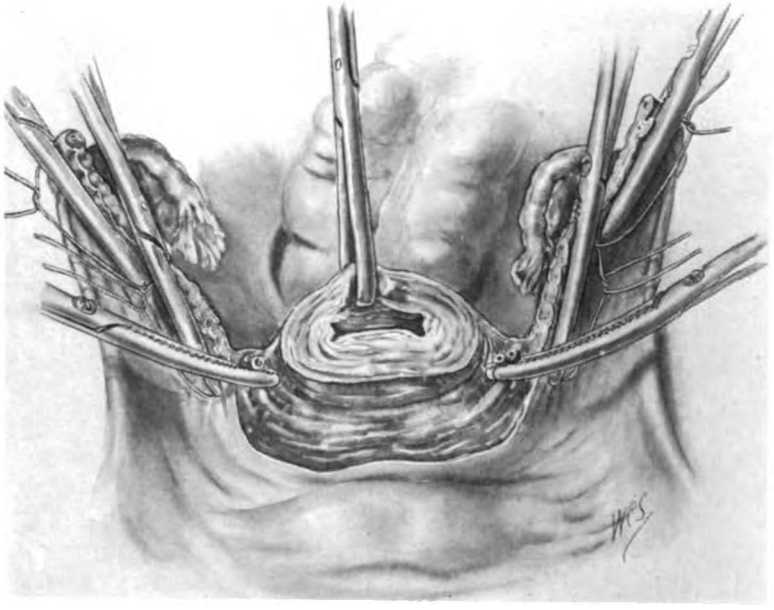

FIG. 189. PORRO CÆSAREAN SECTION. The stump being held by a volsellum while the broad ligament is ligated.

question may arise, but if there is only one child, and that one weak or deformed, it is better not to sterilize her.

If the cæsarean operation is done for contracted pelvis, I earnestly dissuade the patient from such a procedure at the first section, pointing out the fact of the safety of subsequent operations, the possibility of the death of the only child, and the unhappiness of a one-child family. At the second cæsarean I willingly sterilize, if requested, although lately, since the mortality has been so greatly reduced, I often suggest a third operation. At operation one may reverse the intention to sterilize, if the child is not of the desired sex, or if it is asphyxiated and of doubtful recovery.

For many years the ethics of sterilization have been debated. Most American, English, and Continental authors concede the right of decision to the mother and her family, after they have been given a fair presentation of all the facts, a position which I also take.

Methods. Ligation, simple section or exsection of a portion of the tube, as recommended by Blundell in 1819, have proved insufficient,

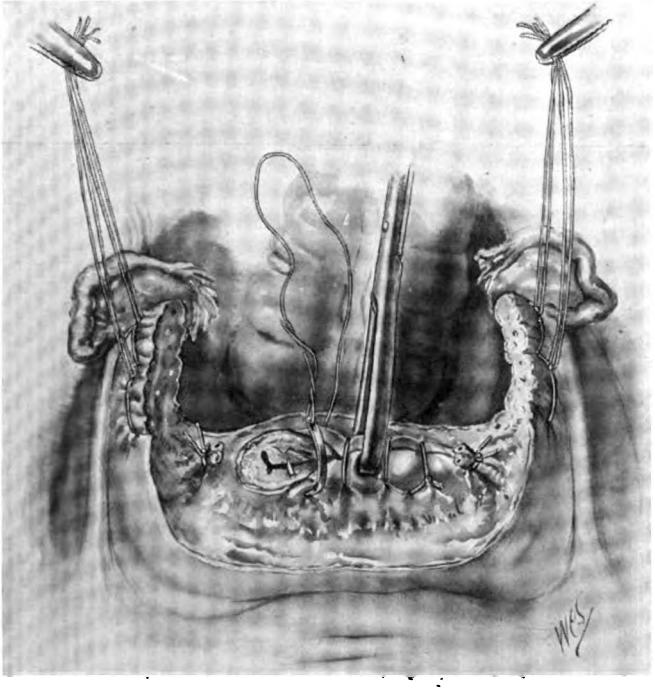

FIG. 190. PORRO CÆSAREAN SECTION. Closure of the cervical stump.

pregnancy having occurred in spite of them. In osteomalacia ovariotomy is done. Ablation of the tubes is safe, as is also removal of wedge-shaped pieces of the uterine horn containing the tubes. The method I use is exsection of an inch of the tube near the uterus with burial of both ends under the peritoneum of the broad ligament (Fig. 192). The peritoneum may be slit open and an inch of the tube itself removed, the gap being filled up by the connective tissue. It would be possible, should pregnancy be later desired, to re-open the belly by anterior colpotomy and anastomose the cut ends again. Extirpation of the uterus as a

means of simple sterilization is hardly to be recommended, certainly not in young women. The desire to have all the functions of a woman is strong, and seldom do the patients not regret the loss of the menses. I agree with Williams that hysterectomy can be done in the same time as removal of the tubes, and that the postoperative recovery is prompter and more satisfactory than in the conservative cæsarean section, but the technical difficulties are greater with amputation of the uterus, and premature menopause is not rare, even if one or both ovaries are preserved.

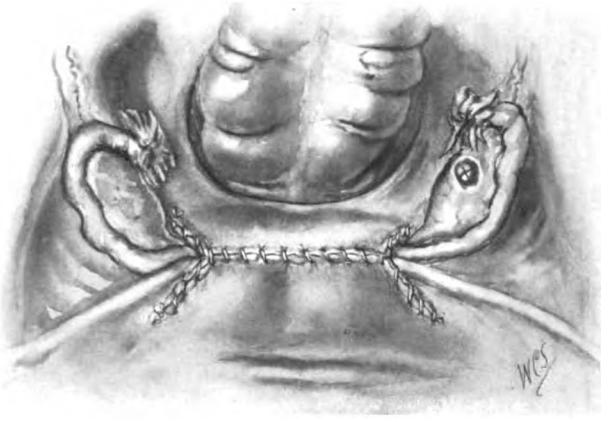

FIG. 191. PORRO CÆSAREAN SECTION. Peritoneal closure after the ligaments and tubes have been securely united to the cervical stump.

SUPRASYMPHYSEAL CERVICAL CÆSAREAN SECTION

There are many disadvantages to the classic, corporeal cæsarean section, and, since the greatest dangers came from the fact that the peritoneum is opened, the old accoucheurs sought to avoid this necessity and tried to extract the child from beneath the peritoneum. The first suggestion came from Joerg in 1809, and Ritgen performed the operation in 1821. Physick, of Philadelphia, in 1824, recommended this method to Dewees, of Philadelphia, but I could not find that Dewees had performed it. Joerg had suggested that the incision be made in the flank, and that the peritoneum be dissected upward in the manner preparatory to ligation of the internal iliac artery, the child then being extracted from the parturient canal. In 1870, T. Gaillard Thomas revived the operation,

which had been named "gastro-elytrotomy" by Baudelocque. Very few of these cases were successful because of the lack of asepsis, infection killing nearly all of the women.

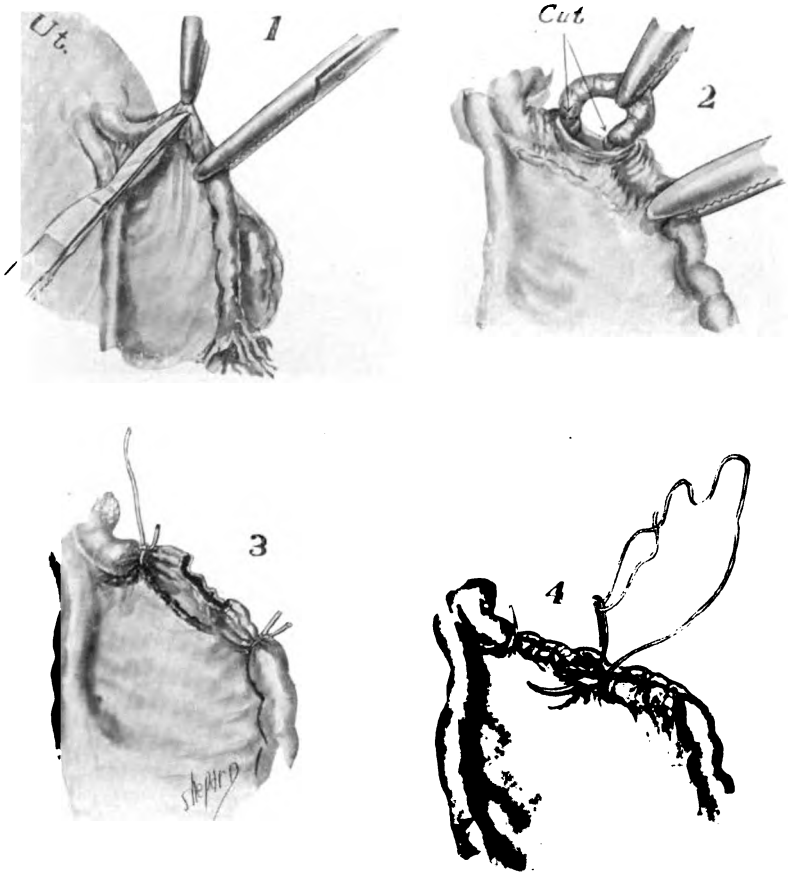

FIG. 192. METHOD OF EXSECTING THE TUBES.

Attempts to improve the classic cæsarean section, to make it adaptable to the neglected cases, failed until 1906, in which year Frank, of Bonn, disinterred the old extraperitoneal methods. He opened the abdomen just above the pubis, united the peritoneum of the uterus to the peritoneum of the abdominal wall, thus shutting off the general peritoneal cavity, and delivered the child through the almond-shaped space

provided. Later Sellheim attempted to push the peritoneum upward from off the bladder, as was recommended by Physick in 1824. This maneuver freed the space over the cervix and lower uterine segment, through which he delivered the child.

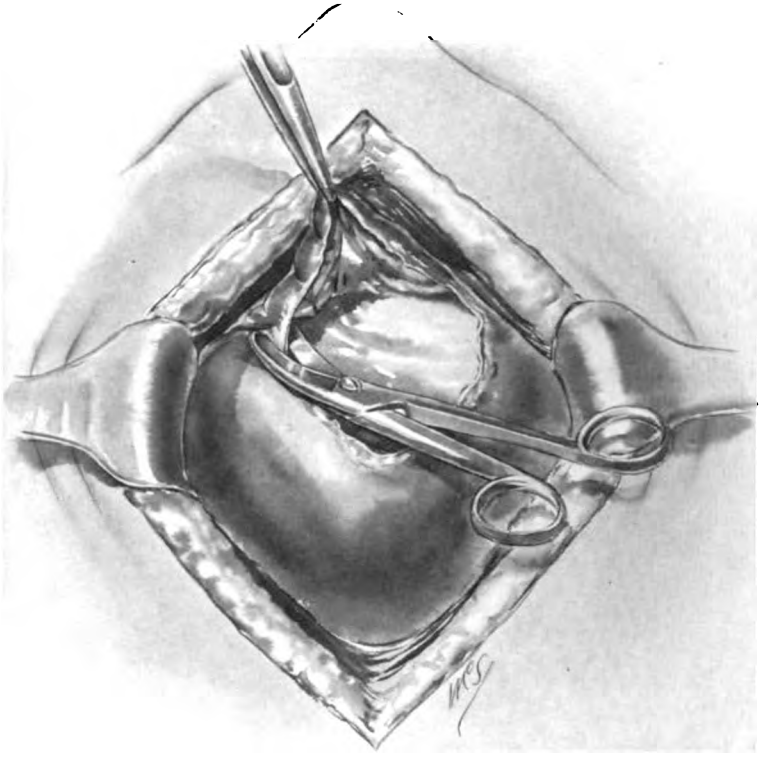

FIG. 193. CERVICAL CÆSAREAN SECTION; KRÖNIG'S OPERATION. With the patient in the Trendelenburg position a median incision is made from the pubis to about 2 inches below the navel. The exposed uterine wall is held against the angle of incision with volsellum forceps. The peritoneum is incised one inch above the attachment of the bladder to the uterus. The bladder is reflected from the uterine wall by blunt dissection.

Many operators, mostly German, developed these ideas, and now there are about twenty different procedures. All these methods of performing the operation depend on certain changes which occur during

pregnancy and labor in the relations of the cervix and lower segment to the bladder and vesical peritoneum.

Special anatomy. We know that during pregnancy the peritoneum over the lower uterine segment and bladder becomes very much softened and loosened from its base. It also hypertrophies under the

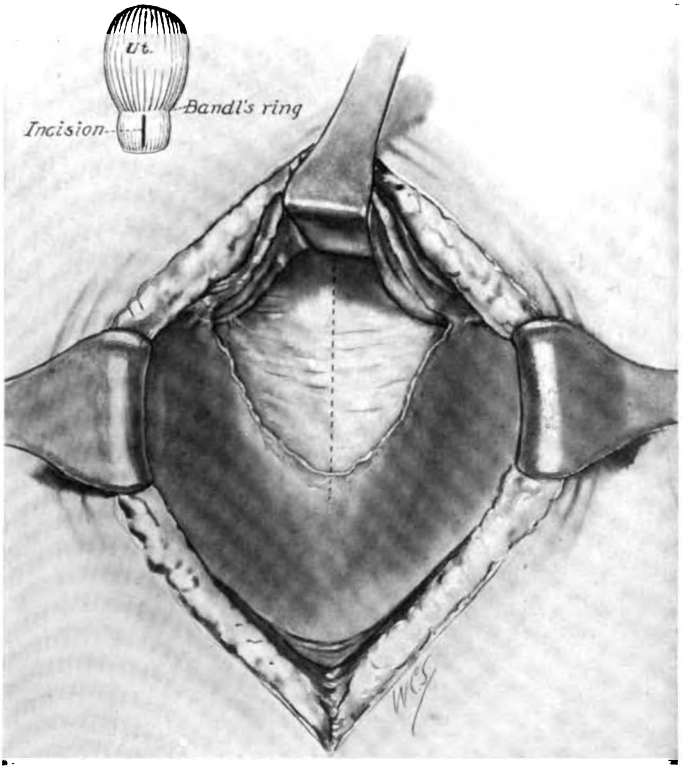

FIG. 194. CERVICAL CÆSAREAN SECTION; KRÖNIG'S OPERATION. The cervix is grasped near the bladder with a volsellum forceps, and an incision made large enough to admit one finger and the blade of a dull scissors. The incision is then continued upward to the line of peritoneal reflection. The visceral layer of the endopelvic fascia is incised, together with the muscle. The peritoneum covering the uterus may be sutured to the parietal peritoneum to avoid exposing the general peritoneal cavity.

stimulation of pregnancy. With the development of the lower uterine segment and cervix in the latter weeks of pregnancy, and particularly in labor, the muscle of the cervix is drawn upward and outward from the

bladder attachments. The vesico-uterine cul-de-sac is usually obliterated. The peritoneum is also drawn upward at the sides of the bladder in the neighborhood of the round ligaments. At the same time the mobility of the peritoneum on the subjacent structures becomes much increased. It is therefore possible, after incising this portion of the peritoneum, to

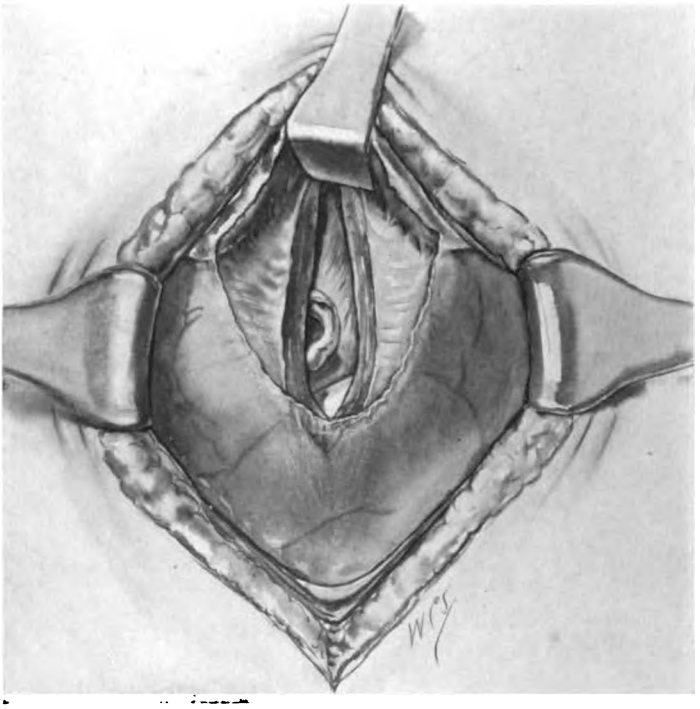

FIG. 195. CERVICAL CÆSAREAN SECTION; KRÖNIG'S OPERATION. The retractors are removed and the wound held open by the fingers of the assistant.

push the bladder off of its cervical attachments with great ease, and to expose an area of the cervix and lower uterine segment large enough for the delivery of the child without encroaching on that portion of the peritoneal cavity which is invaded in the classic cæsarean section. Of the twenty or more operations that have been invented, only two seem likely to obtain recognition.

All these methods may be divided into two classes: first, the transperitoneal or perperitoneal; and second, the extraperitoneal. In the transperitoneal operation, the abdomen is opened above the pubis and

the peritoneum over the cervix near the bladder is incised and loosened from its bed. By means of closely set continuous sutures, or by clamps, the parietal and visceral peritoneal layers are united. Some operators omit this part and protect the general peritoneal cavity by packing sponges around the uterus. In clean cases no more is necessary. The

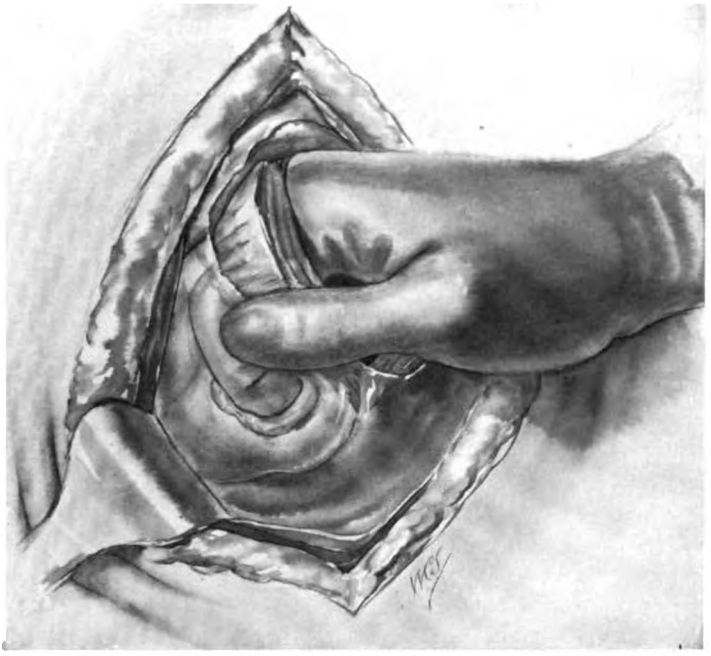

FIG. 196. CERVICAL CÆSAREAN SECTION; KRÖNIG'S OPERATION. A finger in the mouth pulls the face to the front; the head may be steadied by a volsellum forceps attached to the scalp, or it may be squeezed out by pressure from the fundus, as in Kristeller's method.

lower uterine segment and cervix are incised, the child and placenta are delivered, the uterus is closed, and the double layer of the peritoneum is reunited. The general peritoneal cavity is thus temporarily removed from the field of operation, and infectious material, such as meconium, liquor amnii, and blood, are not permitted to spread over it. Some operators cut the line of temporary peritoneal sutures, and reunite the individual layers of peritoneum. Others do not do this, but sew the two layers together. Sellheim sews the uterine wall to the skin and leaves the wound open to drain. He calls this a delivery through an utero-

abdominal fistula. Among the transperitoneal cæsarean sections, that devised by Krönig and modified by Gellhorn, of St. Louis, seems to possess most advantages and is used in suspect cases. Of the extra-peritoneal methods, that of Latzko is the best. In Latzko's operation the

FIG. 197. CERVICAL CÆSAREAN SECTION; KRÖNIG'S OPERATION. The forceps are applied with the front directed toward the pubis. Slow delivery prevents tearing into the bladder or ureter. The placenta is delivered by Credé's method or manually.

incision is made either transversely or longitudinally, just above the pubis. The peritoneum is pulled out of the pelvis, the bladder is pushed off the cervix to the right; and beneath the vesico-uterine fold which has been pushed up toward the navel, a bare space of cervix and lower uterine segment is provided, through which the child is delivered.

Full descriptive legends have been put under the illustrations showing the steps of the operation and the reader is referred to them for the details (Figs. 193–205).

The indications. From the descriptions given above it is evident that two new operations have been added to our armamentarium. Both have this in common, the lower or cervical zone of the uterus is opened

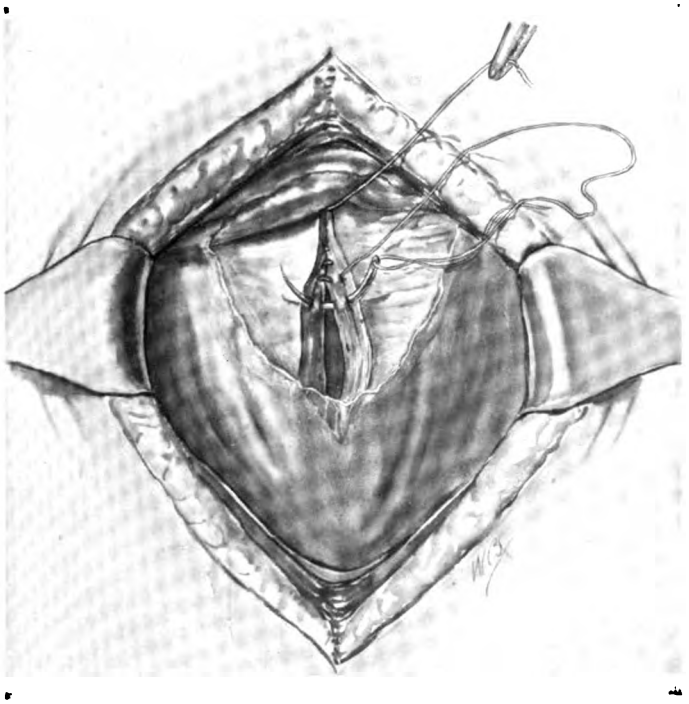

FIG. 198. CERVICAL CÆSAREAN SECTION; KRÖNIG'S OPERATION. The edges of the incision are pulled up with volsellum forceps so that the deepest corner of the wound is accessible. The muscle is closed with two rows of sutures.

for delivery of the child, whereas, in the old, the classic operation, the corpus or fundus uteri is opened. We must hereafter speak, therefore, of cervical cæsarean section and corporeal or classic cæsarean section. Since there are two methods of cervical section, and each has its own indications and conditions, we have three distinct operations to consider when the question of abdominal delivery arises. It is not alone, "Shall we perform cæsarean section in this case?" but, "Given the indication for abdominal delivery, what kind of section shall we perform?"

The old teachers divided the indications for cæsarean section into absolute and relative: the absolute indication existed when there was no possibility of delivering the child through the natural passages, the way being blocked by a contracted pelvis, a neoplasm, scar tissue, etc.; or the child being a mammoth. The relative indication existed, when after carefully balancing all conditions, the accoucheur decided that the ab-

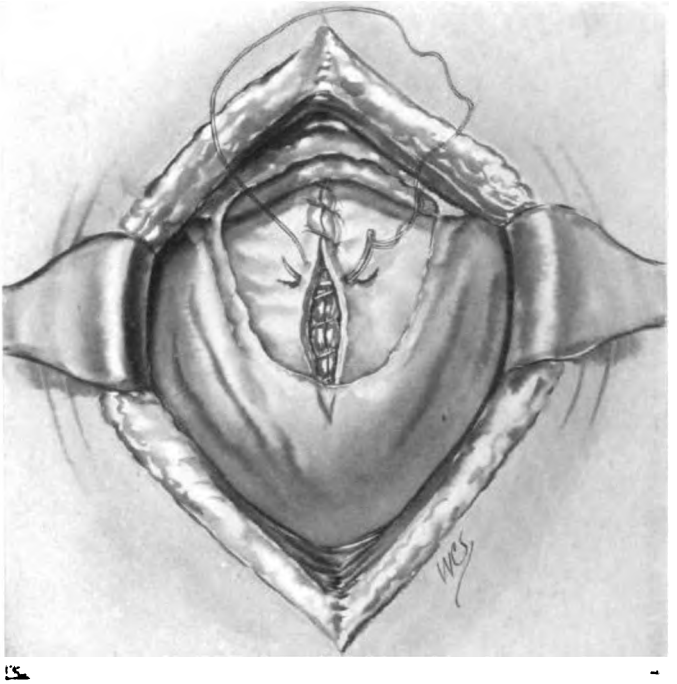

FIG. 199. CERVICAL CÆSAREAN SECTION; KRÖNIG'S OPERATION. Second row of uterine sutures. The visceral layer of the endopelvic fascia is united separately.

dominal delivery offered the best chances for mother and child. It was therefore almost wholly subjective, and it left a wide field for the play of individual preference, for the influence of isolated experience, and for the clash of contending statistics. Moderately contracted pelvis, placenta prævia, and eclampsia are the main so-called relative indications, but there is hardly a complication in obstetrics that has not been treated by cæsarean section. It has been done for the following: abruptio placentæ; prolapse of the cord; stenosis of the parturient canal from congenital deformity or acquired disease, or from encroachment by tumors

of neighboring organs,—such as fibroids, ovarian cysts, exostoses, cancer; in old primiparæ; for abnormal presentation of the fœtus,—breech, face, shoulder; for abnormal position such as occiput posterior; for threatened asphyxia of the child demanding instant delivery; for complications threatening the mother, such as heart disease, pulmonary hæmorrhage, cerebral hæmorrhage, generally weak constitution unequal

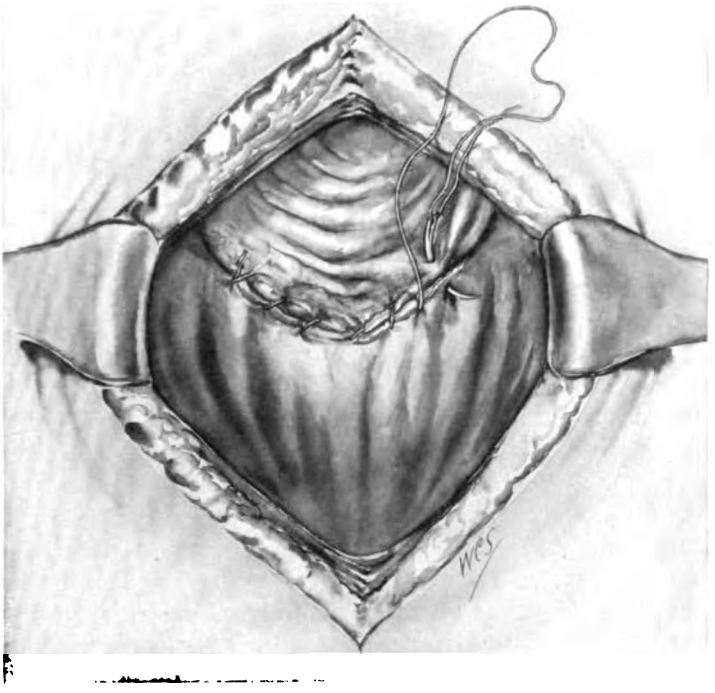

FIG. 200. CERVICAL CÆSAREAN SECTION; KRÖNIG'S OPERATION. With the table lowered the bladder peritoneum is stitched over the wound.

to the stress of labor; because of a previous section, under the dictum, "once a cæsarean always a cæsarean"; because of healed extensive plastic work on the genitalia; and in combinations of the conditions above mentioned. The writer does not subscribe to all these indications but he cannot discuss them for lack of space.

If the abdominal delivery is to be done for one of the above indications, when will the classic or corporeal and when the modern low or cervical operation be selected? Why not always the classic operation? There are five objections to it:

1. The mortality of the old operation, even in clean, non-toxic cases, is still, at the most conservative estimate, over 2 per cent. The mortality of the cervical section even when more than half of the cases are frankly infected or suspicious, is not over 2 per cent. Theoretically and practically there are many reasons why this should be so. The incision is made in the lower part of the uterus, which is known to resist infection well. The same may be said of the lower abdomen; it resists infection better than the upper. The uterine wound is at rest, lochia are not squeezed through it by the after-pains, and, furthermore, should a leak in the line of suture occur, the leakage would be under the peritoneum, between the bladder and the cervix, where it could be easily reached in three ways: by way of the vagina and cervix, between the cervix and the bladder—simple anterior colpotomy, or by opening the lower corner of the abdominal wound. Should infection wander along the line of suture, in the corporeal section it at once reaches the peritoneal cavity; in the cervical section it reaches a safer area, one more easily drained. Another element of safety in the cervical cæsarean section is the entire absence of any handling of the intestine. Often the intestine does not even come into view. Liquor amnii, vernix caseosa, and meconium do not soil the peritoneum.

2. The classic section must be limited to clean cases; the cervical enables us to expand the indication to cover those that have been to an extent neglected. We will in many cases obviate the necessity of craniotomy, and the greater safety of the cervical operation will allow us to perform the abdominal delivery under circumstances in which previously we may have desisted, as for example in eclampsia, breech presentation, or prolapse of the cord. Best of all we may give the parturient a thorough test of labor, lasting hours if need be, which is most unwise with the classic operation.

3. The general morbidity, fever, uterine abscess, and abdominal complications—shock, ileus, gastric dilatation, gas pains, tympany—are decidedly less, for reasons explained above. The feeling of well-being is most remarkable, and while it is the exception after the classic, it is the rule after the cervical cæsarean that the puerpera is comfortable.

4. Adhesions are almost always absent after the cervical, they are almost always present after the classic section. This has been the experience of all operators here as well as abroad. It is explained by the reasons advanced above and by the fact that the line of uterine suture in the finished operation is only about 2½ inches long, smooth and without catgut knots, and, when the bladder fills, is covered by this viscus. In the true extraperitoneal method (Latzko) the peritoneal cavity is not opened at all, and in the absence of infection, adhesions, ileus, etc., will

not occur. Adhesions are sometimes caused by seepage of lochia. This is impossible with the newer methods.

5. Rupture of the uterus in subsequent labor is a not infrequent ac-

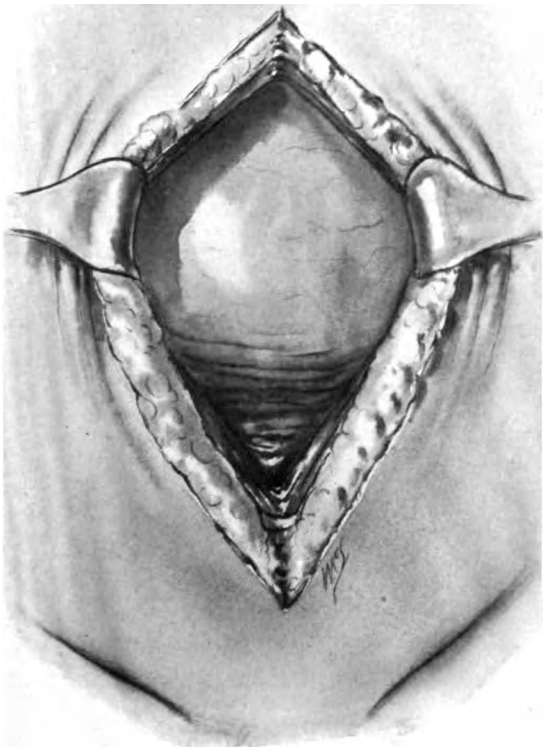

FIG. 201. EXTRAPERITONEAL CÆSAREAN SECTION; LATZKO'S OPERATION. With the patient in the Trendelenburg position the bladder is filled with 150 c.cm. of sterile water and the catheter clamped. The incision extends from the pubis to a point 2 inches below the navel, a finger's breadth to the left of the median line, down to the peritoneum. After the bladder is identified it is emptied through the catheter.

cident after the old cæsarean section. There are only two cases on record of rupture following the new methods, and in both the cut had been extended into the body of the uterus. Immunity from rupture is a strong point in favor of the low incision. Experience with vaginal

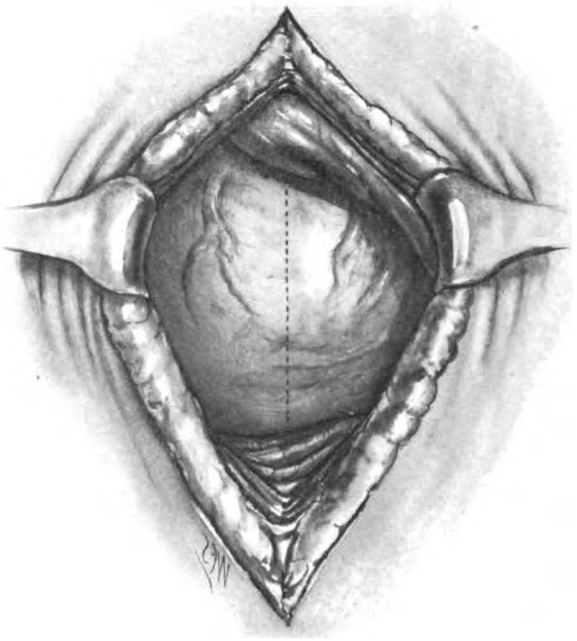

FIG. 202. EXTRAPERITONEAL CÆSAREAN SECTION; LATZKO'S OPERATION. The vesico-uterine plica is pushed upward and medially, while the bladder is pushed downward and to the right of the lower uterine segment. The denudation should not extend too far laterally, lest the large vessels and ureters be injured.

cæsarean section in which the scar is in the same part of the uterus is confirmatory. The freedom from danger of subsequent rupture is easily understood. When the cut is made in the body of the uterus the wound surfaces are not at rest during the healing process. With each after-pain, the sides of the wound grind on each other, and even in the absence of infection are prone not to unite. When the cut is made in the

cervix, all this is absent. The wound is at perfect rest. When doing a section, therefore, in a young woman who will have more babies, the low operation is chosen. In an older woman or where the tubes are exsected (sterilization) this factor has not the same importance.

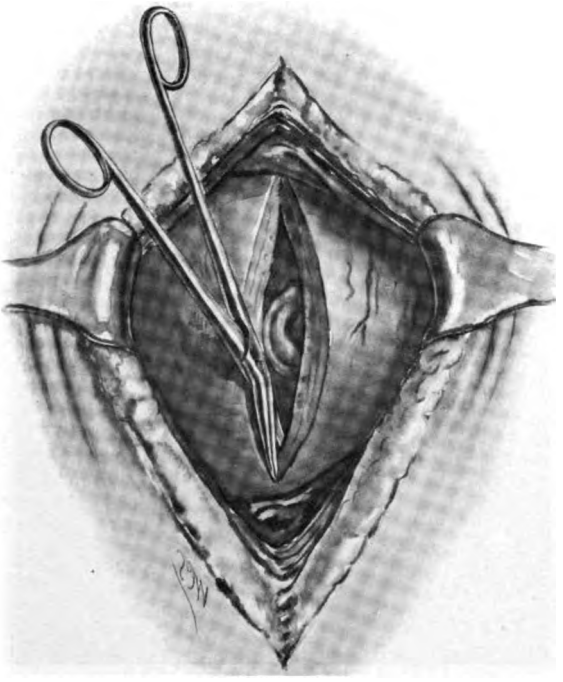

FIG. 203. EXTRAPERITONEAL CÆSAREAN SECTION; LATZKO'S OPERATION. Guided by the fingers, the thin lower uterine segment is incised.

In general, I must say that the more I do these newer operations, the better I like them, and now they are first thought of when the question of cæsarean section arises. For doing the old or classic cæsarean section, I have to have special indications, and these are, usually, the necessity for instant delivery, the desire to remove fibroids, the presence of a placenta prævia, of extreme obesity, or of an extremely pendulous abdomen. If a Porro operation is to follow, the classic operation is indicated. Experience may prove it possible to omit some of these exceptions.

The choice between extraperitoneal and transperitoneal methods is still undecided, but the majority of operators prefer the latter. The true extraperitoneal operation has the distinct advantage that it protects best against peritonitis; and infection, if it occurs, is less dangerous in the connective tissue and more easily drained. Its disadvantages are that

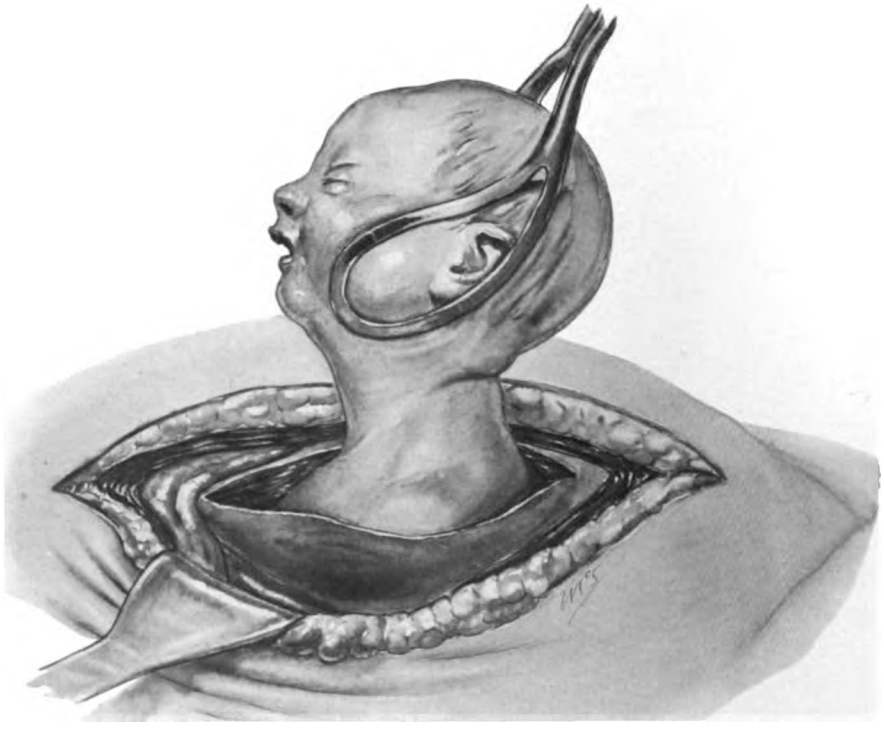

FIG. 204. EXTRAPERITONEAL CÆSAREAN SECTION; LATZKO'S OPERATION. With the table horizontal, the head is pulled into position for forceps by means of a finger in the mouth, or it is steadied by a volsellum fastened to the occiput. Sometimes simple Kristeller expression suffices. The placenta may be removed manually or expressed by Credé's method.

it is hard to separate the peritoneum and the bladder from the uterus, so that the peritoneum often and the bladder occasionally tear through. The uterine incision sometimes tears into the base of the broad ligament where the large veins and ureter lie. The delivery of the child is tech-

nically more difficult and its mortality slightly higher. For these reasons and further, since the results for the mother are almost as good, the transperitoneal operation is most often selected.

Indications for cæsarean section. Which method of abdominal delivery should be selected to fit the individual case?

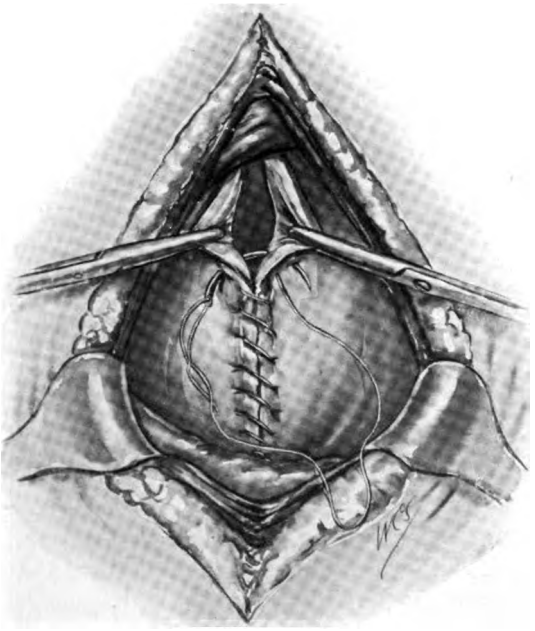

FIG. 205. EXTRAPERITONEAL CÆSAREAN SECTION; LATZKO'S OPERATION. The uterus is closed with two rows of sutures. The subperitoneal fascia is united, the peritoneum drawn downward and the bladder brought into position. A rubber-covered gauze drain is left in the lowest corner of the abdominal wound.

In the presence of insuperable mechanical disproportion, that is, the absolute indication for cæsarean section, the older obstetricians could only do a therapeutic abortion, or the classic cæsarean section at term. If the dystocia was experienced only after infection was present or suspected, a Porro or complete uterine extirpation was demanded, if the life of the woman was not to be forfeited.

Nowadays we may proceed differently. Therapeutic abortion is ab-

solutely contra-indicated. At full term we have four courses to select from: the classic cæsarean section, the classic cæsarean section with the Porro modification, the transperitoneal cervical section, and the extraperitoneal section. In clean and suspect cases I recommend the transperitoneal cervical section, and in frankly infected cases, the extraperitoneal section or the Porro cæsarean section.

In the treatment of labor in pelves that are not absolutely contracted, my plan has become more simplified in recent years. Unless the patient positively demands the induction of premature labor, I do not do it, but I allow the pregnancy to go to term and into labor. If it appears highly improbable that the head will pass, I do the transperitoneal cæsarean section as soon as labor is well under way. If there is reason to believe that the head will go through, I give the patient a real test of labor. If delivery is impossible, in primiparæ I do the transperitoneal section; in multiparæ either this or pubiotomy, being guided by the individual conditions present. This statement holds also for cases in which infection is suspected. In frankly infected cases I still fear to perform an abdominal delivery, in spite of the wonderful results recorded by German operators. If such is necessary, I would recommend the extraperitoneal method with free drainage in young women, and uterine extirpation in old. Williams recommends the Porro operation to meet this emergency. It is just in these neglected cases that the extraperitoneal method is the easiest of performance. The prolonged action of the pains has drawn the lower uterine segment out, pulling the uterovesical fold of the peritoneum high up away from the bladder, and giving a large area for incision and the extraction of the child. However, in frankly infected cases craniotomy is still to be held in reserve, since the child is almost always doomed anyway.

When cæsarean section is done for eclampsia, the cervical operation should be chosen—certainly in young women who will have subsequent deliveries. Before the eighth month of pregnancy, vaginal hysterotomy is permissible and preferred by some accoucheurs. Both deliveries may be performed under local anæsthesia, aided by a little nitrous oxide and oxygen.

In placenta prævia the classic cæsarean is usually preferred, as the immense vascularity of the cervical placental site creates great technical difficulties. I have done two cervical sections with placenta prævia. In abruptio placentæ, the cervical method is preferred unless minutes count in saving the life of the child. For abnormal presentations, attitude and position of the child, shoulder, breech, prolapse of the cord, etc., the cervical method is chosen. In heart disease, one usually exsects the tubes after cæsarean, and as the cases are usually aseptic, the classic

operation is selected; especially, too, since we often use local anæsthesia in such cases, and while this procedure is practical for the cervical, it is more successful with the corporeal operation.

The conditions for all the forms of cæsarean section have been referred to incidentally above, but it is always necessary to assure oneself before operating that the child is alive and viable (except under the absolute indication), that it is not a monster, as shown by X-ray examination, and that the patient is in condition to survive the operation. The latter is especially necessary in the presence of kidney, lung, heart, and general diseases. The cervix must be patulous enough to allow the lochia to escape. If there is cicatricial stenosis of a sufficient degree to prevent this, a Porro operation is needed. Under normal conditions the cervix will open itself sufficiently for drainage.

SECTION XIII

THE SURGICAL TREATMENT OF PUERPERAL INFECTIONS

BY

PALMER FINDLEY, B.Sc., M.D., F.A.C.S.

Omaha, Nebraska

CHAPTER I

THE SURGICAL TREATMENT OF PUERPERAL INFECTIONS

It is by no means easy to estimate the value of any form of treatment of puerperal infection, because in no case is it possible, in the early stages, to predict the course of the disease—whether it will be of long or short duration, whether it will terminate spontaneously, or whether it will proceed to a protracted and grave, if not fatal, condition. Can a local infection be checked in its progress by surgical means so that contiguous structures will not be invaded by the infecting micro-organisms? Can a toxæmia or bacteræmia be averted by the timely removal of the primary focus of infection? Clinical observations and a perusal of the literature convince one that these problems can only be solved by more extended clinical and laboratory observations.

To what extent the course of puerperal infection can be controlled by surgical means is a most difficult question to answer. Where the disease is sharply localized, as in the presence of decomposed placental tissue or a well defined inflammatory exudate, it would appear that surgery could be invoked with reasonable assurance of success. But it must be borne in mind that even in these cases there are grave hazards and much uncertainty as to the outcome. In the more severe forms where the lymph and blood streams have been invaded, where there is a progressive involvement of the veins or peritoneum, and where septic emboli have been deposited in remote parts of the body the problem is indeed baffling. In such severe types of infection one cannot be certain of the indications for operation.

If one is to apply operative measures intelligently, he must know the nature of the infecting micro-organism, and the limit to which the infection has extended. Were this all that is required, I believe that the surgical treatment of puerperal sepsis would be readily placed upon an intelligent, rational basis; but the problem is more difficult, and one which now seems unlikely of solution with our present methods for establishing a diagnosis and prognosis.

How is one to foresee the outcome of a given case with or without surgical intervention? A patient is treated along conservative non-operative lines, and dies. Could she have been saved by timely surgical intervention? We resort to surgery and the patient lives. Would she have lived without operation? Perhaps death follows upon surgical interference. Did the operation contribute to the fatal issue or would the patient have died without operation?

It is a difficult task to formulate the indications for surgical interference in puerperal sepsis because the course of the morbid processes is often difficult of recognition, due to our lack of reliable clinical or bacteriological guides. At the onset of the infection we are unable to foresee the ultimate course of the disease. If we adopt tentative, conservative measures the infection may go beyond our control; if we resort to radical measures at the very onset of the infection, we may, perchance, hasten a fatal issue, or we may have reason later to reflect upon our act as a questionable procedure—a sacrifice that might have been averted had we proceeded with more deliberation.

It is true that adequate laboratory facilities will reinforce our clinical observations so that we can determine with a fair degree of certainty, and at an early date, whether we have to do with an infecting germ of low virulence or of high virulence, and whether the infection is localized or has gained access to the general circulation. These facts are of the utmost importance and will often serve to determine the prognosis and course of treatment with a fair degree of certainty. Yet with all these facilities at our command we are often in doubt as to the proper course to pursue in the early stages of the infection.

The streptococcus has long been regarded not only as the organism most commonly found in puerperal sepsis (in 86 per cent of all cases according to Zangemeister), but as by far the most virulent. The observations of Fromme, Veit, Bumm, Heynemann, Gonnet, Mayer, Barsch, Zangemeister, and others have given us a clearer insight into the nature of the streptococcus as found in the genital tract and blood. Streptococci are found in the lochia of the normal puerperium but they are of low virulence. Zangemeister found streptococci in the vagina in 32 per cent of cases of pregnancy, and by the fourth day in 76 per cent of normal puerperæ. It is, therefore, evident that the mere presence of streptococci in the vaginal secretions is of no special significance in relation to puerperal sepsis.

It is known that non-hæmolytic streptococci rarely cause severe sepsis and that hæmolytic streptococci commonly produce not only a more or less extensive local infection but a general sepsis as well. It is further known that hæmolytic streptococci show great variations in their degree of virulence. They have been found in the vagina during normal pregnancy, and during the normal puerperium in a small percentage of cases. It has long been an accepted theory that germs found in the blood indicate a grave prognosis. Bumm, however, has observed bacteræmias in which recovery was rapid after removing the primary focus, and Barsch (*Zentralbl. für Gynäk.*, 1909, xxviii, 963) has shown that fatal sepsis may result in the absence of bacteræmia. Hence it follows that

a bacteræmia is not necessarily fatal, that the micro-organisms within the blood may be of low virulence.

Unfortunately we do not know why it is that micro-organisms vary so in their virulence; whether the cause rests with the germs themselves or with their environment. Hence, it follows that with our present state of knowledge we are not in command of methods which will serve as infallible guides for our management of these cases.

If we find hæmolytic streptococci in the lochia at the onset of an infection, we fear the development of a general sepsis, and by repeated blood examinations we are able to determine the prognosis; but we cannot in any case say at the onset that these hæmolytic bacteria will or will not invade the blood, hence we cannot be certain as to the advisability of removing the uterus as a means of preventing a general infection. Yet, if good is to come from the removal of the uterus, or from the ligating of veins, or from the removal of infected placental rests, surgery must be invoked prior to the development of a blood infection.

We know that non-hæmolytic streptococci commonly give rise to mild forms of sepsis, while hæmolytic streptococci give rise to both mild and severe forms of sepsis, the extent of which depends upon the number of micro-organisms, their degree of virulence and the tissue-resistance of the individual. In the severe types of sepsis we have to do almost exclusively with hæmolytic bacteria. We may be assured that the finding of hæmolytic streptococci in the blood calls for a guarded, though not necessarily hopeless prognosis, since the mortality of hæmolytic streptococcæmia is from 80 to 90 per cent.

OPERATIONS FOR PUERPERAL SEPSIS

Much confusion has of late been injected into the discussion of this subject. Formerly it was generally accepted that all products of conception together with blood coagula should be removed from the uterus at the earliest possible time, both as a means of preventing infection and of checking the progress of infection in its earliest stages. Under the leadership of Winter came the advocates of nonintervention in all cases of retained secundines. They argued against interference in the acute stages on the grounds that much harm may result from interference, that retained fragments of placenta rarely lead to severe infection and hence should await spontaneous expulsion.

Curettage. Authorities still do not agree upon the advisability of removing retained placental tissue prior to the development of septic infection. Winter counsels delay and the administration of ergot. He argues that the spontaneous expulsion of placental rests is less likely to

be followed by the development and spread of infection than is the artificial removal. Mayor takes issue with Winter, and I believe he voices the opinion of the profession at large. He would remove placental rests with the least possible injury to the uterus and at the earliest possible

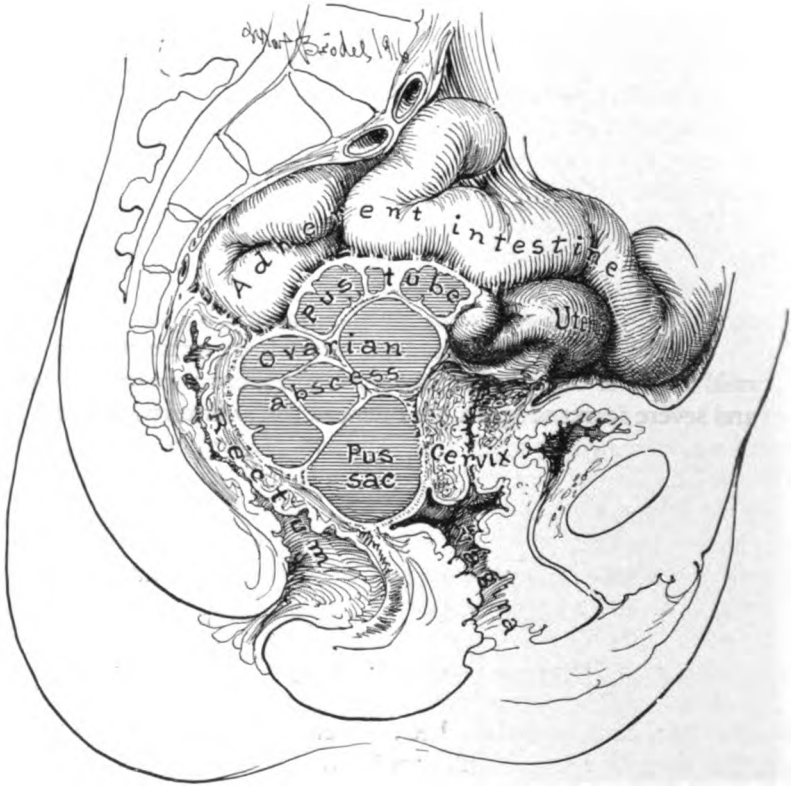

FIG. 206. GENERALIZED SUPPURATIVE INFLAMMATION OF THE PELVIS. (*Cullen.*) The tube on the right is filled with pus, the ovary contains several abscesses, and between the ovary and pelvic floor is a purulent accumulation. Anteriorly the purulent mass is adherent to the uterus, posteriorly to the rectum, and above to the bowel and omentum.

moment, believing that placental remains may harbor saprophytes which in time may become virulent.

Curettage of the infected uterus is universally condemned. It is generally conceded that a thorough curettage of the puerperal uterus is a difficult and dangerous task. "The curette is blind" and is capable of

much mischief in the hands of the skilled as well as the novice. In the presence of virulent streptococci the danger is greatest, because the inevitable wounds created by the curette will almost certainly be infected

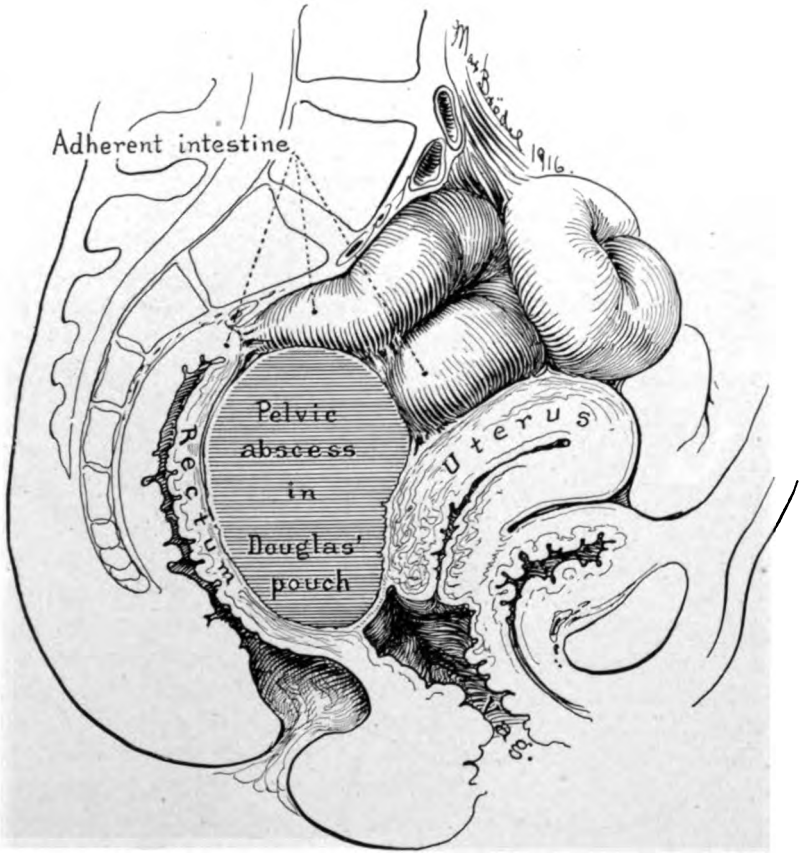

FIG. 207. PELVIC ABSCESS. (*Cullen.*) This abscess filled the pelvis and bulged into the vagina. Such an abscess may encroach markedly on the rectum.

and followed by an extension of the infection to the uterine musculature, the pelvic connective tissue, the appendages, the peritoneum, and the general circulation.

As a substitute for the curette in the removal of infected placental tissue the fingers should be employed, aided, if necessary, by the cautious use of placental forceps or a gauze swab. Under no circumstances should the uterus be irrigated, for fear of spreading the infection.

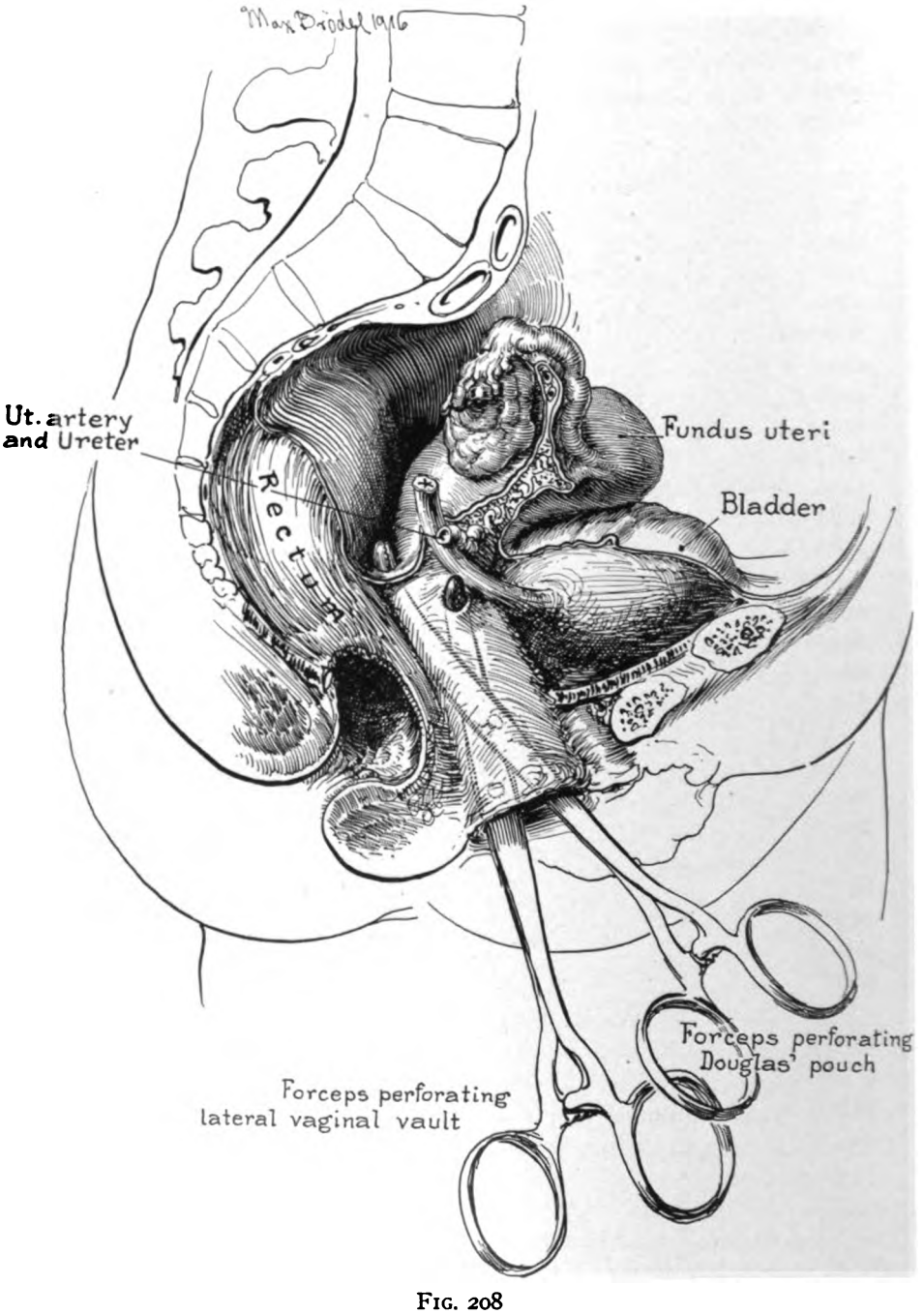
Ut. artery
and Ureter
Rectum
Fundus uteri
Bladder
Forceps perforating
Douglas' pouch
Forceps perforating
lateral vaginal vault

FIG. 208

Hysterectomy. Extirpation of the uterus has been practised in well-selected cases. Mayer would remove the uterus, first when it is the primary focus of infection, and, secondly, when the infection is confined to the uterus.

It is one thing to determine the original focus of infection, and another and more difficult task to determine the extent of the infection. We may readily decide that the endometrium is involved, but to say with absolute certainty whether or not the infection has invaded the musculature of the uterus or the para-uterine tissue is impossible in the early stages—a time when such knowledge would be of the greatest benefit. We must confess that as yet we have no certain means of determining the exact limitations of an infection. The clinical signs cannot be relied upon and, since it is a physical impossibility to take cultures from the deeper-lying tissues, we are at a loss to formulate a plan of action that will insure success in the early management of these cases. Shall we adopt the practice of early extirpation of the uterus in all cases in which there is a virulent streptococcic infection in the uterus, but as yet not in the blood? If we do so there will be many needless sacrifices, for many such cases go on to recovery without such heroic measures and, furthermore, there is the chance of spreading the infection through fresh wounds created in the operation. On the other hand, if we are to wait until it is known that the infection has spread beyond the uterus, the removal of the primary focus will be of little or no avail.

Hysterectomy in puerperal infection was first performed by Schultze. Hegar followed him with another case. Both cases died. America, and then France, adopted the operation, but in all three countries there has been little practice and much discussion of the subject. All agree that the infected uterus should be removed when possible where it has been perforated or torn, where sloughing fibroids are inaccessible to myomectomy, where multiple abscesses are recognized in the uterine wall, and where the infected placenta cannot be removed through the natural channel.

Where the infected uterus demands removal vaginal hysterectomy is the operation of choice.

Drainage of pelvic abscess. Accumulations of pus in the cul-de-sac or between the layers of the broad ligaments call for vaginal

---

FIG. 208. METHOD OF OPENING THE BROAD LIGAMENT FROM THE VAGINA. (*Cullen.*) The septum between the vagina and Douglas' pouch is so thin that the forceps will frequently pierce the peritoneum and enter the pelvic cavity. If the operator succeeds in entering the broad ligament without injuring the peritoneum his forceps come into intimate contact with the uterine artery and ureter.

drainage (Fig. 208). The vault of the vagina is exposed by means of a weighted speculum and two lateral retractors. The cervix is grasped by a volsellum forceps and forcibly brought forward and upward. The vaginal mucosa at its attachment to the posterior wall of the cervix is

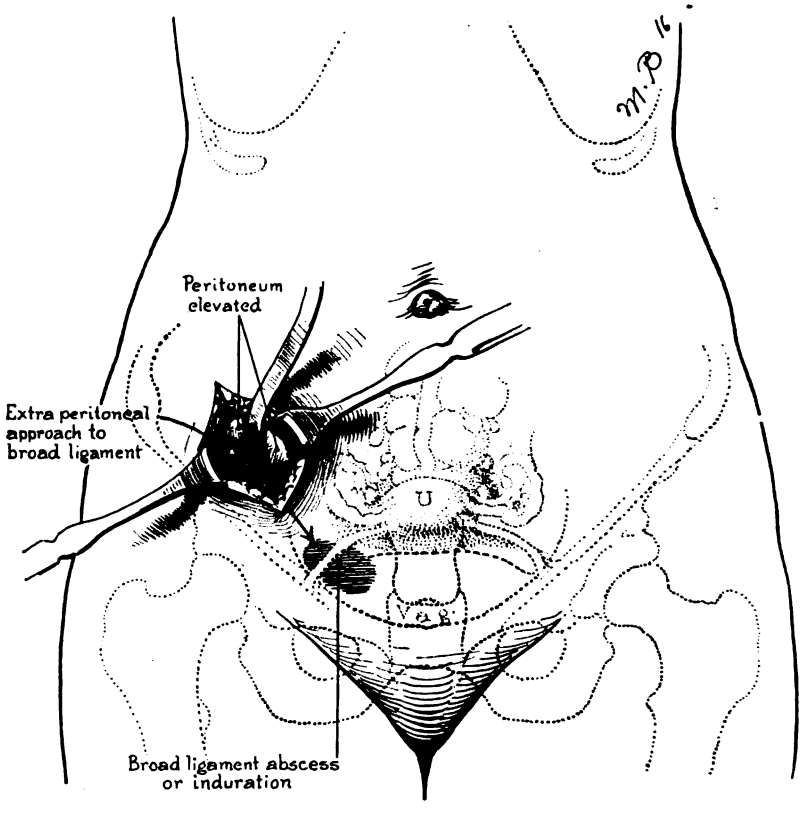

FIG. 209. THE ABDOMINAL APPROACH TO A BROAD LIGAMENT ABSCESS. (*Cullen.*) The abdomen is opened by a muscle-splitting incision above and parallel with Poupart's ligament. The peritoneum is pushed toward the median line without being opened. The two index fingers gradually spread the broad ligament until the area of induration is reached. A drain is carried down to the indurated area and the abdominal incision partially closed.

grasped with a pair of dissecting forceps, and a transverse incision about one inch in length is made close to the cervical attachment. This incision should be made with long blunt scissors. Having completed the incision through the mucosa, the finger or a long blunt forceps is forced through

the overlying tissues in the direction of the bulging mass. When pus is reached the incision may be stretched with the fingers to provide free drainage. Too vigorous exploration of the pelvis with fingers or instruments is dangerous. After gently exploring the abscess cavity, to determine as far as possible that no more abscess pockets exist, a rubber drainage tube is inserted and anchored to the margins of the incision by a catgut suture. In the place of a rubber drainage tube iodoform gauze strips may be inserted. Such strips of gauze may be removed in sections on the second, fourth, and sixth days. The abscess cavity should not be irrigated for fear of spreading the infection to the free peritoneal cavity. After operation the patient should be placed in the Fowler position.

Where the pelvic abscess does not lie low in the pelvis Cullen very wisely advocates a suprapubic extraperitoneal operation. A gridiron incision is made above and parallel to Poupart's ligament on one or both sides (Fig. 209). Upon reaching the peritoneum the folds of the broad ligament are spread with the fingers to the point of induration. When the pus is found a cigarette drain is inserted.

PYÆMIA

Puerperal pyæmia is the most serious affection of the puerperium. The clinical picture varies with the site and extent of the structures involved, with the virulence and numbers of the infecting micro-organisms, and finally with the tissue resistance of the host. In acute puerperal pyæmia chill follows upon chill, the temperature curve presents great fluctuations which mark the flooding of the circulation with micro-organisms or their toxins, the pulse becomes rapid and feeble, and finally great prostration develops. All this is the clinical expression of an infection starting, as a rule, at the placental site and traveling rapidly by way of the veins through the uterine wall, and thence to the broad ligaments, ovarian plexus, internal iliacs, common iliacs, downward to the femoral veins, and upward to the vena cava. Through the general circulation micro-organisms and infected emboli are carried to the lungs and elsewhere, and death almost certainly closes the scene.

In subacute and chronic cases days and even weeks may pass with no more than the local manifestations of a mild uterine infection, as suggested by altered lochia, pelvic tenderness, and slight rise of temperature. Even these symptoms may disappear for a time before the signs of a grave infection become manifest.

The frequency of puerperal thrombophlebitis is estimated at approximately from 30 to 55 per cent of all fatal cases of puerperal sepsis.

Trendelenburg found 22 instances in 43 autopsies, Lenhartz 32 in 60 fatal cases, and Kneise 27 in 89 autopsies.

The veins primarily involved are the uterine, and ovarian or spermatic. The uterine veins convey the blood from the upper portion of the vagina, cervix and the greater part of the body of the uterus, while the ovarian or spermatic veins convey the blood from the fundus of the uterus, tubes and ovaries. The uterine veins converge to form the hypogastric veins, which join the external iliac veins to form the common iliac vein.

Thrombi in these veins may suppurate and give rise to metastatic abscesses of the viscera. The lungs are the most frequent seat of the infected emboli arising from the pelvic veins. Less frequent lesions are ulcerative endocarditis, renal infection, gastro-intestinal infection, as well as infections of the brain and meninges, joints, retina, peritoneum, skin, and subcutaneous tissues.

The clinical course of puerperal thrombophlebitis is seldom acute. While the evidences of a local pelvic infection are usually found early in the course of the disease, it is the rule that characteristic symptoms do not develop prior to the second week of the puerperium. It may be that in the first week of the puerperium the clinical course does not vary from the normal, but, on the other hand, alarming symptoms of a general infection may follow closely upon labor. The symptoms are ushered in by a rigor, followed by a rapid elevation of temperature of from 103° to 106°F., and a corresponding increase in pulse rate. The temperature falls to normal or nearly normal but the pulse will usually continue at a relatively rapid rate.

Rigors are presumed to signal the entrance of micro-organisms or their toxins into the circulation. They are usually repeated at irregular intervals and may continue over a period of many weeks. Cases have been known to recover after from sixty to seventy chills. It is regarded as a hopeful sign when the rigors become less pronounced and recur at longer intervals. Having ceased to recur, recovery is usually speedy. As the disease progresses the pulse becomes weaker, more rapid and compressible. Nutrition fails rapidly, the face increases in pallor, and icterus may develop. Diarrhœa with offensive stools is often observed, but vomiting is unusual. The mind may remain clear to the end, but delirium may develop and deepen into a maniacal condition. Mahler says that great rapidity of the pulse speaks for a wide-spread thrombosis of the pelvic veins.

On examination of the pelvic organs there is usually found some evidence of infection. The uterus may be perfectly involuted, but is more often soft, enlarged, and somewhat tender to pressure. To one side

of the uterus it is often possible to palpate the thrombosed veins, which form an irregular elongated mass running from the uterus to the side of the pelvis. These findings are commonly unilateral. The presence of tenderness along the course of the femoral vein and œdema of the groin and thigh are not constant findings, but when present are of the highest significance.

Surgical treatment of pyæmia. For years the aural surgeons had been ligating the jugular vein to check the advance of infected thrombi when W. A. Freund, in 1897, ligated the spermatic veins of 2 cases of puerperal thrombophlebitis, but without success. Five years later Trendelenburg operated upon 5 cases with 1 recovery. His low percentage of recoveries can be accounted for by the fact that 4 of them were operated upon in the acute stage; the one operated upon twenty-six days after delivery recovered.

Bumm, in 1905, published his results in 5 cases of chronic pyæmia. Of this number 3 recovered. This report gave an impetus to the procedure. Since then Fromme, Cuff, Latzko, Whitridge Williams, Lenhartz, Opitz, Osterlow, Vineberg, Miller, Huggins, Findley, and others have reported cases.

Whitridge Williams operated upon 28 cases which he regarded as suitable. Of this number 6 died, a mortality of 21.4 per cent. There were 12 cases in which the thrombosis was limited to one or both spermatics, and only 1 of this number died. Huggins operated upon 4 cases with 1 death.

Osterlow reported 7 cases with 4 deaths, which he ascribes to too late operation. Latzko reported 37 cases operated for thrombophlebitis, of which number 14 recovered. Michels operated upon 3 cases with 2 recoveries. One of the fatal cases was operated upon in the presence of a general septicæmia. Michels collected 64 operated cases in the literature of which number 29 recovered.

We are admonished not to operate in the acute stage of the infection. In the acute stage of the infection there is great danger of spreading the infection, and at such times the low resistance of the patient would render such an operation extremely hazardous. In the acute stage the mortality is not less than 75 per cent, as compared with a mortality of 38 or 40 per cent in the chronic stage. It may be fairly stated that the mortality of chronic pyæmia has been lowered fully 10 per cent by the timely ligation of infected veins.

Contra-indications to operative interference. Operation is clearly contra-indicated where metastatic abscesses are recognized, where pus has accumulated in the pelvis, and where there are distinct evidences of lymphatic invasion.

Pneumonia and endocarditis are considered as contra-indications to the operation, while pleurisy and lung infarcts do not necessarily contra-indicate operative interference. Where there is marked œdema of the leg it is assumed that the common iliac vein is thrombosed; such cases are not looked upon as favorable for operation. Recovery is possible in the presence of bacteræmia and death may ensue in the absence of micro-organisms in the blood. It is the rule that the blood seldom contains a large number of germs and that these are not constant in their presence. Hence it follows that blood findings are of little value in determining the prognosis or the question of operative interference.

Technique of operation. The thrombosed veins have been approached by three routes, the vaginal, the extraperitoneal, and the intraperitoneal. The first and second procedures have not been generally adopted for the reason that the veins in either side of the pelvis and higher up in the abdomen cannot be under direct inspection.

In the intraperitoneal operation the abdomen is opened in the median line. The uterus and its appendages are inspected. The broad ligaments are inspected and palpated with special reference to the course of the uterine and ovarian veins. If the broad ligaments are found to be thickened along the course of these veins the existence of thrombosis is assumed. The veins are then palpated along their course to a point above the thrombus; here the peritoneum is incised and a ligature is passed about the veins by means of an aneurism needle. Ligation of the ovarian veins may be performed as high as the vena cava on the right side and as high as the point of union with the renal vein on the left side. When the internal iliac vein is involved it should be ligated near its juncture with the external iliac vein. If a median iliac vein exists this should be ligated at its juncture with the external iliac trunk. Lea recommends the ligature of both sides in every case because of the free anastomosis. The more acute the infection the more extensive the ligation. Care must be taken not to include the ureters and lumbosacral cord in the ligature.

SECTION XIV

RADIUM THERAPY

BY

FRANK EDWARD SIMPSON, A.B., M.D.

Clinical Professor of Dermatology, Northwestern University Medical School; Professor of Dermatology, Chicago Policlinic; Attending Dermatologist, Mercy, Wesley Memorial, Alexian Brothers and Henrotin Memorial Hospitals

CHAPTER I

RADIUM THERAPY

RADIUM is a chemical element belonging to the group of metals. It was discovered in 1898 by Professor and Madame Curie. Unlike most elements it is not absolutely stable, but is constantly, though very slowly, transforming itself into another substance known as radium emanation, or niton, a chemically inert gas. The change of radium into radium emanation goes on so slowly that it is estimated that about 1,730 years would be required for a given quantity of radium to diminish by one-half.

Unlike radium, radium emanation is very unstable and is transformed very quickly into a third substance, a solid, known as radium-A. The process of degeneration of radium emanation into radium-A is so rapid that the radium emanation diminishes by one-half in 3.85 days. Still further changes take place. Radium-A is rapidly changed into radium-B. Radium-B turns into radium-C, radium-C into radium-D, radium-D into radium-E, radium-E into radium-F (or polonium), while the end-product of the series of transformations is radium-G, a substance chemically indistinguishable from lead but having an atomic weight of 206. All these substances are solids except radium emanation which is a gas.

Radium-A, -B, and -C disintegrate very quickly so that they are diminished by one-half in 3 minutes, 26.7 minutes, and 19.5 minutes respectively. Radium-D, -E, and -F change more slowly, diminishing by one-half in 16.5 years, 5 days, and 136 days respectively.

The transformation of radium-C into radium-D is not quite so simple as we have indicated, inasmuch as a second substance known as radium-C_2 is formed, but for practical purposes the statement that the transformation takes place as stated above may be accepted.

Radium emanation and radio-active deposit. When a radium salt such as the sulphate is confined in a capillary glass tube or other container and the tube is sealed, it is evident that the emanation which is continuously forming cannot escape. Simultaneously with this process, which is going on, for all practical purposes, at an absolutely constant rate, the emanation confined in the tube is disintegrating as we have previously described. After a certain time the two processes equalize each other. In other words, the number of radium atoms disintegrating per second is equal to the number of emanation atoms disintegrating per

second. When this stage is reached the radium is said to be in equilibrium with its emanation.

When an atom of emanation breaks up in the tube, the atom of radium-A which is produced comes to rest on the wall of the tube or in the salt. The atom of radium-A in a few minutes becomes radium-B, and gradually the whole series of transformations previously described occurs. Radium-A and its successive products are solids; and, under the conditions of confinement in a small tube, the walls of the tube or any other material exposed to the emanation within the tube soon become coated with a thin invisible film of radium-A, radium-B, radium-C, etc. This coating or film is known as the radio-active deposit or simply the active deposit. As we have previously mentioned, radium-A, -B, and -C disintegrate very rapidly, while radium-D, -E, and -F decay much more slowly. Therefore the former group is known as the active deposit of rapid change, while the latter group constitutes the active deposit of slow change. In speaking of the active deposit we ordinarily refer to the former group.

As we shall have occasion to refer frequently to the quantity of emanation used in therapeutic applications we may here define the unit of emanation, viz., the curie. By this we mean the quantity of emanation in equilibrium with one gram of radium element. This term was adopted in honor of M. and Mme. Curie at the Congress of Radiology and Electricity at Brussels in 1910.

Since we are dealing therapeutically with relatively small quantities of emanation it is convenient to use in practice the term millicurie (symbol mc., equal to 1/1000 of a curie), which corresponds to the milligram of radium element. Another still smaller unit is the microcurie (symbol mcc., equal to 1/1,000,000 of a curie) corresponding to the microgram of radium element.

Another unit of concentration of radium emanation which has been used in the literature of the subject of internal radium therapy is the mache unit. Here it will suffice to say that a concentration of one microcurie per liter is equivalent to approximately 2,700 mache units.

Radio-activity. When we speak of a substance as being radio-active we mean that it gives off continuously certain peculiar rays which are invisible, but which are known to be present because of certain phenomena which they cause. The constant emission of these rays is known as radio-activity. While analogous to heat and light rays in many respects, these peculiar radiations from radio-active substances differ from them materially.

Among the interesting properties possessed by these radio-active rays is their power to ionize a gas, to affect a photographic plate in a manner

similar to light, to cause certain substances to become fluorescent in the dark, and most important of all from our present standpoint, to cause the modification or destruction of vital tissues exposed to their influence. We have already said that radium is constantly disintegrating to form a series of degeneration products. It is in consequence of and as a result of these processes of transformation that radio-active rays are given off. While radium itself is very weakly radio-active, certain of its degeneration products are very strongly so. The real source of the most penetrating radio-active rays is actually radium-B and -C and especially radium-C. Confined in a tube for therapeutic use, the only real function of radium itself and radium emanation is to produce radium-A, -B, and -C as fast as these latter disintegrate.

There are three different kinds of radio-active rays emitted by radium and its degeneration products. These are known as the alpha, beta, and gamma rays. The subjoined table will suffice to make clear the variety of rays that each of these substances emits.

Element	Radiation	Half Value Period
Radium	Alpha and Beta Rays	1730 years
↓		
Radium Emanation	Alpha Rays	3.85 days
↓		
Radium-A	Alpha Rays	3 minutes
↓		
Radium-B	Beta and Gamma Rays	26.7 minutes
↓		
Radium-C	Alpha, Beta, and Gamma Rays	19.5 minutes
↓ ↘ Radium-C_2	Beta Rays	1.4 minutes
Radium-D (Radio-lead)	Slow Beta Rays	16.5 years
↓		
Radium-E	Beta and Gamma Rays	5 days
↓		
Radium-F (Polonium)	Alpha Rays	136 days
↓		
Radium-G (end product)	No Rays	Not transforming

Alpha rays are positively charged material particles (helium atoms). They are four times the size of the hydrogen atom. Their velocity is from 1/10 to 1/20 that of light. They are somewhat similar to the anode rays of a Crookes tube. They are only very slightly penetrating, so that the thinnest layer of metal or even a sheet of writing paper is sufficient to absorb them. Alpha rays carry a double positive charge of electricity and are deviated in a magnetic field.

Beta rays consist of swiftly moving negatively charged electrons and are identical with the negatively charged particles constituting the cathode rays. They are about 1/1800 the size of the hydrogen atom. The velocity of the swiftest beta particle is about 0.96 that of light. Soft, medium, and hard beta particles may be distinguished according to their velocity and power of penetration. The slowest beta particles are comparable to alpha rays in penetrating power and are as easily absorbed. These are soft beta rays. The swiftest beta particles have a greater penetrating power than alpha rays and are absorbed to the extent of 99.9 per cent by a thickness of one millimeter of lead. These are hard beta rays. Between the softest and hardest beta rays is an intermediate series of so-called medium beta rays. Beta rays may also be deviated in a magnetic field, but in an opposite direction from the deviation of the alpha rays because the beta ray carries a negative charge.

Gamma rays are not material particles, but are believed to be undulations of the ether. They are similar to X-rays. They have a shorter wave length, however, and are much more penetrating than X-rays. Their velocity is the same as that of light. Their penetrating power may be inferred from the fact that a thickness of 25 cm. of lead is not sufficient to absorb all the gamma rays from radium. Gamma rays cannot be deviated from their course by a magnet.

Quantities of radium are best compared and standardized by means of the gamma rays. When a radium salt has been kept sealed for a month the maximum amount of emanation and active deposit has accumulated. The gamma ray activity is therefore at its height. By means of an electroscope, encased by lead at least 1 cm. in thickness to absorb the beta rays, the gamma ray activity, and hence the quantity of an unknown specimen, may be easily calculated by comparing the rate of discharge of the instrument produced by the unknown specimen with that produced by a standardized specimen.

Mention may be made here of the International Radium Standard. This consists of 21.99 mg. of pure, anhydrous radium chloride containing 16.75 mg. of radium element which was prepared by Mme. Curie in 1910 at the request of the Brussels Congress. This is kept sealed in a glass tube at the International Bureau of Weights and Measures at Sèvres, France. A secondary standard is kept at Vienna.

APPARATUS FOR APPLYING RADIUM

In the treatment of disease, radium may be applied in the form of radium salts, such as radium sulphate, radium emanation, or the active deposit. The therapeutic effects in each case are identical.

Apparatus containing radium salts. Radium salts may be placed for therapeutic use in tubes, needles, and flat plates or plaques. In the first instance capillary glass tubes are filled with a quantity of radium sulphate, representing from 5 to 50 mg. of radium element, which is packed so closely that the salt does not move about in the tube. The length of the tube varies from 1 to 2 cm., and the diameter from 1.5 to 3 mm. For convenience of handling, the glass tubes are usually inserted into silver tubes, just large enough to contain them. The silver tube may have a small screw cap to retain the glass tube and may be hermetically sealed. The wall of the silver tube is usually 0.5 mm. thick, but it may be



FIG. 210. APPARATUS FOR THE APPLICATION OF RADIUM.

of any desired thickness, or the tube may be of platinum or any other material. Over these tubes may be slipped screens of different thicknesses in order to filter out varying portions of the beta and gamma rays.

Radium needles, instead of tubes, may be used and introduced directly into the tumor tissue. In this case the radium sulphate is packed directly into a hollow needle, which is also fitted with a fine screw cap containing the eye of the needle. The cap is soldered on so that the radium may be completely protected. Twelve or more milligrams of the element may be packed into a needle smaller than an ordinary round surgical needle. Needles are usually made of steel or platinum with a wall thickness of 0.3 mm., a length of 2.7 cm., and an outside diameter of 1.75 mm. As platinum is nearly three times as dense as steel, a needle of platinum is almost three times as effective for screening purposes as a steel needle of the same thickness. This factor must be taken into account in choosing the type of screen to be used. Speaking very generally, needles containing as much as 10 or 12 mg. of radium element with 0.3 mm. of steel screening should not be left in the tissues over 8 hours. With 0.3 mm. of

platinum screening, needles placed 2 or 3 cm. apart may be left in the tissues as long as 24 hours. In either case the total amount of radium element should not be over 50 or 60 mg., unless the physician has had experience with the method and the cases are carefully selected.

When radium emanation is available its use is to be recommended in preference to radium sulphate, both because of certain mechanical advantages and the absence of the danger of losing the radium. It is better to use several needles of weaker strength implanted in different parts of the growth rather than one powerful needle, as homogeneity of action on all the tumor cells is the ideal to be achieved.

Flat plates or plaques, on which the radium salt is spread, are of various strengths, sizes, and shapes. The plaques may be composed of metal, linen, or rubber. With the latter two materials flexible applicators may be made, adaptable to the convexities and concavities of the skin surface. Linen applicators are known as *toiles*. The best form of metal applicator is made of silver, with the radium salt spread uniformly over a glazed surface which forms the face of the applicator. Lead free glass must be used. These applicators are known as glazed radium applicators and have practically replaced the older varnished applicators. Attention must be paid to the degree of concentration of "spread radium" as it is evident that different effects are produced by variations of this factor.

Expressed in terms of radium element, which is the common standard in this country, full strength, half strength, and quarter strength applicators contain respectively 5 mg., 2.5 mg., and 1.25 mg. of radium element to the square centimeter. The strength of each applicator is always approximate.

A convenient type of applicator is one 2 cm. square, and of half strength. Other plaques may be smaller or larger, round or oval, and contain less or more radium. Screens of any desired thickness, for example 0.1 mm., 0.5 mm., and 1 mm. of lead, may be used over the face of the plaque just as with tubes, so as to cut off by absorption any desired amount of the beta rays and prevent an excessive action on the superficial layers of the skin. The plaques have the great advantage over the usual capillary glass tubes enclosed in silver of permitting a greater utilization of the beta rays, which are desirable in some types of angioma, epithelioma, etc. They permit, moreover, a more uniform radiation on account of their plane surface and this is especially useful in certain skin disorders, notably angiomata, in which the cosmetic result is important. The disadvantage of the plaques lies in their relatively large size, which practically limits their use to the skin surface.

When one is using plaques with metal screens it is customary to place

over the face of the plaque the desired metal screen, and over the screen 10 or 12 thicknesses of thin notepaper so as to absorb the secondary rays. The whole apparatus is then wrapped in rubber dam and applied to the lesion with adhesive tape or a bandage.

Apparatus containing radium emanation. We have already said that both radium and radium emanation emit only alpha rays, which do not escape from the tube containing them. The real source of the penetrating rays is the degeneration products, principally radium-B and radium-C, or in other words, the active deposit.

When radium salts are confined in a tube the only function of radium itself and radium emanation is to produce radium-B and radium-C. It is evident then, that if we can separate the radium emanation from the solid radium and confine it in a glass container, radium-B and -C will be produced by disintegration of the emanation and will themselves constitute the source of the penetrating beta and gamma rays. In other words the capillary glass tube in which the emanation is confined may be used to radiate the tissues exactly as if it contained radium itself. Inasmuch, however, as radium emanation disintegrates quite rapidly, falling to one-half its original amount in 3.85 days, the radiations from this source are not constant, as is the case when radium itself is used.

Objection to the use of radium emanation alone as a source of therapeutic radiations has been made on the ground that the relatively rapid loss of activity impairs its value. This objection can easily be met by remembering that few treatments exceed 24 hours in duration, and during this time only 16 per cent of the initial activity of the emanation is lost. For the production and collection of radium emanation for therapeutic use at least one gram of radium element is desirable from a practical point of view. This is usually in the form of radium chloride dissolved in water to which a small quantity of hydrochloric acid has been added. The extraction, purification, and compression into a small bulk of the radium emanation from this solution is a highly technical and complicated procedure requiring special apparatus. For the description of this process the reader is referred to special works on the subject. Here it will be sufficient to state that the machine for this purpose devised by Debierue and Duane, and modified by Failla, is the one used by the writer and is satisfactory.

The advantages of radium emanation tubes over tubes containing radium salts are numerous. Among them may be mentioned the minute size of the emanation tubes, for it is easily possible to make an emanation tube less than one-tenth or even one-hundredth the size of a tube of similar activity containing radium sulphate; the greater flexibility of the armamentarium, since tubes or applicators of any size, shape, or strength

may be made; and the obviation of danger of loss of the radium, since the radium itself is not actually used in the therapeutic applications.

The apparatus designed for the practical application of radium emanation consists, first, of capillary glass tubes in which the emanation is confined. These vary in length from 3 to 20 mm., the outside diameter being less than 0.5 mm. They may easily be made of any desired strength,

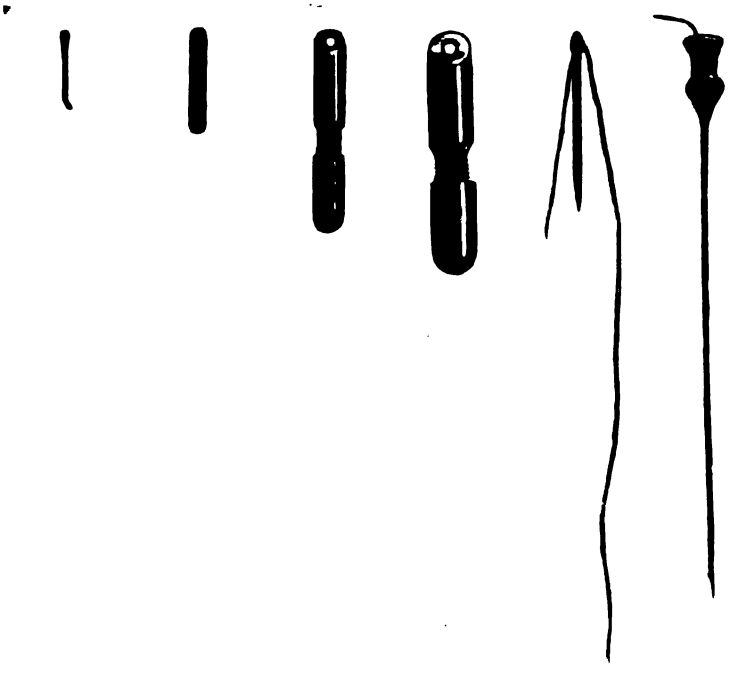

FIG. 211. APPARATUS FOR THE APPLICATION OF RADIUM EMANATION.

averaging in routine work from 5 to 50 mc. Silver tubes open at both ends, and just large enough to contain the glass emanation tubes, are usually slipped over them for convenience in handling. These silver tubes are covered with enamel of various colors which permits them to be easily distinguished. Their wall thickness is 0.5 mm. A record is kept of the number of millicuries of emanation sealed in each enameled tube so that its strength may be calculated from day to day.

A second form of applicator consists of needles in which the capillary glass emanation tubes may be placed for insertion into the substance of tumors. The capillary glass tube may be ejected from the lumen of the

needle and left in the growth while the needle is withdrawn, or it may be left in the needle, both being withdrawn after the required length of time has elapsed. In the former case the tissues receive a continuous bombardment of beta and gamma rays until the emanation has completely disintegrated, i.e., for about 30 days, or until the tube is freed by the sloughing of the tissues about it. This method is very effective in certain cases.

Apparatus for using the active deposit. We have said that when radium emanation is separated from the radium and confined in a tube, a thin coating or film of active deposit forms on the walls of the tube and that the tube itself may then be used as a source of radiation, the function of the emanation being simply to keep up the supply of active deposit. We may even go a step further. Once the active deposit has settled on the walls of the tube, the emanation itself may be taken away and the active deposit alone may be used as a source of radiations. Under these circumstances, however, the effectiveness of the tube is short lived, as the emanation is lacking to replenish the active deposit as fast as it disappears.

If a small piece of metal is enclosed for three or four hours in a container with the emanation, the metal becomes coated with active deposit and may be removed from the container and used alone as a source of radiations. This is a method of practical value in certain cases, although the so-called induced radio-activity of the metal falls to half value in one hour.

Another method for utilizing the active deposit is by dissolving it in water, or allowing it to collect in a closed chamber on some soluble substance such as common salt, which may then be dissolved. The solution may then be imbibed or injected, subcutaneously or intravenously.

ABSORPTION AND FILTRATION OF RAYS

By interposing metallic and non-metallic screens or filters between the radio-active substance and the tissues to be treated the less penetrating rays may be absorbed or filtered out. In the treatment, for example, of a tumor below the surface of the skin one may absorb the undesirable alpha and soft beta rays before they reach the skin, and use only the more penetrating hard beta and gamma rays which pass through the screen. In this way the skin will be spared as much as possible while the deeper layers of tissue will be more effectively reached.

Screens of various thicknesses and densities may be employed to accomplish this purpose. To absorb the alpha rays we may place between the radium and the skin a screen of aluminium 0.01 mm. in thickness or a

sheet of writing paper. The alpha rays, however, do not penetrate the walls of the glass tube or other apparatus in which the radium is ordinarily confined. In order to intercept in addition most of the beta rays we may interpose between the radium and the tissues a screen of lead 1 mm. in thickness. This filters out 99.9 per cent of the beta rays and permits the use of the nearly pure gamma rays which pass through the screen. When massive doses of rays are used it is sometimes desirable to absorb in addition a part of the softer gamma rays. Lead of 2 mm. thickness is then used. It is quite evident that a whole series of screens of different thicknesses and densities may be used to filter out varying portions of the alpha, beta, and even gamma rays, and that the results of treatment will vary accordingly.

Secondary radiations. When radium rays or the radiations due to its disintegration products, particularly radium-B and radium-C, strike metallic or fairly dense non-metallic substances, secondary or beta radiations are set up, the so-called rays of Sagnac. The therapeutic value of these radiations is unknown. While their presence may not seriously affect the skin surface, it is customary to interpose between the metallic screen and the skin non-metallic substances, such as gauze, rubber, or filter paper, in order to absorb these secondary rays.

Screens. We have already referred to the fact that metal screens of various thicknesses and densities are often interposed between the radium and the skin for the purpose of filtering out varying amounts of the beta rays. Such screens may be made of silver, gold, platinum, brass, lead, or aluminium. The choice of material is largely one of convenience. For external applications, brass screens answer almost every purpose, and it is believed that the secondary radiations from brass are not so irritating as those from lead or other denser metals. It is best to use rather simple and uniform screening, at least, until one becomes familiar with the effects of radium on the tissues. For internal applications, e.g., in the uterus, œsophagus, etc., gold or platinum screens have an advantage as their great density allows the use of a much thinner screen. Since platinum is twice as dense as silver, a screen of platinum 0.5 mm. thick will absorb the same amount of beta rays as a screen of silver 1 mm. thick.

While theoretically screens of almost any material or thickness may be employed it is advisable in actual practice to employ different thicknesses of the same metal in order to simplify the technique. It is convenient, no matter what metal is employed, to have it of such thickness as to be equivalent to a certain thickness of lead. Thicknesses of 0.1 mm., 0.5 mm., 1 mm., and 2 mm. of lead are the most desirable for the routine application of radium. The skilled technician will use a greater variety of screens, among the most useful of which are the following:

1. Silver—0.1, 0.5, 1, and 2 mm. thick.
2. Lead—0.1, 0.2, 0.5, 1, 1.5, and 2 mm. thick.
3. Platinum—0.3 and 0.5 mm. thick.
4. Aluminium—0.01, 0.02, 0.05, and 0.1 mm. thick.
5. Brass—0.5, 1, 2, and 2.5 mm. thick.

In addition to the metallic screen it is desirable to use a screen several millimeters thick of rubber, paper, or gauze to absorb the secondary radiations mentioned above. Filter paper is excellent for this purpose since it is composed of pure cellulose of low density, and hence does not appreciably absorb the gamma rays.

Distance filtration. A factor frequently overlooked in the technique of application is the distance of the radium from the tissue to be treated. As the radium tube is usually small, the rays from such a tube may be considered as emanating from a point. The variation of concentration of the rays with distance is in accordance with the law of inverse squares, that is, the intensity of the rays varies inversely as the square of the distance. Neglecting absorption for the moment, a surface 10 mm. from the radium tube will receive only 0.01 the dose which would fall on an equal area 1 mm. distant. A layer of tissue 5 mm. thick and 1 mm. distant from the radium would receive on the near side, 1 mm. away, 36 times the dose received on the far side, 6 mm. away. If the same layer of tissue were placed 5 mm. away from the radium it would receive on the near side, 5 mm. away, only 4 times the dose received on the far side, 10 mm. away. Homogeneity of irradiation of the tissues to be treated is a great desideratum. It is evident, then, that there is a great advantage in having the radium a certain distance from the skin so that the different layers of tissue will receive more nearly the same dose. In practice this is accomplished by interposing a non-metallic screen of rubber, wood, gauze, or filter paper of a thickness of from 2 to 20 mm. between the metallic screen enclosing the radium and the skin, in order to give the desired distance filtration and at the same time to absorb the secondary radiations. When the radium is introduced into a small cavity, as for example the interior of the uterus, it is obviously impossible to keep it at more than a few millimeters distance from the tissue to be treated.

In addition to the absorption of radium rays by screens or filters placed between the radium and the skin, the absorption of the rays by the tissues traversed must be taken into account. This is a very complex subject and has not as yet been entirely worked out. Keetman and Mayer, working with mesothorium, state that 8 per cent of the beta rays are absorbed by each 0.1 mm. thickness of tissue and that 5 per cent of the gamma rays are absorbed by each centimeter of tissue. Speaking in general terms, when superficial effects are desired, little or no metal screening may be

used, as the first centimeter thickness of tissue will practically absorb all the beta rays. Although under these circumstances both beta and gamma rays would take effect, the action of the beta rays would greatly preponderate in brief exposures.

When deep effects are required, the beta rays and some of the softer gamma rays may be screened off by 2 mm. of lead, or its equivalent of another metal, and the radium withdrawn to a distance varying from 1 to 10 cm. The greater the distance of the radium from the skin, if the source of the rays is a point or nearly so, the greater are the relative effects in the deeper layers of tissue, and the less risk is there of serious overdosage of the surface.

METHODS OF APPLICATION

The lesion to be treated, if on the skin, is gently cleansed, and the rubber, gauze, or other material, of such thickness as may be required to keep the radium at the proper distance, is applied and held in place by adhesive tape or a bandage. Upon this the radium tube encased in the metal screen is held in position in the same way. Protection is always assured for the apparatus by wrapping it in a finger cot or dental rubber dam.

For the treatment of larger areas radium pads or packages are conveniently made of blocks 2 cm. square and 1 cm. thick, of soft wood, cork, or hard rubber. These can be fastened together by adhesive tape to form variously sized packages, which will have a certain amount of flexibility because of the joints formed by the tape. On these pads the tubes are placed in parallel rows or in any desired arrangement, and held in place by strips of adhesive tape.

For internal applications various devices have been made. In the vagina or uterus, gauze packing may be used to hold the radium in place. Heavily screened tubes placed against the cervix will not ordinarily injure the healthy, adjacent vaginal mucous membrane if sufficient packing is used to separate the walls of the vagina to the fullest extent. In the nose, mouth, œsophagus, rectum, and bladder, the tubes may be attached to a pliable silver wire which can be bent to the required angle and fastened to the adjacent skin. In addition, it is always advisable to have the radium tube anchored by a long silk thread which is also fastened to the neighboring skin by adhesive tape. We have used for some years, especially in mouth cases, the dental modelling compound suggested by Janeway to hold several tubes in position. After this is fashioned to suit the outline of the growth the tubes are laid in little troughs in the compound. In this way they may be held in position without discomfort for the required length of time.

In order to protect the normal tissues adjacent to any lesion on the skin when using beta rays, one may use a sheet of lead 3 or 4 mm. thick, in which an aperture is cut which corresponds to the outline of the lesion. This does not protect the tissues completely from the gamma rays but it suffices under ordinary conditions. If the radium tube is separated several millimeters from the lesion under treatment by the protecting lead this distance must be taken into consideration in estimating the dosage. For the protection of the eyeball in epithelioma of the lid we use a



FIG. 213. PAD OF CORK SQUARES FOR HOLDING RADIUM IN POSITION.

specially constructed gold screen, made after the model of an artificial eye. We always endeavor to protect hairy regions, such as the eyebrows, in which the loss of hair would cause disfigurement.

Length of exposure. Short exposures varying from one or more minutes to an hour are especially suitable when the varnished or glazed plaques are used. In such treatments, as a rule, no screening at all is used except such as is provided by the rubber dam in which the apparatus is wrapped, but in some cases a screen of 0.02 mm. of aluminium or 0.1 mm. of lead may be employed. The apparatus is applied in close contact with the skin. Such treatments, involving chiefly the use of the beta rays, are most suitable for superficial skin diseases.

Moderately long exposures may last from 2 to 12 hours, divided into

periods of one or more hours each. In treatments of this duration from 0.1 to 1 mm. of lead would be suitable screening, the apparatus being applied closely to the skin in the case of plaques and several millimeters away when using tubes. Such exposures are adapted to moderately infiltrated epitheliomata, etc.

Very long exposures, up to a total of 30 hours, are suitable for deeply situated tumors. Several treatments of from 6 to 12 hours each may be given. The routine screening in such treatments is the equivalent of 2 mm. of lead with the radium at a distance of one, two, or more centimeters from the skin.

The reaction. When the skin or other living tissue is brought under the influence of radium rays a succession of changes occurs which is called the radium reaction. This may be a selective or differential reaction, or an inflammatory reaction. By selective or differential action we designate the effect of radium rays upon certain tissues without the production of visible inflammatory changes. This is illustrated by the action of radium on certain epitheliomata, keloids, and angiomata which may sometimes be made to recede and disappear without visible inflammation. By inflammatory reaction we mean the ordinary changes characteristic of inflammation which may easily be produced by radium. Inflammatory reaction usually appears between the seventh and fifteenth days but it may appear as early as 2 or 3 days after exposure, and in some cases it may be delayed as long as 4 weeks.

For convenience, four degrees of inflammatory reaction may be distinguished, although these degrees or stages of reaction pass insensibly into one another. The first is simple erythema; the second, erythema followed by desquamation; the third, vesication or superficial ulceration; the fourth, deep ulceration. The latter may be accompanied by the production of an eschar. It should be the constant aim in treatment to avoid severe reactions. By following the proper technique as regards dosage, screening, distance, and length of exposure this can almost always be done.

In tissues which have been subjected to previous treatment such as by X-ray, cauterization, etc., radium reaction may be atypical and healing very slow. Such tissues should be treated with the greatest caution and not more than one-fourth of the normal dose should be given.

Areas which have been treated with radium may be sensitive to temperature changes long after healing has occurred. Many patients complain of a peculiar sensation, as of ants crawling on the skin, but such sensations usually disappear in the course of a few months.

In patients who have received large doses of heavily screened radium, for example 250 mg. or more, nausea and vomiting, a feeling of depres-

sion, malaise, and a slight elevation of temperature may occur in the ensuing 24 hours, but these symptoms usually pass off in a few days.

Dosage. This factor is extremely variable and of the greatest importance. It has already been stated that tubes, plaques, etc., containing from 5 to 50 mg. of radium element, or millicuries of radium emanation, are the most convenient and useful. Almost any combination of apparatus to augment the amount of radium in a single case may be employed. Combinations of apparatus to increase the dose are made largely as the result of experience in dealing with special kinds of lesions. No hard and fast rules can at present be laid down, but some general principles may be stated to guide the inexperienced.

While there probably is an optimum dose and method of treatment, equally good results may be achieved in average cases by very different methods. The quantity of radium, the degree of its concentration per unit area, the screening, the distance from the skin, and the time of exposure, may all differ with different operators and yet the final result may be equally good. Wickham long ago insisted upon the fact that we cannot be too dogmatic, or use a routine method in matters pertaining to radium therapy. In children the dose should not be more than one-half, and in the case of very young children not over one-fourth that used in adults. We may draw attention at this point to the necessity of clearly stating the dosage employed. The terms milligram-hours and millicurie-hours in common use (i.e., the number of milligrams of radium element or millicuries of emanation multiplied by the number of hours of exposure) are not entirely satisfactory because of their relative inaccuracy. For example, 100 milligram-hours may mean either 100 milligrams employed for one hour or one milligram for 100 hours, but the effect is entirely different. It is better, in our judgment, to state explicitly the number of milligrams of radium element, or its equivalent, the number of millicuries of radium emanation; the concentration per unit area; the screening; the distance of the radium from the tissues; and the length of exposure.

With radium in plaques the law of the intensity of the rays varying inversely as the square of the distance does not apply, as the source of activity is not a point but a plane surface. The radium plaque wrapped in dental rubber dam, is usually applied directly to the skin, either without or with metal screening. In the latter case, in addition to the metal screen, a few layers of rubber or filter paper are commonly employed to absorb the secondary rays.

With a plaque in which the concentration approximates 1.25 mg. of radium element per square centimeter, and in which the superficial surface is 25 sq. cm., the following dosage may safely be given:

1. Without screening—three minutes. The application may be repeated several times at a week's interval. Such applications are suitable for neurodermatitis, pruritus ani, etc. No inflammatory action should be produced.

2. With a 0.1 mm. lead screen, from 4 to 6 hours total application, given 1 hour a day on successive days. Such applications are suitable for some cases of keloids, superficial epitheliomata, angiomata. etc. Some inflammatory reaction with superficial destruction will be produced.

3. With a 1 mm. lead screen, from 18 to 24 hours in divided doses of 3 or 4 hours each. Such applications are suitable for superficial epitheliomata. Slight surface inflammation is produced.

4. With a 2 mm. lead screen, a total of 60 hours in periods of 10 or 12 hours each. Such dosage is suitable for deeper penetration. The surface inflammation is slight.

With radium salts or radium emanation in tubes it is desirable and even essential to have a different method of arranging the tubes when a large area is to be covered than when a smaller area is treated. In general a concentration of from 1.25 to 10 milligrams of radium element or millicuries of emanation per square centimeter of superficial surface is a useful arrangement. When only 5 or 6 sq. cm. of surface are to be covered, the higher concentrations may be used. When large areas are to be treated the lower concentrations should ordinarily be employed. By increasing the distance of the radium from the skin the higher concentrations of tubes may be employed without ill effects, and with advantage in certain cases in which very deep effects are required.

A few illustrations of dosage when using radium tubes may be given:

1. With one 10 mg. tube to each square centimeter of surface and with a 0.5 mm. lead screen plus 2 mm. of rubber, treatment for 3 or 4 hours may be given safely when small areas such as 5 or 6 sq. cm. are covered. This dosage is suitable for small superficial epitheliomata.

2. With the same strength of tubes and degree of concentration but the screening increased to 1 mm. of lead plus 2 mm. of rubber, a total of 12 hours may be given in divided doses.

3. With the same strength of tubes, the screen thickness is increased for deep penetration to 2 mm. of lead, the radium being 6 cm. distant from the skin. When large areas such as 100 sq. cm. are to be treated the concentration may vary from 2.5 to 10 mc. per square centimeter. The total amount of emanation employed under such conditions would vary between 250 and 1,000 mc. In the former case 40 hours may be given and in the latter 10 hours.

4. In cases requiring very deep effects, the concentration may be from 5 to 10 mc. per square centimeter for areas of 100 sq. cm., and the

distance may be increased to 10 cm. In the first case 30 hours may be given in several treatments, and in the second 15 hours.

RADIUM IN GENERAL SURGERY

Malignant tumors. In the treatment of malignant disease in general, exclusive of certain types of epithelioma of the skin, there remain many difficulties in the way of achieving an ultimate cure. Although the primary growth even in inoperable cases can sometimes be eradicated, unless a sure way is devised of preventing metastases the end-results in malignant tumors will remain far from ideal.

In many cases that come under radium treatment metastasis has already taken place. In such cases palliation is all that can ordinarily be hoped for. In this connection we may note the following remarks from the report of the Manchester and District Radium Institute for 1915: "The investigations of the Middlesex Hospital Cancer Research Laboratories on carcinoma and sarcoma occurring in mice and rats have suggested the possibility of producing immunity to cancer by means of radium, but no method of application or refinement of dosage has as yet been devised which will produce this result with certainty in human malignant disease. In a few cases the sudden and almost unexpected disappearance of a tumor, or such signs of reaction as high temperature, rapid pulse, etc., have suggested the formation of antibodies; but this experience is uncommon, and for the present we must look more for local than for general effects from radium treatment."

At the present time practically all radium therapeutists are in accord that for operable growths, excepting certain epitheliomas of the skin, surgery is the logical procedure. It has been shown by F. C. Wood and others that a certain type of malignant tumor in mice frequently cannot be successfully implanted after radium treatment. The most rational procedure, therefore, even with clearly operable malignant disease is first to treat the growth vigorously with radium. Immediately afterward, operative removal of the tumor should be carried out. A few weeks later postoperative prophylactic radiations should be given.

In inoperable cases of malignant disease, treatment with radium has been followed in numerous cases by a clinical recovery which has sometimes been maintained for a number of years. Radium may be said, therefore, to give promise at least of a certain amount of relief even in those cases in which surgery is hopeless. It is of the utmost importance to bear in mind, however, that the inoperable cases submitted to radium fall into two general categories: Those in which it seems best to make a strong effort to bring about a clinical recovery, and those in which only

palliative treatment is advisable. Failure to recognize the latter class of cases will result in disappointment and may even cause great harm. Indeed it is better to omit treatment altogether rather than attempt the impossible and cause additional suffering from radium effects.

The basis for the treatment of carcinoma or other malignant growths by radium rays is the fact that the tumor cells are more susceptible to the rays than normal tissues. A dose that falls short of destroying normal tissues will often cause necrosis and disappearance of the tumor itself. One strives, therefore, to produce a change in the growth which will not at the same time be accompanied by serious injury to the healthy tissue. This is best accomplished by giving maximum doses at the outset. Subsequent doses should always be of less intensity.

Reports from various sources as to the histologic changes in carcinomatous tissue induced by radium rays are quite uniform. Within a week or ten days after intense radiation there is a swelling of the cell protoplasm, with hyperchromatosis and pyknosis of the nuclei. After 5 or 6 weeks the carcinoma cells have disappeared, while the blood vessels and connective tissue show evidences of hyaline degeneration. Pronounced infiltration with polymorphonuclear leucocytes, and sometimes with giant cells, is observed. Finally the inflammatory and necrotic tissue is replaced by connective tissue, and the histologic local cure of cancer is completed. The final histologic changes usually occur in two to three months after radiation.

Epithelioma of the skin. The problem of treatment of epithelioma of the skin depends to a great extent upon the type of growth that is present. With a squamous-celled epithelioma, if the case is considered operable by the surgeon, the draining lymphatic glands and growth should be excised *en bloc*. There is little doubt, however, that even in distinctly operable cases pre-operative radium treatment will be of advantage in lessening the danger of metastasis and recurrence. After operation, prophylactic radiations should also be given. With an early diagnosis recovery should be brought about in at least 95 per cent of the cases. With inoperable cases, the growth may frequently be retarded in its progress for considerable periods of time, and in some cases a clinical recovery may be brought about.

The differentiation of squamous-celled from basal-celled epithelioma is difficult without a microscopic section, but certain clinical findings are helpful. First, epitheliomata of the lower lip, tongue, and penis are usually of the squamous-celled type. One half of the epitheliomata of the upper lip are also of this type. Second, a papillomatous aspect of the growth is usually indicative of squamous-celled cancer. Third, rapidly growing epitheliomata with metastases in the adjacent lymphatic glands

are practically always squamous-celled. It must be emphasized, however, that there is no absolute rule which allows of a complete clinical differentiation.

The treatment of squamous-celled epithelioma of the glabrous skin, when it is for any reason inoperable, varies with the clinical type and severity. With small and superficial growths one-quarter or one-half strength glazed plaques may be used. With a 0.1 mm. lead screen a total of from 6 to 12 hours may be given in several periods of 1 or 2 hours each.

With larger, deeply infiltrated, and ulcerated growths, it is best to use only hard beta and gamma rays. With 150 mc. (5 or more millicuries per square centimeter), and a 2 mm. screen at a distance of 2 cm., 30 hours may be given in 3 or 4 periods. In 6 weeks, if there are evidences of persistence of the disease, a similar course of less intensity should be given, provided signs of radium reaction are absent. Great care should be taken to avoid burns, which may be very painful and prevent further treatment at a critical time. Some advise vigorous treatment with unscreened applicators for certain refractory types, and even in ordinary cases. This, however, causes considerable inflammatory reaction, and if unsuccessful precludes further treatment for a time on account of the pain. We prefer the former method in ordinary cases, but in some cases we resort to the unscreened glazed applicators. For the treatment of the adjacent lymphatic glands powerful deep radiations are advisable; 250 mc. (2.5 mc. per square centimeter), with a 2 mm. screen at a distance of 6 cm., may be applied for a total of 30 or 40 hours.

For the treatment of basal-celled epitheliomata radium is, in our judgment, the most satisfactory agent we possess, and sometimes succeeds when everything else fails. In spite of statements to the contrary, we believe that this type of epithelioma is of all types of new growth one of the most amenable to radium. Failure may occur in very extensive cases in which the loss of tissue is great and repair is almost impossible; and in a few cases there may be a lack of power in the cells to respond to treatment. Cases that have had other forms of treatment, extending over long periods, frequently do badly. Caution must always be used in applying radium after extensive X-ray treatments.

The method of application in this type of epithelioma is similar to that used for squamous-celled cancer. Treatment of less intensity, however, is usually sufficient. With small superficial growths a very good plan is to use a quarter strength applicator screened with 0.1 mm. lead for 6 or 8 hours, divided into several periods. With larger, more deeply infiltrating growths we follow the plan previously indicated for more grave types of squamous-celled epitheliomata, but as a rule, shorter exposures will suffice to bring about resolution and healing.

In epithelioma supervening on scar tissue resulting from X-ray treatments, very cautious and light treatment should be given. Not over one-half the amount indicated above as suitable for ordinary cases should be used, as experience has shown that the previously treated tissue breaks down very easily and the ulceration caused may heal with the greatest difficulty. The scar following radium treatment, even in extensive cases, is usually smooth and supple, and very inconspicuous. Contractures seem never to occur, a point of the greatest importance in lesions about the eyelids. When contractures causing ectropion have existed from previous operations we have seen them much improved by radium treatment directed against recurrence in the scar. The writer has now treated with radium over 800 cases of basal-celled epithelioma of various clinical types and failure to bring about recovery has been uncommon.

Leukoplakia. The radium treatment of leukoplakia, which is such a frequent precursor of epithelioma of the lingual, buccal, and pharyngeal mucous membranes, is often successful. A caustic dose must usually be employed in order to bring about the desired result, but at times deeper and less caustic radiations may be given. A method which we have frequently used consists in the application of from 60 to 80 mc. (10 mc. per square centimeter), screened with 1 mm. of lead and 16 layers of gauze, for a total of 8 or 10 hours, in periods of 1 or 2 hours each.

Cancer of the lingual, buccal, and pharyngeal mucous membranes. While epithelioma in these situations is frequently refractory to radium, very good and even brilliant results may sometimes be obtained. Failure to bring about recovery may be due to various factors. Too small a quantity of radium, applications made too far away from the growth, and a failure to hold the radium properly in the exact position required are among the errors that may be made. These are difficulties that can ordinarily be overcome. We would advise the use of not less than 100 mc. when surface applications are made. The radium should be separated from the growth by a metal screen at least 1 mm. in thickness and by 16 layers of gauze. From 10 to 15 hours in divided doses may be given. For holding the radium in position we frequently utilize the dental composition material mentioned above. When radium in needles is inserted into the growth not less than 50 mc. should be used.

Cancer of the tongue is always of the squamous-celled type. It is of all cancers the most likely to invade the lymphatic glands early and widely. This tendency in itself precludes successful treatment in most cases. Janeway has stated that with carcinoma of the tongue involving an area more than 1 cm. in diameter there is uncertainty as to the possibility of cure with radium. In the most extensive cases only retardation of the process can be hoped for. Sometimes cases seem to yield quite satis-

factorily to the insertion of radium needles. I have reported a successful case, treated in 1917 in this manner, in which there has been no recurrence. In this case 60 mg. were inserted into the growth for 13½ hours, and 7 weeks later 72 mg. for 12 hours. Hayward-Pinch uses from 21 to 53 mc. for 24 hours in a platinum needle with a wall thickness of 0.3 mm. Sharp reaction follows this treatment and in some cases the nodule is replaced with scar tissue.

Cancer of the buccal and pharyngeal mucous membrane may be treated by surface applications by the method described above. In some cases, however, 50 mc. or more of radium emanation, contained in several steel needles, may be buried in the growth. In other cases, radium emanation may be inserted into the growth by dislocating from the steel needle containing them minute glass ampoules containing 5 mc. or more of the emanation, and allowing these to remain. Sharp reaction follows. Care must be taken not to bury the ampoules too near a blood vessel on account of the danger of hæmorrhage following erosion of a vessel wall. With the latter method not more than 25 mc. should be buried in an area of a few square centimeters.

In most cases of cancer about the mouth the neighboring lymph glands become involved sooner or later, although this event may be delayed for a considerable period. Treatment of the glands often retards their growth, but in using heavy doses care must be taken not to produce severe reactions which may be disastrous to the patient's comfort and may even hasten his end. As much as 250 mc. (2.5 mc. per square centimeter), with a 2 mm. screen at a distance of 6 cm., may be given in divided doses for 30 or 40 hours in ordinary cases of carcinomatous glands. Smaller doses are inadequate.

If the radium is applied in steel or platinum needles inserted in the tissues an aseptic technique is essential, since screened radium does not have a marked antiseptic effect. Several needles of moderate strength should be used, rather than one strong needle, in order that an even distribution of the rays may be produced in the entire growth. A certain quantity of healthy tissue should surround the growth in order that repair may be accomplished.

The quantity of radium embedded in a growth depends upon the size of the tumor and the thickness of the needle wall, and to some extent upon the situation of the growth. Encapsulated organs, such as the tonsil and prostate, are especially suitable for needling. The exact dosage is largely a matter of experience and judgment on the part of the operator. Speaking generally, five steel needles with a wall thickness of 0.3 mm., each containing as much as 10 mc. of emanation, may be left in the tissues 6 hours. If platinum needles of a similar wall thickness are

employed, they may be left in the tissues as long as 24 hours, provided the total amount of emanation does not exceed 50 mc. In all cases needles should not be inserted closer to one another than 1 or 2 cm.

Carcinoma of the breast. One should not attempt to treat operable cases of this disease solely with radium. Pre-operative radiation followed immediately by operation is the most logical procedure. Post-operative radiation of the operative field and the areas most likely to harbor metastatic deposits should certainly be carried out. When a considerable quantity of radium is available, the thorough saturation of the whole chest with deep penetrating rays is advisable. There are certain operable cases in which the patient absolutely refuses to undergo operation. It should be remembered that some of these cases may be successfully treated with radium if the local conditions are favorable. When the breast is not too large and the adipose tissue is not excessive, if the tumor is small and well localized, success is possible so far as the local growth is concerned. Unfortunately, metastases to the regional lymphatics or to distant organs precludes recovery in most cases.

In cases inoperable on account of the extent of the disease only palliative treatment should be undertaken. In cases of the atrophic type, the progress of the disease may be retarded if the more accessible lympathic glands alone have been invaded. In a recent inoperable case under the writer's care, in which not only the breast but the axillary and supraclavicular glands were involved, all the palpable masses disappeared under treatment, but metastases appeared in the spine. In the more rapidly growing type of carcinoma response to radium treatment is likely to be poor, although pain may be relieved.

Inoperable recurrences assume many different forms. Small cutaneous nodules or superficial ulcerations occurring on the chest wall may frequently be healed by careful radiation. Deeper nodules attached to the bone or cartilage of the chest wall may be treated effectively by penetrating rays, or sometimes by the insertion into the nodule for 18 or 24 hours of platinum needles containing radium emanation. Sometimes when a serous effusion has supervened in consequence of involvement of the pleura or peritoneum, the fluid may be withdrawn and powerful deep rays applied immediately. In some cases the effusion has not reappeared.

The technique of treatment varies according to the conditions present. When superficial isolated recurrences are to be treated, the treatment may be carried out just as for epithelioma of the skin. When large and deep masses are present, radiations should be of the most penetrating character. As much as 200 or 300 mc., evenly disposed on a pad 9 x 12 cm., placed at a distance of 6 cm. and screened with 2 mm. of lead, may be applied for a total of 30 hours in several periods of from 5 to 10 hours each. In other

cases demanding deep effects the quantity of radium may be doubled if the distance is increased to 10 cm., while the screening and time remain the same. If as much as 600 mc. are employed, the time should not exceed 30 hours.

Carcinoma of the prostate. Good results are frequently obtained from radium treatment of carcinoma of the prostate. The technique of treatment varies a great deal with different workers. Formerly the radium was introduced into the urethra in a hollow sound with a wall thickness of 1.5 or 2 mm., and allowed to remain in contact with the growth. At the same time another tube was introduced into the rectum for cross-firing. While encouraging results have been obtained by this method, no plan seems to have been so uniformly successful as that of Barringer. The essence of his method is strong central radiation of the prostatic mass. He uses 50 mc. of radium emanation in a special gold or steel needle from 4 to 6 inches long. The screening consists only of the thin wall of the needle. The capillary glass emanation tube occupies the distal 1½ inches of the lumen. The needle is introduced through the perineum under local anæsthesia and allowed to remain six hours in each prostatic lobe. If necessary, it can be pushed into the seminal vesicles, while being guided by a finger in the rectum. In 30 cases treated by Barringer according to this method, marked retrogression of the growth resulted in every case.

Good results have been obtained by a similar method which I have outlined. This consists in the use of eight or more steel needles, each containing about 12 mg. of radium element, introduced into the prostate either through a perineal or suprapubic incision so as to act homogeneously upon the entire prostate. One of the writer's cases in which great improvement followed has been reported by Dr. R. H. Herbst. The needle introducer described in this report was devised by Dr. O. T. Freer.

Carcinoma of the bladder. So many reports of cases of inoperable carcinoma of the bladder successfully treated with radium have been made that the treatment should be advised in all cases in which the bladder wall cannot be resected. The cessation of hæmorrhage, the disappearance of cystitis and all subjective symptoms have been a common occurrence. Objectively, growths of considerable size have diminished and ulcerated areas have become covered with healthy epithelium, as shown by cystoscopy. It is a matter of a good deal of technical difficulty to apply the radium satisfactorily to the tumor through a cystoscope but unless this is done the results will be poor. Great harm can easily be done by allowing the radium to remain in contact with the normal bladder wall for considerable periods.

Young and others have devised special instruments, not unlike the

operating cystoscope, for applying the radium and holding it in contact with the tumor. Preliminary fulguration is advisable to check the bleeding. It should be emphasized that it is worse than useless to apply radium blindly to the interior of the bladder by means of an ordinary rubber catheter. When, for any reason, accurate application through the urethra is impossible, suprapubic cystotomy should be performed in order to render the growth accessible. Radium tubes may then be introduced through the cystotomy wound and held in position by a long pliable silver wire fastened to the abdomen by adhesive strips. More effectual still is the use of emanation needles introduced through the suprapubic opening into the substance of the growth.

The technique of treatment varies. If applied through the urethra not less than 50 or 100 mc., screened with 2 mm. of silver, may be used in periods of several hours each two or three times weekly, until from 10 to 20 hours have been given. When applied through a cystotomy wound, 50 mg., screened with 2 mm. of lead and 3 mm. of rubber, may be applied for 30 or 40 hours in several periods. If radium needles with a 0.3 mm. steel wall are introduced into the substance of the growth, from 60 to 90 mc. in 6 or 8 needles may be applied for from 8 to 12 hours. In addition, heavily screened radium may be applied on the perineum or in the vagina or rectum in order strongly to cross-fire the growth. One of our cases, treated in conjunction with Dr. M. L. Harris, has been well more than five years. In this case from 25 to 75 mg. of radium, with a 2 mm. screen, was applied by means of a long silver wire through a suprapubic opening for a total of 60 hours.

Carcinoma of the œsophagus. In this all but hopeless disease the results of radium treatment in a number of cases have been encouraging. In one case Finzi obtained a clinical recovery which had been maintained for three years when the case was reported. In another case a clinical recovery was maintained for four years when the patient died suddenly. Postmortem there was found involvement of a small intercostal branch of the aorta with resulting hæmorrhage.

Previous to undertaking treatment, careful localization of the growth is important. Skiagrams with and without a bismuth meal, direct œsophagoscopy, and measurements with bougies usually afford sufficient information. It is necessary that the lumen of the growth admit a bougie several millimeters in diameter in order that the properly screened radium may pass completely within the stricture. Swallowing a silk thread several days prior to treatment, upon which the bougie holding the radium may be threaded, will sometimes enable one to engage the apparatus in the lumen of the growth in difficult cases. An average treatment consists of 50 mc., screened with 1.5 mm. of silver, passed into the strictured part

of the œsophagus and kept in position for about 15 hours. Morphine and atropine may be given hypodermically and a special attendant should maintain the bougie in place. The treatment may be repeated in 6 weeks.

Another method adapted to certain cases and suggested by Janeway involves a preliminary gastrostomy. A silk thread is subsequently swallowed and the end pulled out through the gastrostomy wound. A series of several radium tubes is then attached to the oral end of the string and pulled through the stenosed tract by means of the lower end. The upper tube is of such size that it will not slip through the strictured part of the œsophagus, but will rest upon the upper end of the carcinoma. Janeway has used larger doses than we have indicated, but for a shorter period; for example, several tubes of 30 or 35 mc. each for 4 hours, or with a 2 mm. lead screen for 6 hours.

The immediate result of treatment is an improvement in swallowing, due perhaps to the mechanical dilatation. From 5 to 10 days later there may be increased dysphagia, due to the onset of reaction. The hæmorrhage, odor, and purulent discharge which attend the passage and withdrawal of a bougie prior to treatment are no longer present. In a few weeks, as the reaction from the radium subsides, dysphagia is relieved and the patient may be able to swallow all kinds of food for a good many months. Greatly increased body weight and improvement in the general condition are usual accompaniments of the increased power of swallowing.

Carcinoma of the stomach and intestines. In inoperable or recurrent carcinoma of these organs it seems at least permissible to use radium in the hope of retarding the disease and relieving pain. Janeway has seen improvement follow posterior gastro-enterostomy combined with radium treatment. During the operation a series of radium tubes was pulled into place through the gastrostomy wound by means of a string swallowed previously. We have used a similar method for carcinoma of the sigmoid flexure of the colon. By means of a string passed through the distal portion of the bowel from the colostomy opening to the anus a number of tubes is drawn into the lumen of the affected portion. Palliation is all that can be hoped for in these conditions. Symptomatic improvement has been noted following powerful deep treatment over the abdominal wall. This condition demands the use of at least 250 mc. for from 30 to 70 hours. The screen should be of 2 mm. of lead and the distance from 6 to 10 cm.

Carcinoma of the rectum. Considerable experience has been accumulated in the radium treatment of this disease. In general, rectal carcinoma varies a good deal in its response to radium. Adenocarcinoma of the annular, vascular type, situated in the upper one half of the rectum, is probably more amenable than growths occupying only a portion of the

rectal lumen and infiltrating the wall deeply. So-called epidermoid carcinoma in close proximity to the anal region is less easily influenced than the other types. Because of the uncertainty as to whether or not the radium tubes actually remain in contact with the growth during the application, satisfactory treatment is often difficult. A number of cases of apparent clinical cure for varying periods of time have been reported by different authors, but the proportion of such cases is not over 10 per cent. It must be remembered, however, that as a rule only cases in which surgical intervention is impossible are treated with radium. Fully one-third of the cases are distinctly improved. In border-line cases, radium treatment may render operation possible.

The dosage naturally varies. Conservative dosage consists of 50 mg. screened with 2 mm. of lead, applied for a total of 30 hours in from 6 to 10 periods. With this dosage proctitis will be slight or absent. The course may be repeated in six weeks' time. Certain cases may be treated, if thought desirable, with 200 mc., screened with 2 mm. of lead, for 8 hours. Subsequent courses of treatment should always be of less intensity.

If the patient lies quietly on a hard couch and treatments are not prolonged over two or three hours, the tubes can often be applied satisfactorily by means of a long pliable silver wire, one end of which is bent over the buttock and fastened with adhesive tape. The tubes must be carried into the lumen of the growth and retained there during the time of application. Young has devised a satisfactory artificial arm to hold the radium in place. In some cases the application is made best by the aid of the proctoscope.

With growths occupying only a portion of the lumen of the bowel, the normal mucosa on the side opposite the growth may be protected by a lead screen several millimeters in thickness. In other cases, one may pack off the normal rectal wall with gauze or with a rubber finger cot distended with air. Preliminary inguinal colostomy is advisable, although not absolutely essential.

Sarcomata. When treated early and before dissemination to various parts of the body has occurred, the results of radium treatment in sarcomata are, on the whole, very beneficial. Unfortunately, metastases may sooner or later render the prognosis hopeless, but numerous cases have remained well for considerable periods of time.

Lymphosarcoma is particularly susceptible to treatment and, with the exception of so-called teratoid carcinoma of the testis, responds most readily of all growths to radium applications. In this type of disease large masses may disappear in the most surprising fashion.

In a type of tumor usually referred to as sarcoma, but classed by Ewing

as teratoid carcinoma of the testis and ovary, a remarkable susceptibility to radium is often seen. In one of the writer's cases, a large mass existed in the right hypochondrium, extending from the costal arch to the umbilicus and apparently larger than a child's head. This had been preceded a year before by so-called sarcoma of the right testis, which had been surgically removed. Complete disappearance of the abdominal tumor occurred within a few weeks under radium treatment (200 mg.

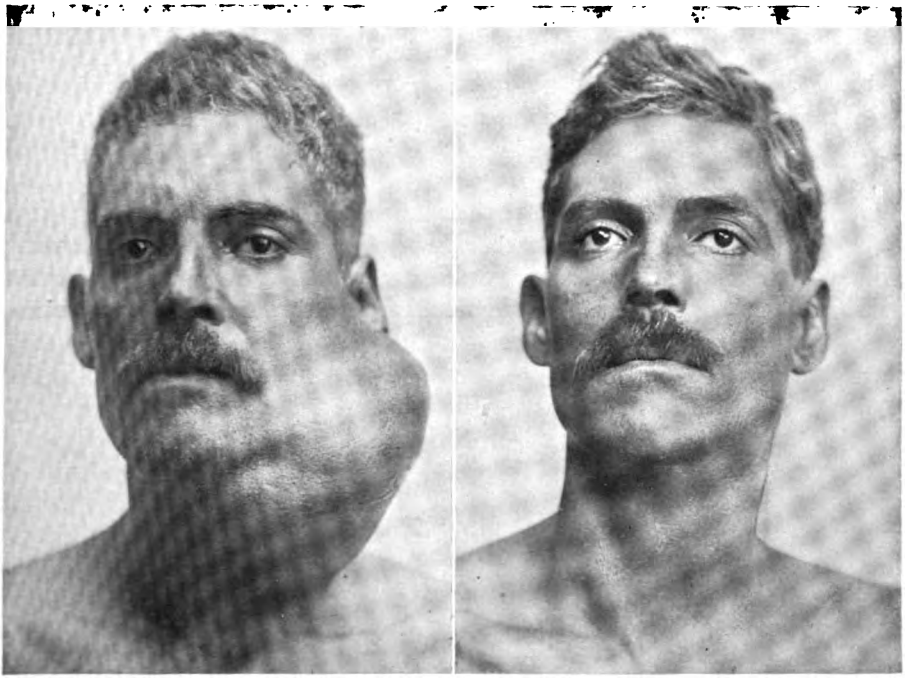

FIG. 214. PHOTOGRAPHS OF PATIENT WITH LYMPHOSARCOMA OF THE NECK RECURRING AFTER OPERATION. Photographs taken August and December, 1919, before and after radium treatment was given.

for 40 hours, at 6 cm. distance with a 2 mm. screen). The patient is now in excellent health after more than two and one-half years.

Melanosarcoma does not as a rule give good results, but in exceptional cases may yield completely. Sarcoma of the skin is usually amenable. Kaposi's sarcoma may yield to radium. Myeloid sarcomata (myelomata) only occasionally are benefited. Periosteal sarcoma is frequently cured and recurrences are uncommon. Sarcoma of the tonsil and postnasal space are usually amenable to radium.

Sarcoma of the orbital tissue recurring after operation is often strikingly benefited by radium. Unfortunately, metastases to the neck or distant organs occur sooner or later in most of the orbital cases and cause a fatal termination.

Numerous cases of mediastinal tumors have received great benefit from radium treatment. The fact that many of these growths are probably lymphosarcomata explains the remarkable results sometimes seen. Burnham has reported an interesting group of 8 cases of mediastinal tumor treated with radium, in which improvement occurred in all but one.

The technique of treatment of sarcoma varies greatly according to the situation, size, etc., of the tumor. In postnasal cases, we have inserted 50 mc. or more in two tubes, with a 1 mm. screen and 1 mm. of rubber, through the anterior nares for a total of 12 or more hours in several periods extending over a week or ten days. In tonsillar sarcoma we have successfully buried in the growth for 8 hours 60 mg. in 5 needles with a 0.3 mm. screen. In orbital sarcoma, 50 mg., with a 2 mm. screen. may be inserted in the orbital cavity for 12 hours and the treatment repeated in a week. This should follow immediately after operation and be repeated in the event of recurrence. In all types of deep sarcoma or when large masses exist, deep exposure with large quantities of radium is the method to be chosen and is usually the only method which gives good results. As much as 250 mg. per 100 sq. cm., with a 2 mm. screen at a distance of 6 cm., may be used for a total of 40 hours. At 10 cm. distance radiation may be given over a period of 60 hours. An even better method in some cases is the use of 500 mg. at the same distance for a total of 30 hours.

In mediastinal tumors, Burnham has used more than a gram of radium at a distance of from 3.5 to 15 cm., with a 3 mm. screen, for periods of 4 or more hours on each area.

Tuberculous lymphadenitis. In the early stages of tuberculosis of the lymphatic glands, radium treatment frequently causes a diminution in size and sometimes complete disappearance of the condition. Moderately deep radiations should be given. Between 100 and 200 mg. may be employed (1.25 mg. per sq. cm.) at a distance of 2 cm., screened with 2 mm. of lead, for about 30 hours in divided doses.

On numerous occasions we have introduced from 25 to 50 mg. in two or more tubes, screened with 1 mm. of silver, along the course of tuberculous sinuses leading to the bone. A total of from 4 to 8 hours has been given. Improvement has frequently followed. Other authors have reported the healing of such sinuses.

In military surgery Cameron and others have seen marked benefit follow the introduction into chronic sinuses of 10 mg. of radium in a

tube with a 1 mm. silver screen, for periods of from 10 to 30 minutes, repeated several times at intervals of 3 or 4 days.

RADIUM IN GYNÆCOLOGY

Fibromyoma of the uterus. In 1905 Abbe, of New York, first treated a fibromyoma by means of radium introduced into the interior of the uterus. Since that time the treatment of this condition with radium has so developed that it is now almost a routine procedure with those who have had experience with the method.

Exclusive of the cervical, submucous, or pedunculated varieties and those undergoing degeneration, radium treatment is now, in our opinion, the method of choice in the treatment of uterine fibromyomata. Prior to its use the absence of inflammatory conditions in the pelvis should be assured. A diagnostic curettage of the uterus to exclude malignancy and remove any polypi is also imperative.

Radium may be applied to the fibroid either by one or more intra-uterine applications, or it may be applied externally over the abdomen when the size of the tumor warrants the latter procedure. In certain cases these procedures may be combined. If there is great objection to intra-uterine applications, radium may be introduced into the posterior fornix and at the same time deep penetrating radiations may be given over the fundus uteri. The latter method has been successfully used by Hayward-Pinch of the London Radium Institute.

The amenorrhœa which one strives to produce should last, if possible, until the fibroid is practically gone, as the tumor may begin to grow again if menstruation returns. In a few cases the menses have reappeared after as long as two years. Under such circumstances the treatment should be repeated. If for any reason the treatment given has not sufficed to cause a cessation of the menorrhagia and metrorrhagia which frequently accompany the fibroid, it may be repeated in 6 or 8 weeks. It is possible by an intra-uterine application of sufficient intensity to destroy the endometrium without causing a cessation of ovarian activity. In this respect radium possesses an advantage over X-ray treatment as the symptoms of the menopause are slight under radium and pronounced under X-ray treatment.

To produce amenorrhœa ordinarily requires an application to the interior of the uterus of from 1,000 to 1,500 millicurie-hours. This means, with 100 mc. properly distributed over the interior of the uterus, a treatment of from 10 to 15 hours. The screening should be of 2 mm. of lead with 1 or 2 mm. of rubber.

Kelly has ordinarily used 500 mc. in the uterus for 3 hours. Hay-

ward-Pinch has applied about 50 mc. with a 2 mm. screen to the posterior fornix, together with the same quantity over the fundus. In his cases, exposures of from 30 to 60 hours, extending over a period of from 5 to 10 days, were given and the series repeated in 6 or 8 weeks.

By external radiations over the abdomen a result similar to that obtained from intra-uterine application can be produced. Employing this method, Kelly has successfully used 1,000 mc., 10 cm. from the skin, and distributed at various points over the abdominal tumor, for a total of 24 hours.

A satisfactory result may also be obtained by using 250 mc. (2.5 mc. per sq. cm.) at 10 cm. distance, screened with 2 mm. of lead, for 60 or 70 hours, divided into several treatments extending over a period of from 7 to 14 days.

Conservatively speaking, the results of radium treatment of fibroid disease of the uterus are most beneficial. Uterine hæmorrhage is almost always relieved and the size of the uterus is usually diminished. If radium fails, operation can be resorted to if indicated.

In chronic endometritis recovery may often be brought about by the intra-uterine application of radium. Several tubes containing a total of 50 mc., with a 1 mm. lead screen and 1 mm. of rubber, may be applied for 8 or 10 hours. The treatment may be repeated in 6 weeks if necessary. Endometritis which has resisted all the ordinary measures and which formerly was only curable by removal of the uterus will sometimes be completely relieved.

In metrorrhagia and menorraghia due to causes other than cancer and fibroid, radium is of the greatest value. S. M. D. Clark has reported fifty cases of this condition benefited by radium. In hæmorrhage in young women without definite etiology, in aggravated and intractable dysmenorrhœa, and in chronic metritis with bleeding, radium has given promise of complete relief. Dr. Leda J. Stacey of the Mayo Clinic has reported favorably on the treatment of menorraghia with radium.

Carcinoma of the cervix uteri. In clearly operable cases of cancer of the cervix we believe that hysterectomy with pre-operative and postoperative radium treatment is the method of choice. Janeway is of the opinion that radium treatment, even of early cancer of the cervix is justified, and some authors go so far as to state that treatment with radium should be substituted for operative treatment.

In cases in which the surgeon is in doubt as to the advisability of operation, radium treatment is probably the preferable procedure. In these cases long experience has shown that operative interference is not followed by good results. In some cases of this type and even in some cases that are strictly inoperable, radium treatment may render the case

operable. It is probably best, however, not to attempt to remove the uterus when a clinical recovery has occurred under radium.

"Uterine cancer continues to yield most gratifying results and the effect of radium treatment in inoperable cases is far in advance of those obtained by any other known medical or surgical methods." [1] Indeed, certain authors are of the opinion that 25 per cent of inoperable uterine and vaginal cancer can be cured by radium.

The clinical improvement of carcinoma of the cervix under radium is usually most striking. Relief from the hæmorrhage, the foul discharge, and pain is usually obtained. Disappearance of the fungating masses and healing of ulceration are often noted.

The technique of treatment varies with different cases, and almost every experienced worker with radium has, to some extent, an individual method. This variation illustrates the toleration of the cervix and adjacent tissues toward radium. It is noteworthy, however, that the enormous doses recommended by some writers have not infrequently been attended by untoward sequellæ, particularly by rectovaginal and vesicovaginal fistulæ.

A review of the different methods as practiced by Bumm, Cherons-Duval, Clark, Degrais, Janeway, Pinch, Schmitz, Wickham, and many others, seems to demonstrate quite clearly that moderate dosage causes the disappearance of the cancer quite as well as enormous doses, and without the untoward effects which may attend the use of very large quantities of radium. We believe also that several treatments are often preferable to a single treatment, although the effect may not seem quite so brilliant. Whether or not a certain amount of curetting should precede radium treatment in order to remove fungating masses is debatable. We believe it is not advisable. We are opposed to preliminary cauterization undertaken for the same purpose.

In the technique of treatment much depends upon the method of distribution of the radium with reference to the growth. When the radium is not too concentrated per unit area, larger doses are naturally tolerated. Burrows (Manchester and District Radium Institute) gives 3,000 millicurie-hours. He buries in the growth 6 or 7 platinum tubes with a wall thickness of 0.3 mm., containing 120 mc., and allows them to remain 24 hours. Hayward-Pinch (London Radium Institute) gives a total of about 1,600 millicurie-hours. One tube of not less than 53.6 mc. is introduced, if possible, into the cervical canal or, failing this, into the posterior vaginal fornix. The screening is 2 mm. of lead plus 2 mm. of rubber. Several treatments are given, the total exposure being from 24 to 30 hours. Janeway advises in average cases 6,000 millicurie-hours.

[1] Report of London Radium Institute.

He uses 300 mc. in three tubes inside the uterus, and three tubes containing 200 mc. over the cervix. The screening is the equivalent of 3 mm. of lead plus rubber. One treatment of 12 hours is given. Schmitz gives from 2,000 to 2,400 millicurie-hours in the cervix and from 24 to 36 hours later the same dose against the cervix. He uses 50 mg. in 2 tubes screened with 1.2 mm. of brass.

The writer's technique in average cases has consisted hitherto in giving about 3,000 millicurie-hours. One hundred mc., screened with 2 mm. of lead, are introduced into the cervix for 15 hours. Two subsequent exposures of 15 hours each with 50 or 75 mc. are then given against the cervix at intervals of 3 or 4 days.

It must be emphasized that there is no one technique adapted to all cases and equally good results may doubtless be obtained by different methods. The amount of radium at one's disposal and the convenience of application has doubtless had an influence in modifying the technique in certain cases.

We believe it is advisable to use, in addition to the intra-uterine and intravaginal exposures, heavy radiation over the abdomen, for example 300 mg., 3 mg. per square centimeter, for 30 hours, at a distance of 10 cm., with a 2 mm. lead screen.

In carrying out intravaginal treatment it is important to pack off well the posterior vaginal wall, as the rectum is especially sensitive to radium rays and treatment may otherwise be followed by more or less severe proctitis.

When treatment is undertaken for recurrences after extensive pelvic operations, the quantity of radium should be reduced by one half and the time of exposure by one fourth; otherwise the radium may cause a destructive reaction. Following intravaginal treatment, douches should be systematically given for at least 6 or 8 weeks to prevent the formation of adhesions. A second series of treatments 6 or 8 weeks after the first series is advisable, but these should be of less intensity.

John G. Clark draws a sharp distinction from the standpoint of treatment between cancer of the cervix and cancer of the fundus uteri. In the latter condition he advocates hysterectomy even though the disease is advanced. In the former condition he advises radium in all border-line and inoperable cases. Other authors advise radium in all border-line and inoperable cases irrespective of the location of the growth.

RADIUM IN DERMATOLOGY

We have already referred to the fact that radium rays may produce either a selective or an inflammatory reaction in the skin. By some

writers, the selective reaction, a process by which pathologic tissues are altered without visible inflammatory changes, is held to be the more important. The ease, however, with which the actual destruction of certain pathologic tissues can be produced leads us to place radium in the front rank as a destructive agent. Within certain limits radium is superior to the other common destructive agents used in dermatology, such as chemical caustics, the cautery, freezing with carbon dioxide snow or liquid air, electrolysis, etc. In actual dermatologic practice it can be seen that one may and often does combine the selective and destructive action of radium. A warning should be given, however, against the too free use of this destructive or cauterizing power when the cosmetic appearance of the tissues is to be considered. The possible development within the succeeding 8 or 10 months of telangiectases on the site of the healed lesion may detract greatly from the ideal result so much to be desired. These minute blood vessels are nearly always the result of too large doses.

Another detriment to the appearance of an area that has been too strongly irradiated is a depression or contraction of the skin. Fortunately even a scar resulting from too strong doses of radium is usually smooth, supple, elastic, and free from defects which follow almost every other kind of destructive measure. In favorable cases the color of the previously irradiated skin area is almost like that of the normal skin. A slight pigmentation may be present for a time, but this disappears sooner or later. In some cases the color of the tissues may be too white or may vary in different areas. Instead of an appearance almost like the normal skin there may be varying degrees of smoothness and whiteness due to atrophy or destruction of the follicular structures, and the replacement of normal elements of the skin by connective tissue. From a practical point of view, the inflammatory reaction due to radium should be reduced to the minimum in the treatment of most dermatoses and, whenever possible, should be avoided altogether.

"From the histologic point of view, the action of radium on the integument (at least in therapeutic applications) can be shown to produce the same effects whether the condition of the skin be normal or diseased. The normal and pathological elements of the epidermis are absorbed by degrees and disappear, whilst the overlying malphigian epithelium persists. The cells of the vascular connective tissue, whether normal or modified by inflammation or a carcinomatous process, have an alternating evolution. In the first stage, they return to the state of embryonic connective-tissue cells; in the second, they again arrive at maturity under the form of elongated fibroblasts, which are superimposed and follow the regular lines of stratification, again forming connective-tissue bundles and elastic fibers." (Dominici and Barcat.)

The main groups of dermatoses in which radium offers a possibility of use are malignant tumors; benign tumors; chronic infections; inflammatory and granulomatous infiltrations of uncertain nature; hypertrophies; neuroses; disorders of the sebaceous glands, hair, and hair follicles. In nearly all of these conditions radium has already a well established field of action.

Malignant tumors. Besides epithelioma, carcinoma, and sarcoma, which have already been considered, other malignant growths of the skin, such as Paget's diseases, xeroderma pigmentosum, and mycosis fungoides may be greatly benefited by radium.

Benign tumors. Keloids and certain cicatricial bands are very favorably influenced by radium. In true keloids of recent formation, and especially in children, a very excellent result is frequently obtained. Sometimes the skin may be quite normal in appearance after involution. In some cases the treated area is too white and in others too red, and there may be a smooth, glazed appearance which, although differing from normal skin, is not unsatisfactory compared with the keloid itself. Usually the keloid is levelled and decolorized, and pain is completely relieved. Compared with other methods of treatment, it is not too much to say that radium is easily the method of choice in this condition. In keloids mixed with scar tissue, the prognosis is not so favorable. More intensive treatment must then be given and actual destructive doses sometimes used. A similar technique must naturally be used when fibrosclerotic bands exist alone.

With true keloids selective doses may suffice and are always to be preferred. The technique of treatment varies greatly according to the age of the patient and the size and duration of the keloid. A tentative course of treatment may first be given, as some of these growths yield very easily. One-quarter or one-half strength glazed applicators may be used, screened with 0.1 mm. lead, and a course of 2 or 4 hours in 6 periods may be given. In children, one-half or one-fourth of this dose should be used at first. In some keloids of considerable thickness, radium salts or emanation in tubes instead of glazed plaques may be used advantageously. With a concentration of 5 mc. per sq. cm. at a distance of 6 mm., with a 1 mm. lead screen, radium may be applied for 8 or 10 hours, divided into several periods, provided an area not larger than 20 sq. cm. is treated. The series of treatments may be repeated in 6 weeks, but subsequent courses should be of less intensity.

With fibrosclerotic bands, the doses suggested above may be slightly increased so as to cause an actual destructive reaction. This should be done, however, only when the milder doses have failed, and with the understanding that destructive doses may cause a reaction requiring weeks

to heal and that telangiectases may eventually occur. Even under these circumstances the final result may be much preferred to the original lesion.

The treatment of angiomata and lymphangiomata with radium has in most cases supplanted all other methods of treatment. Even the more modern methods, such as the injection of boiling water or hydrogen peroxide, destruction by liquid air, carbon dioxide snow, and electrolysis are more or less painful, and by no means ideal, particularly in children. While a certain place is left for all of the other well-known and well-proved methods, radium is on the whole our most satisfactory agent in dealing with angiomata and lymphangiomata. Certain of the more painful of the methods mentioned above are little short of barbarous, especially in extensive cases, and should, in our opinion, be unqualifiedly condemned. Radium is painless and efficient, and the cosmetic result in many cases is excellent. Not all cases respond equally well, but in favorable and selected cases a good result may be anticipated. In certain cases of port-wine stain I now combine the use of radium and the Kromayer lamp.

In considering the treatment of angiomata with radium from a clinical standpoint, we may follow the grouping suggested by Wickham and Degrais. These authors divide vascular nævi on the basis of treatment into: (1) Flat, superficial angiomata, level with the skin; (2) flat, deeply infiltrating angiomata, level with the skin; (3) raised angiomata which present a hard and more or less sclerotic surface; (4) raised angiomata which are soft, and often pulsatile and erectile; (5) deep, subcutaneous and submucous angiomatous tumors. This classification represents the more common types, though they tend to merge into one another and different forms may be present in the same person.

The method of treatment varies with the type. For superficial angiomata nothing equals the *toiles* or glazed plaques. For deep tumors tubes may be employed, although the flat applicators answer equally well.

In the treatment of flat superficial angiomata we cannot insist too strongly upon the avoidance of inflammatory reaction. The production of slight redness and scaling of the skin is permissible, but endeavors to bring about more rapid results by strong treatment will only be fraught with disaster. At the beginning of treatment one may use, for example, a one-twentieth strength *toile* with a 0.01 or 0.02 mm. aluminium screen for 3 or 4 hours, divided into periods of an hour each on successive or alternative days. In children one-half of this dose should be given. If a slight fading occurs within 6 or 7 weeks after the last treatment, sufficient will have been accomplished. A second course of treatment may then be given, but subsequent courses should always be of slightly less in-

tensity. With no group of cases is a more refined and skillful technique necessary in order to accomplish good results.

The method of treating flat, deeply infiltrating angiomata is similar to that employed in the first group, except that it is permissible to use stronger doses. Angiomata of the first group can be quite well concealed by the artifices of the toilet. Angiomata of the second group are often so deeply colored and unsightly that no amount of artificial coloring or dis-

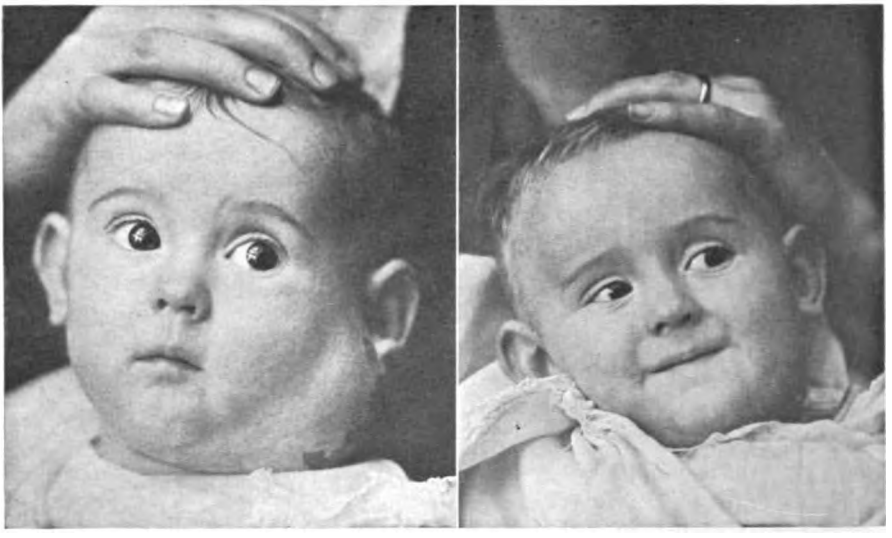

FIG. 215. PHOTOGRAPHS OF PATIENT WITH CUTANEOUS AND SUBCUTANEOUS ANGIOMA. Photographs taken October, 1918, and May, 1919, before and after radium treatment was given.

guise really conceals them. Hence, we are justified in proceeding somewhat more boldly. With the same apparatus and screen we may apply radium for 5 hours in periods of an hour each on successive days. With one-fourth strength apparatus, screened with 0.1 mm. lead, we may give 3 or 4 hours total exposure. Here also severe reactions should be avoided. In subsequent courses, instituted six weeks or two months after the preceding series, the screening may be increased to 0.2 mm., and a total of 5 or 6 hours given in several periods. Good results in this group are difficult to accomplish, but in some cases the final appearance is excellent.

The third group, including the raised hard angiomata, comprises a considerable number of clinical types with no exact limitations. Their size and extent vary greatly. In some of them the surface may be smooth: in others it is papillated and irregular. A varying degree of hardness is

noted on palpation, some being quite sclerotic. In this group one is justified in producing definite reaction. With one-fourth strength applicators, an exposure of two hours with the applicators unscreened, or of five hours with the applicators screened with 0.1 mm. lead, may be given as a first course. When the reaction subsides, a less intensive course with a screen of 0.2 mm. may be used.

In the fourth group are included variously sized tumors. A frequent type is the cavernous angioma often seen in infants. It is elevated one or more centimeters above the skin level, and frequently is limited to several square centimeters in extent. In more extensive cases the entire side of the head may be involved so as to cause great deformity. It is in this group that radium is particularly satisfactory in its effects. One should endeavor to utilize to its fullest extent the selective action of radium, and success frequently attends the use of doses that are in nowise destructive or productive of more than the slightest reaction. The cross-fire device suggested by Wickham is especially useful. With one-fourth strength applicators, screened with 0.1 mm. of lead, applications of 3 or 4 hours, divided into several periods, may be given over one area. The course may be repeated in 6 or 8 weeks. In the case of very extensive tumors in infants 2 hours may be sufficient for the first course and less for subsequent courses.

With deep subcutaneous and submucous tumors very extensive growths may be treated successfully if the proper method is used. It is best to treat separate sections of the tumors successively, so as not to give an over-dosage. Tubes are particularly effective in this type of tumor, although plaques are equally successful.

With a concentration of 5 mc. per sq. cm. at a distance of 12 mm., with a 2 mm. screen, a single area of 30 sq. cm. may be treated for a total of 12 hours in several periods of 2 or 3 hours each. The method of cross-firing should be utilized to the utmost in order to spare the skin. At intervals of 6 or 8 weeks subsequent courses may be needed, although 2, or at most 3 courses are usually sufficient. Often large angiomatous tumors may be made to disappear without inflammatory reaction and with little involvement of the overlying skin.

Lymphangiomata yield in excellent fashion to radium. Abbe reported the first cases in 1915 and the following year I reported an extensive case successfully treated. When the mucous membranes, particularly of the tongue, are affected, radium is of unique value and can hardly be replaced by any other agent. The method of treatment is similar to that for hard, raised angiomata.

Nævus pigmentosus. Only pigmented nævi more than several square centimeters in area are amenable to radium. Growths that are

very unsightly in consequence of rugosities, much thickening, the presence of hair, and dark pigment may well be subjected to radium. Radium has no special selective action on pigmented nævi, and in order to bring about their disappearance destructive doses must be used. The final result may not be so good as in angiomata, since the healed skin may show uneven coloring and even points of excessive pigmentation. We would, therefore, not recommend the use of radium in faintly pigmented nævi, but in selected cases of disfiguring growths an excellent result may be obtained. Great care should be used in the treatment not to give excessive doses. With one-fourth strength applicators treatment for 1 or 2 hours may be given without screening, followed by treatment for 2 hours with a 0.1 mm. lead screen. This produces a slightly destructive action. The treatment may be repeated, but with less intensity, in 8 weeks. Compared with other methods of treatment, radium offers an excellent prospect of relief. The final result will depend very largely upon the judicious selection of cases and upon the skill and care with which the treatment is carried out.

In various other disorders of the skin usually classed as benign tumors, radium has been found of value. Among these may be mentioned especially linear nævus, in which radium is of the greatest value. In addition, dermatitis papillaris capillitii, molluscum contagiosum, multiple benign cystic epithelioma and xanthoma are all susceptible to radium.

Chronic infections. In certain types of tuberculosis of the skin radium is of value. Tuberculosis verrucosa cutis responds well. Destructive doses with one-fourth strength applicators and a 0.1 mm. screen given for 5 or 6 hours in divided doses, must be used. In lupus vulgaris radium is only of limited use, being, in the writer's judgment, distinctly inferior to the Finsen light. The best plan of treatment is probably to use one-fourth or one-half strength glazed applicators with a 0.1 mm. lead screen. A total of 5 or 6 hours may be given in fractional doses. Only small lesions should ordinarily be treated at first. We have seen large lupus patches increase at the border under radium treatment, because of insufficient doses. It is the general experience that radium has little or no selective action on lupus tissue, which responds, as a rule, only to caustic or destructive doses. In lupus vulgaris of the mucous membranes, radium often has a beneficial effect. Doses of less intensity than for the skin should be used.

In 1914 the writer reported the first case of blastomycosis of the eyelid successfully treated with radium. Since that time several other cases have been treated. A similar but less intensive treatment than that for tuberculosis is efficient.

In occasional cases of obstinate syphilides, Wickham, Degrais, and

others have found local radium treatment beneficial. The technique is similar to that described above for tuberculosis.

Inflammatory and granulomatous infiltrations of uncertain nature. In certain groups of dermatoses of inflammatory or granulomatous nature, radium is of considerable value. In psoriasis, lichen planus, lichen chronicus simplex, chronic eczema, lupus erythematosus, etc., radium treatment offers in selected cases a great amount of relief.

In psoriasis of the nails radium is particularly useful. In obstinate patches of psoriasis in almost any situation not involving too large an area, radium may be used in a similar manner to the X-ray. It must be understood, however, that neither radium nor any other measure prevents recurrence of the patches. With one-fourth strength applicators screened with 0.1 mm. lead, treatment for 1 or 2 hours and often less, in divided doses, is usually sufficient to cause involution. Inflammatory reaction should be avoided.

In cases of lichen planus confined to small areas radium often relieves the itching and hastens involution. In lichen planus of the mucous membranes radium is especially valuable. The technique of application is the same as for psoriasis. Not more than one-fourth of the dose employed on the skin should be used on lesions of the mucous membranes.

In lichen chronicus simplex, radium often gives the most striking relief, the itching frequently disappearing very promptly. Short applications with one-fourth or one-half strength glazed applicators, unscreened, are advisable. Two or three exposures, each lasting from 3 to 10 minutes, and repeated at intervals of a week, are efficient. Inflammatory reaction should be avoided. Certain cases of chronic eczema may yield to similar treatment.

The writer has treated more than 50 cases of lupus erythematosus with radium. In this curious and puzzling disease radium is one of our most valuable agents. Considerable judgment is necessary, and caution should be practised until the degree of irritability of the individual case is determined. Most cases require only a moderate reaction to produce involution. The method of treatment is usually with one-fourth strength glazed applicators, screened with 0.1 mm. of lead. Half-hour exposures are given on successive or alternating days until 4 or 5 treatments have been given. The effect is noted and the treatment is repeated as soon as the reaction is over, i.e., in from 2 to 4 weeks. Care must be taken that the edge of the applicator overlaps by at least 5 or 10 mm. the visible edge of the disease. This treatment is usually adapted only to the cases of fixed type. Freedom from the disease for several years may be attained in certain cases. In other cases, relapse may occur in a few months, or

even sooner. In leukæmia cutis radium is of value and may cause resolution just as in the leukæmic spleen.

Hypertrophic diseases of the skin. In many of the disorders classed as hypertrophies, radium is of considerable value. In clavus, callositas, and the various keratoses (keratosis senilis, X-ray keratosis, angiokeratoma, etc.) radium is of the greatest use. The general method of treatment of these disorders is to use one-fourth strength applicators, unscreened, for from ½ to 2 hours, or with a 0.1 mm. screen for 3 or 4 hours.

Among affections often regarded as trivial, the subungual and periungual wart, and the palmar and plantar wart deserve special mention, the latter particularly because it may cause great distress and pain on walking. All of these types are peculiarly resistant to the ordinary dermatologic measures. As a rule, all yield easily to treatment with radium. One-fourth strength glazed unscreened apparatus applied carefully for from ½ to 2 hours is usually sufficient. A still better method, requiring more time but causing little reaction, is to use the same apparatus with a 0.1 mm. screen for 4 hours in exposures of 1 hour each.

In certain rare disorders, such as acanthosis nigricans and Darier's disease, radium would undoubtedly be of benefit in so far as the removal of localized areas of the disorder is concerned.

Neuroses. We have already spoken of the relief obtained by the use of radium in certain persistent, itching dermatoses, notably lichen chronicus simplex, lichen planus, and eczema. There are other disorders classed as neuroses in which the subjective symptoms are prominent, but in which little or nothing is seen objectively except the results of scratching. Localized pruritus, such as pruritus ani and pruritus vulvæ, is frequently relieved by radium. In these affections the best method of treatment is by means of unscreened glazed apparatus. Exposures of 5 or 10 minutes, repeated several times at intervals of a week, may be given. The total application should never be sufficient to produce an inflammatory reaction. We have seen excellent results in a number of cases. In various other affections, the analgesic action of radium has been made use of. In hyperæsthesia, following herpes zoster, in neuritis and in intercostal and sciatic neuralgia, Wickham found radium of value. He used approximately one-fourth strength apparatus, screened with 0.1 mm. of aluminium, and gave applications of from 10 to 60 minutes. Reaction in the skin should be avoided.

Disorders of the appendages of the skin. In selected cases of acne rosacea radium is of value. In rhinophyma very good results have been obtained by Wickham and Degrais and others. In these cases, one-fourth strength glazed applicators are usually employed and a slight

reaction produced. With a 0.1 mm. lead screen, a total of 2 or 3 hours in fractional doses will usually be sufficient for the first course, or until the effects are seen. Subsequent courses may be given at intervals of from 3 to 6 weeks. We have also seen good results follow the local treatment of acne varioliformis, although the formation of new lesions is uninfluenced. In hyperidrosis radium is sometimes of value. The glazed plaques are the most convenient form of applicators. Inflammatory reaction should be avoided.

In the extreme cases of hypertrichosis, which may cause so much mental anguish as to wreck the happiness of the individual, radium may occasionally be employed. As a rule, however, in order to produce permanent alopecia a degree of atrophy must be produced which is undesirable, and in addition telangiectases may result. In selected cases very excellent results may be obtained. In cases in which temporary alopecia is desired, as in ringworm and sycosis vulgaris, radium may be used instead of the X-ray, though often inferior in convenience to the latter agent. Radium is safer, however, in inexpert hands. With a concentration of tubes of about 5 mg. per sq. cm., with a 1 mm. lead screen and 5 mm. of rubber, temporary alopecia may be produced by an exposure of about 10 hours in fractional doses. In children the dose should be reduced by one-half until trial has been made of the effect in the individual case. Only small areas, for example 6–12 sq. cm., should at first be attempted.

RADIUM IN OPHTHALMOLOGY

Epithelioma of the conjunctiva has been successfully treated by Wickham, Degrais, and others. The treatment of sarcoma of the orbit has already been discussed. In vernal conjunctivitis radium is of the greatest value. Some times the most rebellious cases are completely relieved. A full strength applicator (5 mg. per sq. cm.), varnished or glazed, may be employed unscreened and a fifteen-minute exposure given. In two weeks this may be repeated, but only if inflammatory reaction has been slight or absent. Instead of the above applicators, radio-active deposit may be collected on lead foil and used in a similar manner.

Radium is often of benefit in trachoma. The technique of application is similar to that for vernal catarrh.

Cohen and Levin have reported upon the use of radium in 24 cases of cataract and claim improvement in 87.5 per cent of the cases. The exact technique is not given other than to state that gamma rays only were utilized, and that the radium was applied over the closed eyelid at 2 cm. distance. Confirmation of the report is hoped for.

RADIUM IN OTOLOGY AND LARYNGOLOGY

In granulomata and papillomata in the external auditory canal, radium frequently is of great value. We have treated a number of cases in which recovery has been brought about. In tinnitus aurium radium has not been of marked benefit. Little can be expected from the treatment of chronic deafness due to middle-ear disease. In conjunction with Dr. O. T. Freer we have treated numerous cases of this type without definite benefit.

In carcinoma of the upper larynx (so-called extrinsic carcinoma), the results have been encouraging. The most effective method of radium application is the introduction of radium needles, each containing 12 mg. of radium element, or 12 mc. of radium emanation, directly into the growth. The needle introducer devised by Dr. O. T. Freer is invaluable for this work. The needles may be left in place for from 8 to 12 hours. In one case of extensive carcinoma involving the epiglottis, base of the tongue, and left vallecula complete recovery was achieved. There has been no local recurrence after more than two years. A recurrence in the glands of the neck one year ago yielded to radium so that the patient is now clinically well. This case has been previously reported by the writer.

In intrinsic carcinoma of the larynx, radiation from the outside may be employed. Kelly and Burnham have referred to several cases which have recovered and remained well for varying periods. Abbe has reported a remarkable and successful case of papilloma of the vocal cord in which complete relief was obtained. Sarcoma of the larynx may be treated in a similar manner to carcinoma.

In the treatment of laryngeal tuberculosis the results have varied. In a case treated in connection with Dr. O. T. Freer some years ago with radium held in the larynx by a laryngeal applicator (50 mg. with a 1 mm. screen for a total of 3 hours), no result was obtained. In a case of probable laryngeal tuberculosis recently treated, in which two small lesions on the right vocal cord were present, a good result was secured. In this case radiation was entirely external (150 mc. 1 cm. distant, with a 2 mm. screen, for 30 hours).

Dr. O. T. Freer has recently devised an ingenious contrivance made of copper wire for holding a powerful emanation tube in the larynx. One tube may be held in the larynx and another in the fossa pyriformis at the same time by means of this device. It is especially useful in the presence of laryngeal tuberculosis, chronic laryngitis, papillomata, and other benign growths. During intralaryngeal applications the throat must be kept clear of saliva by means of a strong electric suction pump acting continuously.

RADIUM IN DISEASES OF THE DUCTLESS GLANDS

Leukæmia. In splenic and lymphatic leukæmia the remission of symptoms is frequently very satisfactory. Ordway states that radium therapy in leukæmia is the best form of treatment now at our disposal and the writer's experience in a considerable number of cases confirms this view. The enlarged spleen may be reduced to normal and the lymphatic glands may be so diminished in size as to be practically non-palpable. The blood picture may also become quite normal.

Even when treatment with benzol and the X-ray fails, radium may still produce an apparently complete remission. Numerous cases have now been reported by Giffin, Ordway, Peabody, Pinch, and many others, including ourselves. The technique of treatment is simple, and while similar results may be obtained by different methods it is our belief that too large doses should be avoided in ordinary cases. The radium may be applied successively to different areas over the spleen or to the lymphatic glands, as the case may require. Although some advocate radiation of the long bones in myelogenous leukæmia, this has not been thought advisable, or in our experience necessary in order to produce remission. Ordway has carefully described his technique which is similar to that used by certain French workers. An applicator of double or triple strength (50–60 mc. concentrated on 4 sq. cm.) was used. With this the spleen was covered by radiating successively every 9 sq. cm. of skin surface. The metal filter was 3 mm. of lead and the distance obtained by interposing 15 or 20 thicknesses of filter paper, or 25 or 30 layers of gauze, from 5 to 10 mm. thick. Exposures of 5 or 6 hours over each area were given. Three series of treatment were given from 4 to 6 weeks apart. The small amount of radium used is noteworthy.

As much as 200 mc. of radium (1.25 mc. per sq. cm.) may ordinarily be used if it is available. Screened with 2 mm. of lead and at 3 cm. distance an exposure of 12 hours a day every other day may be given over successive areas until the splenic area has been covered. The course may be repeated in 6 weeks, or earlier, if thought advisable. Complete or nearly complete remission may be expected in from 3 weeks to 3 or 4 months. It is not advisable to reduce the leukocyte count to less than 20,000 or 30,000 per cu. mm. Patients may remain apparently well for several months or even several years. Recurrences may take place, but these usually yield, at least for a time, to further treatment. Surgical removal of the spleen has been advised when the remission of the disease is at its height. In one of the writer's cases of leukæmia of acute fulminating type, radium produced little or no effect, although previously complete remission had been brought about.

Hodgkin's disease (lymphadenoma). In this disease the affected glands frequently disappear very promptly. In only one of eleven cases treated have we seen failure to respond to treatment. In two cases of that form of the disease in which nodular tumors appear on the bones very marked susceptibility to the radium rays was noted. In several cases we have seen remissions which have persisted for more than a year. It is probable, however, that recurrence takes place sooner or later in most cases.

To obtain satisfactory results one must ordinarily employ powerful deep radiations. The enlarged glands may be treated serially in order to spare the patient as much as possible the nausea, malaise, and fever which frequently follow heavy doses. As much as 250 mc. (2.5 mc. per sq. cm.) 6 cm. distant, with a 2 mm. screen, may be used for a total of 30 hours in divided doses. Treatments may be given every other day, or less often, until the entire areas involved have been radiated. Occasionally daily treatments may be given for 5 or 6 days if the systemic disturbance is slight.

Exophthalmic goiter. Numerous writers have now reported favorably upon the results of radium treatment of exophthalmic goiter. Among these may be mentioned Abbe (who treated the first case in 1905), Dawson Turner, and Aikins. Radium may be used when the ordinary methods prove unavailing, or when operation is considered inadvisable. In cases which respond favorably, improvement in all the symptoms may be noted in 6 or 8 weeks. Tachycardia, tremor, and exophthalmos are frequently diminished. In some cases operation may be performed, if thought advisable, after a certain degree of improvement has been brought about by the radium. The method of treatment involves the use of moderately deep penetrating rays.

Between 100 and 200 mc., concentrated on an applicator having a superficial area of 50 or 100 sq. cm., at a distance of 2 cm., with a 2 mm. screen, may be used for a total of 30 hours in 2 or more exposures. The course may be repeated, if thought advisable, in 6 weeks.

RADIUM IN INTERNAL MEDICINE

Interesting investigations have been undertaken by various workers to determine the constitutional effects of radium and its value as a therapeutic agent when taken in solution or injected intravenously.

Bellingham-Smith has shown that radium injected into mice is excreted principally by the small and large intestine and by the kidneys. Ketron found that a very minute quantity only (0.025 micrograms) was eliminated by the skin after the intravenous injection of 100 micrograms.

Seil, Viol, and Gordon have confirmed Bellingham-Smith's experiments. The same authors have also studied the rate of excretion of soluble radium salts. They state that from 25 to 35 per cent of the radium taken by mouth remains in the body 4 or 5 days after injection, while with radium injected intravenously, from 55 to 65 per cent remains for the same length of time. From this time on the rate of elimination is about the same, whether ingested or injected. By the tenth day the daily rate of excretion is less than 1 per cent. On the basis of these studies these authors suggest a rational method of maintaining radium in the system. If it is desired to maintain 50 micrograms of radium in the body, one may give an intravenous injection of 100 micrograms and, after 10 days, 2 micrograms by mouth every 2 days to replace what is excreted.

While it is generally stated that metabolic changes in the tissues are more rapid during the administration of radium, the studies of McCrudden throw some doubt upon this statement. In three patients whose metabolism was studied while taking radium emanation water (3 ounces 5 times a day or 20,000 mache units in all) no marked metabolic change was determined. Only one definite change was observed—a slight increase in the rate of creatinine excretion. Rosenblum, who also studied the result of an intravenous injection of 100 micrograms of radium element, found considerable increase in the ethereal sulphur output. Further research, however, is necessary in order to determine the effect of radium salts on metabolism.

Radium salts are usually administered by giving water containing the salt in solution, or by injecting the salt intravenously. The drinking water usually contains one microgram of radium element in 30 c.cm. of distilled water; the ordinary dose is from 120 to 240 c.cm. per day. For intravenous injection from 50 to 100 micrograms of radium element in 2 c.cm. of normal salt solution may be used. Injections are usually given every 8 or 10 days until the patient has received 300 micrograms.

Radium emanation may be administered by inhalation, by baths, or by means of drinking water in which the emanation is dissolved. With the inhalation method the patient may sit in a small room, the air of which is impregnated with the emanation mixed with oxygen. The air which is breathed is purified by being passed over caustic soda, but respiratory products are continually being reinhaled. With another method the patient inhales a stream of air or oxygen mixed with emanation and exhales it into the open air by a valve arrangement. This is an improvement but rather wasteful. The quantity of emanation in the air inhaled varies from 0.003 to 0.8 microcuries per liter of air. Inhalation treatments may last an hour or more. Emanation baths may be given, but the good effects claimed seem to be due solely to the emanation that is inhaled. Radium

emanation in solution may also be given by mouth, the strength of the solution being usually 1.5 or 2 mc. per liter of water. About 250 c.cm. daily is the usual dose.

The results of treatment by the inhalation method seem to differ in nowise from those obtained by the administration by mouth of emanation drinking water. Whether a radium salt or radium emanation is taken the effect is practically identical, except that the action of the emanation is more evanescent on account of its rapid decay.

One of the chief benefits derived by patients' taking radium seems to be a feeling of *bien être*. Whether or not this is entirely subjective, it is difficult to say. The blood pressure is lowered, at least temporarily. There is an increase in the hæmoglobin and erythrocytes, and a decrease in the leucocytes. The majority of patients taking emanation in solution have a definite diuresis and a slight tendency toward diarrhœa.

Hayward-Pinch has reported very favorable results from the administration of emanation drinking water in arthritis deformans, especially in relieving pain and in increasing the mobility of the joints, provided no bony or cartilaginous changes have occurred. In some cases the results have been quite remarkable. The same author has seen good effects in angioneurotic œdema. Cameron has seen favorable results in various types of arthritis. Beneficial effects have been reported in gout, Bright's disease, and diabetes. Proescher recommends, on the basis of experimental studies, injection of soluble salts of radium in pernicious anæmia, and leukæmia. Other authors have seen good effects in chlorosis and other forms of anæmia.

While it has been claimed that good results have followed the internal administration of radium in cancer, there is no convincing evidence of this assertion. For the present we must rely in malignant disease solely upon the effect of local radiations with radium rather than upon its constitutional effects when ingested or injected into the body.

INJURIES DUE TO RADIUM

Both local and systemic injuries may be caused by radium. We have already described the phenomena resulting from the action of radium rays on the skin. These effects are known as the radium reaction.

Everyone who has had experience with radium knows of the ease with which inflammatory reaction may be produced when the time of the application has been unduly prolonged or when overdosage from error in technique in any particular has occurred. Inflammatory reactions of severe type may require as long as 8 months or more to heal. Up to the present time the writer has not seen radium reactions which did not sooner

or later cicatrize. We have emphasized the importance of avoiding overdosage in order to spare patients this painful complication, which may even be dangerous when an important organ is injured. An event which has been too little commented upon is the possible occurrence of late or deferred radium reactions, developing many months or even a year or two after a severe radium reaction. On the site of a cicatrized or even an atrophic surface we have several times seen this painful effect develop. In a periosteal sarcoma of the pelvis treated with very large doses a severe reaction of the skin of the abdomen developed which required 8 months to heal. Upon the site of the former burn a radium dermatitis developed spontaneously 2 years subsequently. This dermatitis took the form of a superficial ulceration accompanied by the formation of a pultaceous, adherent mass of necrotic tissue, and required three months for healing. In the treatment of severe skin reactions the writer has found an application containing zinc oxide 5 gms., bismuth subnitrate 5 gms., lanolin 12 gms., olive oil 60 gms., and liquor calcis 60 gms., of some benefit in relieving the subjective symptoms. Irritating applications should be avoided. In fact, in most cases it is best to make no local applications, but to expose the inflamed area to the air and allow nothing, not even gauze dressings, to come in contact with it.

Many workers with radium suffer from a chronic dermatitis, especially of the finger ends, which are not infrequently exposed in the various manipulations required in making therapeutic applications. These have been well described by Ordway, who mentions "flattening of the characteristic ridges, thickening and scaling of the superficial layers of the skin, and even atrophy and intractable ulceration" as the chief objective signs. An additional phenomenon which we have many times observed consists in the formation of tiny wart-like epithelial tumors. These may project several millimeters above the level of the skin and are not unlike senile keratoses of a certain type. These thickened epithelial wart-like growths cannot be scraped off except with the greatest difficulty, and when this is done there is left a depression reaching nearly or quite to the corium. Even when removed, these epithelial thickenings sooner or later recur and may persist for years, becoming worse or better as the individual is more or less exposed to the rays. We have not seen as yet any reported case of epithelioma supervening on these radium keratoses. Subjectively the affected finger ends may show "anæsthesia, paræsthesia of varying degrees, tenderness, throbbing, and even pain. The persistence of such effects is noteworthy." (Ordway)

In addition to local effects, laboratory workers or those exposed more or less continuously to the rays from radium may show various systemic symptoms, such as headaches, malaise, nervousness, attacks of dizziness,

menstrual disorders, etc. These symptoms, when occurring in workers in radium, have been regarded by Gudzent, Halberstaedter and others as probably due to the persistent exposure to the rays. Blood changes also may be produced. Sooner or later there is invariably a leukopænia in radium workers. The leukocyte count may fall as low as 1000 per cu.mm. In a few cases the hæmoglobin and the number of red blood cells have been found decreased. Further study is needed of the systemic disturbances due to radium, but enough has been observed to show the need of great precautions on the part of those extensively engaged in radium work.

Radium tubes and other apparatus should always be handled with special forceps and those engaged in the technical part of radium manipulations should be protected by lead plates at least 5 cm. thick and large enough to shield the body. Absence from contact with radium for at least two days per week and frequent vacations of a month or longer are imperative.

SECTION XV

LOCALIZATION AND EXTRACTION OF FOREIGN BODIES UNDER X-RAY CONTROL

BY

JAMES T. CASE, M.D., F.A.C.S.

Professor of Roentgenology, Northwestern University Medical School; Surgeon, Battle Creek Sanitarium; formerly Senior Consultant in Roentgenology for the American Expeditionary Forces.

CHAPTER I

THE LOCALIZATION AND EXTRACTION OF FOREIGN BODIES UNDER X-RAY CONTROL

THE development of methods for accurate localization of projectiles and other foreign bodies was one of the earliest phases of the application of the X-ray to medical work. Not more than five years passed following the discovery of the X-ray before combined surgical and radiological methods were devised for the extraction of projectiles. Though civil surgery affords relatively infrequent opportunity for the surgeon or the radiologist to put to actual test the methods of localization which are to be found in every textbook on radiology, the recent war afforded an extraordinary multiplicity of occasions for studying foreign body cases, and enforced a careful analysis and modification of the more than two hundred procedures which were described in the medical press early in the war.

Some of the procedures described are complex, some are simple; some require complicated apparatus or special instruments, while others may be carried out with any of the ordinary types of X-ray equipment; some require the aid of radiographic plates, while others are screen methods quickly performed and affording an instant answer to the surgeon's query as to the presence or situation of the offending foreign substance. Out of the war have arisen systematized localizing procedures, with standardized apparatus especially adapted to the expeditious handling of large numbers of wounded men. Some of the standardized types of apparatus developed for military work are already being used in our civil hospitals, and the general trend of manufacture of X-ray equipment is toward the simpler instruments developed during the war.

It is the purpose of the writer to set forth briefly only those methods most readily learned and carried out with a minimum of accessory instruments. Explanations of geometrical propositions are, for lack of space, reduced to a minimum. Any reader interested in the details of such mathematical propositions will find discussions in the various excellent treatises on localization which have been prepared by the medical departments of the various allied armies.[1]

[1]Ombrédanne, L., and Ledoux-Lebard, R. Localization and extraction of projectiles. London, 1918.
United States Army X-Ray Manual. New York, 1918.
Delherm, Louis, and Rousset, J. Le repérage des projectiles. Paris, 1918.
Nogier, T. Localization et extraction des projectiles de guerre. Lyon, 1918.

Magnets, vibrators, and telephone probes have been variously recommended by military surgeons but they are limited in their usefulness. Magnets, for instance, are applicable only to the localization and extraction of such metallic foreign bodies as are responsive to magnetic attraction, whereas the radiologic method should discover all metallic foreign bodies (with the possible exception of aluminum), besides many nonmetallic substances. The radiologic method as a part of the surgical procedure lends itself admirably to helping the surgeon during the extraction of any foreign body, whereas the magnet and vibrator methods above referred to have the same limitations in respect to nonmagnetizable substances.

The person undertaking a localization should by no means confine himself to an estimation of the depth of the foreign body, but should acquire all possible information afforded by an X-ray study of the case. For the best results it is essential that the radiologic work be done by a physician, or better still, the surgeon should be familiar with the radiologic procedures involved in foreign body localization; indeed, there is such temptation for the surgeon himself to go ahead with the radiologic part of the extraction procedures that unless he has a thorough technical knowledge of the subject, he is likely to harm himself through inadvertent over-exposure to the rays. These dangers will not be discussed here as they are fully described in numerous textbooks.

Localizations are usually accomplished by fluoroscopic methods, although there is no objection to radiographic methods other than that they involve more time and expense and are not so informing as the screen methods. Stereoscopic radiograms are more valuable than single plates.

A localization should afford the following information:

1. Anatomical data, showing the relation of the foreign body to neighboring structures, such as a trochanter, a condyle, or some other well known bony point; to a muscle; or to an artificial opaque marker affixed to the skin.

2. Mathematical data as to the depth of the foreign body in relation to marks or markers on the skin.

3. Directions which will guide the surgeon to the foreign body. This guidance is frequently afforded by the fluoroscope through observations made during the removal of the foreign body.

The following localizing methods will be considered:

1. Rotation of the part; study of the movements of the shadows of the projectile or other foreign body in relation to neighboring opaque structures or skin markers.

2. The "nearest point" method.

3. The parallax method, which is often combined with the nearest point method.

4. The orthodiagraphic method, which is also often combined with the nearest point method.

5. The method of right-angled planes (four-point survey).

6. The multiple diameters method.

7. The single-shift triangulation method, with which may be included the stereoscopic method.

8. The double-shift fixed-angle methods.

9. Harpooning methods, combined with reconstruction of the part by the aid of a cross-section anatomical atlas.

There are numerous other methods which might be described, but the above-mentioned are all very simple, easily learned, quickly performed, and accurate to within a half centimeter, without the aid of

FIG. 216. PALPATOR MADE FROM A SMALL WOODEN ROD, WITH A SCREW AND A SCREW-EYE.

plates. There is no reason why one or more radiograms of the part should not be made if the surgeon so desires, especially if he has not been present at the X-ray localization. If such plates are made, they should be stereoscopic plates.

Apparatus required. In addition to the usual current-generating apparatus of any type supplying a milliampere or more of current through a tube of sufficient hardness, and a horizontal or vertical fluoroscope installed in a room capable of being completely darkened, the following items of equipment are necessary:

1. A ruler.

2. A localizing rod or wooden stick, the size and length of an ordinary lead pencil, with a metal ring approximately two centimeters in diameter screwed into one end and an ordinary screw with a well rounded head in the other (Fig. 216).

3. Grease pencils, such as are used for marking on glass or chinaware.

4. Suitable skin-marking ink. An aniline dye may be used, or the Finzi ink; but the writer prefers an ordinary indelible pencil which makes a semi-permanent mark on the moistened skin. For war surgery the indelible pencil would hardly satisfy the need, but in civil practice it will usually do very well.

5. A cross-section anatomy. That published for Prof. Johnson Symington is highly satisfactory.[1]

The foregoing accessory articles permit the performance of most of the localizing procedures listed and described in this article, but the following inexpensive and simple accessories are often very useful.

6. Large calipers, such as obstetrical calipers.

7. A foot-switch for controlling the current through the X-ray tube. A combination switch, controlling both the overhead light and the tube current, is still better.

8. Strips of flexible metal, such as composition tin, 1.5 or 2 cm. in width, and of appropriate lengths for surrounding an arm, a leg, or the torso. These strips should be hinged together in pairs.

9. A cannula and trocar, and a supply of fine piano wire cut into lengths somewhat longer than the trocar.

Centering the tube. Accuracy in localization work requires an exactly centered X-ray tube. Some of the French manufacturers supply a special device for centering the tube. Among the numerous groups of rays given off in the active hemisphere of an X-ray tube is one to which the term "normal ray" has been applied. It will be recalled that in geometry a line normal to a second line is one perpendicular to it, making with it two right angles. In radiology, therefore, the term normal ray is applied to that group of rays perpendicular to the long axis of the tube. Unless the tube is carefully centered beneath the diaphragm in such a way that when the diaphragm is closed down to a small opening the normal ray will pass through it, there will be a resulting error in the localization calculations.

One may determine when the tube is centered by the following means:

When the military type of table is not available, the screen is locked in position above the tube box and a plumb-bob attached to a metal marker, such as a lead ball, is affixed by adhesive plaster to the underside of the screen somewhere near its center (Fig. 217). The opening in the diaphragm is reduced to about 1 cm. and the tube box moved until the pencil of rays emitted through the small opening casts the shadow of the plumb-bob and the metal marker on the screen. If the two shadows do not coincide, the tube is not correctly centered, and alterations in its position should be made and compared until the two shadows coincide.

An ordinary tin cup or a glass tumbler may be placed accurately over the small opening in the diaphragm, care being taken to see that the cup or tumbler is on a level support, and that the opening in the diaphragm comes as near as possible to the center of the cup. Then the diaphragm is opened so that the shadow of the whole cup shows. One may judge

[1] Mayne, Boyd & Son, Ltd., 2 Corporation Street, Belfast.

by the symmetry of this shadow whether or not the tube is properly centered (Fig. 218).

With the table supplied by the United States government during the war, the diamond-shaped opening of the shutter is reduced to about 1 cm. The tube box is locked in position and the screen moved so that the perforation in its center will coincide with the center of the projection of the small

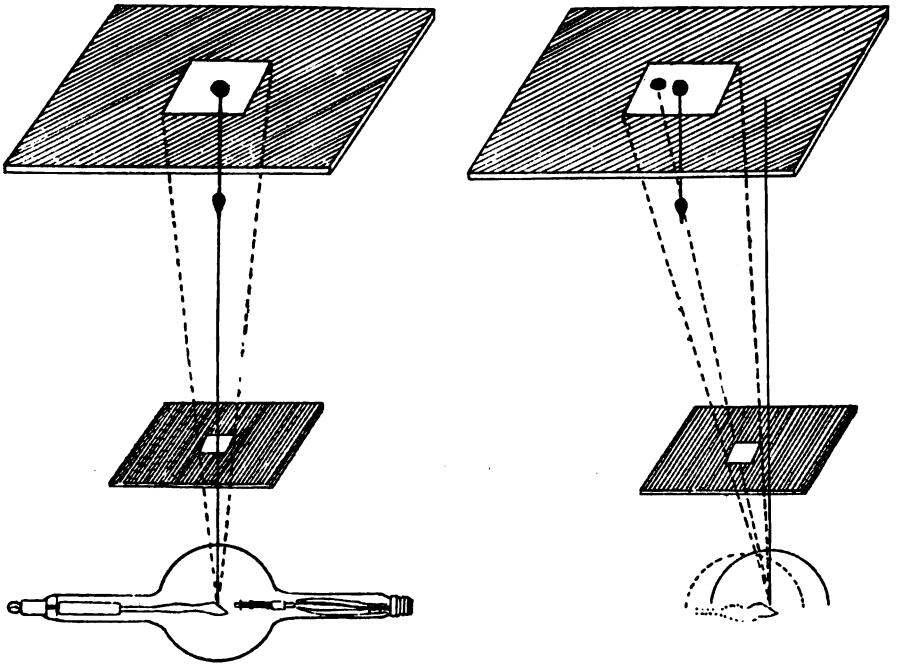

FIG. 217. X-RAY TUBE PROPERLY CENTERED, AND OFF CENTER.

diagonal opening of the shutter. The carrier is locked against longitudinal motion and against rotation, and the screen raised by the vertical movement of the carrier. If the perforation does not retain its symmetrical position the tube needs shifting until this condition obtains.

It is important that this process of centering the tube be carried out each time a localization is attempted, unless a number of localizations are planned for the same day.

Marking the skin. For marking the skin in relation to foreign bodies, especially where there is only occasional need for localization work, the ordinary indelible pencil, dipped in water or used on the moistened skin, is quite satisfactory. This mark is not obliterated by painting

the skin with tincture of iodine. If a black mark is desired, which dries quickly and which will withstand scrubbing, the Finzi formula is useful:

Pyrogallic acid	1 gm.
Acetone	10 c.cm.
Liquid chloride of iron	4 c.cm.
Wood alcohol q. s. ad	20 c.cm.

This ink, when made up fresh about once in ten days, makes a black mark and dries quickly. It is best applied with a sharp stick or a fine

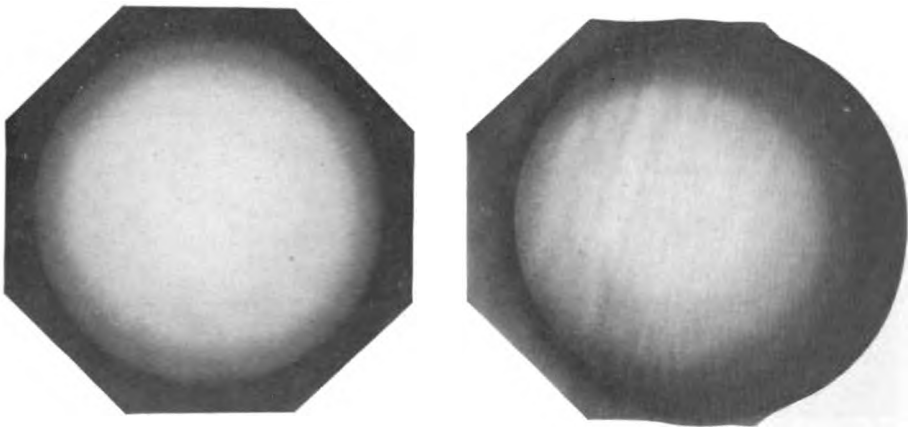

FIG. 218. SCREEN APPEARANCE OF A TUMBLER WITH THE TUBE PROPERLY CENTERED AND NOT PROPERLY CENTERED.

brush. If allowed to dry thoroughly the mark will resist alcohol, show through an iodine stain, and persist for from two to seven days.

In emergency cases a persisting mark can be made with a stick of silver nitrate on the skin moistened with a few drops of photographic developer. A match or toothpick dipped in a 10 or 20 per cent solution of silver nitrate will serve the same purpose without the irritation of the skin which sometimes results from the use of the silver nitrate stick. An aqueous solution of brilliant green has also been suggested for marking the skin.

The method of marking will vary with the case. If multiple foreign bodies are present, it is sufficient to mark such of them as can be located by the "nearest point" method with a dot surrounded by a circle, the dot indicating the nearest point. In cases of a single foreign body it is well to make as many marks as may be helpful to the surgeon; for

instance, one mark perpendicularly over the foreign body recording its depth, with two horizontal marks on either side of the part in the plane in which the foreign body lies.

It is also highly important that the localization be carried out and the marks placed upon the skin in the position which the patient is likely to occupy while undergoing operation. Hence, when it is feasible, the surgeon or his assistant should be consulted as to the probable method and site of surgical approach. It should be stated as an axiom that in all localization work the patient should be carefully placed in the operative position before one begins to make the localizing marks.

THE TECHNIQUE OF LOCALIZATION

One of the first steps in the localization of a foreign body, after determining its presence, is an estimation of its approximate position—whether it lies in front of or behind a certain bone or other anatomical landmark, whether it lies within the substance of a great muscle, etc. This is termed the anatomical localization, and it often suffices to enable the surgeon to perform the extraction.

It should be emphasized that the extraction of the foreign body is often one of the lesser considerations in dealing with a gunshot or other emergency case. The proper toilet of the wound, the removal of clothing and other foreign materials which may have been carried into the part by the projectile or foreign body, as well as attention to damaged bone, nerve, or other tissue, are of paramount importance, and in many instances the extraction of the offending foreign body comes in for secondary consideration. Along with the data for localization the radiologist should supply all information possible regarding injury to bone, dislocations, blood or pus accumulations, gas infections, and other conditions relating to the wound.

Anatomical localization. From the surgical standpoint, it may be stated that it is more important for the surgeon to be informed of the anatomical situation of a foreign body than of the mathematical distance it lies perpendicularly below a given point on the skin. For example, the surgeon is more interested in knowing that a foreign body has penetrated the pleura than that it lies 4.5 cm. below a certain point on the back when the patient is lying prone; and whether a projectile recorded as being 7 cm. beneath a point just below the vertebra prominens is intrapleural or lies within the substance of the body of the last cervical or the first dorsal vertebra. In order to give this information it is essential that the radiologist should possess an accurate knowledge of anatomy. It is here that the cross section anatomies may lend considerable

aid, though sometimes anatomical conditions vary in individual cases on account of unusual accumulations of fat and because of varying build in different individuals.

The anatomical location can often be determined by requiring the patient to carry out some active movements, or the radiologist can himself move the part and observe the changing relations of the foreign body during these maneuvers. The movements of the shadow during the contraction of muscular masses are significant. For instance, a foreign body in the forearm which exhibits considerable displacement when the patient closes his fist manifestly lies in one of the flexor muscles; if it ascends on flexion of the thumb and remains stationary during movements of the other fingers, it obviously lies in the flexor muscle of the thumb.

Foreign bodies in the region of the eye may be more exactly localized by causing the patient to open and close the eyes, to rotate the eyeball and to carry out other movements which bring into play the individual eye muscles. As foreign bodies within the eyeball may be located with a very high degree of precision by eye-localizing devices found in almost every radiological laboratory, no space will be devoted here to that subject. By having the patient protrude the tongue, open and shut the mouth, perform movements of deglutition, swallow a capsule containing bismuth, etc., one is able to determine the relative anatomical position of a foreign body in the face or neck.

For differentiation between intra- and extrathoracic foreign bodies, it is usually sufficient to cause the patient to practise several deep inhalations and exhalations. During inspiration, the lung is displaced from above downwards, while the thoracic cage is displaced in a contrary sense. Lateral or oblique fluoroscopy of the chest is very important, especially when the patient's diaphragm is immovable. Unless rather definite and extensive movement of a foreign body in the lower half of the chest can be determined during respiratory movements (save when the diaphragm is motionless), it should not be considered to be intrapulmonary; in the upper part of the thorax intrapulmonary foreign bodies may exhibit very little respiratory movement, and in the middle of the lung on either side they may be quite stationary. As intrapulmonary and hilus calcifications have caused many errors in the study of intrathoracic foreign bodies, it is well to have stereoscopic plates made in all doubtful cases. The pulsation imparted to intrathoracic foreign bodies by the heart or great vessels, especially to those lying near the midline, may occasionally cause great difficulty in exact localization.

Foreign bodies lying within the pericardium are usually movable, and gravitate to the most dependent point possible when the patient

changes his position; in old cases, intrapericardial foreign bodies may be attached to the wall of the pericardium, and render the diagnosis more difficult.

Projectiles lying near the diaphragm but just above it, should be easily localized, provided one views the patient from a sufficient number of angles. Intra-abdominal, subdiaphragmatic foreign bodies are not so easily localized. Arthur Stein and W. H. Stewart[1] have recom-

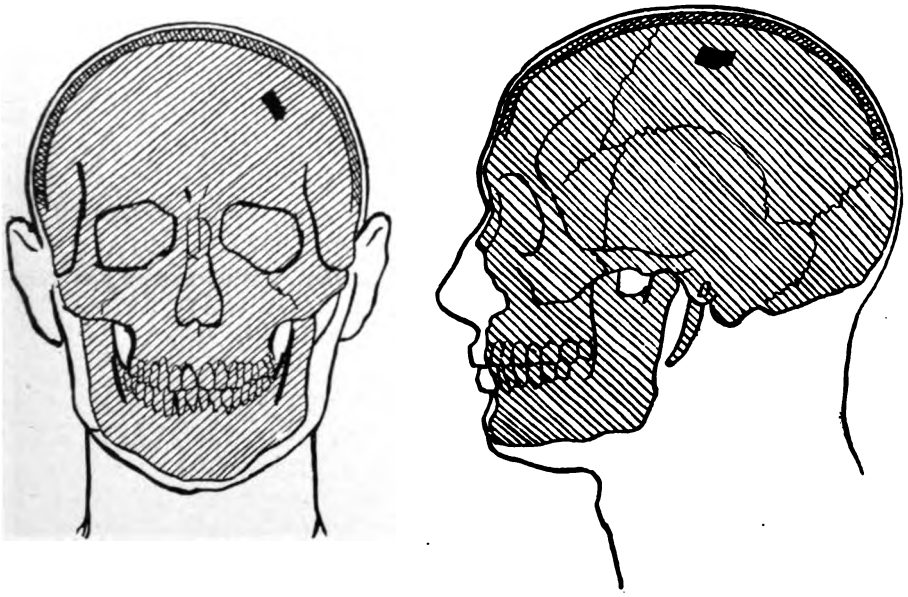

FIG. 219a. SCREEN APPEARANCE OF AN INTRACRANIAL FOREIGN BODY.

mended the introduction of oxygen or some other gas into the peritoneal cavity, so that by changing the posture of the patient it is possible to separate the subdiaphragmatic structures from the diaphragm itself. Many cases of wounds with intra-abdominal projectiles will have developed sufficient gas in the peritoneal cavity to make the introduction of oxygen unnecessary. Careful palpation of the abdomen, inflation of the colon or stomach in selected cases, the use of the Trendelenburg position, etc., will usually be sufficient without an induced pneumoperitoneum. Viallet has called attention to the possibility in certain cases, especially in wounds of the urinary bladder, of localizing a foreign body inside a hollow organ if, by localizing alternately from the anterior and the

[1] *Ann. Surg.*, July, 1919.

posterior aspect of the torso, results are obtained which disagree as regards the total thickness of the subject and are notably less. This is due to the displacement of the projectile from one position to the other.

In considering foreign bodies in relation to the vertebral column, attention should be drawn to the great value of stereoscopic plates and to lateral radioscopy and radiography of the spine, too little practised by the average radiologist. Lateral radiography of the spine is generally considered impossible without extraordinary apparatus; on the contrary the average type of portable apparatus will suffice to make excellent radiograms if intensifying screens are used. Even the sacrum can be radiographed laterally in this manner.

Foreign bodies in the pelvis should be localized with ease provided one makes stereoscopic radiograms. In occasional cases it may be possible to gain more information concerning a foreign body located in or near the rectum if an assistant makes intrarectal manipulations at the moment of the X-ray examination.

In wounds of the head it is sometimes possible for the casual X-ray observation to be very misleading. This is demonstrated in Figures 219a and 219b. In Figure 219a a typical intracranial projectile is shown in the frontal and lateral projection. Figure 219b represents the actual position of a projectile which is extracranial and lies within the soft tissues of the temporal region, but which with the usual frontal and lateral X-ray projection appears to be intracranial. This error would hardly occur during a fluoroscopic localization but it would be entirely possible with a radiographic procedure, and the possibility should be duly noted.

In a routine examination the patient is first placed on the horizontal fluoroscope and a brief fluoroscopic survey made to determine the presence of a foreign body. Of course, one may deal with foreign particles too small to be seen with the fluoroscopic screen, but except in the eye and a few other similar critical locations, a metallic foreign body too small to be seen with the fluoroscope usually does not require extraction. When the eyes are properly prepared by a preliminary stay in a darkened room one may see on the screen the shadow of such small substances as a common pin or a bird shot in the cæcum or a fairly small foreign body in the eye. In civil practice one or more radiograms will be made in nearly every foreign body case. In France more than 5,000 wounded men passed through the X-ray department of a certain unit without a single plate being made, all the localizations being done by the screen method.

Rotation of the part. The presence and general locality of the foreign body having been determined, it is easy by rotation of the member or part to determine the relative depth of the foreign body in rela-

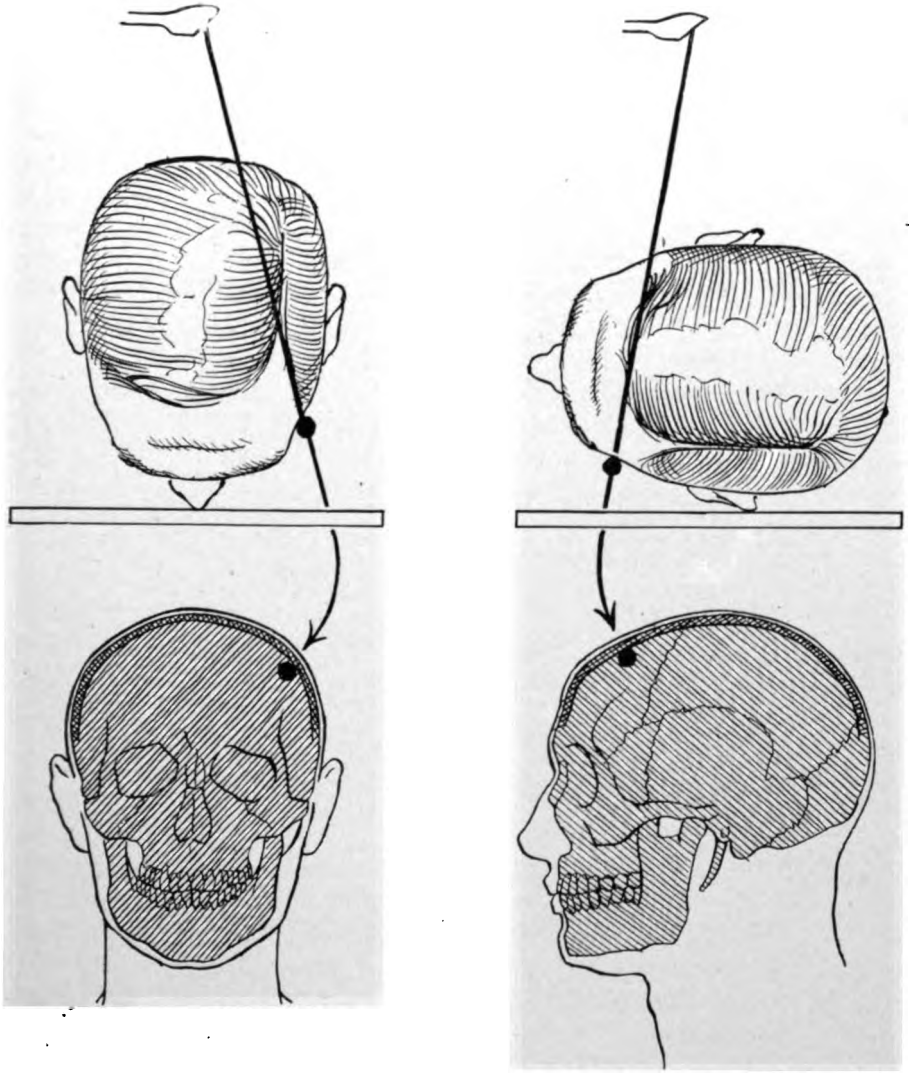

FIG. 219b. SCREEN APPEARANCE WHICH MIGHT LEAD TO AN ERRONEOUS DIAGNOSIS OF INTRACRANIAL FOREIGN BODY.

tion to bony landmarks or other opaque structures or markers. The shadows which move in the direction in which the part is rotated (Figs. 220a and 220b) will be found to lie between the axis of rotation of the part and the fluorescent screen; in other words, nearest the screen or

nearest the upper surface of the part. On the other hand, if the shadow of the foreign body is displaced in the opposite direction to that in which the part is rotated, the foreign body will be found to lie between the axis of rotation of the part and the tube; in other words, nearest the inferior surface of the part or member. This is illustrated in Figure 220a (after Nogier) where projectile P^1 is located near the upper surface and P^2

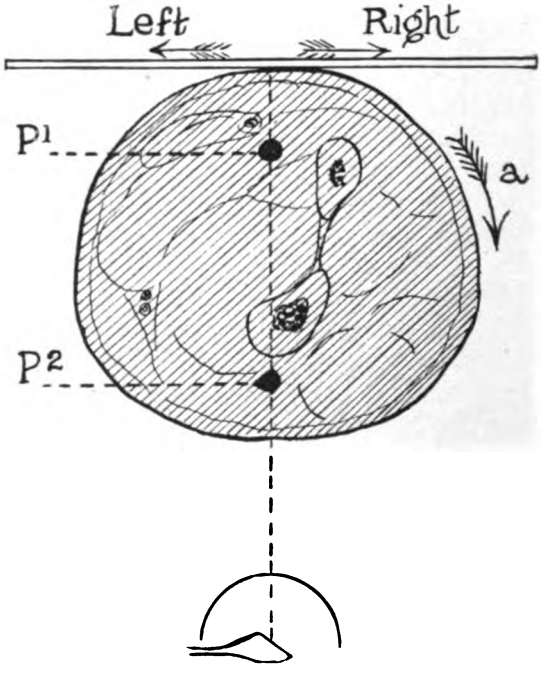

FIG. 220a. METHOD OF ROTATION OF THE PART. (*Nogier.*)

near the lower surface of the limb. When the part is rotated to the right, in the direction of the arrow *a*, naturally the shadow of projectile P^1 travels toward the right and the shadow of projectile P^2 toward the left. P^1 therefore lies above the axis of rotation of the part and P^2 between the axis of rotation of the part and the tube.

Nearest point method. After the above described method of rotation has enabled one to form an opinion as to the general situation of the projectile, the next step is to palpate the part containing the projectile and at the same time to observe on the screen the results of the palpation. One will not employ the unprotected fingers for the purpose, but rather the localizing rod (Fig. 216) or any suitable pointer. By the

movements of the foreign body under pressure upon the soft tissues surrounding it and by the amount of pressure required, one may estimate very accurately the point upon the skin which is nearest to the foreign body, and by simultaneous rotation of the part the depth at which the foreign body lies. In utilizing the palpating rod, one should turn the part until the position is found in which the shadow of the projectile or foreign body will be as near as possible to the surface. This done, the part is explored by touching it with the extremity of the palpating rod while making light vibrating movements. The nearer the end of the palpator to the "nearest point," the more will the foreign body move with

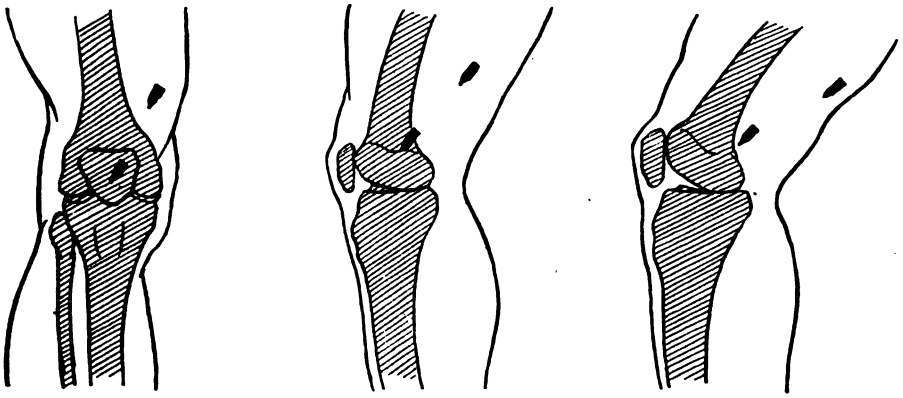

FIG. 220b. METHOD OF ROTATION OF THE PART.

these slow vibrating movements. When the movements transmitted by the palpator show the maximum mobility of the foreign body, this point on the skin should be marked as indicating the shortest possible distance from the foreign body to the skin.

This method is, of course, best adapted to the foreign bodies which are relatively superficial, as in the soft tissues of the arms, legs, neck, axilla, and buttocks; but it is a fact that fully one-half the foreign bodies may be included in this class. It is also frequently of value in demonstrating that a foreign body is within a joint, or that a foreign body cannot be displaced by pressure, suggesting that it may be embedded in very firm deep tissue or in bones.

The nearest point having been marked, the depth of the foreign body is next determined by one of the following methods:

Parallax method. This method is based upon the experimental fact that two opaque markers placed at an equal distance from the screen

will, when the tube is moved, cast upon the screen two shadows whose range of movement is equal; that is, whatever may be the displacement of the tube, objects lying in a plane parallel to the screen will project their shadow upon the screen in parallel lines. In Figure 221, for instance, T^1 and T^2 represent two positions of the tube; P, the projectile; L, the palpating rod held against the part at the same level as the projectile; P^1

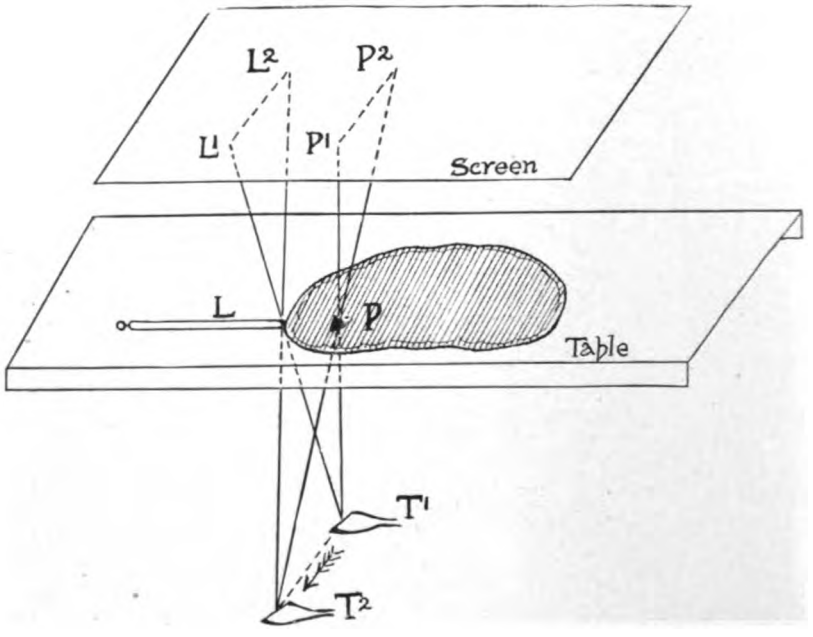

FIG. 221. DIAGRAMMATIC REPRESENTATION OF THE PARALLAX METHOD.

and P^2, the shadows of the projectile with the tube at T^1 and T^2 respectively; and L^1 and L^2, the shadows on the screen of the end of the palpating rod under the same circumstances. The line L^1L^2 represents the excursion of the shadow of the palpator as the tube is moved back and forth from T^1 to T^2; and the line P^1P^2, the excursion of the shadow of the projectile P. It is obvious that when the foreign body P and the end of the palpating rod L are at an equal distance from the tube, the excursion of their respective shadows will be equal and the lines L^1L^2 and P^1P^2 will be equal. When the foreign body is nearer the tube than the palpating rod, the excursion of the shadow of the foreign body will be greater than that of the shadow of the palpator; on the contrary, when the palpator is in a plane nearer the tube, the excursion of its

shadow will be greater than the excursion of the shadow of the foreign body.

This maneuver is carried out as follows: The end of the palpating rod is placed against the part as near as possible to the foreign body and in what seems to be the plane of the foreign body, and both shadows are brought to the edge of the shadow of the opened diaphragm. The

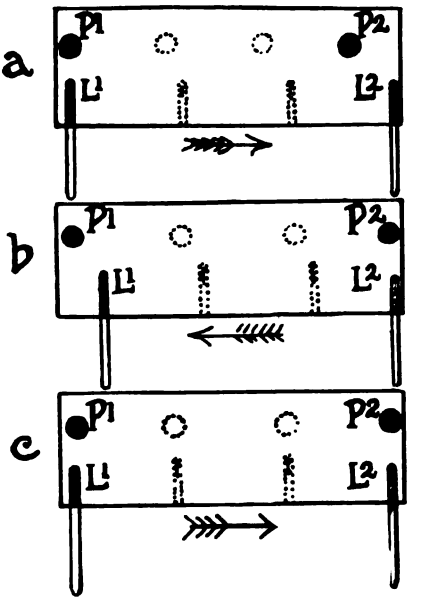

FIG. 222. SCREEN APPEARANCE DURING DIFFERENT STEPS OF THE PARALLAX METHOD.

tube is then deliberately moved in such a way as to cause the shadows to travel to the other edge of the open diaphragm. In Figure 222,*a* the foreign body shadow lags behind the shadow of the palpator in reaching the mark; therefore, the palpator is in a plane deeper than that of the projectile. If one raises the palpator slightly in order to correct the error (Fig. 222,*b*) and moves the tube just enough to bring both shadows again to the edge of the diaphragm, the tube is shifted in the contrary direction, causing the two shadows to return to the first position, shown in Figure 222,*a*. This time, the shadow of the projectile travels faster than the palpator and it is evident that the position of the palpator was overcorrected and brought nearer the surface than the foreign body. Once more a correction is made as shown in Figure 222,*c*, and now,

when the tube is shifted, both shadows arrive at the other edge of the diaphragm simultaneously. The screen is then removed and a horizontal mark placed upon the skin at the level of the palpator point. From this it is easy to deduce the distance at which the foreign body lies from the surface of the part. The procedure may be repeated on the other side of the part if it be an arm, leg, head, or neck.

This method is also valuable in connection with fluoroscopic screen control of foreign body extractions carried out during operation, for it

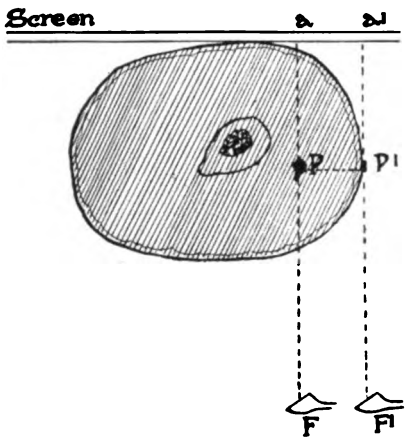

FIG. 223a. ORTHODIAGRAPHIC METHOD OF LOCALIZATION.

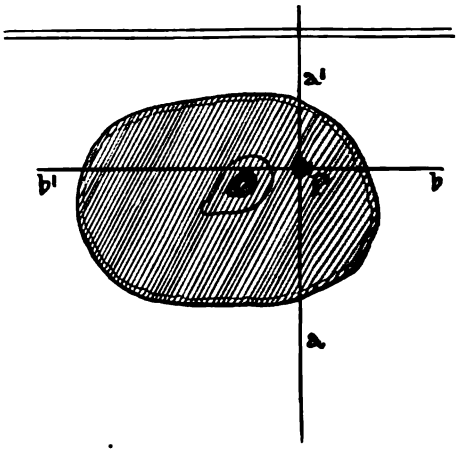

FIG. 223b. MEASUREMENT IN TWO DIRECTIONS (RIGHT-ANGLED PLANES).

permits the radiologist to tell the surgeon whether the end of the seizing forceps lying in the wound is above or below the foreign body to be extracted.

Orthodiagraphic method. Another simple means of ascertaining the exact distance from the foreign body to the nearest point on the skin is the orthodiagraphic method (Fig. 223a). The part is rotated until the shadow of the foreign body *P* and the marker upon the nearest point P^1 lie in the same plane. With the part held in this position, the tube is shifted until the shadow of the foreign body lies in the middle of the illuminated field upon the screen. The diaphragm is then narrowed down to the smallest possible opening which will illuminate a field upon the screen larger than the foreign body, the screen being held in a horizontal position parallel to the table and perpendicular to the central ray. The shadow of the foreign body is then brought to the center of the

small illuminated field upon the screen at *a* and a mark made upon the screen at this point with a grease pencil. The screen being held rigidly still, the tube is shifted until the small illuminated field shows as its center the marker upon the skin at a^1. The distance aa^1 is equivalent to the distance PP^1, the depth of the foreign body from the nearest point upon the skin.

Method of right-angled planes. Another simple method of localizing the foreign body is the four-point survey or the method of right-angled planes (Fig. 223b). This method is applicable only to those parts which can be rotated, unless a special instrument for fluoroscopy in both the vertical and lateral position is available. Special apparatus has been designed for simultaneous fluoroscopy of a part in two directions at right angles to each other,

We first pass the normal ray through the projectile *P* in the direction aa^1 and by means of the ring marker the point of exit and the point of entry of the vertical ray are marked on the skin (Fig. 223c). The part is then rotated through approximately 90 degrees when for a second time the normal ray is made to pass through the projectile, now in the direction bb^1, and these two points again ascertained by means of the ring marker and indicated upon the skin. The localization of the foreign body is thus definitely determined at the crossing of these two axes; and with the aid of a cross section anatomical atlas, one may reconstruct the part and the position of the foreign body. One may rotate the tube instead of the part if the apparatus permits it. It is not essential that the two planes of observation be at right angles; the crossing of any two axes through the foreign body will indicate its position.

This method is slightly less accurate than the multiple diameters or six-point survey.

The multiple diameters method. The multiple diameters method consists simply in securing several lines of sight through the body, each of which is made to pass through the projectile. The point of entry and the point of exit of the normal rays used in establishing these lines are plainly marked upon the skin. It is, of course, essential that a small diaphragm opening be employed in these methods.

The method of multiple diameters combined with the use of the strips of malleable metal, as employed by several authors, was described in the United States Army X-Ray Manual as follows:

"Two pieces of flexible metal, such as a composition of tin, are hinged together in the middle and placed around the body in the plane of the skin marks and made to conform to the shape of the body. Note is made of the distance that one unhinged end overlaps the other, and the skin marks are transferred to this metal band. After carefully removing the

latter from the body, it may be laid down on a card or a sheet of paper, and by bringing the overlapping end to its original position a pencil

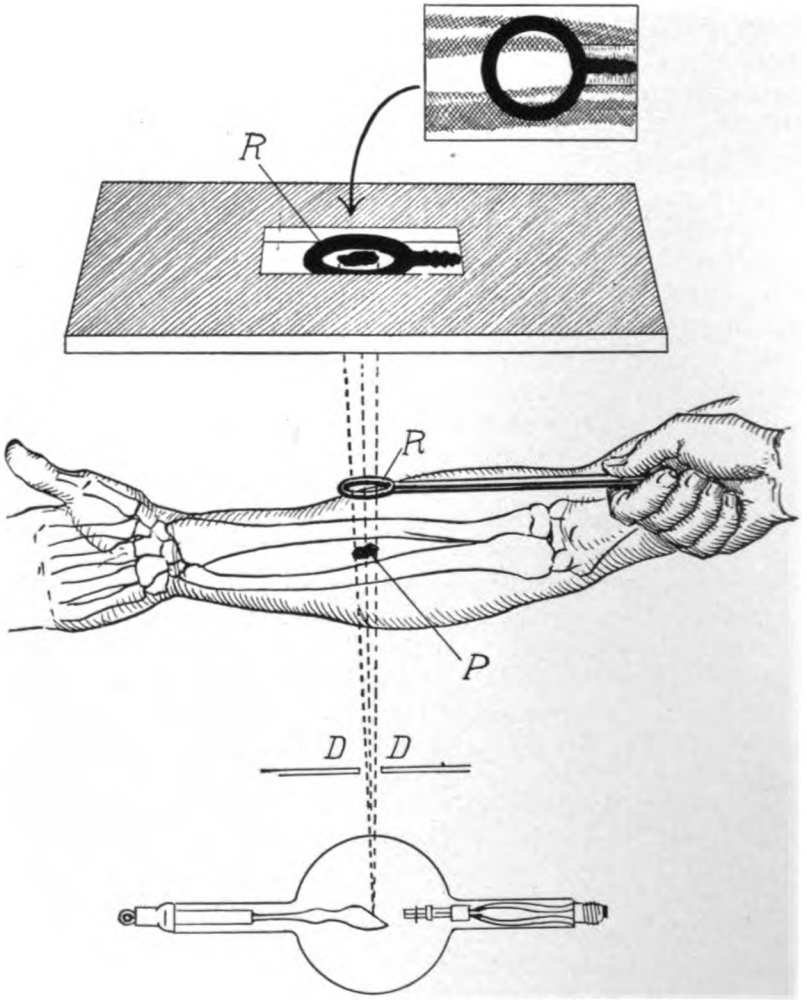

FIG. 223c. SCREEN APPEARANCE AND METHOD OF USING THE RING-LOCALIZER.

tracing will show the outline of the body in the plane of examination. The skin mark positions are then transferred to the diagram so as to make an approximate duplicate of the shape of the body and the location of the external skin markings.

"If, on this diagram (Fig 224a), one numbers the skin marks in series, 1, 2, 3, 4, 5, and 6, and joins 1 and 4, 2 and 5, and 3 and 6, and if the work has been strictly accurate, that is, if the sight lines were properly established, if the shape of the body did not alter by change of position when the band was put on, if the band was properly formed and not distorted afterwards, these three lines will intersect at a point; as a rule they are likely to form a small triangle, but with an excellent chance of the projectile being located in this small area. If one now compares the diagram, so formed, with a cross section anatomy for the same region of

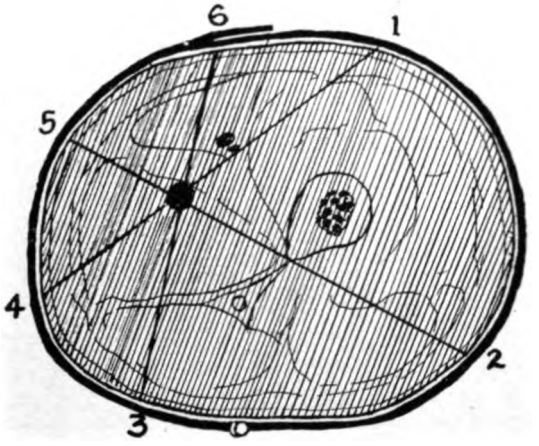

FIG. 224a. MALLEABLE BAND AND THE SIX-POINT SURVEY METHODS.

the body, definite anatomical information as to the position of the projectile and the relative position of muscles or organs likely to be encountered in its removal is gained.

"The value of this method will depend to a considerable extent upon the care exercised in forming and handling the strip and in properly adjusting it to the cross section anatomy. It is suggested that in many cases at least one of the skin marks might well have a definite relation to some anatomical landmark, so that there could be little opportunity for a rotation of the band with reference to the anatomical chart. This will be especially true of portions where the cross section is nearly a circle. It should also be observed that the accuracy of this method increases when the three sight lines are made to differ materially in direction. In some cases, this would be a difficult matter, as with a seriously wounded patient, or one for whom change of position on the X-ray table would be painful."

Lacking malleable metal strips one may make a cardboard cutout conforming to the contour of the part, and transfer to this cutout the skin marks indicating the points of entry and exit of the lines of sight above referred to. This cardboard is not, however, so easily sterilized and taken into the operating room as a guide for the surgeon.

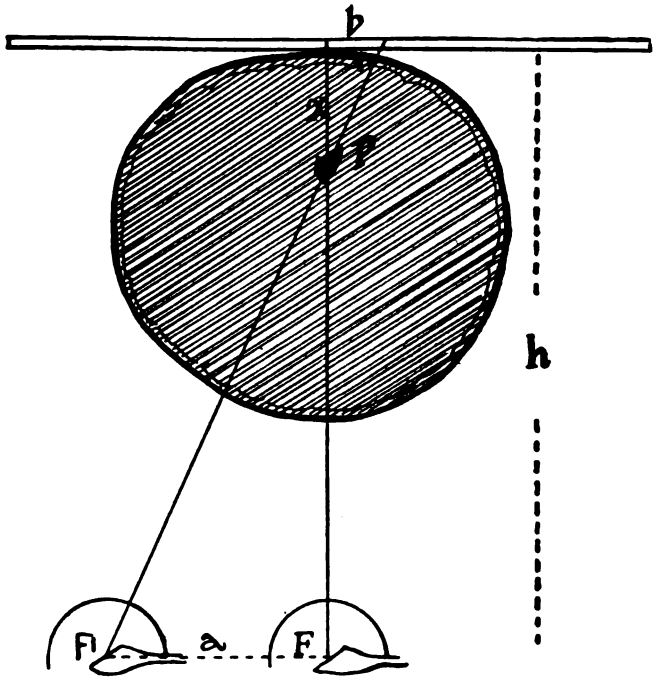

FIG. 224b. CLASSICAL SINGLE SHIFT TRIANGULATION METHOD.

The single shift triangulation method. One of the earliest procedures of foreign body localization was that set forth in 1896 by Buguet and Gascar who applied to foreign body localization the classical formula, depth $= \frac{bh}{a+b}$, where a represents the distance the tube is shifted; b the distance of the shift of the foreign body shadow; and h the height of the screen or plate from the point of focus of the tube.

The patient is placed upon the couch in the position he will occupy during operation and the screen fixed horizontally above the part and resting on it. The tube is moved about until the foreign body shadow lies in the normal ray, and a mark is placed on the skin at the points of entry

and exit of the normal ray. The position of the projectile is further marked upon the lead glass of the fixed screen. On opening the diaphragm the tube is shifted any distance, say 10 cm., without disturbing the position of the patient or screen, and the new position of the shadow of the foreign body is marked upon the screen. By measuring the height *h* from the screen to the point of focus of the tube, the distance *a* the tube is shifted, and the distance *b* the shadow of the foreign body was moved, we are able to work out the formula above stated and to arrive at the depth of the foreign body below the screen. In order to determine the exact depth below the skin, it remains only to subtract the distance from the screen to the skin, if the skin and the screen are not in contact. This method may be worked out accurately without arithmetical computation by simply redrawing the procedure to scale.

In civil practice, where only the occasional localization case is encountered, there is no necessity for maintaining a fixed distance between the screen and the focus point, for all these distances and shifts can be easily measured. In war, it will be better to adopt a standard focus-screen distance *h* (55 or 60 cm.) and a standard tube shift *a* (10 cm.), and to construct tables by which the depth of the foreign body below the screen can be instantly read from the shadow shift. Many such tables and many graphic devices were published during the war, but lack of space will not permit their reproduction in this work.

The stereoscopic method is really a single shift triangulation method. During the war, the United States Army Medical Department perfected an apparatus devised by the late E. W. Caldwell, of New York, permitting stereoscopic fluoroscopy. This method, of course, requires special apparatus and the instrument is not yet generally upon the market. The stereoradiographic method is the procedure of choice when plates are made. In civil practice, it is well to make stereoscopic plates in addition to the ordinary screen localizations.

Double shift fixed-angle method. A number of single and double shift fixed-angle methods have been described, all, however, based upon the same principle. The method of Strohl, Professor of Physics at the Sorbonne, was described by the writer in the United States Army Manual, as follows:

At a convenient distance above the tube *T* (Fig. 225a), usually on the diaphragm of the tube holder, it is easy to fasten a piece of cardboard or aluminum to which are affixed two bits of straight wire, W^2 and W^3, placed parallel on either side of the midline W^1, so that the distance between the wires will bear a fixed relation to the distance *O* from the cardboard or aluminum sheet to the focus of the tube. In other words, in the triangle FW^2W^3, the distance W^2W^3 bears a definite relation to

the distance W^1F. For convenience, let us say that the two distances are equal and that $W^2W^3=W^1F$. If desired, a third wire may be added at W^1, coinciding with the normal ray. W^2W^1, therefore, equals W^3W^1. It is a geometrical fact that the distance between the shadows

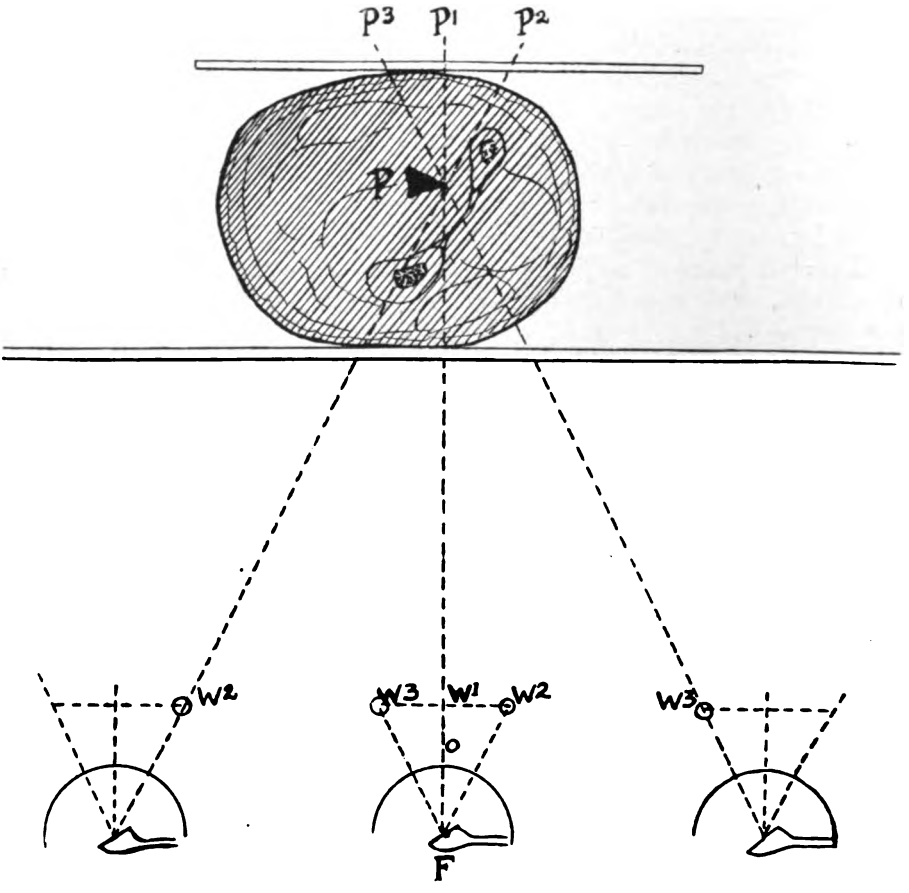

FIG. 225a. METHOD OF SIMILAR TRIANGLES (DOUBLE SHIFT FIXED-ANGLE METHOD).

cast upon the screen by the wires W^2 and W^3 will, under these circumstances, always be equal to the distance from the screen to the focus point of the tube, so long as the screen is held horizontal to the tube. With a small diaphragm opening the tube is brought directly beneath the foreign body P (Fig 225a) and the position of the foreign body shadow

marked upon the screen at P^1 and upon the skin directly underneath. The screen appearance at this moment is shown at *a* (Fig. 225b). Two leaves of the diaphragm are then opened widely making a slit and giving the appearance illustrated in Figure 225b, *b*; the tube is then shifted to the left, during which movement the shadow of the right wire W^2 will

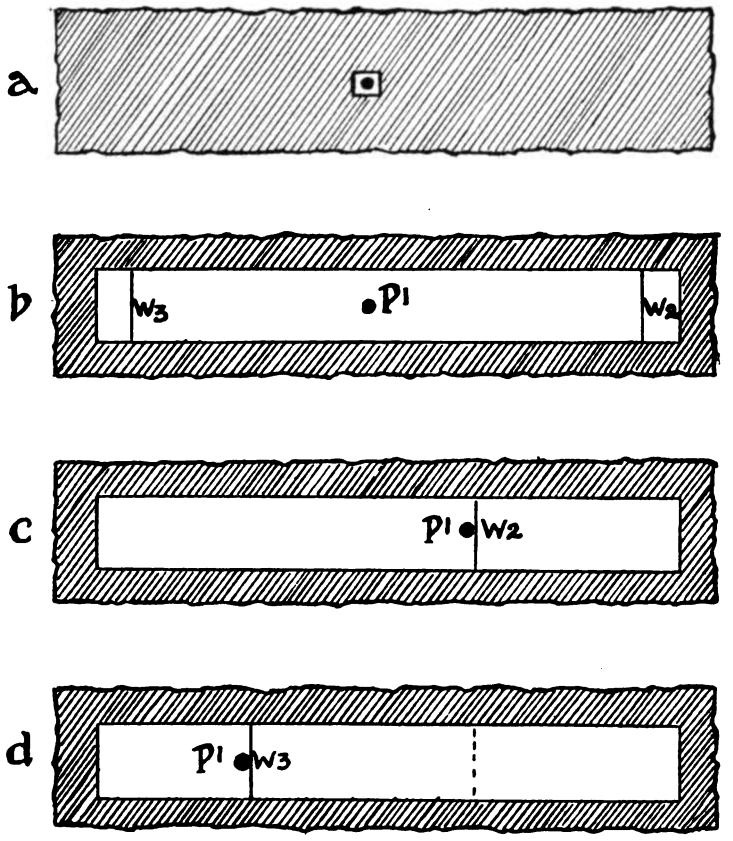

FIG. 225b. SCREEN APPEARANCE AT DIFFERENT STEPS OF THE DOUBLE SHIFT FIXED-ANGLE METHOD.

also travel toward the left while the shadow of the projectile will travel toward the right, until a tube position will be reached where the two shadows coincide (Fig 225b, *c*). This point is marked upon the screen with a grease pencil. The tube is then shifted in the opposite direction until the shadow of the left wire, W^3, and of the projectile coincide

(Fig. 225b, *d*). This point is also marked upon the screen. According to the law of similar triangles, the distance between the two marks upon the screen equals the distance from the screen to the foreign body; and to estimate the depth of the foreign body it only remains to subtract the distance from the screen to the skin, if the screen itself does not rest directly upon the skin.

The distance between the wires W^2 and W^3 may bear any given relation to the distance from the focus point to the plane in which the wires are fixed. It is only necessary to know this relation in order to estimate the depth of the foreign body by this very rapid and accurate method. It is not necessary to know the focus distance of the screen or the distance of the tube shift. The wires may be placed upon any of the

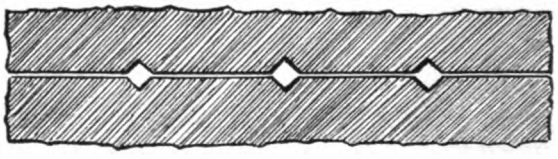

FIG. 225c. SCREEN APPEARANCE AFTER NOTCHING THE DIAPHRAGM LEAVES FOR THE ROUSSEL METHOD.

ordinary types of fluoroscopic apparatus without interfering with the routine work; one must only know the ratio of the distance between the wires to their distance from the focus above referred to.

In place of the wires, which are sometimes somewhat hard to see through the denser portions of the body, one may file upon the two leaves of the diaphragm three notches (Fig. 225c), one directly above the focus of the centered tube, and one on either side of this central point at any given distance. The ratio may be varied, just as in the Strohl method. With the diaphragm closed, one has therefore upon the screen three diamond-shaped, illuminated notches (Fig. 225c); the two outermost notches correspond to the shadow of the two wires shown in Figure 225b, *b*. The tube is shifted in the same manner, first to the left and then to the right until the foreign body shadow is brought to the center of each of the diamonds; these spots are marked upon the screen with a grease pencil, and the distance between them measured and translated into the depth of the foreign body.

During the war the so-called "twenty-six degree method" was popular among French radiologists, the distance from the middle notch to either of the outer notches being half the focus-diaphragm distance. With this method, only one shift was made from the central notch to one

of the outer notches, and the distance of the shadow shift multiplied by two to determine the depth of the foreign body below the screen.

Harpoon method. The harpooning method, the insertion of a sterile needle through the tissues to the foreign body, which serves as a guide to the surgeon in removing the projectile, requires no special apparatus not found in any hospital with a fluoroscopic X-ray equipment.

The instruments, the field of operation, and the surgeon's hands must be surgically clean, and a sterile sheet or towel must be held between the operative field and the fluoroscopic screen. By rotation and manipulation of the part the approximate anatomical position of the foreign body is determined as nearly as possible. The needle when introduced will mark out the line of the surgeon's approach; if the track of the needle is likely to pass near vital structures it is of importance that this line be determined in consultation with the surgeon. The path of attack having been determined and the surgeon having marked on the skin approximately where he wishes to make his incision, the part is rotated under the screen so that the skin mark will lie vertically over the foreign body. A needle of proper length having been selected, it is seized with forceps and held at such an angle that the fingers of the operator will not be exposed to the rays. Under the fluoroscopic screen, the needle is pushed down upon the foreign body and left *in situ*.

This method has been modified and improved under the name of the "trocar and cannula method" by various surgeons of the allied armies. It should always be used under the direct supervision of a competent surgeon or of one who has the necessary anatomical knowledge and surgical judgment to use it without danger of infecting the patient or of injuring important structures. In cases with encapsulated foreign bodies the trocar and cannula method is often of great value, but it is not useful as a routine procedure in recent wounds, where the surgeon usually approaches the projectile or foreign body through the path by which it entered.

Under anæsthesia, the skin should be punctured with a sharp scalpel, after which the cannula, with the obturator in place, is slowly passed into the tissues until it comes into contact with the projectile as determined by touch or by fluoroscopic observation at varying angles. After contact is secured, the obturator is removed and a piece of piano wire, bent at the lower end in the form of a fish hook, is passed well through the cannula. The latter is then withdrawn, leaving the piano wire hooked into the flesh. If necessary, the external end of the wire may be clipped with forceps or cut off short, and bent down close to the skin. The length of wire introduced beneath the skin indicates to the surgeon the depth of the foreign body. It is very important that the introduction of the needle or trocar

should be carried out with the instrument in the line of the normal ray; any attempt to insert it at an angle will result in considerable mutilation of the tissues.

The harpooning method is not only a method of localization, but it is also a method of guidance for the surgeon during the operation of extraction. There are a number of other methods which serve both to

FIG. 226. HIRTZ COMPASS GUIDANCE DURING A SURGICAL OPERATION.

localize and to guide the surgeon, foremost among which should be mentioned the Hirtz compass. This is an apparatus of which several types, all similar in principle, were employed during the war. For clinics where there are frequent extractions of foreign bodies from the cranium and from the deeper structures of the shoulders, axillæ, lumbar region, pelvis, and buttocks, this instrument can be highly recommended. A complete description will be found in the United States Army X-Ray Manual (pp. 250-266), and in the literature accompanying the instrument.

The advantages are numerous. After the sterilized compass has been placed in position, the penetration needle, when brought in contact with the skin, indicates the point where the incision should be made, and the

depth and the direction in which the foreign body lies. By means of the rotating device through which the penetration needle is passed, the surgeon can select the point of entry without in any way embarrassing the usefulness of the instrument. The instrument, being sterile, can be reapplied as often as needed during the operation.

In using the compass, it is important that the skin marks selected for the compass legs should constitute a large triangle and that these marks should not be covered by drapes or towels during the operation. When the compass is being set, the patient should lie in either the prone or the supine position rather than on the side, and at operation exactly the same attitude should be assumed. It is important that the muscles be relaxed as far as possible; otherwise muscular contraction maintained during the X-ray examination is likely to disappear during anæsthesia and thus possibly alter the position of the projectile to a considerable degree. Duval cites a case in which a bullet located in the adductors of the thigh shifted eight centimeters when the contracted muscles were relaxed.

The settings for the compass may be determined by fluoroscopic observations only or by radiograms. If the latter are employed, it is preferable to make the two exposures on separate plates rather than on a single plate, for thus one has stereoscopic radiograms of the part in addition to the data for setting the compass.

EXTRACTION OF FOREIGN BODIES UNDER X-RAY GUIDANCE

X-ray guidance during surgical operations is indispensable for the expeditious removal of a large proportion of foreign bodies. It is applicable not only to the extraction of projectiles and other foreign metallic substances, but also for the removal of pathological foreign bodies, such as renal calculi, encountered in civil life. In fact if there is any question as to the location of an elusive stone or doubt as to whether or not all stones have been removed, it is possible, by means of the fluoroscopic bonnet and portable X-ray equipment, to make an X-ray examination of a kidney which has been lifted out of the wound at operation. This method of screen control is also useful during the injection of opaque fluids into the urinary tract, during the aspiration of intrathoracic accumulations of fluid, and in the control of injection of air, oxygen, and other gas into the pleural or peritoneal cavity, or into the ventricles of the brain.

The method of intermittent fluoroscopic control is more satisfactory for general use in the extraction of metallic foreign bodies than are electrovibrators, telephone probes, or other similar devices, for the reason

FIG. 227a. EXTRACTION OF A FOREIGN BODY UNDER FLUOROSCOPIC CONTROL. The open screen method in darkened room.

FIG. 227b. EXTRACTION OF A FOREIGN BODY UNDER FLUOROSCOPIC CONTROL. The open screen method in darkened room.

that a considerable percentage (approximately one-fifth) of the foreign bodies of war are not magnetizable. Fluoroscopic control methods save time, lessen trauma, and conserve the temper of the surgeon.

The requirements for the malleable band, harpoon, and Hirtz compass methods have already been sufficiently referred to in the preceding section.

Two other methods of fluoroscopic control will be described in detail: The method of the open screen in the darkened room, and the bonnet method in the usual light of the operating room.

The open screen in the darkened room. The requirements for this method are the usual fluoroscopic horizontal table; a fluoroscopic screen; a proper overhead red or green light, sufficiently bright, preferably under control of the same foot-switch that controls the X-ray current; surgical equipment, including sterile sheets, gloves, gowns, and instruments.

No instruments of special design are needed except a pair of narrow-jawed forceps. A special bullet-seizing forceps or a forceps of the type used for exploration of the gall-bladder or common duct is usually satisfactory for grasping the foreign body. The forceps of Wullyamoz is bent at a right angle in such fashion that the prehensile portion of the instrument is held in the line of the vertical ray without exposing the hand of the operator.

If it is not convenient to use the ordinary horizontal fluoroscopic table, any wooden or aluminum-topped table will suffice if so constructed that an X-ray tube can be placed beneath it without danger of short-circuiting the current. The modern bedside equipment (Fig. 228a) serves very nicely for this purpose. The small Coolidge tube and the tube-holding arm can be turned downward and placed under the table at a point vertically beneath the foreign body when the patient lies in the position for operation. Blankets or black or green cloth draped around the table to the floor will prevent the escape of light into the room, or a smaller piece of black cloth can be placed directly around the tube for the few moments necessary for the examination. The ordinary horizontal fluoroscope is, of course, already equipped.

One may use the ordinary, lead-glass covered, fluoroscopic screen; or an old intensifying screen, no longer useful for radiographic work, may be fastened to a piece of lead-glass by means of adhesive tape and held by an assistant whose hands are properly protected by leaded rubber gloves. Special tables were constructed during the war supplied with a hinged arm for holding the fluoroscopic screen, so that when the screen was not in use it could be tilted back out of the way of the operator.

For the overhead light one may employ an ordinary incandescent

bulb, stained red. This red light may be as brilliant as the surgeon desires. The writer prefers a bluish bulb mounted in a yellow globe, which gives a very agreeable light, much like moonlight. On the other hand, the overhead light in daily use in the fluoroscopic room may be utilized in place of a red light for most of the manipulations; if at any stage of the operation more illumination is required, a headlight may be supplied to the surgeon. Where extractions under X-ray control are frequent, it will be advantageous to provide a special source of overhead light, five or six feet above the fluoroscopic table, so arranged with glass filters that a powerful red light is thrown upon the operative field. If this light is equipped with a rheostat for dimming or intensifying the illumination, it will be all the more serviceable. In the absence of more elaborate equipment, a hand lamp equipped with a red bulb will serve.

Before the operation it is important that both the surgeon and the radiologist spend ten or more minutes in an obscurely lighted room, or with the eyes protected by smoked glasses.

After the patient has been made ready upon the table, and the sterile linen has been arranged as for any aseptic operation, an additional sterile sheet, known in France as the *velum,* is thrown over the operative field and fastened down by towel clips on the side next to the radiologist, opposite the surgeon. On the side next to the surgeon, the sheet is held at its two corners by sterile forceps in the hands of assistants. These assistants may or may not be dressed for sterile work as the circumstances warrant. The assistants holding the front ends of the *velum* drop it over the operative field, protecting it from the radiologist and his unsterile screen. Figure 227a shows the operating scene at this moment. The red light is then extinguished and the X-ray is turned on (Fig. 227b). The radiologist adjusts the tube under the table so that only a small spot on the screen, not more than three centimeters square, will be illuminated, and the foreign body is brought to the center of this spot. The tube is then fixed in position and the radiologist makes pressure against the skin with a sterile pointer at a spot directly over the foreign body.

The surgeon notes the point on the skin thus indicated and, if it is a satisfactory path of approach to the projectile, makes his incision there. The radiologist then steps back, the *velum* is raised, care being taken not to contaminate its underside, and the surgeon proceeds with the incision and dissection toward the foreign body.

During the dissection, at such times as he wants help, the surgeon holds the end of a forceps directly over the point where he believes the foreign body to lie, and the protecting *velum,* its under side still sterile, is turned down over the wound, the red light is again extinguished, and

the radiologist corrects the position of the surgeon's forceps by directing him to move it to the right or the left, until the correct spot is found. The surgeon has only to work directly downward to come upon the object of his search.

It will be unnecessary in many cases to expose the foreign body completely by dissection; often it is only necessary to determine its ap-

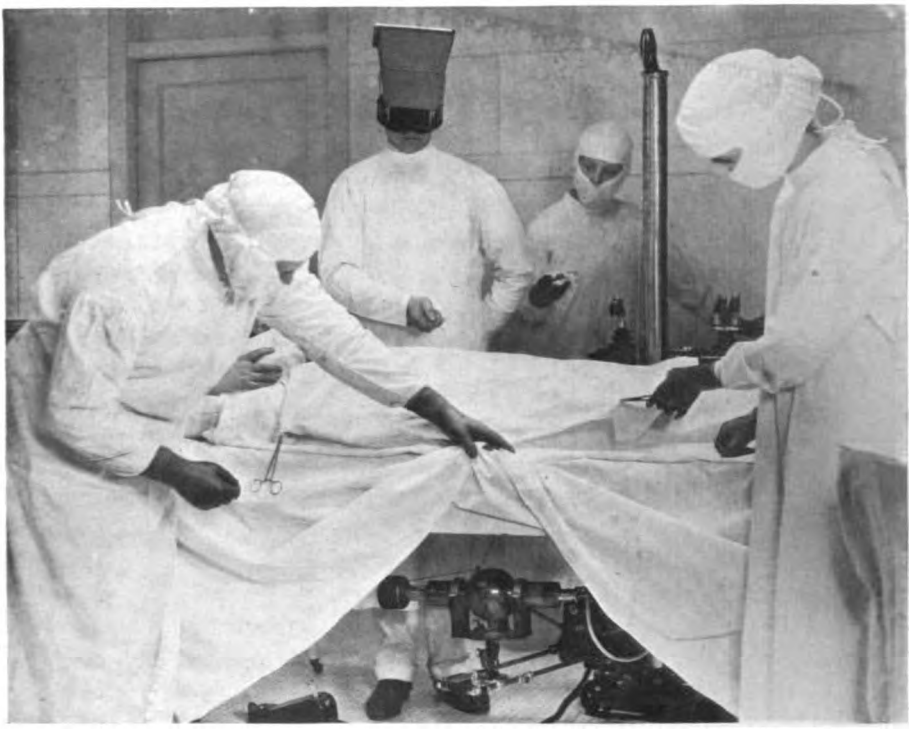

FIG. 228a. ARRANGEMENT OF THE TUBE AND TABLE FOR THE BONNET METHOD.

proximate anatomical position, especially when it lies in the depth of a muscle. Frequently it will be possible, after making a small skin incision, to extinguish the red light, turn on the X-ray current, and under fluoroscopic guidance insinuate the end of a closed, narrow-jawed, blunt forceps into the tissues until it touches and moves the foreign body. With the X-ray current still on, the jaws of the forceps are separated, the foreign body grasped and extracted. The red light or the ordinary brilliant white light of the room is then turned on, and the remainder of the operation conducted in the usual manner. In some situations it will

be possible to turn a jagged projectile so that the extraction forceps will seize it by its sharp or jagged edge or point. A needle may be grasped near one end. One who has not gained experience in this method of extraction cannot appreciate the ease with which a foreign body may be secured and removed in this manner. In a series of several hundred extractions performed in this way, the writer has never been longer than twenty minutes, usually much less, from skin puncture to extraction of

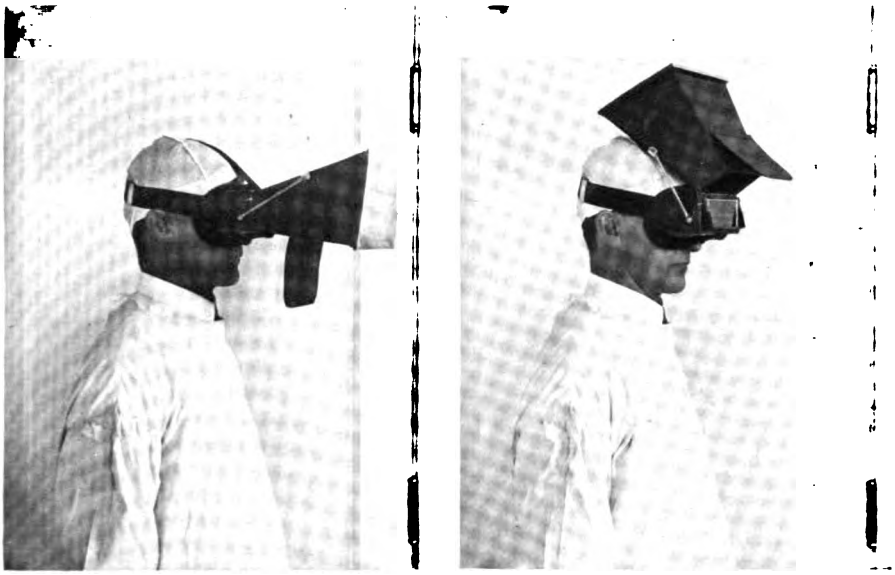

FIG. 228b. DESSANE BONNET FLUOROSCOPE FOR SCREEN OBSERVATION.

foreign body, and only twice has he failed to remove the foreign body. Both failures were in cases in which hypodermic needles were broken off deep in tissues too thick to be easily studied with the fluoroscope.

Protection of both the patient and the operator from an overexposure of X-rays is of first importance. It goes without saying that the usual lead lining of the X-ray tube holder protects the patient and the operator from all rays except those illuminating the spot upon the fluoroscopic screen. This field of radiation should be kept as small as possible and nothing but the forceps of the operator should ever enter it while the current is on; sufficiently long forceps should be employed to keep the hands out of the direct rays. Protection of the patient and additional security for the operator is afforded by placing over the tube a filter of

at least two millimeters of aluminium, and by reducing to a minimum the time required for the X-ray observations. Onlookers not directly interested should not prolong the operation by participating in the screen work. The method is entirely safe if reasonable care is taken to minimize the time of X-ray observations. If the eyes have been properly prepared by a preliminary stay in obscurity one or two milliamperes of

FIG. 228c. BONNET METHOD. After the sterile *velum* is interposed between the radiologist and the field of operation, the radiologist places the pointer directly over the foreign body.

current will suffice. A foot-switch is essential. The X-ray current should be off every second the observer's eyes are not intently studying the screen. During early experiences, the X-ray current may be turned on and off twenty or thirty times during the operation; but after the first few cases the extraction will be accomplished during a very few moments.

The bonnet method. The bonnet procedure has the advantage over the foregoing method that it can be carried out in the operating room in the usual light by which the surgeon operates.

The requirements are an ordinary fluoroscopic horizontal table or a

makeshift; a fluoroscopic bonnet; and a sighting needle or pointer sufficiently long to permit the hand holding it to remain safely outside of the zone of active X-rays.

The United States army bedside unit, which is now being adapted to general practice, affords a very convenient instrument for taking the X-ray apparatus to the operating room, providing the surgeon does not wish to take his patient to the X-ray room. An ordinary massage or

FIG. 228d. BONNET METHOD. Working underneath the sterile sheet the surgeon places his pointer at the spot marked by the radiologist, who again verifies the correctness of the localization.

other non-metallic table or a stretcher will serve the purpose. The tube-holding arm and tube of the bedside unit is placed under the table, approximately under the foreign body when the patient is in the position for operation (Fig. 228a). No effort need be made to hide the glow of the X-ray tube, as this type of X-ray operation can be carried on in the most brilliant light needed for operating purposes.

A fluoroscopic bonnet, or, in its absence, a hand fluoroscope of the ordinary type will be needed. In the latter instance, it will be necessary to provide the radiologist with a pair of smoked glass spectacles. The

bonnet fluoroscope, especially Dessane's, illustrated in Figure 228b, is much simpler and more convenient. Figure 228b shows the radiologist with the bonnet in place. As soon as he finishes his observation, the lower part is turned up (Fig. 228b) and held in this position by springs, while a shutter of smoked glass comes down automatically in front of his eyes. The position of the hood thus lifted eases the weight and materially

FIG. 228e. BONNET METHOD. The *velum* is lifted and the surgeon goes on with his work, the radiologist standing by to render further assistance when needed.

lessens the inconvenience of its use. The screen in this form of fluoroscope measures 13 by 18 cm., an area much larger than the illuminated field should ever be. For a pointer or sighting device, an ordinary urethral sound or a long forceps may be used, if a special localizing pointer is not provided.

The radiologist must put on the bonnet or a pair of smoked glasses twelve or fifteen minutes before he will be needed, unless he is already engaged in fluoroscopic work, so that when called he has only to don the bonnet and step to the operating room.

For anæsthesia in these cases, when a local anæsthetic is not suitable,

nitrous oxide gas is preferable since it is non-explosive. The danger of an explosion of ether vapor, however, has, in the writer's opinion, been considerably overdrawn. He has seen only one case and in this no

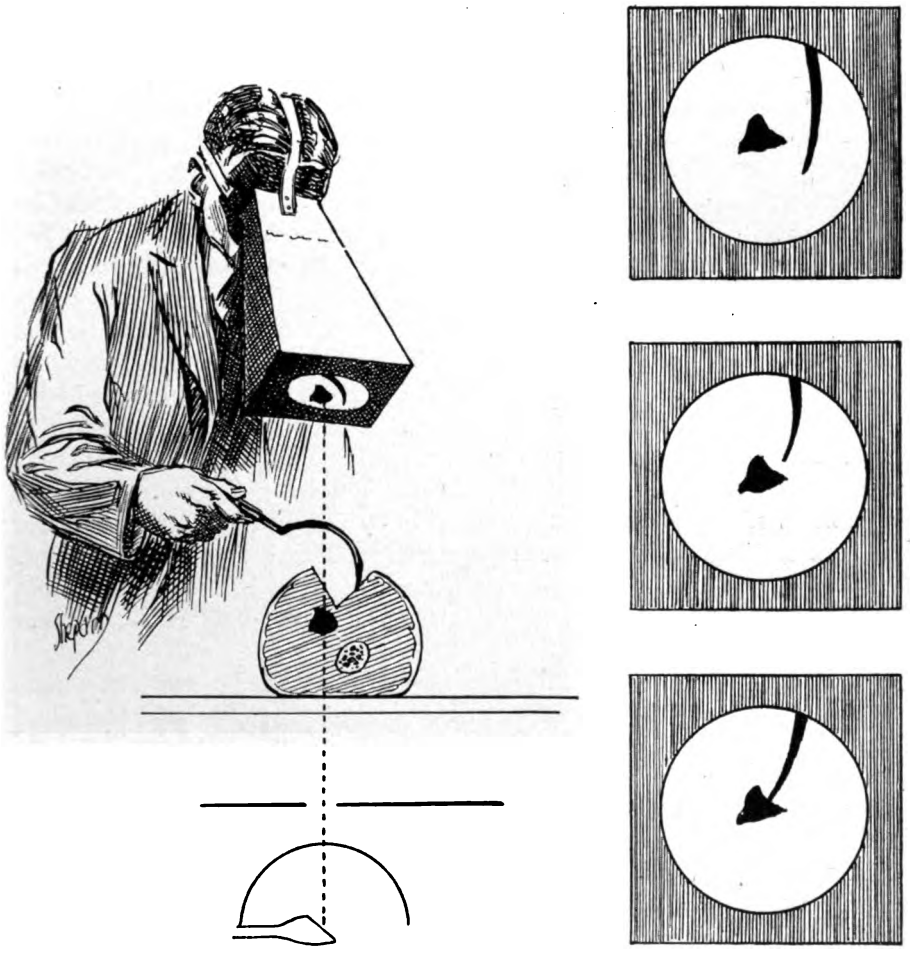

FIG. 228f. BONNET METHOD. Diagram illustrating the relative position of the tube, wound, radiologist's pointer, and bonnet fluoroscope. (*Ledoux-Lebard.*)

harm at all was done as the flame was instantly smothered. The danger, of course, is greater with the open drop method than with some form of rebreathing anæsthetic device. The Ombrédanne anæsthetic mask is very satisfactory for this purpose.

After the patient has been made ready for operation in the position in which the localization was done, the protective sterile *velum* is placed over him in the manner already described. When the surgeon is ready, the radiologist indicates through the sterile *velum,* by means of a pointer, the exact spot on the skin which lies vertically above the foreign body (Fig. 228c). While he holds the pointer in place the *velum* is lifted on the side next the surgeon, who places the end of a sterile forceps on the skin in the position shown by the radiologist's pointer (Fig. 228d). The bonnet and *velum* are lifted out of the way (Fig. 228e), the surgeon notes carefully the point indicated on the skin and cuts down vertically upon it to find the foreign body. If he does not find it at the depth he supposes to be correct he ties the bleeding points in order to clear the field of hæmostats, and asks to be shown again the spot where the vertical ray corresponding to the projectile passes through the wound. This takes but a moment on the part of the radiologist and is done as often as required. The surgeon places his sterile pointer in the wound as nearly as possible above the exact center of the image of the foreign body. Figure 228f shows the image seen upon the screen when the pointer is not accurately over the bullet, and the successive images seen during the process of correcting the position of the pointer. Correction of the position of the surgeon's forceps is made by telling him to move to the left, right, front, or back, until the correct location has been found. After the extraction procedure has been completed it will be advisable to make still another observation to insure that the whole of the foreign body has been removed.

This method will rarely fail except in badly planned operations where an insurmountable difficulty of an anatomical or physiological nature has been overlooked, or where through some accident it will be necessary to terminate the operation suddenly.

In the case of recent wounds, the surgeon will often prefer to conduct his search through the already existing wound rather than to cut down vertically upon the foreign body. Here again the bonnet will afford valuable control, especially if the tube beneath the table is susceptible of movement.

The bonnet method is particularly helpful in cases of old encapsulated projectiles or foreign bodies. By using a very small diaphragm aperture the radiologist employs the bundle of rays perpendicular to the plane of the table. When the foreign body is brought into the line of this ray and the point marked upon the skin perpendicularly over the ray, the surgeon knows that if he dissects vertically downward he cannot fail to find the foreign body. Ledoux-Lebard has demonstrated the special value of this method in cases of intra-osseous projectiles.

SECTION XVI

WOUNDS OF THE BONES AND JOINTS

GUNSHOT WOUNDS OF THE JOINTS

BY

SUMNER L. KOCH, M.A., M.D.
Instructor in Surgery, Northwestern University Medical School, Chicago

WOUNDS OF THE LONG BONES

BY

DUNLAP PEARCE PENHALLOW, S.B., M.D.
Major, Medical Corps, U. S. Army; Chief Surgeon, American Women's War Hospital, Paignton, England; Boston

CHAPTER I

GUNSHOT WOUNDS OF THE JOINTS

No one who compares the results attained in the treatment of joint injuries at the close of the war with those accomplished during the early months of the war can help but be tremendously impressed by the advances made in the methods of caring for this type of injury. At the outset of the war a serious joint wound meant amputation or death. Many cases of joint injury, apparently not so serious at the outset, went on to prolonged suppuration, ankylosis, and permanent disability. The morbidity and mortality following joint injuries were frightfully high. At the close of the war this state of things was completely changed. Duval (1) states that during 1914 and 1915 the mortality following gunshot wounds of the knee-joint was 27.6 per cent; and that during this period amputation of the thigh was performed in 30 per cent of cases. During 1916, 1917, and 1918 the mortality was 0.9 per cent and amputation was performed in 2.8 per cent of cases with similar injuries.

Two important factors helped to bring about this result. Organization of the medical services and motor transport, that permitted the wounded to be cared for promptly and by competent surgeons with adequate facilities at their disposal, was obviously of the first importance. The realization that the principles of primary excision and suture could be successfully applied to wounds involving the joints developed slowly, due to the firmly rooted belief that the synovial lining of joint cavities was absolutely intolerant of injury. With an increasing experience the fact was established that synovial membranes possessed a high degree of resistance; that injured joints, if operated upon within a reasonable interval of time, might be opened, cleansed, and sutured again with every expectation of complete recovery. To our minds this is the most striking lesson of the many we have learned during the war, a lesson of particular interest to the surgeon in civil practice because of the not uncommon occurrence of such injuries in civil life.

TYPES OF JOINT INJURY

Certain types of joint injuries may be dismissed with a very brief mention. Crushing injuries, with extensive destruction of bones, nerves, and blood-vessels demand amputation. With such cases the important

considerations are when operation should be performed and how much of the limb should be sacrificed. As a general rule operation should be carried out as soon as the patient reacts from shock. Unless he does react the administration of an anæsthetic is invariably fatal.

In cases with a fulminant, rapidly spreading infection involving the peri-articular tissues it is again a question of judgment as to the proper time for surgical intervention rather than a question of procedure. If left untreated these cases invariably succumb within from 12 to 24 hours. Amputation will save a few. Arthrotomy is of little avail and only helps to hasten the fatal outcome.

Through-and-through bullet wounds with punctiform wounds of entry and exit, and without local symptoms of bone injury, hæmorrhage, or infection, should be treated conservatively by rest and immobilization. When the exact extent of injury is ascertained the question of further treatment, particularly as to the time when mobilization should be begun, can be determined.

Aside from the types mentioned, joint injuries may be divided into three general groups: those without penetration of the synovial membrane, penetrating injuries and perforating injuries. The treatment indicated depends upon the interval of time that has elapsed since the receipt of injury, the extent of the associated bony injury, and the presence of lesions elsewhere in the body.

Since a favorable outcome depends so largely upon the promptness with which treatment is instituted after injury, and since in the majority of cases of gunshot wounds of the joints occurring in civil life it is possible to care for cases within a few hours after the receipt of injury, we believe that it is this phase of the problem which is of particular interest to the surgeon today.

The importance of an X-ray examination preceding operation is self-evident. A stereoscopic picture is most valuable if it is possible to study the picture. If a reflecting stereoscope is not available and the surgeon may not leave the operating theater, two plates taken at right angles to each other may serve to give the necessary information.

Non-penetrating injuries. These are due to contusions, to tangential or gutter wounds, to wounds from missiles travelling at a low rate of speed, or to injuries of the bone near the joint with fissure fractures extending to the articular cartilage.

With tangential wounds or wounds in which a foreign body lies close to the synovial membrane the ideal treatment is primary excision of the damaged tissue, removal of all foreign material, and suture. Under ordinary conditions the synovial membrane should not be opened. Not uncommonly, however, the contused and distended synovial membrane

will bulge into the wound because of the presence of fluid within the joint cavity. If it is thought advisable to relieve the tension, the synovial cavity may be emptied through an opening large enough to accommodate an aspirating needle of large caliber, and closed again with a single suture. A compression bandage should be applied and the limb immobilized with extension in a Thomas splint. Should it subsequently become necessary to aspirate the joint, this should be done from the side opposite to the wound in order to prevent a leakage of fluid over tissues already injured and susceptible to infection.

With injuries of the bone near a joint it is not unusual for fissure fractures to extend to the articular surface, and permit transmission of infection into the joint cavity. If removal of the foreign body and infectious material which has been carried into the bone is accomplished promptly, and if cleansing of the wound track is carried out thoroughly, the joint cavity is not likely to become infected, even though it may become distended with fluid.

A case in point is that of a soldier who sustained a penetrating wound of the popliteal space close to the midline and about 2 inches above the lower end of the femur. The foreign body was localized but no X-ray plates were made. (This incident occurred at a casualty clearing station during the height of the battle of Cambrai in November, 1917.) The wound was excised, but the foreign body was buried so deeply in the medial condyle of the femur that it could not be seen nor distinguished by palpation from the bony tissue surrounding it.

The following day the patient's temperature reached 104°, and the joint was swollen and painful. X-ray examination showed a foreign body, roughly a cube about 1 cm. in each dimension, lying in the medial condyle, and a fissure fracture extending into the joint.

The joint was opened through a medial incision and some blood-stained fluid evacuated. The synovial membrane covering the medial condyle was dark and mottled. Through a higher, extra-articular incision the foreign body was removed and the cavity in the bone thoroughly curetted. Both wounds were sutured, a paraffin gauze drain was left in the original posterior wound, and the joint was immobilized. The patient's fever gradually subsided and the temperature became normal on the fourth day. Recovery thereafter was uneventful.

The accurate repair of the torn and lacerated ligaments about the joint, particularly in wide gutter wounds with a considerable loss of tissue, is of great importance in the eventual restoration of joint function. While the primary consideration is a complete *débridement* and wound healing by first intention, one must never forget the importance of preserving the peri-articular structures if a useful joint is to be secured.

Penetrating injuries. Penetrating injuries vary in severity from tiny perforations of the synovial membrane without bony injury to extensive destruction of the soft tissues and structures that form the articulation. If the wound is caused by tiny shell splinters or smooth bullets, little foreign material may be carried into it, but more commonly fragments of clothing, bits of metal, infected skin or other foreign substances are forced into the tissues by jagged, irregularly shaped missiles. Such foreign substances are practically always infected, often with virulent organisms. Unless they are promptly removed a serious outcome is inevitable.

Just as with wounds elsewhere, the exact treatment depends on a number of conditions: the extent of time that has elapsed since the receipt of the wound, the condition of the patient, the presence of other wounds, and the facilities at hand for carrying out the type of procedure indicated.

Leriche (2) believes that in every penetrating joint wound, except those caused by tiny splinters, exploratory arthrotomy is indicated if the patient is seen within six or eight hours of the receipt of injury, and if suitable operating facilities are available.

The essential consideration in the treatment is the complete removal of all foreign and infected material. In the case of extensive bony injury this may be a tedious and difficult task, for not uncommonly fragments of detached bone may be driven into the soft tissues over a wide area. Every such detached splinter or fragment of bone not only injures the soft tissues through which it passes, but becomes a foreign body and a potential source of further injury.

Just how extensive the operative procedure should be in these cases has been the subject of much discussion. To some surgeons the removal of foreign bodies and débris and of loose bone fragments, with resection of the injured soft tissues, has seemed sufficient. To others it has seemed that a primary resection of the joint was indicated more frequently than was generally so considered. The Lyons school of surgery in particular has been considered as advocating resection, without sufficient indications, for many cases of joint injury. A careful reading of Leriche's book, however, will help to correct this impression. Leriche says in his preface, "* * according to my experience it is rarely that one is called upon to make use of resection."

To generalize concerning the treatment of cases presenting such a tremendous range of injuries is difficult. The ideal is removal of all the injured soft tissues, and of small detached bone fragments, cleansing of the joint cavity, suture of the synovial membrane, and of the external wound. Removal of all the injured soft tissues may be tremendously difficult. Not uncommonly, large vessels or nerve trunks are exposed.

perhaps contused, and overlaid with infectious material. Bone fragments of considerable size may be completely detached, yet appear clean and viable. Leriche advises careful subperiosteal removal of such fragments. Duval (1) believes that if such fragments are essential for the preservation of the joint outline they should be cleansed and replaced. If necessary, they should be held in place by screws or nails. He cites a case in which Gatlier removed a completely detached femoral condyle, cleansed and replaced it with good results. Jones similarly believes that fragments of any size should be cleansed, if necessary, and replaced in the hope that they will act as autogenous bone grafts.

All surgeons agree that the important considerations are complete removal of the infected tissue and preservation of the joint outline. Although, as Leriche has pointed out, the cleansing of fissure fractures extending from a joint is very difficult of accomplishment, it seems to us that if operation can be performed early and if the wound can be rendered aseptic, there is every reason for replacing bone fragments, both to preserve the outline of the articulation and to obviate the presence of a dead space for the accumulation of blood and joint fluid. To hold such fragments in place with a suture or two is wiser than to insert nails or screws. Foreign bodies, even if sterile, are undesirable and sources of danger.

In cleansing the joint cavity it is important to secure a good exposure. To cleanse a knee-joint, for example, by irrigation through an opening one or two inches in length is manifestly impossible. If the joint can be left dry and clean by carefully sponging every recess and removing all clotted blood and foreign material, the chances of a complete recovery will not be invalidated by an adequate incision.

Suture of the synovial membrane may be difficult in the case of extensive injuries, but it is of primary importance. Unless the joint can be closed, infection is inevitable. If the synovial edges cannot be brought together, closure may be accomplished by means of a plastic flap, but the apposition of serous surfaces is so important that no other form of closure will compensate for it.

Reconstruction of the ligaments and tendons about the joint is of especial importance in the functional result. This is particularly true with reference to the quadriceps extensor at the knee, and the triceps at the elbow. Primary tendon suture should be practised unless the loss of tissue renders it absolutely impossible.

Closure of the superficial tissues is the best prophylactic against wound infection. For a time, during the earlier years of the war, the synovial membrane was sutured and a drain left in the open wound down to the synovial membrane. This course was frequently followed by dis-

aster. Only when the injured tissues were completely excised and the wound closed, were the results consistently good. In cases with extensive loss of the superficial tissues skin grafting at the earliest possible date, preferably by means of a pedicled graft, is the procedure of choice.

Perforating injuries. Perforating injuries, unless caused by bullets travelling at a high rate of speed, are more serious than penetrating wounds simply because of the greater extent of the injury. In addition to the entry wound there is not uncommonly a severe, more extensive wound of exit due to the damage caused by the bone fragments which are driven through the soft tissues by the impact of the missile. Not uncommonly a small wound of entry is associated with a jagged irregular wound of exit, apparently out of all proportion to the size of the missile. In such cases the more serious injuries lie on the side of the exit wound. The general methods of procedure do not differ from those in penetrating injuries.

INJURIES OF INDIVIDUAL JOINTS

The shoulder-joint. If caused by a small shell fragment, penetrating wounds of the shoulder-joint may be difficult of diagnosis, because the joint is so completely covered by thick layers of muscle. If conservative treatment is carried out, the fact that the joint cavity is involved may only become apparent after two or three days, when the appearance of high fever and of the symptoms of sepsis, associated with a diffuse swelling of the entire region of the shoulder, calls attention to the true character of the injury. Gas bacillus infection in the muscles of the shoulder girdle is a not uncommon accompaniment.

With injuries due to larger missiles, crushing of the cancellous head of the humerus, with fissures extending into the joint cavity, is not uncommon. Excision of the wound followed by removal of the injured bone, even if it necessitates removal of the greater portion of the head of the humerus, is frequently followed by good results if the contour of the articulating surface can be preserved.

If the head is detached or completely shattered, subperiosteal resection of the loose bone fragments is the operation of choice. In such cases resection has practically been carried out by the missile, and it only remains to preserve as much tissue as is consistent with a complete *débridement*.

As a rule, operation will be carried out through an enlarged entry wound. If this is inconvenient the classical incision for exposure of the joint, through the anterior fibers of the deltoid lateral to the long head of the biceps, may be used. The position and importance of the circumflex nerve (n. axillaris) should not be forgotten.

In the event of a probable ankylosis the arm should be maintained in a position of complete abduction, that is, with the arm in a horizontal plane. The most satisfactory apparatus for this purpose is one whose chief support is the opposite, rather than the affected shoulder.

The elbow-joint. Because of the narrow arc of curvature of the joint surfaces at the elbow and because of the close apposition of the articular surfaces, injury of the elbow joint with involvement of only one bone is rare. The severity of elbow-joint wounds is commonly greater than appears possible from the character of the external wound. Even the X-ray picture is apt to be deceiving, so that on opening the joint one frequently finds injuries much more extensive than were anticipated. The importance of the elbow from an economic standpoint, the difficulty of controlling an infection once under way, and the danger of ankylosis, perhaps in a disadvantageous position, render early exploratory arthrotomy an imperative measure if there is doubt as to the benign character of the injury, or as to the presence of infectious material in the wound.

Bilateral incisions are usually necessary. The lateral incision is made just lateral to the origin of the supinator longus (m. brachioradialis) and in the direction of the muscle fibers; the medial incision along the medial condyle. The position of the ulnar nerve must always be borne in mind; in case of resection it should be isolated at the beginning of the operation.

The extent of injury that can be treated by esquillectomy, that is, by simple removal of injured bone, depends on the extent of involvement of the articular surface. Leriche advises limited arthrotomy and esquillectomy for parietal fractures and cases of cancellous crushing by a missile imbedded in bone; primary resection for all fractures into the joint and for all bony injuries of an explosive nature. He reports remarkable functional restoration following recovery in a number of cases of immediate primary resection. The majority of surgeons hold that such an operation is indicated only where the injury itself has virtually amounted to a resection, or where an infection has developed that can be adequately drained in no other way.

We have not had the opportunity of seeing the final results in any of Leriche's cases, nor the results in any cases in which we were certain that the resection was carried out with the careful attention to technique, particularly to the subperiosteal removal of bone, on which he lays so much stress. In those cases which we have seen the results were far from admirable—a flail elbow with a weak forearm, in our estimation a much less favorable condition than ankylosis at an angle of 80° or 100°.

Injuries of the wrist and hand. The commonly benign character of injuries of the wrist and hand, unless they are associated with such a considerable loss of the soft tissues as to make infection inevitable, serves

to impress anew on the surgeon the fact that it is the presence of the infection carried in from without that is the most important factor in determining the result. As a source of this infection the patient's clothing is first in importance, the skin the next, and the missile itself the least important. In injuries of the wrist and hand fragments of clothing are usually not carried into the wound. Unless the missile is large and jagged, little of the superficial tissues may remain adherent to it.

Primary arthrotomy with removal of the foreign body and of the injured tissues, followed by suture, will usually be followed by favorable

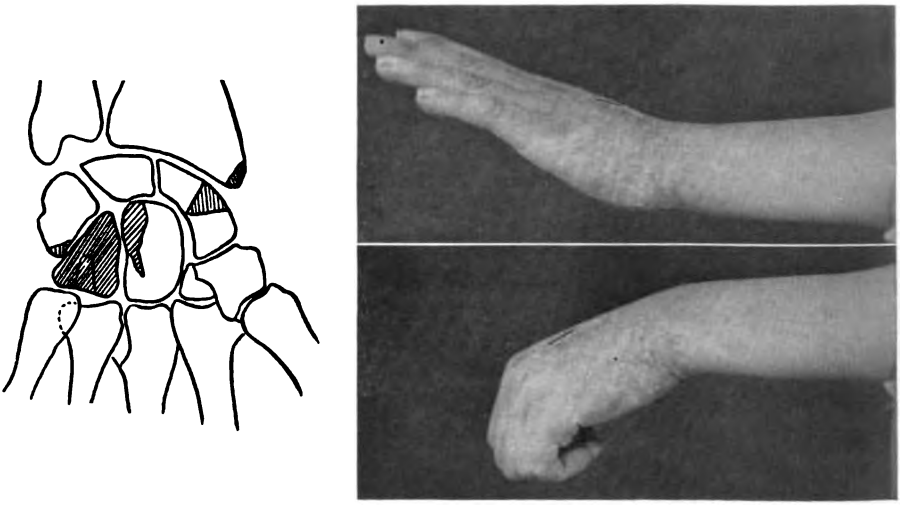

FIG. 229a. PERFORATING WOUND OF THE WRIST-JOINT TREATED BY PRIMARY EXCISION AND SUTURE. (*Duval.*)

results. The importance of avoiding injury of the tendons by lateral incisions, the position of the vessels, and of the median and ulnar nerves must be constantly borne in mind.

Injury of the carpal joints is more common than injury of the wrist-joint itself. If treated promptly after injury, infection is not likely to spread from one joint to another, because of the rather narrow channels of communication between the carpal joints.

With injuries of the metacarpal and interphalangeal joints the question of primary amputation frequently arises. The patient's occupation, the probable duration of disability, and the question of the final functional result will determine the character of the procedure to be carried out.

The hip-joint. The severity of injuries of the hip-joint is directly associated with two anatomical factors: the depth and inaccessibility of the joint, and the presence about the joint of thick muscular masses which form a favorable location for the development of anaerobes. So important is this latter factor that all injuries in the region of the hip must be watched with the utmost care. Small penetrating wounds, which in other regions of the body would cause little concern, may be the source of serious infection.

With involvement of the joint as evidenced by X-ray examination, cleansing of the wound track and exploratory arthrotomy should be carried out at the earliest possible moment. The most satisfactory avenue of approach is through an anterior incision between the tensor fasciæ femoris laterally, and the psoas and sartorius medially.

With cancellous crushing of the upper end of the femur *débridement* and removal of the damaged bone will usually suffice. With fractures of the neck or complete separation of the head the treatment to be followed will depend upon the promptness with which operation has been carried out, upon the extent of comminution, and upon the amount of wound contamination. The common occurrence of non-union without operative interference following simple fractures of the neck of the femur, and the difficulty of draining an infected hip-joint without removal of the head must always be borne in mind.

The knee-joint. Gunshot wounds of the knee-joint have pre-eminently held the attention of surgeons during and since the war because of their frequency, because of their seriousness, and because the contrast between the results of correct and incorrect treatment is so striking that even the most disinterested must be impressed.

The knee-joint presents certain definite anatomical peculiarities which are of importance in a consideration of injuries involving the joint. It is comparatively superficial in its entire circumference except posteriorly, where it is covered by a considerable thickness of soft tissues. It depends for its stability upon the ligaments, particularly the intra-articular crucial ligaments, rather than upon the contour of its articular surfaces. These surfaces are more nearly plane than concavo-convex, and lie practically in a horizontal plane and parallel with one another. The crucial ligaments divide the joint more or less completely into two compartments, an anterior and a posterior; the larger part of the former is formed by the suprapatellar pouch, which extends upward on the anterior surface of the femur underneath the quadriceps for a distance of from 7 to 10 cm. above the lower margin of the femur. The posterior surface of the patella, a sesamoid bone within the tendon of the quadriceps, forms a part of the anterior wall of the joint cavity. No other

joint can be exposed in its entirety so readily or with so little injury of the surrounding muscles or of the joint capsule.

The types of injury following gunshot wounds of the knee are so varied that only general principles of treatment can be given. In addition to the completeness of the primary *débridement*, including if necessary subperiosteal removal of a shattered patella, a successful outcome

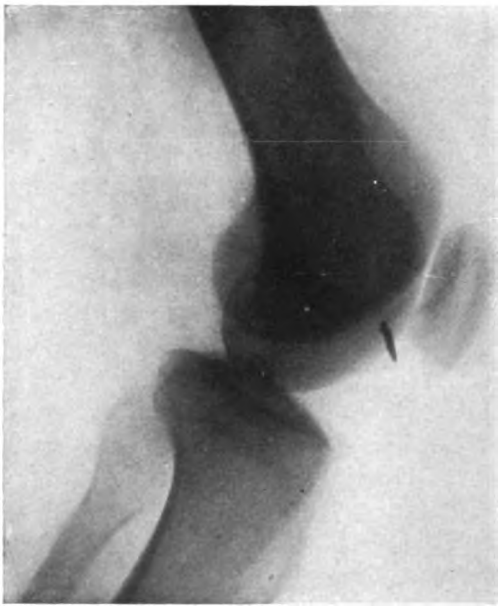

FIG. 229b. PENETRATING WOUND OF THE KNEE-JOINT SUCCESSFULLY OPERATED UPON FIFTY-SIX HOURS AFTER INJURY.

depends largely upon the possibility of closing the synovial cavity and the joint capsule, and suturing the superficial tissues.

Even as long as 48 hours after the receipt of injury arthrotomy, followed by closure, may be completely successful if *débridement* is complete. In the case illustrated in Figure 229b a shell fragment was stuck in the articular surface of the lower end of the femur. The joint cavity was distended with thick, blood-stained fluid. Fifty-six hours after injury the wound was excised, the joint cavity washed with salt solution and the wound closed in layers. Recovery was prompt and uneventful.

The extent to which the articular surface may be affected without vitiating the result is a matter of dispute. As was said above, Duval be-

lieves that it may be possible in certain cases to restore a separated condyle and still secure primary union. Figures 229c and 229d illustrate the extent of bony injury and the functional result following *débridement* and closure in two of Duval's cases. The fact that primary resection is almost inevitably followed by ankylosis makes it imperative to exert every possible endeavor to preserve the integrity of the joint no matter how badly damaged.

Arthrotomy is advantageously carried out through lateral incisions on either side of the patella. If these do not afford an adequate exposure the

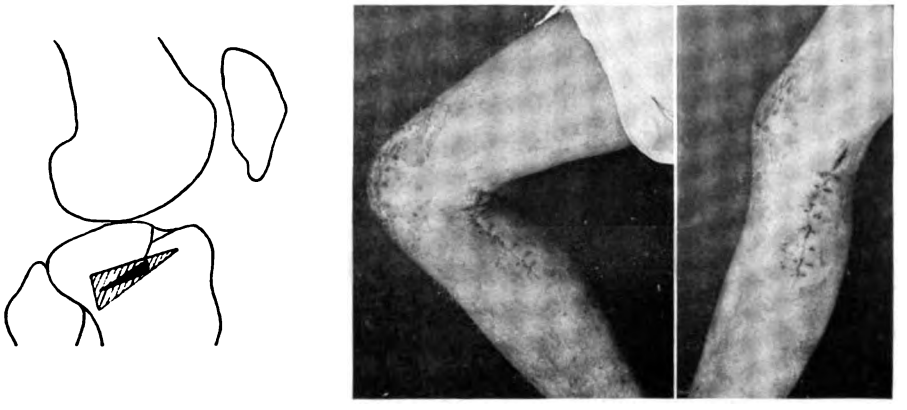

FIG. 229c. PENETRATING WOUND OF THE KNEE-JOINT TREATED BY DÉBRIDEMENT AND PRIMARY CLOSURE. (*Duval.*)

incisions may be connected below by cutting across the patellar tendon. The patella may then be thrown upward and the joint cavity widely exposed by partially flexing the leg on the thigh.

Wounds of the ankle and foot. Joint wounds of the lower extremities are characterized by the development of serious infection, due to the frequency with which the omnipresent infectious material is carried into the wound from without. This is particularly true of wounds of the foot.

Wounds of the ankle, like those of the elbow, are invariably associated with fractures of the surrounding bones. Frequently several bones are involved. The difficulty of securing an adequate exposure, without seriously impairing the integrity of the joint, renders arthrotomy for *débridement* a tedious and difficult operation.

The most advantageous incisions are a medial incision along the posteromedial border of the tibia, curving forward from the tip of the

malleolus, and a lateral incision at the anterior edge of the fibula, beginning about 2 inches above the tip of the malleolus lateral to the peronæus tertius, and extending to the level of the cuboid.

With extensive injury of the astragalus (talus), complete removal of the bone gives the best chances for rapid recovery. With injuries in-

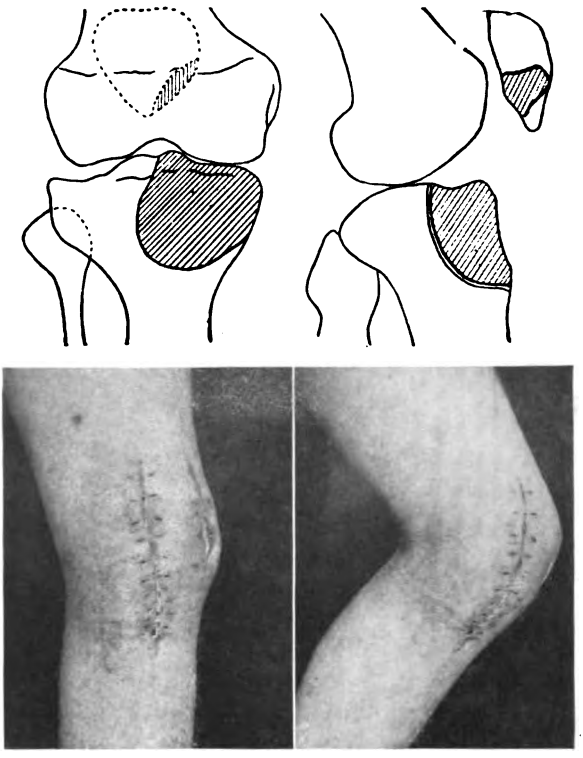

FIG. 229d. PERFORATING WOUND OF THE KNEE-JOINT TREATED BY DÉBRIDEMENT AND PRIMARY CLOSURE. (*Duval.*)

volving the calcaneus, *débridement*, with careful removal of the injured bone, is usually followed by good results. It is important to preserve the insertion of the tendo Achilles and the weight bearing surface of the heel.

COMPLICATIONS

Aside from primary injury of the neighboring blood-vessels and nerves there is essentially only one complication of gunshot wounds involving the joints—infection. Abscess formation, secondary hæmorrhage,

osteomyelitis, thrombophlebitis, œdema of the extremities, ankylosis, "large white joints" are all secondary, and the direct results of joint infection.

We have dwelt at some length on the primary treatment of joint injuries because it is only during the hours immediately following injury that treatment can be successfully carried out. When infection has developed so that drainage becomes necessary, the indications for treatment are no longer definite and clearly defined, but depend upon many variable

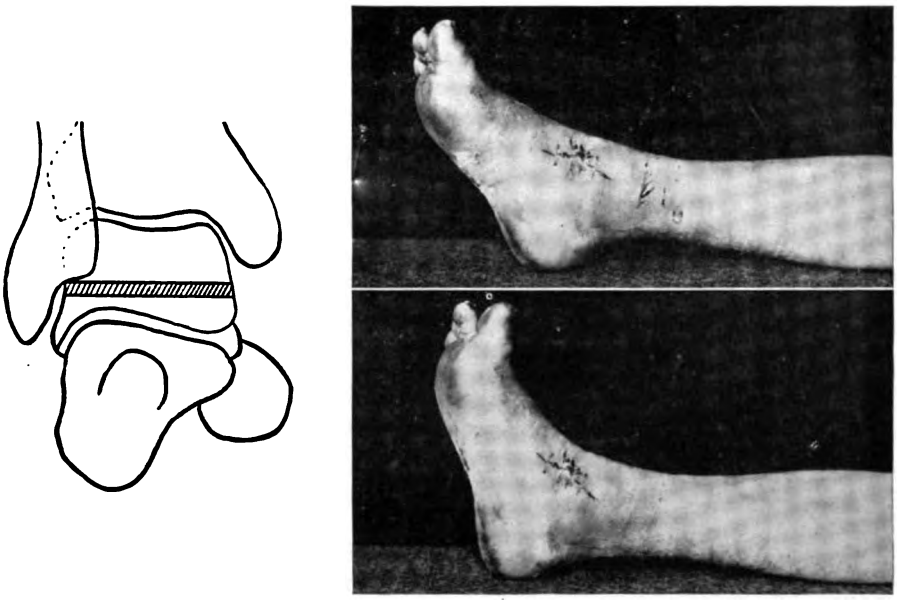

FIG. 229e. PERFORATING WOUND OF THE ANKLE-JOINT TREATED BY DÉBRIDEMENT AND PRIMARY CLOSURE. (*Duval.*)

factors. "Drainage, like amputation, is a confession of failure," and the treatment of failures is difficult and discouraging.

The symptoms of joint infection are readily recognized; continuous irregular fever, rapid pulse, localized pain, swelling and tenderness with gradual involvement of the peri-articular tissues point definitely to its presence.

Where the joint is surrounded by thick muscle layers, as in the case of the shoulder and hip-joint, the local signs may be masked by the diffuse character of the swelling, but the general symptoms, the intense pain on movement, with tenderness and swelling about the deltopectoral groove

in the case of the shoulder-joint, and high up in Scarpa's triangle in the case of the hip-joint, make the diagnosis evident. Involvement of the knee-joint is more easily determined. Swelling of the suprapatellar pouch appears early, and aspiration is a simple matter.

If there is a question as to the presence of infection, the joint should be aspirated. If culture shows the presence of a slight infection or of an organism of low virulence, it may be permissible to wait and repeat the aspiration subsequently. If the infection is due to the streptococcus, or if the general symptoms show an increasing and serious toxæmia, drainage must be instituted promptly.

In the case of the shoulder-joint an anterior arthrotomy, as described above, gives an opportunity for posterior dependent drainage through a stab wound on the back of the shoulder.

With infection of the elbow-joint drainage is always unsatisfactory. Lateral incisions, made with due regard to the important tendons and the ulnar nerve, will relieve tension during the acute stage of the infection. The marked convexity of the lower end of the humerus and the concavity of the articular surface of the ulna render drainage by simple incisions hopelessly inadequate. When the acute stage of the infection has subsided joint resection may become imperative before adequate drainage is secured.

Lateral incisions usually suffice to drain the wrist-joint. Drainage of the carpal joints is almost impossible. Joint infection usually goes on to osteomyelitis with eventual removal of several or all of the carpal bones.

Drainage of the hip-joint, like drainage of the elbow-joint, is notoriously unsatisfactory and difficult. An anterior arthrotomy gives an opportunity for the insertion of a tube through the gluteal muscles to the posterior and dependent portion of the joint cavity. Not uncommonly removal of the femoral head is necessary before satisfactory drainage is secured.

The knee-joint can frequently be successfully drained through lateral incisions on either side of the patella. If infection has involved the posterior compartment of the joint, i.e., that portion behind the partition formed by the crucial ligaments, the case is much more serious. Drainage through the popliteal space is a hazardous procedure. Abscess formation and secondary hæmorrhage are common complications of this type of drainage. Abbott reported successful results in the drainage of the popliteal space through a 4-inch incision along the medial border of the space over the upper end of the tibia. Through this incision drainage was introduced under the insertion of the popliteus muscle into the joint cavity.

Drainage through a vertical incision on the anterior aspect of the thigh into the suprapatellar pouch, with the limb sufficiently elevated to

render the drainage opening dependent (Poncet's method) has given satisfactory results in some cases. Speed employed the same incision and placed the patient in the prone position for several hours two or three times daily.

Drainage of the ankle-joint is carried out through lateral incisions. Removal of the astragalus may be necessary before satisfactory drainage is established.

In any case of joint infection the use of tubes in the joint cavity is to be avoided. They rapidly become enmeshed in a fibrinous exudate, and serve only as a source of constant irritation.

The use of fluids for irrigation has steadily decreased. Salt packs, saline solution, mercuric chloride, ether, magnesium chloride and dilute iodine solution have all had their advocates. Only one, Dakin's solution, has proved successful with any degree of uniformity for a prolonged period of time. Instead of being used for indefinitely prolonged periods, as at first, the use of Dakin's solution is being restricted to attempts to sterilize the infected area by intensive treatment over a brief period of time, that is, from 12 to 14 days (Hepburn,[3]). If the joint infection cannot be controlled within two weeks the source of trouble must be sought elsewhere—in the adjoining bone or in the soft tissues. Osteomyelitis and secondary abscess formation are such common complications of joint injury that their presence must be constantly suspected.

THE AFTER-TREATMENT OF JOINT INJURIES

The after-treatment of joint injuries has been revolutionized in late years almost as completely as the primary operative treatment. Due chiefly to the teachings of Willems and his followers, active mobilization is begun at an early date in all cases of joint injury except those in which large fragments about the joint are liable to displacement. Instead of allowing the muscles to atrophy and the joints to become stiff and ankylosed from disuse, the patient is urged from the very outset to move the joint both passively and by the voluntary contraction of his own muscles.

Willems urges the importance of such exercise not only in cases of internal derangement of the joint with the accumulation of fluid in the joint cavity, and in clean cases following operation, but also in cases of joint infection. He believes that after arthrotomy has been carried out active movement of the joint is the most effective method of maintaining drainage, and that for this purpose it far surpasses irrigation or any other known method of getting rid of intra-articular accumulations of fluid.

Because of the very successful results Willems ([4]) has secured, the

methods he has advocated have been widely and sometimes indiscriminately used. The use, for example, of active motion and of forceful manipulation of a joint during the height of an acute metastatic infection is in no way comparable with active mobilization following an accumulation of fluid in the joint cavity because of a sudden twisting or wrenching, or with mobilization of a joint that has been injured directly by a bullet or shell fragment. In the latter cases the patient is usually in good health, local resistance develops rapidly and any local infection tends to become

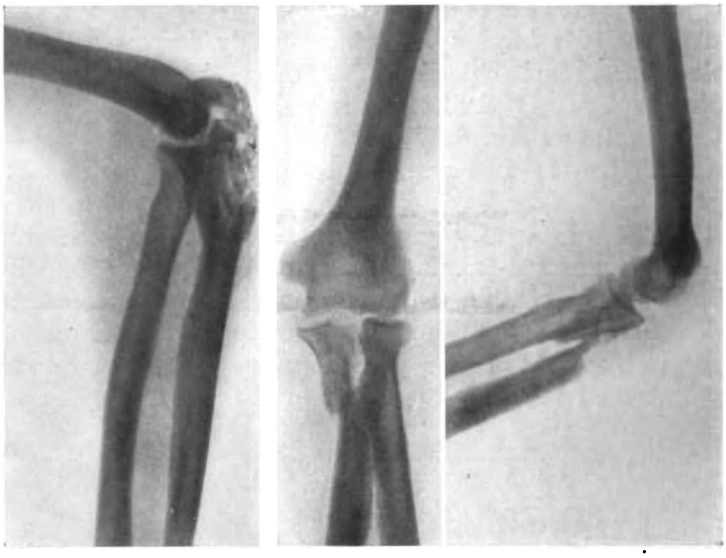

FIG. 229f. SKIAGRAM OF ELBOW-JOINT SHOWING EXTENT OF BONE INJURY. (*Willems.*)

walled off promptly. In the former the patient is suffering from a generalized infection, a septicæmia in which the joint has become involved because of a slight, localized trauma. In such a case the important consideration is not the preservation of joint function, but the combating of a generalized infection by every means possible. One of the most important is absolute rest. To force movement during the acute stage of the disease in a joint which is the seat of a virulent metastatic infection seems to us as unwise as would the injection of a culture of the causative organisms directly into the blood stream.

If purulent arthritis develops following local injury, as a gunshot wound, the case is quite different. With individuals in good health the

infection is rapidly walled off. In such cases wide arthrotomy openings with active mobilization, as advocated by Willems, will undoubtedly help to secure the most complete drainage and to prevent, if it is at all possible, the development of ankylosis.

That this method is not always successful emphasizes the fact that it is upon the general resistance of the patient and the definite limitation of the infection that its success depends. Orr ([5]) cites the case of an officer who developed a purulent arthritis secondary to a gunshot wound of the knee-joint. Following arthrotomy and Carrell-Dakin treatment,

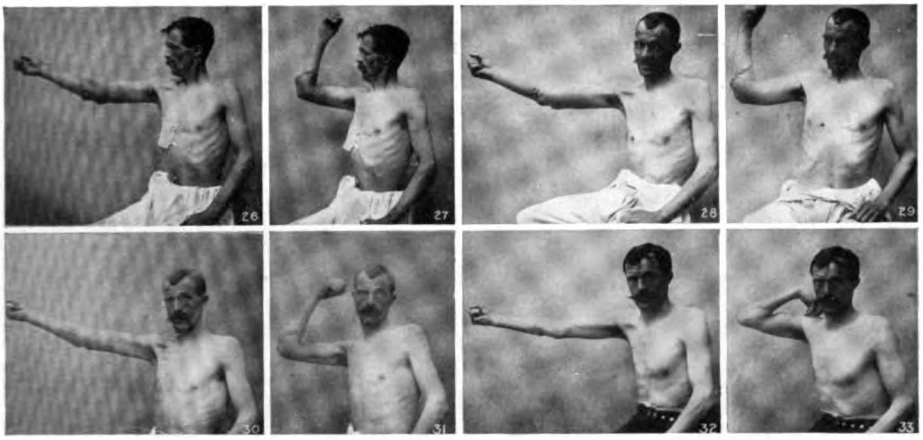

FIG. 229g. RESTORATION OF FUNCTION ACCOMPLISHED BY ACTIVE MOBILIZATION IN THE CASE ILLUSTRATED IN FIGURE 229F.

combined with active motion twice daily, the wounds healed, so that efforts were made to increase the range of motion. Just as the patient was about to leave his bed an acute exacerbation of the process developed, osteomyelitis of the tibia supervened, and amputation was performed to save the patient's life.

Sudden rise of temperature, acute pain, and peri-articular swelling with signs of inflammation coming on after active mobilization are definite indications of a dissemination of infection, and of the need of caution in carrying out active movements.

The degree of restoration of function attainable after extensive joint injury, in cases that have been promptly cared for and conscientiously treated after operation, is little short of amazing when one recalls the results attained in the treatment of similar injuries only a few years ago. The degree of function attained in one of Willems' cases is illustrated in Figures 229f and 229g.

Many helpful agencies are available in securing the best possible results. The use of sunlight, of moist and dry heat, baths, massage, of electrical stimulation, of graduated muscle contractions by the aid of the Bristow coil, and of exercises of various types, is discussed in Section IX, Volume I. No one method can be used to the exclusion of others. The best results will be attained by a judicious combination of the best features of all of them.

REFERENCES

1. Duval, P. Surg., Gynec. & Obst., 1919, xxix, 222-235.
2. Leriche, C. The Treatment of Fractures, vol. i, London, 1918.
3. Hepburn, H. H. Brit. M. J., 1918, ii, 338-340.
4. Willems, C. Surg., Gynec. & Obst., 1919, xxviii, 546-554.
5. Orr, H. W. Surg., Gynec. & Obst., 1919, xxix, 492-496.

CHAPTER II

WOUNDS OF THE LONG BONES

IN WAR surgery there are probably no cases which show such a marked difference from those seen in civil hospitals, both as regards the lesions resulting and the methods of treatment required, as do gunshot wounds of the diaphyses. Such cases form one of the most important groups of wounds, both because of their frequency and because of the varying problems to which every fracture gives rise in the matter of treatment. When we remember that in civil practice the proportion of fractures is not great in comparison with other surgical conditions, that the majority of fractures are of the closed or simple type, and that open or compound fractures are not complicated by extensive wounds of the surrounding tissues, it is easy to understand that fractures caused by projectiles and associated with extensive injuries of the adjacent tissues, and further complicated by the presence of infection, give rise to many difficult problems which are seen under no other conditions. Furthermore, such injuries are frequently multiple, they are often associated with severe wounds elsewhere in the body, and may be complicated by lesions of blood vessels and nerves.

Statistics compiled from the records of the American Women's War Hospital show that fractures occur in about one-fifth of the total number of wounded. This number includes fractures of the closed type caused by factors incident to warfare, such as the caving in of a trench, mine explosions, falls from a wagon or gun limber, and kicks from horses or mules.

Of the total number of cases under observation the long bones were found to be involved in 52.18 per cent of cases. In this group were included fractures of the humerus in 25 per cent of cases, fractures of the radius in 12.5 per cent, fractures of the ulna in 15.6 per cent, fractures of the femur in 9.4 per cent, fractures of the tibia in 21.9 per cent, and fractures of the fibula in 15.3 per cent. With fractures occurring in bones other than the long bones, the bones of the hands, of the feet, of the skull, and of the pelvis were involved most frequently in the order named.

Infection occurred in 76.9 per cent of the cases; 23.1 per cent were not infected. Six per cent of cases were complicated by non-union, 7.1 per cent by nerve injury, and 18.9 per cent by ankylosis.

TYPES OF INJURY

The various lesions encountered in gunshot wounds of the long bones present a wide variation in extent and degree. For purposes of classification they may be divided into several groups.

Contusions. In this group of cases the lesion may be small and often imperceptible; sometimes the only injury of the bone is a laceration of the periosteum. Such wounds are caused by projectiles with a low velocity which strike the bone directly, or by smaller projectiles which strike tangentially and injure the shaft of the bone very superficially.

Fissures. Fissures or cracks in the shaft of the bone are very frequent and usually occur in connection with other types of fracture, but such injuries may be isolated and very extensive. They are often difficult to diagnose, as they give rise to very few symptoms other than the initial pain of the wound, and rarely give rise to any disability or abnormal mobility. The diagnosis may be made when the wound in the external tissues is being disinfected, or by means of the X-ray. Such wounds are caused by projectiles with a low velocity striking the bone either directly or tangentially.

Contact fractures. These are caused by machine gun or rifle bullets, by shrapnel bullets, by shell and grenade fragments, and by deformed or deflected bullets which strike the shaft of the bone either transversely or obliquely; they may or may not be associated with large splinters of bone and longitudinal fissures. The resulting deformity may be very slight or considerable, depending upon whether the fragments are widely separated, or held in place by intact periosteum and fascia.

In fractures caused by projectiles with a higher velocity there is frequently a comminution of the splinters, but there is little loss of substance as the comminuted fragments are usually held in place by the periosteum.

The diagnosis of such fractures is easily made by means of the X-ray, and usually shows the projectile which caused the injury lying in close proximity to the lesion in the bone.

Perforations of the diaphysis. Perforations may involve one side of the diaphysis alone or the entire thickness of the bone. The first type is usually caused by bullets with a low velocity, and is associated with longitudinal fissures radiating from the point of perforation and due to the contact of the bullet. There is frequently a small rounded or oval wound in the shaft of the bone from which the fissures radiate. Complete perforations are caused by bullets with a high velocity and may be simple or comminuted. The wound of entrance in the bone is round or oval, and the track through the bone can usually be seen with the aid

of the X-ray. At the point of entrance there is some slight splintering and pushing outward of separated bone fragments. While there may be only a few detached splinters about the aperture of exit, more often there is a considerable degree of comminution and loss of bony substance on the side from which the projectile emerges. The size and position of the detached fragments indicate the velocity of the bullet causing the injury. The greater the velocity the greater is the degree of comminution and the greater the area over which the detached fragments are driven.

Delorme states that "when the velocity is excessive, free splinters are no longer carried along, but are violently thrown out in the form of a sheath. They no longer have any exact situation. They bury themselves in the soft parts at a variable distance from the track, and some of them break out of the limb through numerous separate orifices." He further states that "the dimensions of the splinters, like their number, are inversely in proportion to the velocity of the projectile—the less the velocity, the larger the adherent splinters and the less their number, and conversely."

Grooved and gutter wounds. Such injuries are caused by projectiles which strike the diaphyses tangentially, and which cause a groove or gutter in the shaft of the bone. From this groove radiating cracks and fissures may extend for a considerable distance.

Fractures by indirect violence. Such fractures are essentially fractures by contact and are associated with a direct injury of the same bone elsewhere. In the leg we sometimes find associated with an extensive direct fracture of the tibia an indirect fracture of the fibula, due apparently to the sudden and violent vibration established by the missile inflicting the wound (Fig. 287). A similar condition is occasionally seen in the forearm, where either the radius or the ulna may be fractured by direct contact of the projectile, while the shaft of the opposite bone presents an indirect fracture.

The diagnosis of the various conditions which have been described may be made by direct inspection of the bone injury at the time when the wound in the soft tissues is being cleaned up, and by the X-ray. In those cases where there is a considerable degree of comminution palpation of the injured part reveals a diffuse crepitation, but it is important in all cases of gunshot fracture that no undue manipulation of the injured part should be made, as otherwise splinters which are still adherent to one another and which are attached by periosteum may become separated and their attachments broken. The size of the wounds of entrance and exit together with the direction of the track sometimes gives us important information. The presence or absence of spicules of bone in the aperture of exit also indicates the degree of comminution which has occurred, as may also the presence of fat globules in the case of extensive comminu-

tion of the long bones. There may be deformity of the part injured, and in many instances the displaced edges of the bone may be felt subcutaneously. The diagnosis of the type of fracture is confirmed by radiographic examination.

Complications of fractures. The severity of the trauma, not only of the soft tissues but of the bone itself, depends upon the size, the shape, and the velocity of the projectile causing the injury, and as in other wounds, the size of the projectile determines to a great extent the severity of the infection and the amount of contaminated matter carried into the wound. In the simple bone lesions caused by projectiles of a low velocity there may be no infection and such wounds may heal aseptically; but where the destruction of soft tissue and of bone tissue is much greater, various complications caused by injuries to other structures may accompany the wound in the bone.

The immediate complications of importance are injuries of the blood-vessels and nerves. Lacerations of blood-vessels, either by the missile itself or by splinters of bone, are common; and frequently go unrecognized until the site of fracture is exposed or until some sudden movement sets up a severe bleeding. Lesions of nerves may be unrecognized because of failure carefully to examine the patient before operation.

Later complications of common occurrence are hæmorrhage and infection. The latter may be of a virulent, rapidly spreading type, usually due to streptococcic invasion; it may be due to anaerobes or to the ordinary pus organisms. Although the patient's resistance may enable him to overcome the immediate effects of infection, involvement of the bone with osteomyelitis and subsequent necrosis are so frequent that such cases form by far the larger part of those undergoing treatment in permanent war hospitals. Secondary hæmorrhage, nerve involvement, arthritis, and ankylosis follow upon long continued infection. Unless every effort is made to check its course muscle atrophy, amyloidosis, and permanent disability are inevitable results.

THE TREATMENT OF FRACTURES

Treatment at the front. The preliminary treatment of fracture cases is important since it determines to a great extent, not only the comfort afforded during transportation, but the entire course of the case. Preliminary treatment is of importance in the prevention of complications such as injuries to blood-vessels, for if such fractures are not properly immobilized in the beginning, the displacement of small fragments during transportation may cause serious injury to adjacent blood-vessels with resulting hæmorrhage.

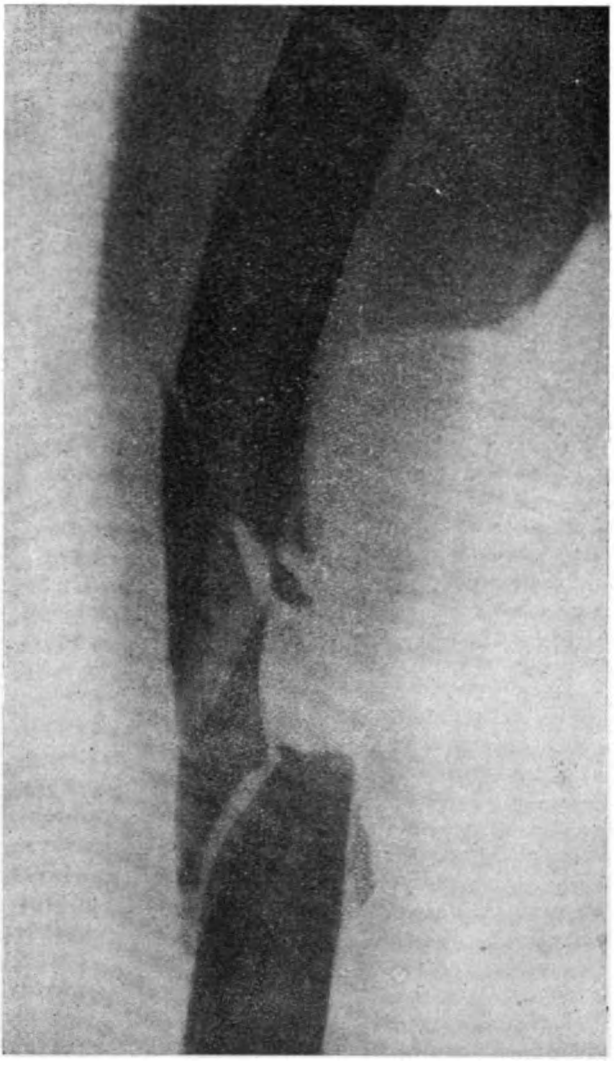

FIG. 230. GROOVING FRACTURE OF HUMERUS CAUSED BY RIFLE BULLET. X-ray shows destruction of part of cortex associated with separation of large fragments in posterior portion. This is one of the more severe types of grooving fracture.

Treatment at the front, therefore, should resolve itself into the disinfection of the skin wounds, the immobilization of the fractured limb, and the application of protective dressings, and the injection of anti-tetanic serum, the more extensive treatment of such fractures being reserved for the base hospitals.

FIG. 231. PERFORATING BULLET WOUND OF HUMERUS WITH FRACTURE AT JUNCTION OF LOWER MIDDLE THIRD. X-ray, taken seven months after reception of wound, shows firm union of shaft.

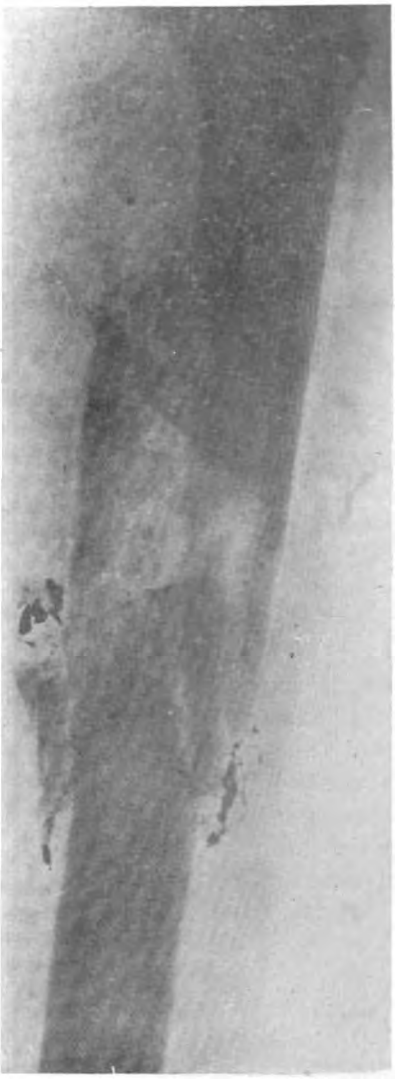

FIG. 232. SHOWS FISSURED FRACTURE OF SHAFT OF HUMERUS CAUSED BY BULLET. There is also considerable displacement and some comminution. Metal from fragmented bullet may be seen in tissues.

Treatment at the Base. This treatment is by far the most important, as it determines not only the rapidity with which these cases become again fit for duty or for discharge, but also determines the future usefulness of any limb involved.

Conservative Treatment. Conservatism should be the rule, and no amputations should be performed unless conditions supervene which threaten the life of the patient, unless gangrene resulting from the occlusion of blood-vessels occurs, or unless it has been definitely proved that there is no regeneration of bone about the site of the injury or that a functionally good member cannot be obtained and that the patient will be far better off with an efficient artificial limb than he would with a limb which would be a constant impediment to him. This is especially true in the case of the leg, a man with a modern, well-constructed artificial leg being able to do more and in a more efficient manner than he could with an improperly healed or deformed leg.

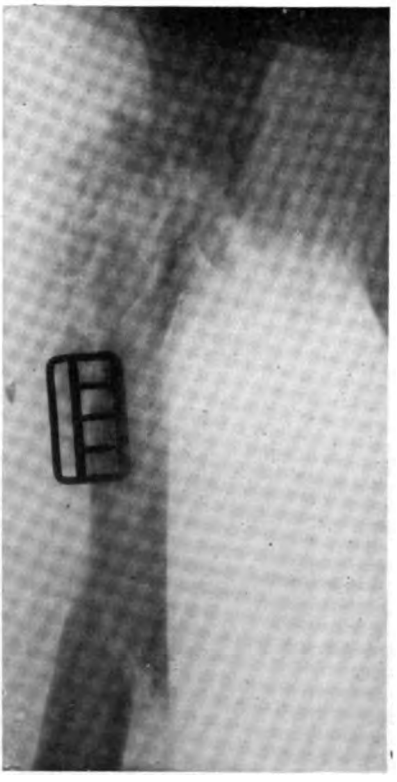

FIG. 233. SHOWS COMMINUTION OF SHAFT OF HUMERUS BY RIFLE BULLET, ALSO INDIRECT FRACTURE 3 INCHES BELOW.

Perforated wounds by bullets as well as small comminutions and fissures associated only with a small wound in the external tissues heal readily if properly immobilized, and in such cases the external wounds usually heal aseptically, as there is practically no contaminated matter carried into such wounds by the bullet which causes the injury.

The larger lacerating wounds caused by deformed or deflected bullets, by bullets travelling at a high rate of velocity and having a divulsive and propulsive effect upon the bone fragments and, therefore, causing a large external wound of exit, as well as those wounds caused by shell and grenade fragments, require much more extensive treatment, not only as regards dressings and proper care, but also as regards the correct alignment and immobilization by suitable apparatus. Such wounds are nearly always infected,

FIG. 234. COMMINUTED FRACTURE OF SHAFT OF HUMERUS CAUSED BY BULLET. Fragments are large and show very little separation.

and the degree of infection is here, as in other wounds, dependent upon the size and shape of the projectile inflicting the injury and the amount of contaminated matter which it carries in with it. In all wounds of the diaphyses associated with extensive lacerated wounds of the external tissues, as well as splintering or comminution of the shaft of the bone itself, conservative measures should still prevail. There is no doubt that if conservatism and patience are practised, many limbs can be saved and useful limbs be obtained in cases which at first seem hopeless.

If infection be present, the treatment in general of such wounds should consist of a free incision in order to obtain efficient drainage, the removal of foreign bodies, such as clothing or projectiles, and also the removal of bone fragments which are detached from all surrounding tissue.

It is an important point, and one which should be especially emphasized, that only those bone fragments which show no periosteal attach-

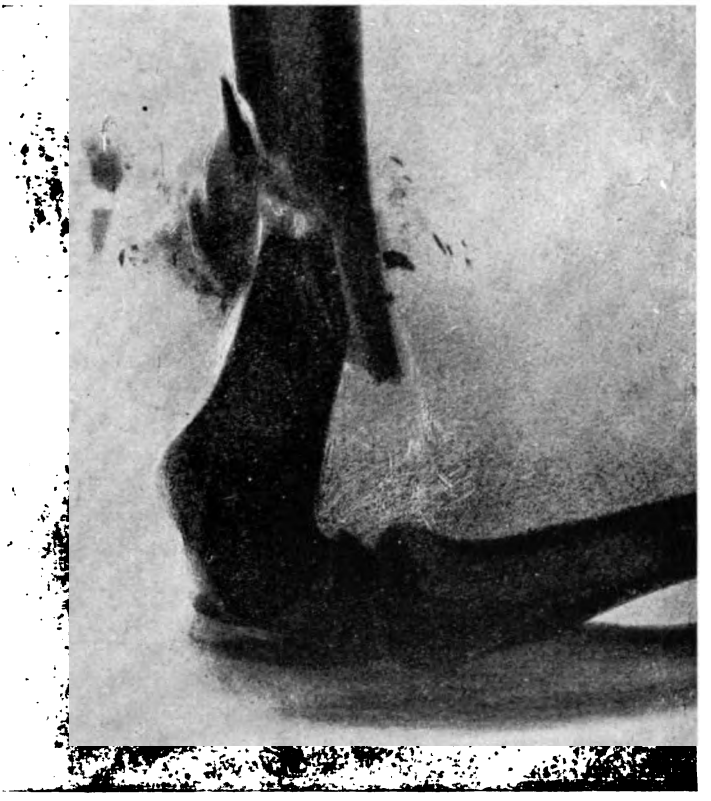

FIG. 235. COMMINUTED FRACTURE OF SHAFT OF HUMERUS CAUSED BY RIFLE BULLET. In this case the fragments are rather large, and there is considerable deformity.

ments or periosteal covering should be removed, and that all bone fragments, no matter how small, which are still attached to the periosteum should be left absolutely alone. These fragments which are still attached form an important point in the regeneration of such fractures, as so many of them still preserve their viability and have a distinct osteo-genetic effect, and will therefore act as bone grafts and aid in the



FIG. 236. COMMINUTED FRACTURE OF SHAFT OF HUMERUS CAUSED BY RIFLE BULLET. Fragments are fairly large, and there is considerable separation of the outer fragments.

formation of new bone. This point has been illustrated time and again at this hospital, and we make it a rule here never to remove any such fragments until such time as it has been definitely proved that they are no longer viable or until spontaneous sequestration takes place. If we remove these fragments we retard the process of repair,

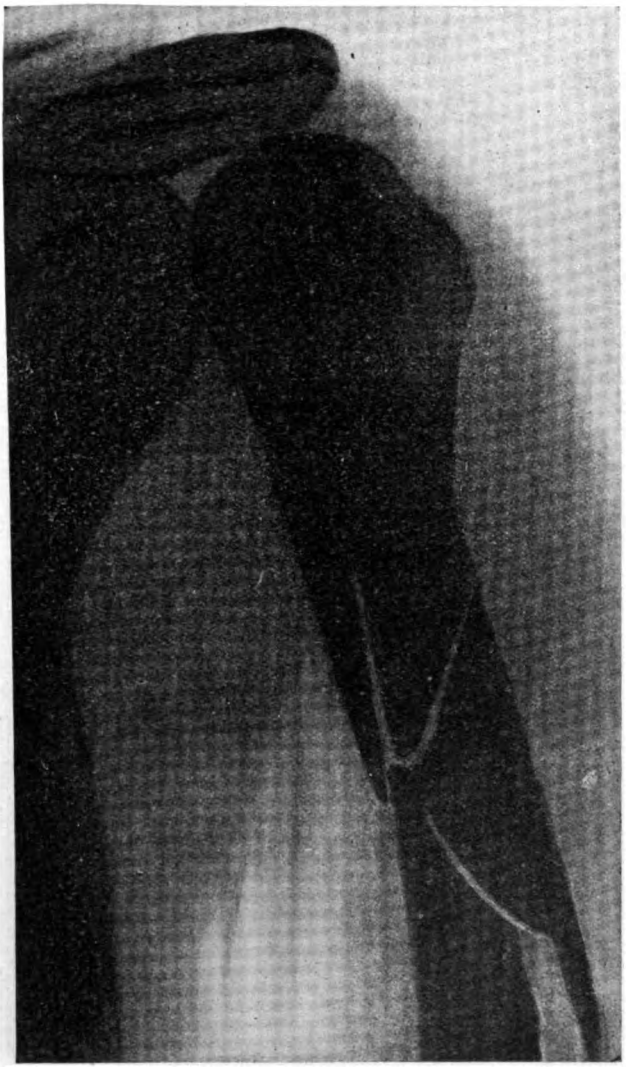

FIG. 237. SHELL FRACTURE OF SHAFT OF HUMERUS. Fragments are large and show little displacement.

and furthermore we may get as a result of such removal a condition of non-union or only partial union. It is far better to err on the side of leaving these fragments in place with the knowledge that they may have to be removed later than it is to remove them at the outset and then to feel that if they had been left in place they might possibly have been an important factor in the reunion of the bone.

FIG. 238. SHOWS SEVERE COMMINUTION OF SHAFT OF HUMERUS CAUSED BY SHELL FRAGMENT. Fragments are broken up, causing practically a solution of continuity of large area of shaft. The dark spot seen in the midst of the fragments is Bismuth-iodoform-paraffin paste with which the wound had been treated.

A

FIG. 239. *A* SHOWS FRACTURE OF SHAFT OF HUMERUS CAUSED BY SHELL FRAGMENT. There was a complete fracture about 2 inches above condyles associated with detachment of large fragments.



B

FIG. 239. *B* SHOWS POSITION OF FRACTURE TREATED BY THOMAS ARM EXTENSION SPLINT AND SHOWS FORWARD DISPLACEMENT OF UPPER END OF LOWER FRAGMENT.

The dressing of such wounds is important, as we must endeavour to remove as quickly as possible all infected foci and to establish clean and healthy granulations. In such cases we are now obtaining the best results with Dakin's solution, after having carefully prepared the wound according to the Carrel technique, and wounds so treated heal rapidly and can soon be closed.

One of the most important items in the treatment of such wounds, however, is the proper immobilization of the injured bone, and this is important, not only in order to obtain correct position and alignment of the fragments, but also to prevent the fragments from moving, for if any abnormal mobility is allowed to persist, it will constantly constitute an added source of trauma and will preclude the possibilities of the infection subsiding as rapidly as it should.

For the permanent fixation of fractures at the base hospitals various types of apparatus may be used, and the type of apparatus utilized de-



C

FIG. 239. *C* SHOWS SAME FRACTURE AFTER THE APPLICATION OF THE OSGOOD-PENHALLOW SPLINT. This shows in a striking manner the alignment which is obtained by treatment with this form of splint.

pends upon the nature of the injury and the position of the external wounds (Figs. 226 and 227). An apparatus to be efficient in open suppurating fractures should not only immobilize and hold in perfect alignment the fracture, but should also allow of easy access to the wound for constant and repeated dressings, and should at the same time be so arranged that it will be comfortable and will not become soiled by the discharge from the wound. The various types of apparatus and their methods of application will be discussed more in detail under their specific regions.

Radical Treatment. This form of treatment consists essentially of amputation or of more extensive operative measures for the fixation of the bone fragments or where there is no union, and should be resorted to only when it has been definitely proved that conservative measures are

of no avail or that the patient's life is threatened by a severe and spreading infection which can be controlled in no other way, or when there is extensive necrosis or osteomyelitis of the bone with no evidence of any regeneration.

Having discussed the various forms of fractures, we shall now consider the various bones involved and the treatment and the various forms of apparatus to be applied in each case.

Wounds of the Humerus. Gunshot wounds of the diaphysis of the humerus consist of contact fractures by rifle bullets travelling at a low

D

FIG. 239. *D* SHOWS METHOD OF APPLICATION OF SPLINT AND OF THE STRAPPING TO HOLD SPLINT IN PROPER POSITION. In this case there was a wound just above elbow on posterior surface where projectile passed through and severed the triceps tendon. No injuries to nerves or blood-vessels.

velocity, by shrapnel bullets and by shell (Fig. 228) and grenade fragments, of contusions, grooves (Figs. 229, 230), perforations (Fig. 231) and fissures (Fig. 232) by rifle bullets, shrapnel bullets, shell and grenade fragments, of comminutions (Figs. 233, 234, 235, 236) caused by rifle bullets travelling at a high velocity and by shell (Figs. 237, 238, 239) and grenade fragments. They may also consist of indirect fractures which may be associated with any of the above-mentioned types of wounds.

Complications. Associated with fractures of the shaft of the humerus we sometimes find injuries to the blood-vessels which lie in close relation to the diaphysis, or injuries to the brachial plexus or to the musculo-spiral nerve. Injuries to blood-vessels may give rise to an aneurism or to a total severance or occlusion of the artery, and, as a consequence of the latter condition, we may get a partial or total loss of circulation, with a resulting gangrene. Injuries, however, to the brachial artery

FIG. 240. SHOWS MODIFIED THOMAS SPLINT FOR FRACTURES OF THE HUMERUS.

are not so serious as regards the ultimate loss of the limb as are injuries to other arteries, as the collateral circulation readily re-establishes itself owing to the large number of anastomosing branches which are given off along the course of the artery especially in its upper part and about the elbow, and these branches readily accommodate themselves to the re-establishment of the circulation. Injuries to the brachial or musculo-spiral nerves occasionally occur and should be treated as will be described in a chapter on these special structures.

Infection is the principal complication with which we are concerned, as every gunshot wound of any size is infected, and we must always bear

in mind the fact that such wounds may be contaminated not only by the pyogenic organisms, but also by the *B. tetani* and *B. perfringens,* and, furthermore, we must remember that the presence of infection where there is much comminution of the bone may give rise to a severe and

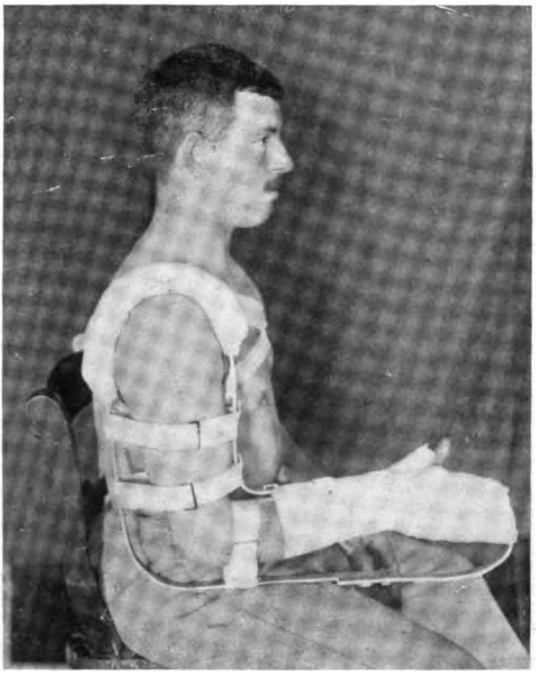

FIG. 241. SHOWS PAGE ALUMINIUM SPLINT APPLIED FOR FRACTURES OF THE HUMERUS.

persistent necrosis which retards the regenerative powers of the periosteum in these bone fragments. Again, if such infection and necrosis be allowed to persist, non-union of the fragments may result.

Diagnosis. As little manipulation as possible of the arm should be done, as it can only establish the fact that abnormal mobility is present, and further confirmation of the type of injury should be made by means of the X-ray after the arm has been immobilized. The appearance of the apertures of entrance and exit, as well as the direction of the track of the wound, gives one a considerable idea of the severity of the osseous lesion, and it is better to make the diagnosis by means of the X-ray and by inspection rather than to cause a large amount of trauma by undue manipulation.

Treatment—(*a*) *Conservative.* After the diagnosis of the fracture has been confirmed and the position and condition of the fragments determined by means of the X-ray, the type of apparatus to be used for immobilization can be determined. In those cases in which the wounds in the external tissues are small, and if no infection be present and there be little or no fragmentation of the bone, a simple fixation apparatus will be sufficient. In such instances we may use an Osgood-

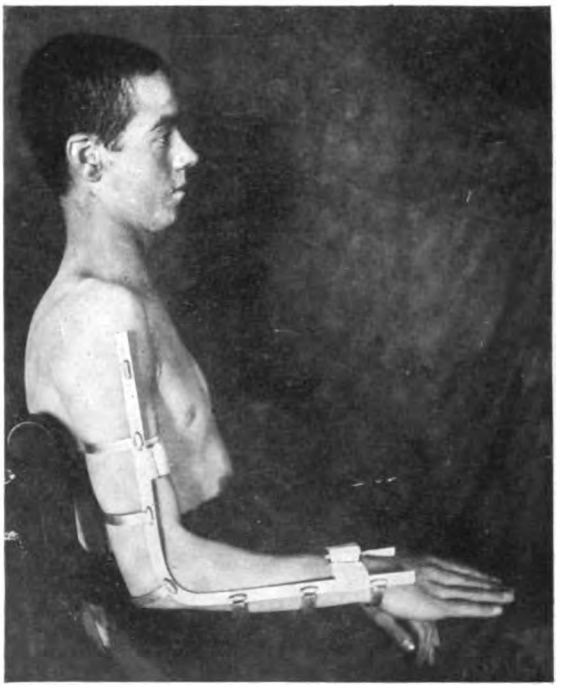

FIG. 242. SHOWS RIGHT-ANGLE SPLINT FOR FRACTURES OF THE ELBOW OR FOREARM. Splint constructed of aluminium.

Penhallow humerus splint (Fig. 239 *C* and *D*), which will correct any deformity from over-riding which may be present and which will also allow of the fragments being easily aligned. Furthermore, if only a small external wound be present, especially in the antero-posterior direction, this splint will allow of easy access for the dressing of the wound. Other types of apparatus consist of a modified Thomas splint (Fig. 240) or of a Page arm splint (Fig. 241), and either of these will allow of a certain degree of traction to correct the over-riding and will also give easy access to the dressing of the wounds (Fig. 242).

(*b*) *Radical Treatment.* In those cases where there is a large extensive external wound associated with much comminution of the diaphysis and further complicated by the presence of extensive suppuration, operative measures should be immediately instituted and all necrotic and devitalized tissues removed, the wound thoroughly cleaned mechanically, and all bone fragments which are devitalized or which show no periosteal attachments should be removed. Such a wound will of necessity be immobilized in some apparatus which will allow of constant traction to preserve the alignment and to prevent shortening, and which at the same

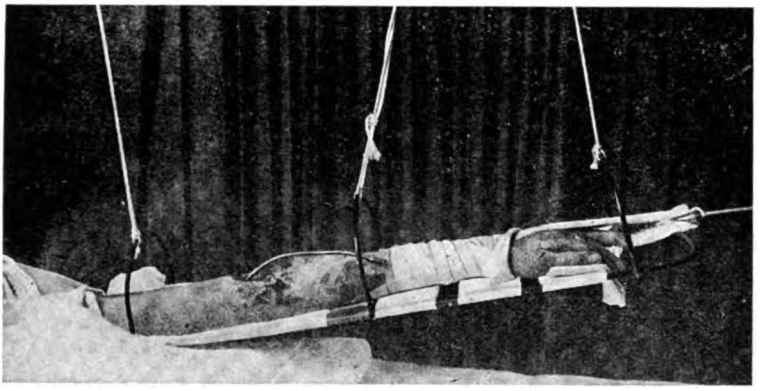

FIG. 243. COMPOUND FRACTURE OF HUMERUS TREATED BY EXTENSION AND SUSPENSION ON MODIFIED HODGEN'S SPLINT; WOUNDS BEING TREATED BY CARREL-DAKIN METHOD. Carrel tube is shown in photograph inserted into wound. This modification was suggested by Dr. Frost.

time will allow of ready access to the wounds either for constant irrigation or repeated changes of the dressing (Figs. 243 and 244). Probably the best form of apparatus to use in this type of case is the Arm Extension apparatus, as shown in Fig. 245. This apparatus is fastened to the bed and is so arranged that it will allow of any degree of adduction or abduction of the arm, and the arm can thus be placed in the most advantageous position for the maintaining of the alignment. Furthermore, the arm support may be raised to such an angle as to aid the return flow of the venous blood and thus overcome any tendency to œdema of the distal portions of the limb. Extension straps should be placed along the forearm and held in place either by means of adhesive plaster or by means of an adhesive varnish. Various formulæ have been advocated for holding extension straps to the skin. The best-known one is Heusner's Glue, which is made as follows:

	Grammes.
Resin	50
Alcohol	50
Benzine, pure	25
Venice turpentine	5

Powder the resin, then add half the alcohol, then the Venice turpentine and benzine, and wash out the measure with the remaining alcohol. Remove with benzine.

Another glue is that devised by Major Sinclair, R.A.M.C. Two forms of this are in use:

I

Ordinary glue	50 parts
Water	50 "
Glycerine	2 "
Calcium chloride	2 "
Thymol	1 part

II

Isinglass	50 parts
Glue	50 "
Water	50 "
Calcium chloride	2 "
Tannic acid	12 "
Thymol	1 part
Glycerine	2 parts

This is a rather more elastic adhesive than No. 1. The glycerine and calcium chloride allow perspiration to take place and so prevent skin troubles, as well as taking up the perspiration and keeping the glue from getting brittle. The thymol prevents putrefaction and diminishes smell. A pound of the preparation can be placed in airtight tins, sterilized at 100°, and placed in store; when required, the contents are melted in a water bath and then set aside to cool. The skin should first be washed with soap and sodium carbonate solution (four drachms to the pint) but not shaved, and then when dry the adhesive applied with the palm of the hand or a brush, covering the area evenly. This is covered with four-ply gauze, which has previously been roughly measured, and which adapts itself to the conformity of the limb and is kept in apposition with the skin by a loose woven bandage. The extension can be made almost immediately.

At the end of the extension straps is fastened a spreader, and the

extension on the arm is obtained by means of sufficient weights to maintain the arm in good position and alignment without causing any undue amount of pull. With this apparatus the position can be maintained and dressings done without disturbing the position of the arm. Apparatus which is simple, which attains the desired result so far as maintaining the position and alignment is concerned, and which gives ready access to the wounds for dressings is preferable to the more complicated forms of



FIG. 244. BLAKE'S METHOD OF TREATING FRACTURES OF THE HUMERUS BY SUSPENSION AND EXTENSION. In this case the humerus is supported by a cradle held in position by weights. There is direct pull downward on the humerus; the forearm is held flexed and suspended by another weight. The photograph also shows exercise handle which enables patient to use fingers constantly.

apparatus which need constant readjustment. Later when the sepsis subsides and bony union begins to take place, some other form of apparatus, such as one of those which have been mentioned for the more simple types of fractures, may be applied. But it is most important in all these fractures, whether infection be present or absent, that the joints above and below the lesion should be immobilized and, further, that any tendency on the part of the muscles to cause deformity should be overcome. The later developments should be treated symptomatically, and as fragments of bone become necrotic or sequestrated they should be removed. Other forms of treatment for the immobilization of fractures,

where no other methods are available, will be discussed later, as will also the treatment of non-union.

The importance of conservative treatment and the leaving *in situ* of bone fragments is illustrated by the following case:

A. W., aged twenty-five, Grenadier Guards, was wounded on October 8th, 1915, during a counter-attack of the enemy at Hulluch. Patient received a bullet wound of the left upper arm. The bullet was fired from a short range. Received his first aid one hour later, and was

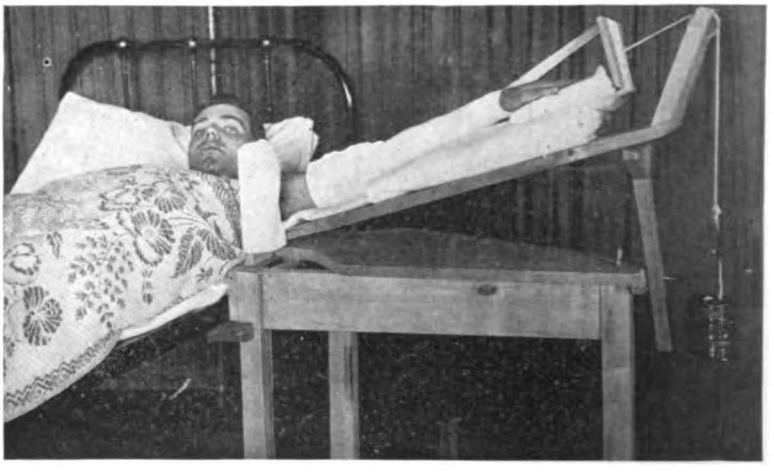

FIG. 245. SHOWS EXTENSION APPARATUS FOR FRACTURES OF THE HUMERUS, AS DESCRIBED IN TEXT. This apparatus was designed at the A.W.W.H. and is a modification of other forms which are in use elsewhere.

transferred and admitted to the American Women's War Hospital on October 16th, 1915.

Examination on entrance as follows: Patient presents a gaping wound 4 inches long and 2 inches wide on the outer posterior aspect of upper third of left arm. There is a profuse purulent discharge from this wound. There is abnormal mobility of the humerus and comminuted fragments of bone may be seen in the wound of exit. X-ray (Fig. 246 *A*) shows comminuted fracture of humerus at about junction of upper and middle thirds. Fragments vary in size from large to minute, and there is solution of continuity of the bone. Scattered throughout the soft tissues are many pieces of disintegrated bullet. On the day following admission the wound was thoroughly cleaned under ether anæsthesia and free fragments of bone were removed. Arm immobilized

by means of an Osgood-Penhallow Splint. Wound dressed with hypochlorous acid.

November 16th. Wound still discharging a considerable amount of pus. No evidence of union.

December 1st. Patient running a moderately septic temperature for the past ten days, and wound discharges a few small pieces of necrotic bone.

December 3rd. Ether; wound opened and several loose fragments of necrotic bone removed. One long spicule of bone found on posterior

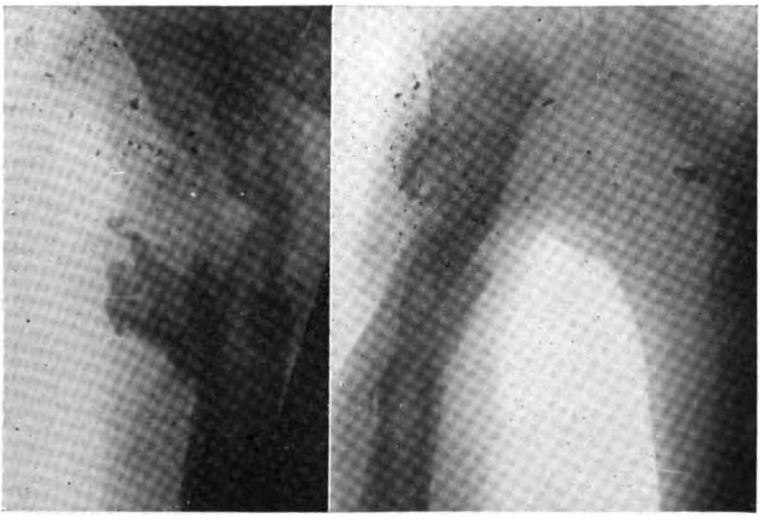

A *B*

FIG. 246. *A* SHOWS EXTENSIVE COMMINUTION OF UPPER PART OF HUMERUS CAUSED BY BULLET. Comminuted fragments vary in size from large to minute splinters of bone. Embedded in tissues may also be seen metallic fragments from disintegrated bullet, which fragmented on striking the humerus. *B* shows result 7 months after admission. There are good union and alignment, as has been described in text.

aspect of humerus, but as this still showed some attachment at its upper end it was left *in situ.*

January 1st. Since last note wound has cleared up somewhat, but some necrotic bone may still be felt.

January 3rd. Ether: wound explored and more necrotic fragments of bone removed. Wound left open and drained and dressed with constant hypochlorous acid. Patient in bed. Arm fixed on extension apparatus.

January 9th. To-day there is some redness and induration in left

axilla. Patient given gas in the ward and abscess cavity opened. Through-and-through drainage established.

February 19th. Since last operation temperature has become normal.

FIG. 247. FISSURED FRACTURE OF LOWER END OF RADIUS CAUSED BY SHRAPNEL BULLET. Fissures extend into carpal joint.

Wound clean. Abscess in axilla entirely subsided. Wound in arm still discharging a small amount of pus. General condition good.

March 19th. Patient up and about for the past week. Arm in splint. General condition good; patient has gained 13 lbs. during last

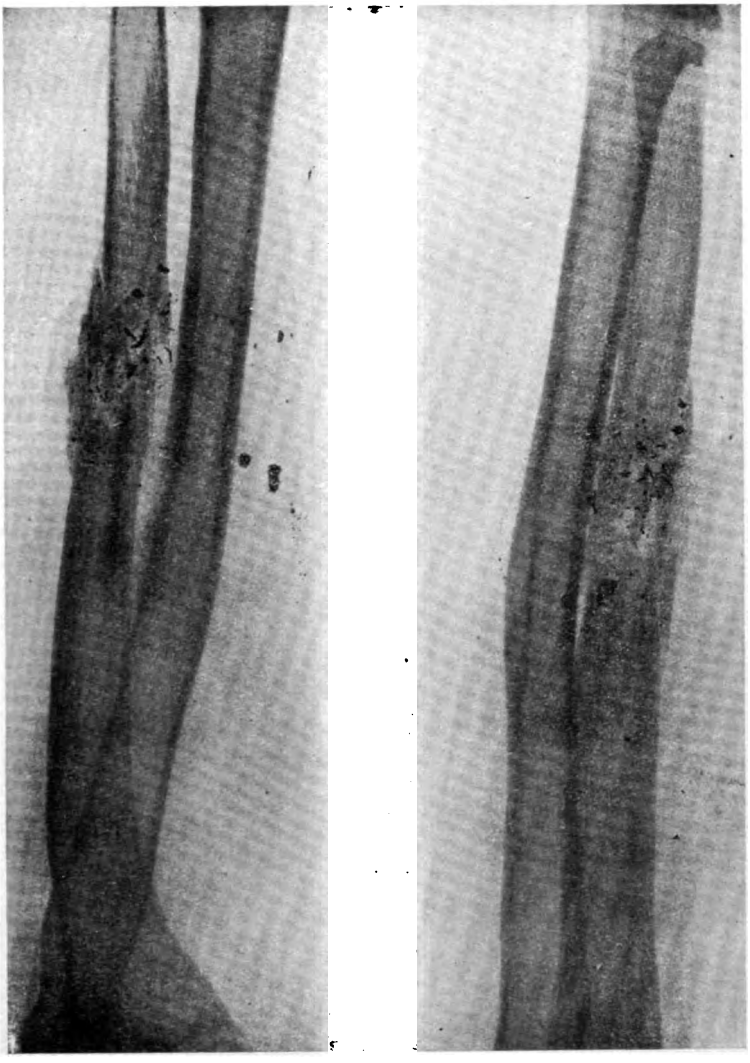

FIG. 248. FISSURED FRACTURE OF SHAFT OF ULNA CAUSED BY SHRAPNEL BULLET. A few small pieces of the disintegrated bullet may be seen embedded in the soft tissues.

month. Very little discharge from wound. X-ray shows evidence of some callus formation, but clinically there is not much union.

April 19th. Wounds closing in rapidly. Union much more firm.

May 15th. Wound practically closed save for small sinus. X-ray shows fragments in good position and alignment. Considerable callus

formation has taken place along the bridge made by the long spicule of bone which had been left *in situ* (Fig. 246 *B*). Union good, alignment of arm good, patient having massage. Still in hospital at time of writing.

FIG. 249. SHOWS PERFORATED AND FISSURED FRACTURE OF ULNA FROM DEFORMED AND DISINTEGRATED BULLET, FRAGMENTS OF WHICH ARE SEEN IN THE TISSUES.

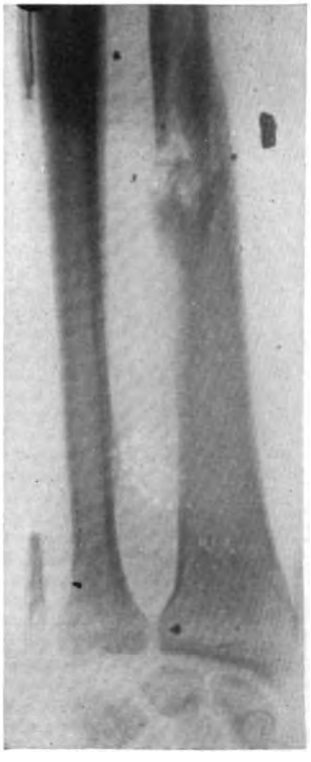

FIG. 250. SHOWS GROOVED AND FISSURED FRACTURE OF RADIUS CAUSED BY SHELL FRAGMENT.

At one time it seemed doubtful whether the arm in this case could be saved, and as though it might be better, on account of the continued infection, to amputate. Through persistence and conservatism, however, there was a good functional result.

Prognosis. In the more simple fractures where there is little or no comminution, and in the case of indirect fractures and in wounds caused

by the smaller projectiles, such as bullets, aseptic healing may result or else healing with very little infection; but in the more extensive wounds where there is much laceration of the soft parts, together with more extensive infection and comminution, the prognosis may be much more serious owing to the dangers of secondary hæmorrhage, and, furthermore, there may be associated with the infection and the destruction of the tissues severe injuries to nerve or blood-vessels which may result either in gangrene of the peripheral portion or a loss of function due to the nerve lesion.

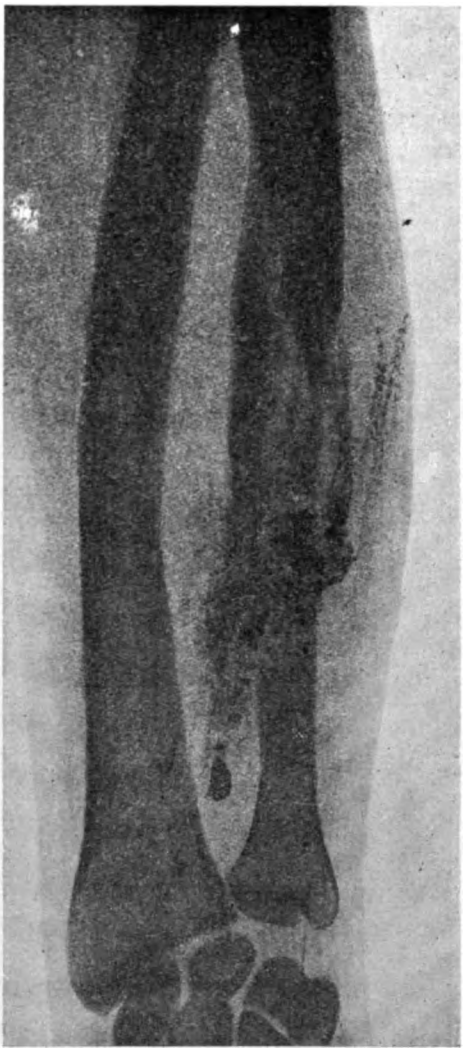

FIG. 251. COMMINUTED FRACTURE OF ULNA CAUSED BY SHRAPNEL BULLET. The comminution has given rise to fragments of various size, but there is very little separation of them. The disintegrated parts of the shrapnel bullet can be seen embedded amidst the fragments and in the soft tissues.

Wounds of the Radius and Ulna. In the forearm either the radius or the ulna alone may present typical bone lesions caused by projectiles, or both the radius and the ulna may be involved, depending upon the location of the wound and the nature of and course taken by the missile inflicting it. Injuries to either the radius or the ulna consist of fractures by contact from projectiles with a low remaining velocity, of fissures (Figs. 247 and 248), grooves, and perforations (Fig. 249). Deformed or deflected bullets give rise to more extensive injuries of one or both bones (Fig. 250), whereas bullets travelling at a high velocity, as well as shell and grenade fragments and shrapnel bullets (Figs. 251 and 252),

give rise to more extensive comminutions of one or both bones (Figs. 253 and 254). Occasionally cases are seen where there is a solution of continuity of the bony substance associated with an extensive lesion of tissue of the soft parts (Fig. 255). We may also find indirect fractures of one or other of the bones associated with a fracture at some little distance.

Complications of wounds of the bones of the forearm consist of



FIG. 252. SHOWS COMMINUTION OF RADIUS AND ULNA CAUSED BY RIFLE BULLET.

hæmorrhage, either primary or secondary, of nerve injuries. of infection, and of necrosis of the bones.

Hæmorrhage has already been considered in its different aspects.

Involvement of the nerves gives rise to typical lesions associated with such injuries, such as wrist drop or contractures of the fingers depending upon the nerve involved.

Infection is here as elsewhere one of the most important factors to be taken into consideration, for not only may we get a secondary hæmorrhage, but also an increased amount of necrosis of the bone fragments due to a persistent infection, and this, if allowed to continue, may give rise to non-union in the shaft of the bone. Furthermore, if the tendons and tendon sheaths become involved by the infective process or have been injured by the original wound, we may get as a result a partial or complete loss of function due to the sloughing of these tendons. Again, if

comminution of both bones be extensive, the motion of rotation and supination will be lost or partially lost, owing to bony union taking place between the radius and the ulna.

Diagnosis. The diagnosis of fractures of the forearm depends upon

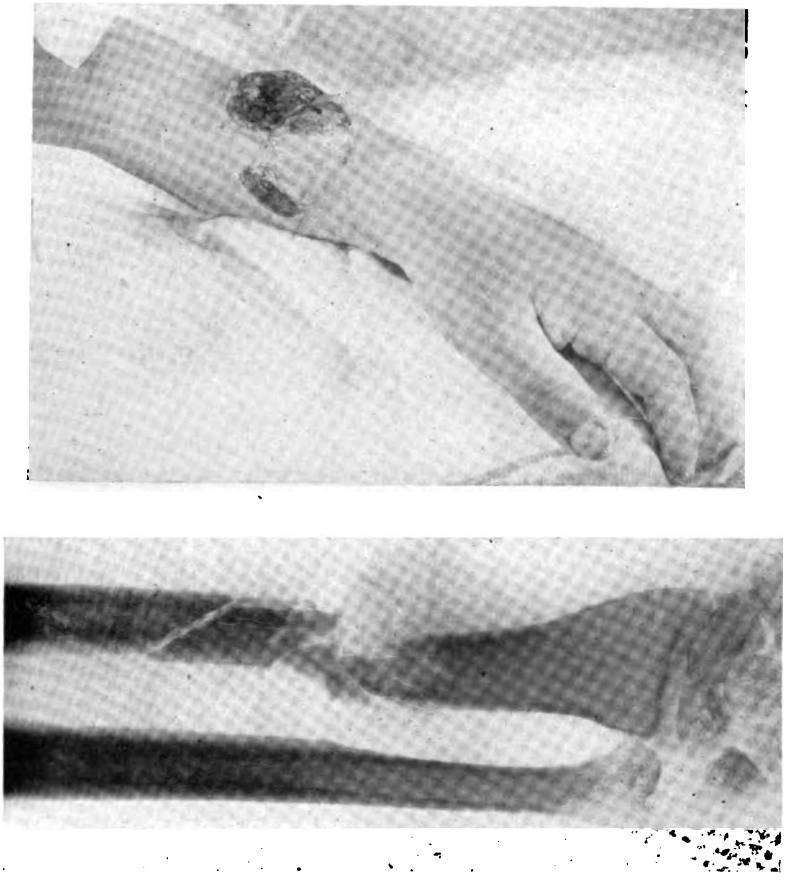

FIG. 253. SHOWS PERFORATING RIFLE BULLET WOUND OF ARM. Wound of entrance on flexor side and wound of exit shows large extensive wound on extensor surface. Bullet caused a groove in the radius with some splintering, and also an indirect oblique fracture about 1 inch from the groove. Range about 100 yards.

the size and shape of the projectile, and upon the appearance of the wounds of entrance and exit and the direction of the track made by the projectile. Abnormal mobility and crepitation, especially if there be comminution, are present, but as little manipulation as possible should be

made in order to verify the diagnosis. The appearance of the external wound will often indicate the degree of severity of the bone lesions, and the ends of the bone may be seen in this wound, or we may find small spicules of bone lying embedded and projecting from the tissues. The amount of damage, and the presence of associated foreign bodies, is best confirmed by means of the X-ray.

Prognosis. Simple wounds of one or both bones may heal aseptically and with very little deformity. Wounds where there is much comminu-



FIG. 254. SHOWS SPLINTERING OF RADIUS FROM SHELL FRAGMENT WHICH IS SEEN LYING BETWEEN THE TWO BONES.

tion, caused by large shell fragments or by bullets travelling at a high rate of velocity and causing large destruction of soft tissues, give a more grave prognosis as regards the healing and ultimate return of function. The amount of destruction to the soft parts and the involvement of the nerves and tendons also complicate the prognosis as to function.

Treatment. Treatment should follow along the same general lines which have already been laid down, and consist of control of the hæmorrhage, the drainage of the more extensive infected wounds, the removal of free bone fragments and any foreign bodies, and the immobilization of the fragments by some form of apparatus which will allow of adequate dressings being applied, and which will at the same time hold the bones in proper position and alignment. If there be any nerve involvement, the apparatus should be such as will overcome any tendency towards deformity from relaxation of the muscles supplied by that nerve. Again, if there be much loss of substance of the muscles of the forearm, the apparatus should be so constructed as to bring the injured muscles into the best apposition, so that when healing takes place there will be a minimum of scar tissue interposed between the severed ends. The apparatus to be used will depend to a great extent upon the size and the locality of the wound of exit. Such a wound is usually of a large

size, owing to the tearing effect of the secondary projectiles, such as bone fragments, which have been propelled through the tissues and have exerted a divulsive effect upon the muscles and skin, as is commonly seen in those injuries which have been caused by bullets, especially of shorter ranges. It is important that the wrist joint as well as the elbow joint

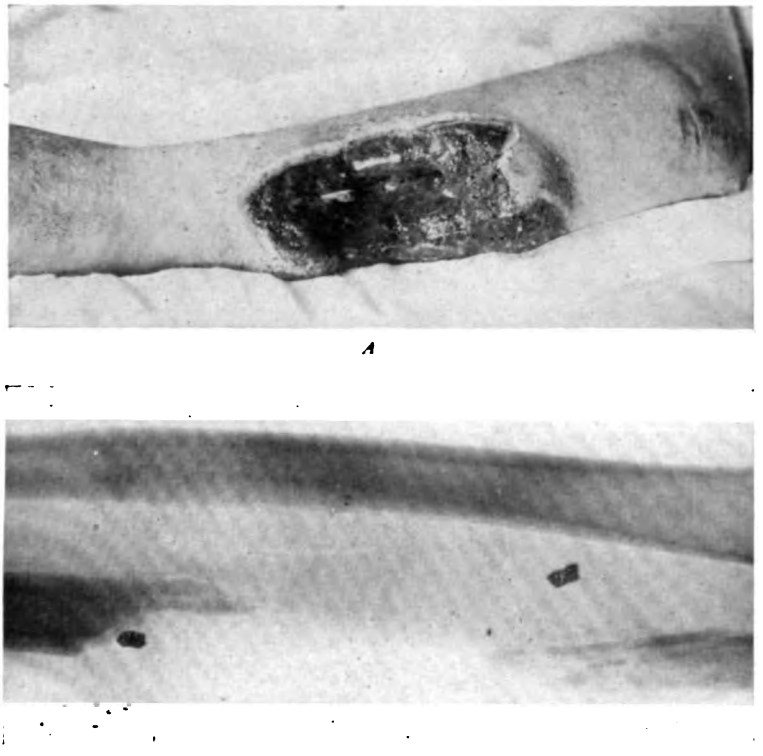

A

B

FIG. 255. *A* SHOWS GRENADE WOUND OF FOREARM WITH EXTENSIVE DESTRUCTION ON ULNA SIDE. Ends of bones may be seen lying exposed in the wound. *B* shows the extensive destruction of the shaft with some comminution and splintering of the ends. Two small grenade fragments seen lying embedded in tissues.

should be immobilized, and that not only should the bone fragments be fixed, but the apparatus should be so arranged that dressings can be carried out without having to disturb the position of the arm.

Various forms of apparatus have been devised. Splints made of tin and so constructed as to conform to the shape of the arm and to keep the hand in proper position, and overcome any tendency which might result from the severance of the muscles or from injuries to nerves, afford one

of the simplest forms of apparatus, but it is necessary that such splints should be built for each individual case, as the conditions vary in each instance. Such a splint is shown in Fig. 227, C and H. Splints made of wire and so constructed that there is a bridge at the site of the wound which will allow of easy access for dressings are also of use, and plaster of Paris forms one of the most efficient forms of apparatus, as it will allow of absolute fixation. This is best applied in the form of a bridged plaster with metallic bridges incorporated into the plaster in such a way as freely to expose the wound and yet allow of adequate fixation. With such an apparatus dressings of any nature may be easily applied. Later, when the wounds are healed, other forms of apparatus may be applied to overcome any deformity. It is important that all fragments of bone which show any attachment should be left in place, and only those which are detached should be removed.

Conservative treatment therefore should be the rule in those cases, and amputation should be performed only in those instances where there is complete destruction of the tissues and a resultant gangrene or where an infection which threatens the patient's life supervenes. In every case an attempt should be made to save as much as possible.

Wounds of Metacarpal Bones. Wounds of the metacarpal bones consist of fractures by contact from shell fragments (Fig. 256), from shrapnel bullets or from rifle bullets with a low remaining velocity. They also consist of comminutions and destruction of tissue from projectiles moving at a high rate of velocity, and these may be caused not only by rifle bullets, but by small shell fragments which still retain a high velocity. Associated with injuries to the metacarpal bones there is usually extensive laceration of the soft parts, and the tendons and fascia become torn and split not only by the impact of the projectile causing the injury, but also on account of the comminution of the metacarpals themselves.

Complications. The complications in these instances consist usually of destruction of the flexor and extensor tendons of the hand, of marked deformity due to destruction of tissue, and also of hæmorrhage from the deep or superficial palmar arch, caused either directly by the projectile inflicting the injury or by secondary projectiles from the injured bone.

Owing to the anatomical structures which are found in this region, infection is most important. The structures which play the most important part here as regards infection are the tendon sheaths of the palm, for if an infection in this region be not local, it may mean involvement and loss of the flexor tendons of the palm with a consequent loss of function of the fingers. Associated also with this infection we may

find a palmar abscess, or the infection may give rise to a secondary hæmorrhage in the deep or superficial palmar arches.

Late complications consist essentially of necrosis of the metacarpals and of contractures and loss of function of the fingers from adhesions about the tendons.

Diagnosis. The diagnosis of fractures of the metacarpals is as a rule easily made. There is deformity in the region of the wound asso-

FIG. 256. CONTACT FRACTURE OF 3RD, 4TH, AND 5TH METACARPAL BONES BY SHELL FRAGMENT, WHICH IS SEEN LYING *in situ*.

ciated with crepitation and pain. Frequently the fractured ends of the bone may be seen protruding from the wound, and again, especially in the case of shell fragments, a mass may be felt lying in the tissues and grating against the bones. The diagnosis is readily confirmed by X-ray, which shows also the amount of destruction which has been inflicted.

Prognosis. In the smaller wounds with a relatively simple fracture and very little destruction of soft tissue the prognosis is good, but in

the more extensive comminutions, where there is destruction of the soft parts and tenderness associated with infection, necrosis may result and prognosis as regards function should be guarded.

Treatment. The treatment of fractures of the metacarpals resolves itself into the treatment of the wounds of the soft parts, the overcoming of the infection, the removal of contaminated matter and foreign bodies, and the removal of loose fragments of bone, the control of hæmorrhage, and finally the application of an apparatus which will hold the fractures in proper alignment and also overcome the tendency towards deformity (Fig. 257). Adequate drainage also is necessary. Later, after the wounds have healed, and union has taken place, massage may be started and, if necessary, operation for the freeing of tendons from adhesions and the formation of new tendon sheaths by means of fascia or fat may be done.

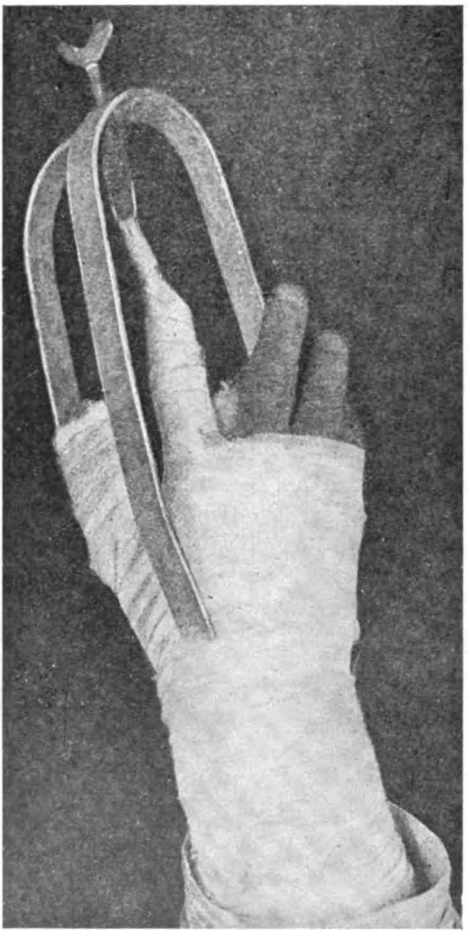

FIG. 257. AN EXTENSION SPLINT FOR THE REDUCTION AND PROPER ALIGNMENT OF FRACTURE OF THE METACARPUS.

Apparatus in these cases may consist of wire splints to hold the bones in alignment or some form of extension splint should be applied. If the wounds are small and there is little infection, or later, after the wounds have healed, and before union has taken place, the deformity may be best overcome by using a roller bandage splint and flexing the fingers over this. But no hard-and-fast rule can be laid down concerning any apparatus, as existing conditions must govern the best types to be used.

Wounds of the Phalanges. Wounds of the phalanges consist of

fissures, of grooves (Fig. 258) or perforations (Fig. 259) with comminution, and of extensive comminutions with many small detached bone fragments (Fig. 260). Such injuries are usually caused by bullets, and more extensive injuries caused by shell or grenade fragments consist in most cases of a total loss of the phalanx as well as of the surrounding soft parts.

Complications. The principal complication which we have to consider in these regions is infection and necrosis associated with loss of function of the finger.

Diagnosis. The diagnosis is easily made by inspection and by means of the X-ray, and the severity of the injury determines to a great extent the treatment to be followed.

Prognosis. In the small uncomplicated wounds the prognosis is good. With the more extensive wounds associated with infection and necrosis and involving destruction of tendons, prognosis as to function is poor.

Treatment. Grooves of the phalanges and perforations with slight comminution and little separation of the fragments are best treated by conservatism, especially if the wound be situated towards the centre of the diaphyses. The fracture should be immobilized on a splint which will allow of easy access to the wound for dressings, the loose detached fragments of bone should be removed, and adequate drainage established if infection be present. Some of these wounds may heal aseptically, and in such the prognosis is better as regards function, unless there be associated with the injury a destruction either of the flexor or of the extensor tendon.

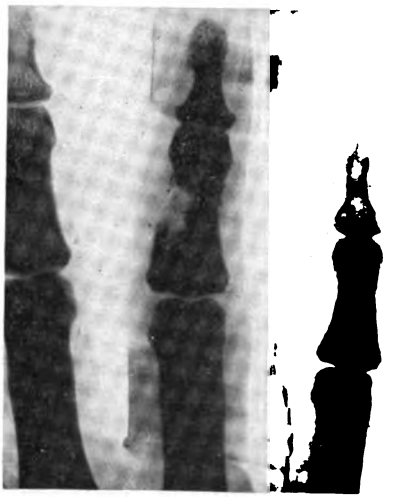

FIG. 258. SHOWS GROOVING FRACTURE OF PHALANX WITH RADIATING FISSURES, CAUSED BY BULLET.

In the more extensive wounds, associated with a considerable degree of comminution with infection and necrosis, and with destruction of the tendons, amputation gives the best result. In the more simple cases later operations may be done for the freeing or repair of adherent or severed tendons.

Fractures of the Femur. These consist of contusions or erosions and perforations due to projectiles striking tangentially, to projectiles

FIG. 260. SHOWS COMMINUTION OF TERMINAL AND PROXIMAL PHALANGES OF THUMB WITH COMPLETE DESTRUCTION OF THE INTER-PHALANGEAL JOINT, CAUSED BY BULLET.

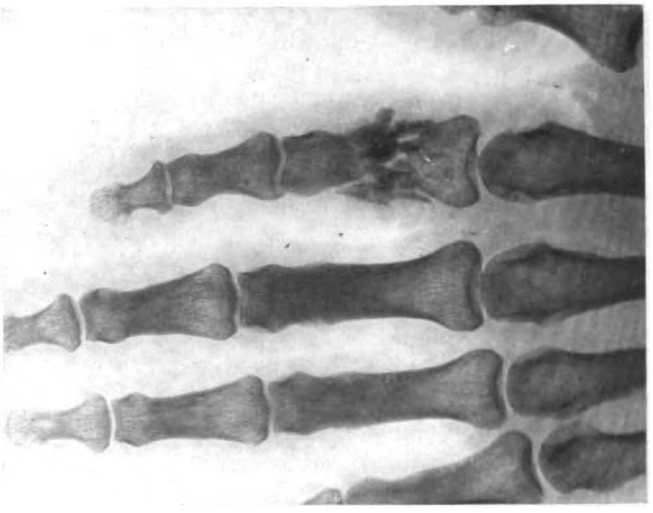

FIG. 259. SHOWS PERFORATION OF PROXIMAL PHALANX SIMULATING A BUTTERFLY FRACTURE. Wound caused by bullet.

of a low velocity striking directly, and to rifle bullets of low velocity. Rifle bullets and shell fragments of low velocity cause contact fractures and fissures, and rifle bullets travelling at a high velocity cause gutters or furrows (Fig. 261) and also extensive comminutions (Fig. 262). Shrapnel bullets and shell fragments cause fissured fractures and comminutions, as do also deformed and deflected bullets (Fig. 263). In-

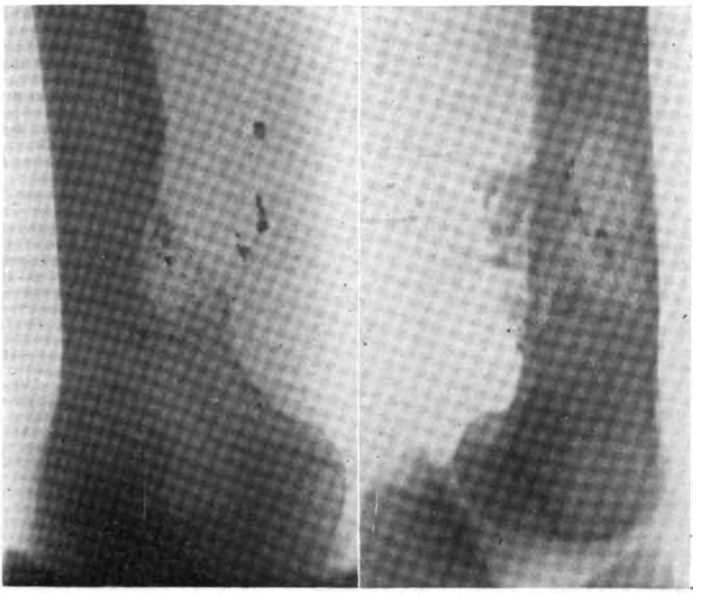

FIG. 261. SHOWS SHELL WOUND OF FEMUR. Shell fragments may be seen lying in soft parts. Fragments carried away part of the cortical bone of the shaft and caused a deep furrow.

direct fractures are also occasionally seen and are caused by trauma elsewhere, such as from a severe blow of the lower leg by a larger shell fragment (Fig. 264).

Complications. Complications here as elsewhere consist of hæmorrhage, either primary or secondary, due either to involvement of the femoral vessels, or to infection of injuries to the sciatic nerve, and of infection. Other complications consist of extensive lacerations of the muscles of the thigh and the formation of hæmatoma from injuries to these muscles or to the blood-vessels.

Diagnosis. The diagnosis is made by the direction and nature of the wounds in the soft parts, by the deformity or shortening of the thigh, by crepitation which is palpable, and by the finding of spicules

of bone in the aperture of exit. It is important here, as it is in the case of all fractures, that no undue manipulation should be made in order to determine the severity of the fracture, and X-ray should be used to confirm the nature and extent of the lesion.

FIG. 262. COMMINUTED FRACTURE OF FEMUR CAUSED BY RIFLE BULLET. Marked deformity and displacement of fragments.

Prognosis. In the more simple fractures caused by the small projectiles and where there is little or no comminution of the shaft, or where there is a perforation or gutter wound or even an oblique fracture, the evolution may be relatively aseptic, but with the larger lacerated wounds where there is marked destruction of the soft parts, associated with infection and extensive comminution of the shaft, the condition may become very serious, either owing to the rapid spread of the infection through the fascial planes, or to erosion of the blood-vessels or the formation of a large infected hæmatoma. Furthermore, the amount of resultant deformity or shortening is dependent upon the degree of comminution which has occurred, and upon the severity of the infection which takes place. If a severe sepsis be present or if there is evidence of infection by *B. perfringens,* the prognosis is grave, and this is especially so if there be any disturbance of the circulation. Often when there is no infection but there is a marked lesion of the blood-vessels and disturbance of the peripheral circulation, the outlook as regards the saving of the leg is not good.

Treatment. The treatment of the uncomplicated fractures of the femur consists of disinfection or excision of the wound, of the application of an occlusive dressing and of proper fixation or extension apparatus. In the larger lacerated wounds where there is much infection or much comminution of the fragments, much more extensive treatment

is required. Wounds should be thoroughly excised and drained, all contaminated matter and foreign bodies and detached fragments of bone removed, and any incident hæmorrhage controlled. The leg is then immobilized in some form of fixation and extension apparatus and every attempt made to overcome any shortening. In such cases as the latter, various forms of apparatus may be used, depending to a great extent upon the nature of the fracture and the position and condition of the external wounds. Reduction under ether and the application of a plaster spica with metal bridges over the site of the wound affords one of the best forms of apparatus. Other forms of apparatus consist of a modified Thomas Splint with extension, a Page Extension Thigh Splint (Fig. 265), a Blake Splint, and these combined with a suspension apparatus form a most efficient and comfortable method of treatment, and in some cases a simple Buck's Extension with the patient on a Bradford Frame will suffice. Numerous other splints have also been devised, but the splint and the method best suited to the individual case should be used.

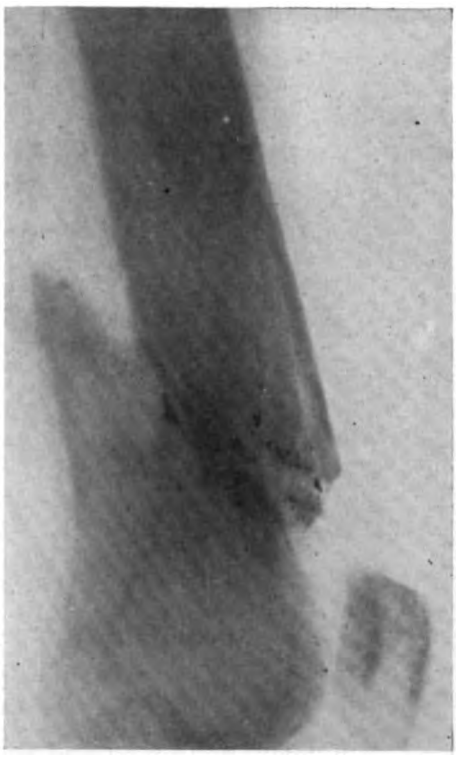

FIG. 263. OBLIQUE AND FISSURED FRACTURE FROM DEFLECTED BULLET, FRAGMENTS OF WHICH ARE SEEN STILL EMBEDDED IN BONY TISSUES.

In some instances, where the wounds in the soft parts are extensive and considerable added trauma would be caused to the patient by moving him in order to dress the wounds, a suspension apparatus (Fig. 266) gives the most satisfactory result. With such an apparatus the patient may be kept on a Bradford Frame with constant extension applied to his leg. To facilitate dressings the patient lies on a hammock which is placed over the frame, and this can be suspended to the hooks placed on the apparatus and the frame dropped, leaving the patient suspended in the air. The wound is then easily accessible for dressings, and this method can be carried out without disturbing the position of the limb

or causing any undue pain to the patient. As healing takes place in the wound, spontaneous sequestration of loose fragments will result, and these should be removed as they occur, and later, after callus formation begins to take place, a more simple form of apparatus may be applied.

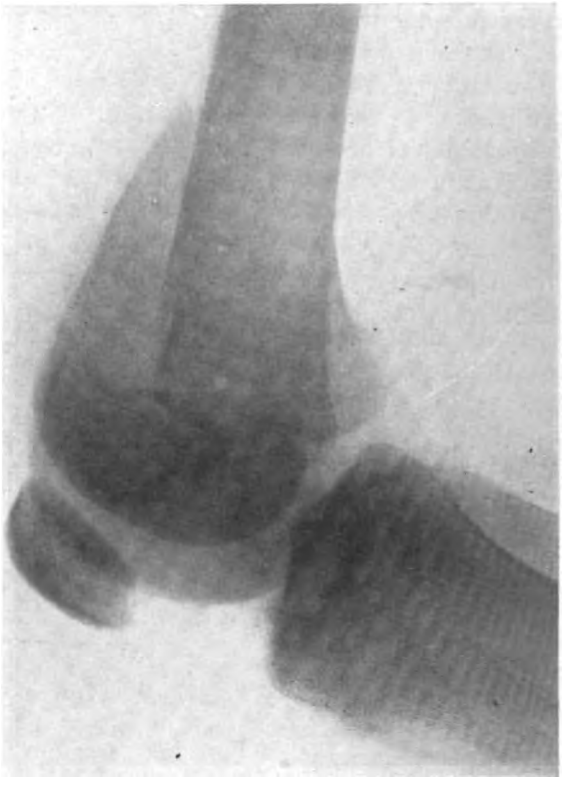

FIG. 264. SHOWS AN OBLIQUE FRACTURE OF THE LOWER END OF THE FEMUR WITH DISPLACEMENT DOWNWARD AND BACKWARD INTO THE JOINT OF THE UPPER FRAGMENT. This was an indirect fracture which occurred coincidently with a shell wound of the lower leg which carried away the soldier's foot. Amputation was later done on account of infection in the joint.

In the more extensive wounds, where there have been laceration of the soft tissues and involvement of the blood-vessels, ligation for the control of hæmorrhage should be immediately performed, hæmatoma should be evacuated, and, if a severe sepsis supervenes and secondary hæmorrhage constantly recurs and, further, if there be evidence that there is an occlusion of the circulation, amputation should be done. Amputation is also indicated even in cases of indirect fracture if the

infection extends and persists, and this is shown by the following case, in which the patient received an indirect fracture of the lower end of his femur caused by a shell wound which amputated his lower leg just above the ankle.

F. C. S., aged eighteen, London Regiment, wounded on September 26th, 1915, by a shell, while making a charge at Loos. Shell carried away his left foot and at the same time his left knee was injured by the force of the blow on his leg. A circular amputation was per-

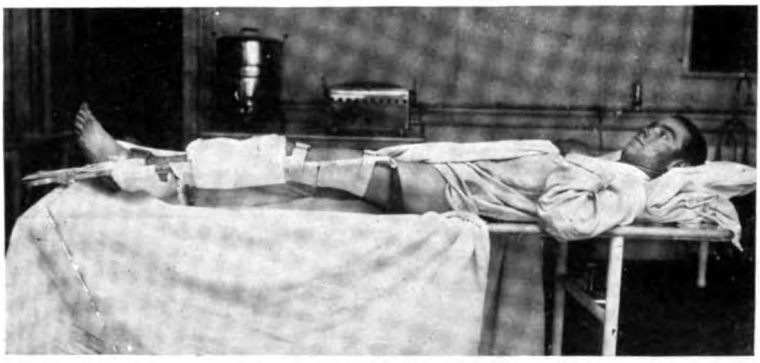

FIG. 265. SHOWS PAGE ALUMINIUM EXTENSION SPLINT FOR FRACTURES OF THE LOWER LEG AND THIGH.

formed at one of the ambulances. Patient was finally admitted to the American Women's War Hospital on October 19th.

Examination at that time was as follows: Left leg presents at a point 9 inches below the tibial tubercle a circular amputation stump. Wound clean and granulating, but skin edges have retracted and end of tibia is exposed. Skin adherent and tender. Left knee is held in a position of semi-flexion and the relation of the long axis of his lower leg to that of the femur simulates a case of genu varum. Knee swollen and painful, and deformity very apparent. Patella displaced outward. Passive motions of knee very much limited and leg cannot be extended. Active motions nearly absent. Patient rather anæmic, and not in specially good condition physically. X-ray shows oblique indirect fracture (see Fig. 264) through the condyles with marked displacement of the upper fragments downwards and backwards to a level of the condyles. Considerable bony union. The problem in this case was to reduce the fracture, and to immobilize it when reduced. This was especially difficult on account of the amputation stump, which would not allow of the

application of any efficient traction apparatus. It was therefore decided to perform an open operation to reduce the fracture and to plate it.

October 25th. Ether: Incision 6 inches long on outer end of thigh. Fracture exposed. Moderate callus formation found. Fracture exposed, reduced, and held in position by a Sherman's bone plate. Wounds closed in layers. Posterior and anterior flaps made over am-

FIG. 266. SHOWS SUSPENSION FRAME FOR FRACTURE OF THE THIGH. This frame was constructed in order to facilitate dressings, as the thigh was very badly infected and any movement caused extreme pain to the patient. A Bradford frame is supported on two crossbars and over the frame is a hammock which can be suspended to the hooks on the upper bar. When it is required to do a dressing the hammock is caught over the hooks, the Bradford frame is dropped out and the patient remains suspended. By this method the wound is freely accessible for dressing, while at the same time the patient is disturbed very little.

putation stump. Tibia and fibula shortened and wound closed with drainage.

November 1st. Amputation wound healing satisfactorily, small amount of drainage at angles where drains had been inserted.

November 16th. For past few days patient has complained of considerable pain in femur over site of wound. Since operation has been running an irregularly elevated temperature. Examination of leg shows some swelling about wound, which has healed by primary union. Lower end of scar swollen and fluctuant.

November 17th. Gas anæsthesia: Incision through scar and 3 ounces of pus evacuated. Wound drained.

November 20th. Wound clearing up, swelling and tenderness have entirely disappeared.

December 1st. Wound entirely healed. There is still some swelling about knee joint. Motions of leg fair. Alignment excellent. Is now having massage and passive motions. X-ray shows fracture to be in excellent position.

December 28th. Up and about on crutches. Wounds healed solid. Some swelling in knee still persists, but there is no pain. Movements of knee fair.

January 15th. About a week ago a small discharging sinus developed in wound on thigh. Considerable pain in knee. There was also a slight elevation of temperature. Movements of knee are good, but there is considerable general tenderness about the knee joint, especially on the outer side, and a small amount of a thin purulent discharge may be expressed from this sinus.

January 30th. Ten days ago temperature became much more elevated. Scar became swollen and fluctuant. Again incised under gas anæsthesia and a large pus pocket was found and evacuated. Since that time knee has been swollen and tender and motions very much limited. X-ray shows marked proliferations of callus. Amputation deemed advisable on account of patient's general condition, as he was showing signs of toxic absorption.

January 31st. Ether: Long anterior flap made with lower border just above patella; short posterior flap. Muscles and deep tissues found to be œdematous and porky, and when femur was exposed a distinct osteomyelitis was found. Soft tissues retracted until normal bone was exposed, which was at a point 4 inches above the condyles, at which point amputation was done. Bleeding points ligated and sciatic nerve cut short. Muscles sutured with interrupted catgut and cigarette drains inserted to end of femur and to either angle of wound. Skin closed with interrupted sutures. Good ether recovery.

February 10th. Wound healing by primary union except at site of drains, where there is a slight serous discharge.

March 5th. Wound healed solid. No pain or tenderness. Since amputation patient has gained steadily in weight and now looks much improved. Up and about on crutches and ready for discharge.

March 27th. Discharged for invaliding. Examination of femur after amputation showed a marked condition of osteomyelitis with proliferation into the knee joint. There was also a fissured fracture extending down between the two condyles into the joint and the articular surfaces were eroded, and whether or not the infection of the wound in the thigh was the result of infection from the lymphatics at the time of operation could not be absolutely determined, but seemed probable

in view of the fact that every possible precaution had been taken to perform an aseptic operation in this region.

The following case illustrates the need for radical treatment where no union takes place after a prolonged convalescence, and where there is an extensive necrosis with no attempt at regeneration.

T. H., aged twenty-seven, South Staffs Regiment, was wounded on May 16th, 1915, at Festubert, by a shell fragment which struck him on left thigh just above knee. Was transferred to hospital at Rouen and operated upon there on May 19th; the shell fragment was removed and drainage instituted.

June 6th. At Rouen was operated upon again and wound incised and drained.

Admitted to the American Women's War Hospital on July 30th, 1915. Examination at that time was as follows: Left thigh just above knee shows much thickening; 3 inches above patella is a practically healed granulating wound 2 inches by 2½ inches; at the same level on outer side is a wound 1½ inches long which is draining thick pus and in which is a rubber-tube drainage. On inner side, at the same level, is a healed granulating wound; and on outer side of thigh in upper third is a healed wound 1½ inches long and 1½ inches wide; all tissues indurated and œdematous, and the scars are rather pale and elevated. Palpation of knee painful; some abnormal mobility and crepitus.

X-ray shows oblique and comminuted fracture through the condyle of femur and displacement inward and downward of fragments.

August 14th. Wound on inner side became swollen and fluctuating yesterday. Gas anæsthesia. Incision and drainage and a large amount of pus evacuated.

September 1st. Wound on outer side healed. Wound on inner surface still discharging a considerable amount of pus and also some necrotic bone fragments.

October 1st. Condition practically the same.

October 29th. Ether. Operation: Incision 6 inches long carried through outer side of thigh and fracture exposed. Necrotic bone removed and fracture reduced. Wound closed with drainage, and leg immobilized on Thomas Extension Splint. At time of operation the bone at site of fracture was found denuded of periosteum and pitted. Chances of union seemed very remote, but it was decided to see if any repair would take place.

November 6th. Wound discharging freely; patient comfortable in apparatus.

November 21st. Wound still discharging freely, but is gradually closing in.

December 21st. Condition practically the same.

January 5th. Gas. Incision on outer aspect of thigh re-opened; considerable amount of necrotic bone removed. Denuded bone could be felt and there was apparently no union between the fragments.

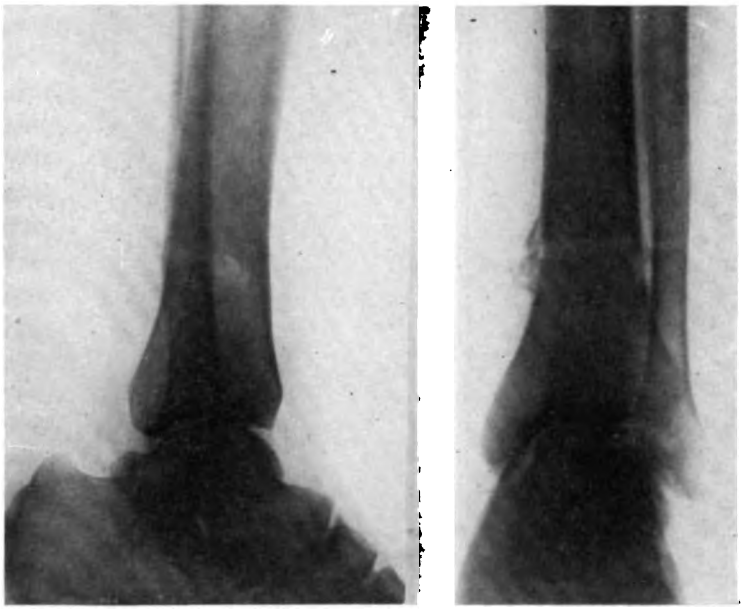

A *B*

FIG. 267. PERFORATING BULLET WOUND OF TIBIA. *A* shows small oval aperture lying just in front of fibula. *B* shows the track made by the bullet, with a few fragmentary parts of bones about aperture of exit.

January 15th. Discharge much diminished since last operation; condition satisfactory.

January 30th. X-ray shows fragments to be in good position, but there is no evidence of any union. Considerable necrotic bone could be made out by means of the X-ray. In view of the fact that after so many months there had been no attempt at regeneration of the bone, amputation was deemed the only possible solution.

February 8th. Ether. Operation: Long anterior and short posterior flaps were made. Subcutaneous tissue was found to be very œdematous and porky. As soon as the muscles were severed, the lower portion of the femur separated at the site of the fracture. Lower end of upper portion of femur found to be very much necrosed, and there was abso-

lutely no evidence of repair. Soft tissues dissected back until normal bone was found, which was at a point about 4 inches above the condyles, and the femur was resected at this point. Wound closed with drainage.

FIG. 268. PERFORATING BULLET WOUND OF TIBIA ASSOCIATED WITH FISSURED FRACTURE AND SOME SLIGHT COMMINUTION. There is very little separation of fragments.

FIG. 269. SHOWS PERFORATION OF TIBIA BY RIFLE BULLET. Considerable loss of substance around wound in tibia, as may be shown by the thinning of the shadow; and two long fissured fractures may be seen radiating from the wound through tibia.

February 28th. Much more comfortable since operation; stump draining small amount of pus.

March 5th. Wounds in angle discharging slightly; remainder of wound healing primary union.

March 20th. Discharge much less; up and about on crutches.

April 2nd. Stump slightly œdematous. Wound entirely closed ex-

cept for a small sinus from which there is a little sero-purulent discharge. Patient showed an uneventful convalescence and was finally discharged for invaliding.

Fractures of Tibia and Fibula. Often one or other of these two bones may be injured alone, depending upon the nature and the direction

FIG. 270. SHOWS PERFORATION AND SPLINTERING OF FIBULA CAUSED BY RIFLE BULLET. This fracture has a tendency towards the so-called 'butterfly' type.

FIG. 271. GROOVING FRACTURE OF LOWER END OF TIBIA CAUSED BY RIFLE BULLET.

of the projectile causing the lesion, and this may occur especially with rifle bullets, shrapnel bullets, shell and grenade fragments of varying size, as well as deformed and deflected bullets. Such injuries are usually caused by the projectile striking in an antero-posterior direction, although it may happen that lesion of a single bone may occur when the

projectile strikes laterally. Fractures of both bones may result from rifle bullets travelling at a high rate of velocity and striking laterally or tangentially, or, in the case of shell fragments, striking laterally and with considerable force. Occasionally the tibia may be fractured in



FIG. 272. COMMINUTED FRACTURE OF LOWER END OF TIBIA CAUSED BY BULLET. Considerable degree of separation of fragments.

FIG. 273. COMMINUTED FRACTURE OF BOTH TIBIA AND FIBULA CAUSED BY SHELL FRAGMENTS.

such a manner, and a fracture by indirect violence be caused at the same time in the fibula, and we may also find that the fibula may be fractured in two places at a distance from each other. The severity of the injury of these bones depends upon the nature of the projectile inflicting the wound. Rifle bullets travelling at a moderate rate cause perforations (Figs. 267, 268, 269, and 270) or grooves (Fig. 271), whereas rifle bullets travelling at a high rate of velocity may cause extensive comminutions (Fig. 272), as may also some of the larger shell

fragments travelling at a high velocity (Fig. 273). Deformed and deflected bullets (Fig. 274) striking the bone direct and at a low rate of velocity may cause fissured fractures, as may also smaller shell fragments. Rifle bullets with a low remaining velocity and small shell fragments (Fig. 275) may perforate one side of the bone and cause fissures, this being more especially true of the tibia. Contact fractures may be caused in one bone or the other by small shell fragments (Figs. 276, 277, 278), by shrapnel bullets, by rifle bullets either deformed or deflected and travelling at a low rate of velocity. Grenade fragments cause a varying degree of comminution (Fig. 279) or splintering of one or of both bones, depending upon the nature of the fragment causing the injury and the force with which it strikes the tissues.

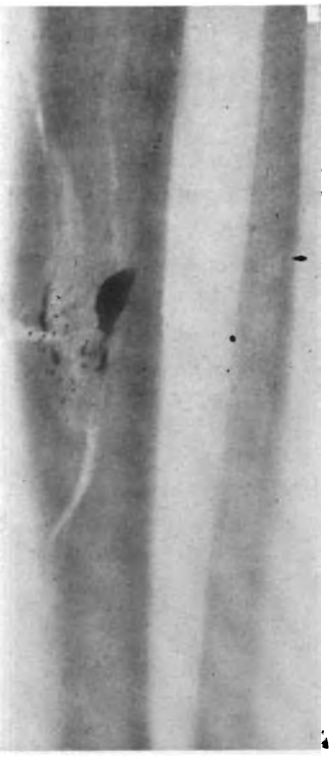

FIG. 274. SHOWS CONTACT FRACTURE WITH RADIATING FISSURES CAUSED BY THE LEAD CORE OF A DEFORMED BULLET. Bullet was found embedded in bone, and was removed.

Complications. The complications which we have to consider in this region consist of infection, depending upon the nature of the projectile causing the injury, and the size of the external wounds, hæmorrhage either primary or secondary from the anterior and posterior tibial arteries, involvement of the external peroneal nerve, if the fracture be near the head of the fibula, and also involvement of tendons near the lower end of the leg, as well as the later complication of necrosis.

Diagnosis. In the simple wounds caused by rifle bullets, where there may be merely a perforation of one or other of the bones of the leg or an erosion or contusion or simply a groove without complete fracture, the diagnosis is confirmed by means of the X-ray. In the more extensive lesions if both bones be involved, the deformity is apparent and fragmented pieces of bone may be felt subcutaneously, and crepitation is discernible on palpation. If one bone only be involved, abnormal mobility and crepitus of that bone furnishes the diagnosis, which, however, should be confirmed by the X-ray.

Prognosis. The prognosis of the more simple types of injuries is good, as such wounds may heal aseptically. With the more extensive wounds, where there is any degree of comminution, the prognosis as to the ultimate outcome, especially if there be much infection, should be guardedly careful, as often delayed or non-union may result, depending upon the amount of necrosis which has taken place. If there be any

FIG. 275. SHOWS EROSION OF THE TIBIA JUST BELOW THE TUBERCLE, CAUSED BY A SMALL SHELL FRAGMENT, WHICH MAY BE SEEN LYING JUST ABOVE THE EROSION.

disturbance of the circulation of the foot, and especially if infection be present, the prognosis should be guarded.

Treatment. With the more simple types of injury, where a complete fracture does not exist, disinfection of the wound, an occlusive dressing and fixation by means of a posterior wire splint or by plaster of Paris will suffice (Fig. 280). Where fracture of one or both of the bones exists, the treatment should be as has already been described,

namely, disinfection of the wound, the establishment of adequate drainage if infection be present, the removal of foreign bodies and of detached fragments of bone and the proper fixation. If no deformity exists, a simple posterior splint, such as a Liston or McIntyre Splint (Fig. 281) or a Cabot Posterior Wire Splint (Fig. 282) or a plaster

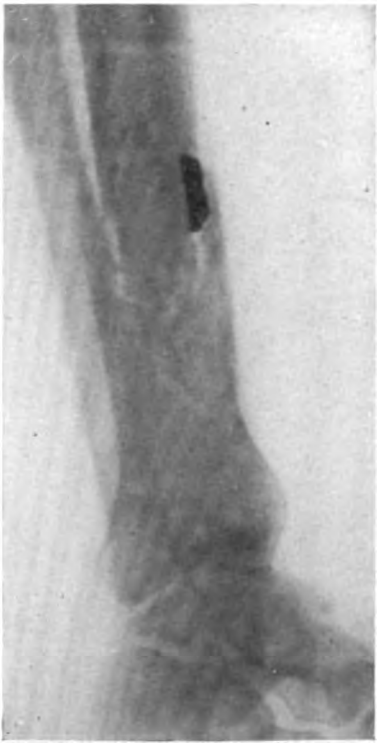

FIG. 276. SHOWS SPLINTERING OF TIBIA CAUSED BY SMALL SHELL FRAGMENT. Contact fracture.

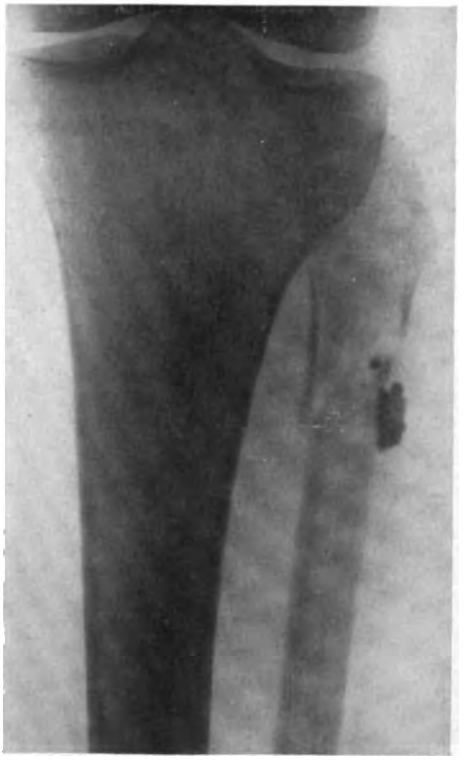

FIG. 277. CONTACT FRACTURE OF FIBULA CAUSED BY SMALL SHELL FRAGMENT, WHICH IS SEEN LYING AGAINST FIBULA.

applied so as to allow of the dressing of the wound will suffice. In the more extensive wounds involving both bones, where there is over-riding of the fragments and deformity, and when infection is present, the wound should be thoroughly cleaned and disinfected, and all loose fragments of bone and all foreign bodies should be removed and reduction effected while the patient is still under the anæsthetic. A bridged plaster may then be applied, as this is a most efficient form of fixation apparatus

and also allows of ready access to the wound for inspection and for dressings; but other forms of fixation apparatus may be used to advantage, especially in those cases where a plaster fixation splint cannot be

FIG. 278. CONTACT FRACTURE BY LARGE FRAGMENT OF SHELL, SEEN LYING IN TARSAL REGION. There is very little splintering of the tibia, and fracture is of the long oblique type.

easily applied, and this apparatus, as we have already said, depends upon the individual case (Figs. 283 and 284).

It is important in all fractures of the leg that the position of the foot be maintained at a right angle, for if this is not done a considerable degree of disability may follow when the apparatus is removed, and this is especially true of those cases in which there is any nerve involvement. In such cases the foot should be if anything over-corrected in order to prevent undue stretching of the muscles supplied by that nerve. Conservative treatment will usually suffice in such cases, and it is im-

portant here as elsewhere that all bone fragments which show any attachments whatsoever should be left in place, as they form an important adjunct in the healing of such wounds.

In cases where there has been extensive comminution and destruction of tissue, as well as involvement of the vessels, amputation may be

FIG. 279. GRENADE WOUND OF TIBIA SHOWING COMPLETE FRACTURE WITH VERY MODERATE COMMINUTION. Grenade fragments seen embedded in tissues.

necessary, especially if there be a severe infection or if gangrene supervenes.

Fractures of the Metatarsals. These are caused by bullets striking directly or tangentially, by shell and grenade fragments and by shrapnel bullets, as well as by deformed and deflected bullets. Such fractures may be caused merely by contact and may be simple in nature, or there may be extensive comminution and solution of continuity, especially

in the case of rifle bullets travelling at a high rate of velocity or from deformed or deflected bullets and shell fragments.

Complications. The complications consist of hæmorrhage, of destruction of the plantar muscles or of the tendons of the foot, together with necrosis and also a possible resulting deformity.

Diagnosis. The diagnosis is made by inspection, by palpation and by X-ray, and here also the degree of injury may be determined by the severity of the external wound.

Prognosis. The prognosis of the more simple injuries is good, but with the more extensive injuries should be guarded, as sometimes a

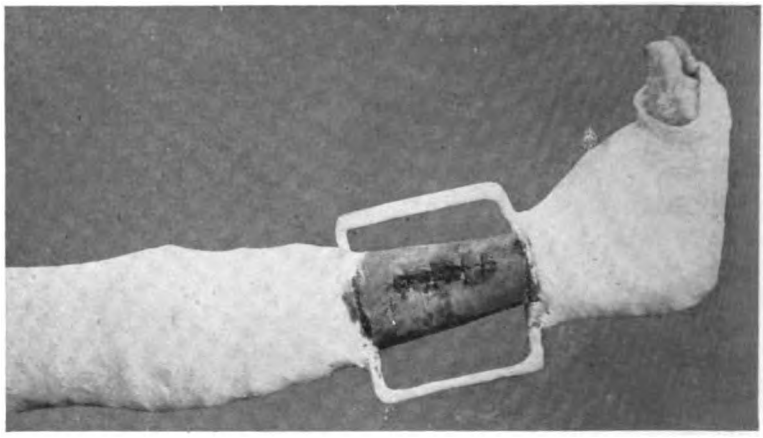

FIG. 280. SHOWS BRIDGED PLASTER APPLIED FOR AN INFECTED GUNSHOT WOUND OF THE LEG IN ORDER TO FACILITATE DRESSING AND AT THE SAME TIME TO IMMOBILIZE THE FRAGMENTS.

painful foot will result, which will detract from the man's usefulness as a soldier.

Treatment. Conservatism should be the rule in such injuries, as it may so happen that wounds which seem hopeless, so far as the saving of the foot is concerned, yield to conservative treatment, and a foot which is functionally good may result. The treatment consists, as has already been described, of adequate drainage, the removal of contaminated matter and foreign bodies and detached fragments of bone, the correction of the deformity and the immobilization of the foot by means of a plantar splint.

In those cases in which there has been so much destruction of tissue that the outlook is hopeless, or in cases which do not yield to conservative treatment or in which the result will be a foot so deformed as to

render the patient unable to walk, an amputation should be done, as a man with a good modern artificial leg will be more able to perform his duties than will a man hampered by a painful foot on which he is unable to walk.

The value of conservative treatment in such cases is well illustrated

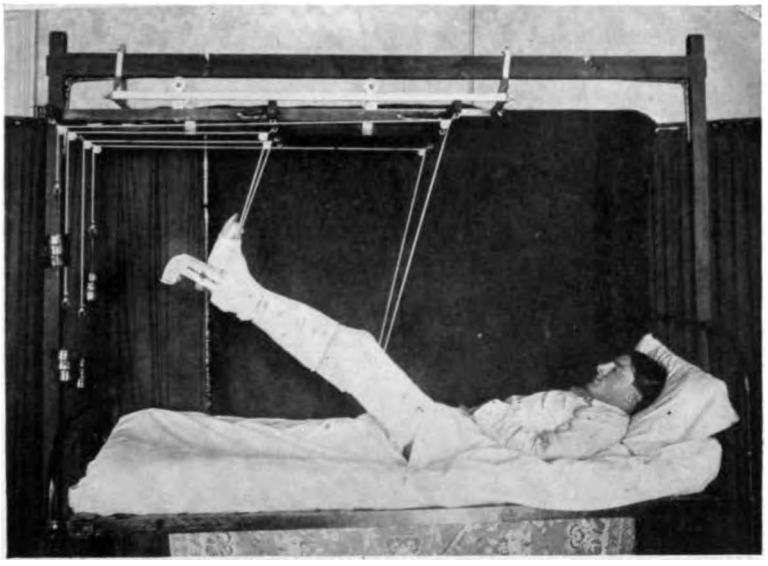

FIG. 281. SHOWS A PARKER SUSPENSION APPARATUS AND METHOD OF APPLICATION. Patient's leg is immobilized on a Liston splint and is suspended on the travelling crane and counterbalanced by the weights. Patient is able to raise and lower his leg himself, and also to sit up or to lie down in bed, all motions which he makes being counteracted by the travelling of the crane and by the rise or fall of the weights. In this position the suspension cord should be exactly perpendicular. It was held in this position to facilitate the taking of the photo and to show the different cords.

by the following case, in which the condition of the foot on entrance seemed hopeless.

W. D., aged twenty-two, North Staffs Regiment, was wounded on October 13th, 1915, at Hulluch, by a rifle bullet which perforated the soft parts of his left leg about 4 inches above his ankle and then became apparently deflected and ploughed a furrow across the dorsum of his right foot.

Was admitted to the American Women's War Hospital on October 16th, 1915, and examination at that time was as follows: Dorsum of right foot presents an extensive lacerated wound of the whole of the

upper surface extending transversely across the foot (Fig. 285 *A*). The edges of this wound are everted and blackened and are widely gaping, and from this wound the fractured ends of the metatarsal bones are seen protruding. There is a fracture of first, second, third, and fourth metatarsals with a loss of substance of the first and second metatarsals (Fig. 285 *B*), the direction of the bullet when it struck the right

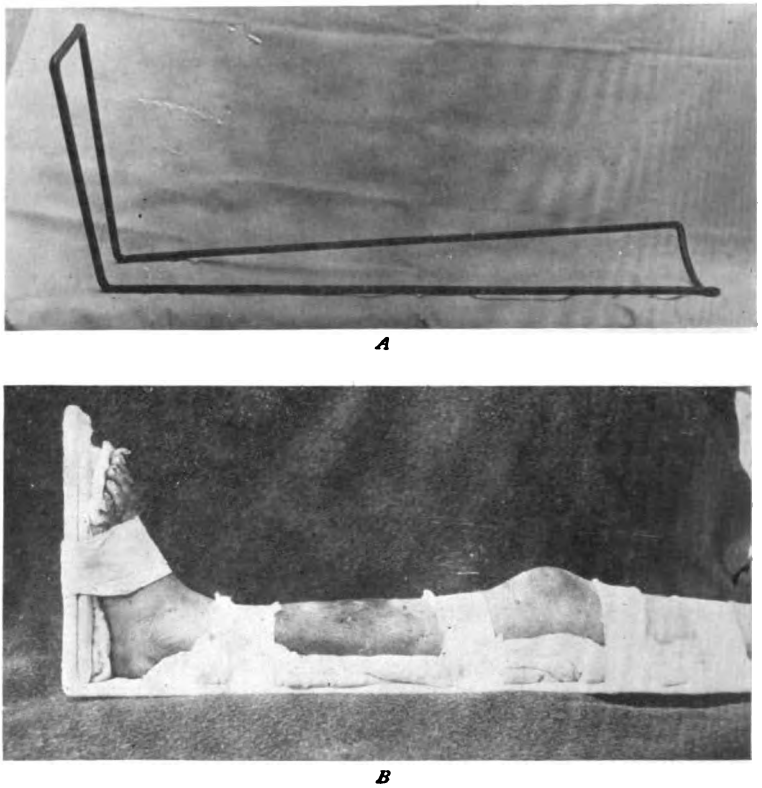

A

B

FIG. 282. *A*. CABOT POSTERIOR WIRE SPLINT. *B*. SPLINT COVERED AND APPLIED.

foot apparently being from the plantar surface outward and upward. Wound moderately infected. There is complete severance of the dorsal tendons, but the circulation of the toes is only slightly impaired. Left leg presents about 4 inches above ankle an infected perforating wound through the muscles in the posterior aspect of tibia. There is no bone involvement in the left leg.

October 20th. Ether. Operation: All necrotic and devitalized tissues excised. First three metatarsals badly comminuted, and all de-

tached and loose fragments of bone removed. Wound packed wide open for drainage.

November 20th. Wound clean and granulating except for some sloughing of tendons and fascia, which were removed.

December 20th. Wound granulating in rapidly, a small amount of a sloughing tendon over the fourth metatarsal was removed.

January 6th. Ether. Wound clean and granulating, edges freshened and wound curetted. Closed by secondary suture.



FIG. 283. AUTHOR'S IRRIGATION AND EXTENSION SPLINT FOR FRACTURES ABOUT ANKLE JOINT. This splint is used to gain extension where wounds are so situated that other methods of extension are impracticable. The leg is fixed just below knee by padded tin clip (*A*), which can be adjusted to the proper tension by the thumb-screw. The padded tin clip (*B*) is adjusted to the dorsum of the foot close to the ankle joint and the required degree of extension can then be attained by the turn-screw (*C*) which regulates the movement of the foot-piece. The splint is so arranged that it can be used to suspend the leg, and underneath is a drip-pan which carries off any irrigation fluid.

January 15th. Wound healing well except for two small sinuses over first and fourth metatarsals. Since that time sinuses have gradually closed in. Occasional small fragments of bone have been removed, and patient was discharged for invaliding on May 19th with the following note: 'Wounds entirely closed (Fig. 285 *C*). Foot of good formation but considerably shortened, especially over the first and second metatarsals. Union of third, fourth, and fifth metatarsals firm. Fibrous union of first and second metatarsals, but patient is able to walk without discomfort and for all purposes has a good functional foot.'

In addition to the general lines of treatment which have been discussed in the treatment of fractures of the diaphyses, conditions also arise which necessitate more extensive measures, not only for the reduction and immobilization of fractures, but also as a form of treat-



FIG. 284. AUTHOR'S IRRIGATION SPLINT. This consists of a modified tin ham splint with a foot-piece, and continued underneath is an irrigation pan for carrying away drainage. A large rubber tube is connected to the funnel at the end of the irrigation pan, and this tube can be carried into a bucket under the bed. In this way a great saving of bed clothing can be effected. This splint is of use when the fragments are in good position, and can be used with the Parker extension apparatus.

ment in cases where there is loss of continuity in the bone shaft, or where there is delayed, partial, or non-union of the fragments.

We will, therefore, consider such treatment under two headings:

1. The Reduction and Fixation of Open Fractures by means of a *Bone Plate.*
2. *Bone Grafting,* for Delayed or Non-Union, or for Loss of Continuity.

1. **Bone Plating.** Open fractures caused by gunshot injuries give rise to many complex problems in their treatment, and often such fractures are seen in which proper apparatus for the fixation and the alignment of the fragments cannot be applied, owing to the size and the location of the external wounds.

With such wounds there are two methods of treatment. The first method is to reduce the fracture as well as possible, to immobilize it and to hold it in as good a position as possible under the circumstances,

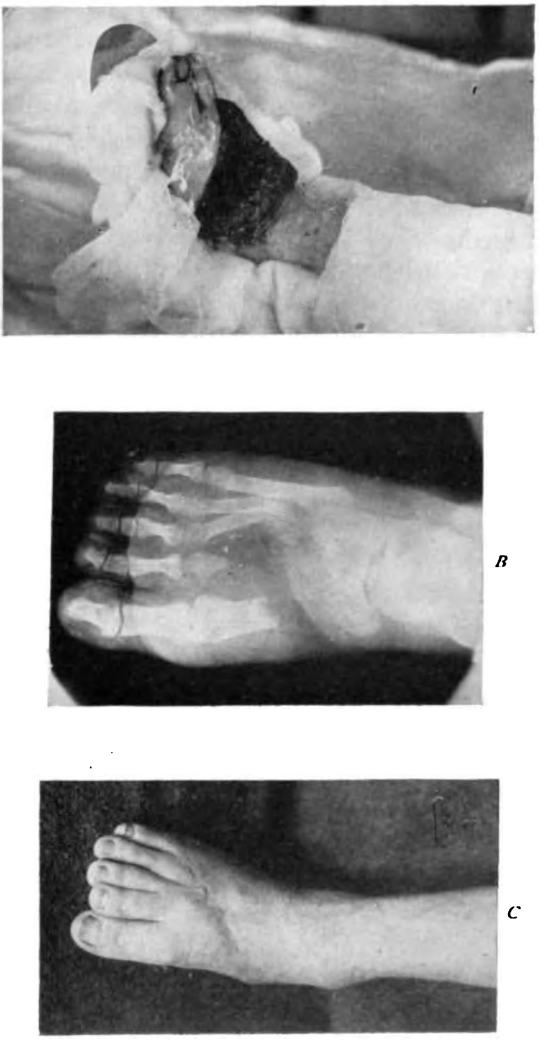

FIG. 285. A FURROW WOUND OF FOOT CAUSED BY A DEFLECTED BULLET WHICH PASSED THROUGH THE LEFT LEG, AND THEN STRUCK THE RIGHT FOOT. *A* shows appearance of wound with widely gaping furrow with everted edges. *B* shows the condition as shown by X-ray, with loss of continuity of the first and second metatarsals. *C* shows appearance on discharge seven months after being wounded. Condition described in text.

to promote efficient drainage, and to wait until the external wound has entirely closed and all infection has subsided before instituting further measures for the correction of the deformity or for the alignment of the fracture. The second method in such wounds consists of immediate reduction of the fracture, a general cleaning-up of the wound, and the holding in alignment and position by means of a bone plate, the application of an efficient fixation apparatus with the bones held in good alignment, and the promotion of free drainage and adequate treatment. With such treatment there will be no necessity for subsequent operations to overcome any existing deformity, as proper alignment is secured from the beginning.

This latter method has been more or less universally condemned, and the reasons which have been given for its condemnation are that such a procedure increases necrosis, that no union takes place in the presence of the infection, that convalescence is protracted, or that union may be unduly delayed.

Over two years ago I tried this method on some of our cases here, as it was the only way in which proper position and alignment could be obtained, and the results which I obtained were so satisfactory that it seemed to me a justifiable procedure; and since that time several cases of this type of wound have been plated with no failures and with excellent functional results, and I have not seen any reason to believe that it is not a justifiable procedure in certain cases, provided that due care is taken as regards the subsequent treatment. If the existing conditions, the limitations and dangers from the application of the bone plate are taken into consideration and guarded against, it would seem to be an ideal method of treating such fractures, especially in the hands of the more experienced operators.

We have had here in hospital the opportunity of comparing this method with methods which have been advocated, and the conclusions at which I have been able to arrive are these:

(1) Even if an infection in the wound be present, union will take place.

(2) Little more, if any, necrosis occurs than takes place in those cases which are allowed to heal in a deformed position.

(3) Early removal of the plate is indicated as soon as there is any callus formation, and this is an important point, as callus will not form at the site of the plate, but will form everywhere else.

(4) Convalescence is not protracted much longer, if at all, than in other cases.

(5) Better alignment and position are obtained from the very beginning with less resultant deformity.

(6) Adequate drainage should be established in all cases, not only of the soft parts, but of the medullary canal itself.

This treatment seems rational, when we consider the process which takes place in fractures which are treated simply by conservatism, and are later operated upon for the correction of the resultant deformity. In such a group, if complete reduction cannot be effected and the fragments brought into apposition, the fracture is immobilized, the wound healed, and the fracture allowed to unite in a deformed position. In these cases, too, there is very apt to be a necrosis of the overlapping ends of the bones, especially if they have been denuded of the periosteum, and later measures have to be instituted for the removal of these necrosed fragments and for the correction of the alignment and the holding in position of the refractured bone. Then, too, we must always take into consideration the fact that in such fractures, even if the wound is healed and there is union of the fragments, operative procedures for the refracture of the bone may start up a severe latent infection, and we shall then be in exactly the same position, as far as the healing of the wound is concerned, as we were months before when the patient was admitted with the original infected wound.

It would, therefore, seem reasonable to assume that, if such a condition of infection exists or is inevitable following operative procedures, it would be better to effect an early reduction and to allow the infection to clean up and the unavoidable small amount of necrosis to take place with the bones already in proper position and alignment. It would certainly seem preferable to allow union to take place from the beginning with the bones held in good position, than to allow the wound to heal and necrosis and union to take place in a mal-position, and then again to light up infection by operative procedures. It must be clearly realized that in these extensive gunshot fractures union and return of function are a matter of many months at the best, no matter which method of treatment is instituted.

A certain degree of judgment is, of course, necessary in the selection of the case suitable for this method of treatment by bone plating. By no means all cases of fracture should be treated in this way, many of them being readily reduced and held in proper position and alignment by means of a simple fixation apparatus. But this method of treatment would seem to be indicated in those cases where there are marked deformity and over-riding of the fragments with little comminution, and in which reduction and fixation in proper alignment and position can be effected in no other way. If the limitations of the use of the plate in such cases are recognized, together with its attendant dangers, the fragments may be held in good alignment and an efficient fixation

apparatus applied until such time as the plate may be removed. In such cases union takes place with the bones in good position rather than in poor alignment.

These facts are perhaps best illustrated by the following cases:

H. S., aged twenty-eight, Middlesex Regiment, was wounded on April 19th, 1915, at Hooge, by a high-explosive shell which wrecked the trench where he was standing. Admitted to the American Women's War Hospital on July 30th, 1915.

Examination on entrance was as follows: On middle third of lower leg there is a large infected shell wound about 2½ inches long and 1 inch wide; leg swollen and ecchymosed. Abnormal mobility and deformity of leg at this point, together with crepitation. Marked deformity of leg, and lower fragments displaced outward and upward with about 2 inches shortening. X-ray shows wedge-shaped fracture of tibia with a large detached triangular piece from the posterior portion of tibia lying transversely at level of wound. Leg very painful and tender. Fibula shows two indirect fractures—one on the level with the fracture of the tibia and one about 3 inches above. It was found impossible to reduce and hold the fragments in proper position and alignment even under an anæsthetic, and it was, therefore, decided to hold the fragments in position by means of a bone plate.

August 3rd. Ether. Operation: Wound on inner side of leg slightly enlarged to give better exposure and all granulating tissue removed. Ends of tibia exposed and found to be necrotic and denuded of periosteum. Necrotic ends were removed with a saw. A large splinter of bone which was seen by the X-ray was found to be detached and lying free in the tissues. This bone fragment was necrotic and was entirely removed and, as a consequence, there was a large V-shaped solution of continuity left in the posterior portion of the tibia. The ends of the bone were brought into apposition and held in alignment and position by a Sherman bone plate, as this was the only method by means of which fixation could be maintained. Wound left open and packed with gauze saturated with saline. Bridged plaster applied from toes to mid thigh.

September 1st. X-ray shows fragments in good position and alignment, wound cleaning up rapidly.

September 20th. X-ray shows some callus formation. Plate removed and also a small piece of necrotic bone.

October 1st. Wound clean and granulating; some slight union; leg in good position and alignment.

November 1st. Wound entirely healed save for small sinus which leads down to original wound in bone. Good union.

November 22nd. Sinus curetted out and a small amount of necrotic bone removed. Union solid.

December 15th. Patient up and about on crutches; union solid, no deformity of leg except for some thickening about site of injury. Wounds entirely healed.

January 15th. Leg solid; patient walking well; alignment and position of leg excellent; wound healed solid. There is ¼ inch shortening of left leg measured from tibial tubercle to internal malleolus, due to trimming off of necrotic ends of the tibia.

Patient discharged to duty on January 17th, 1916.

The following case also illustrates very strikingly the importance of leaving in position any fragments of bone which still show any periosteal attachments and which play an important part in the reformation of bone:

G. M., aged twenty-six, Royal Sussex Regiment, was wounded on October 13th, 1915, by a bullet which struck him on his right arm just above his elbow. Admitted to the American Women's War Hospital, October 16th, 1915.

Examination at that time was as follows: Right arm on the outer side about 4 inches above the elbow shows a small wound of entrance, and on inner side is a wound of exit 2 inches by 1 inch, the edges of which are everted. Both wounds infected. Marked abnormal mobility of humerus at this point. No disturbance of circulation and no involvement of nerves.

X-ray shows transverse fracture of shaft of humerus 3 inches above condyles, some comminution, and also one long splinter attached to the upper fragment (Fig. 286). Upper portion of lower fragment displaced forward so that when forearm is held horizontally the angle between this lower fragment and the forearm is about 45 degrees. Arm immobilized, but lower fragment could not be held in proper alignment.

November 10th. Wound healing; still some slight discharge. It was decided to reduce the fracture and hold it in proper alignment by means of a plate.

November 15th. Ether. Operation: Incision made through original wound and outer side of arm. Musculo-spiral nerve found to be lying across site of fracture, but was uninjured. This was pushed aside and fracture exposed. There was no union of the bony fragments, but a considerable number of necrotic fragments were found lying loose, as well as some necrosis of the distal and proximal ends of the humerus. Necrotic fragments removed, and a large spicule of bone, which was shown by the X-ray, was found to be attached and was left. Necrotic

ends of humerus trimmed, fracture reduced and held in position by means of plate. Wound closed with drainage.

December 1st. Wound healing rapidly; still some slight purulent discharge. X-ray shows fragments in excellent alignment and position.

January 1st. X-ray shows considerable callus formation; wound

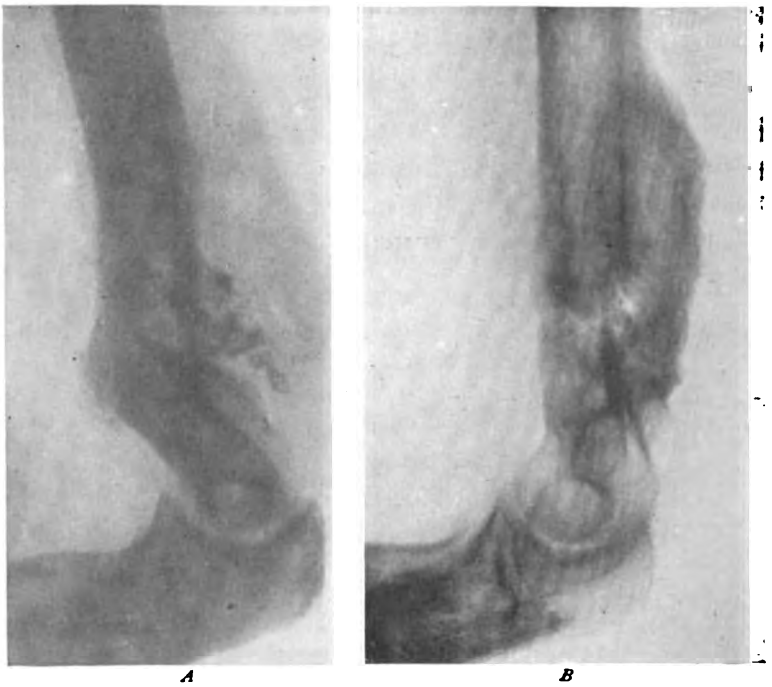

FIG. 286. BULLET WOUND OF HUMERUS. Some comminution and splintering of posterior portion. Distal fragment tilted forward so that forearm is relatively in the position of flexion. *B* shows condition six months after operation: union is solid and there is a marked formation of callus, especially on the posterior aspect, which has taken place from the long splinter which was left in place. In centre may be seen a small cavity which later was curetted out.

entirely healed save for a small sinus which leads down to the site of fracture, at bottom of which some necrotic bone may be felt.

January 10th. Ether. Plate removed; union solid. Formation of callus, especially about spicule of bone in posterior position. Small amount of necrotic bone lying between fractured ends of humerus was removed.

February 1st. Wound entirely healed; patient having massage; very little motion in elbow joint.

March 1st. Motions of elbow gradually increasing. Motions of rotation and supination improving.

June 1st. Union of fragments absolutely solid. X-ray shows large callus formation; movements of forearm gradually increasing.

H. M., aged thirty, Grenadier Guards, wounded September 25th, 1916, by shell fragment which struck him in left leg. Admitted to the American Women's War Hospital on October 18th. Examination at that time as follows: Left lower leg on outer side between tibia and fibula, middle third, shows a circular wound of entrance 1 inch in diameter. This wound is clean and granulating. On inner side of leg on same level is a gaping wound 3 inches by 2 inches filled with foul-smelling pus and numerous comminuted and necrotic fragments of bone. There is considerable shortening of leg and over-riding of fragments together with considerable loss of bony substance in anterior portion of tibia. X-ray shows much displacement together with large detached and displaced fragment in posterior portion. (Fig. 287 *A.*)

October 24th. Ether and operation. Pus pocket thoroughly cleaned; necrotic detritus removed; large posterior fragment found partially necrosed but fragment partially adherent to periosteum. Necrotic portion was removed but remainder left undisturbed. Ends of tibia necrosed; necrosed portion removed. When tibia was placed in proper position there was found to be some loss of substance between the ends of the bone; ends of bone fragments found denuded of periosteum. Tibia placed in position with small gap between the ends, and held in position by Sherman plate. The large posterior fragment was left in hopes that it might act as a splint. Wound was thus converted into a smooth-walled cavity. Rubber tubes placed to all parts of wound for irrigation purposes; light gauze pack to wound; wound left wide open; bridged plaster applied.

November 1st. Two days after operation leg became very œdematous, necessitating removal of the plaster; a special splint with drainage pan was built and applied (Fig. 287 *C*). Patient comfortable in new splint; leg in good position and alignment.

December 1st. Œdema gradually subsiding; wound clean and granulating and filling in rapidly. A few small necrotic fragments removed from ends of tibia; plate was removed on November 7th.

January 1st, 1917. Wound filling in rapidly; tibia in good position; moderate union.

January 27th. Condition satisfactory; union fairly solid; no splint for past two weeks; wounds closing in; irrigation omitted three weeks ago.

April 1st. Patient up and about on crutches; leg solid.

June 1st. Small bone sinus persists.

August 1st. Sinus still persists (Fig. 287 *B*). Has since been opened, thoroughly curetted and filled with 'Bipp'; now closing. Patient walking very satisfactorily; no shortening of leg; no deformity.

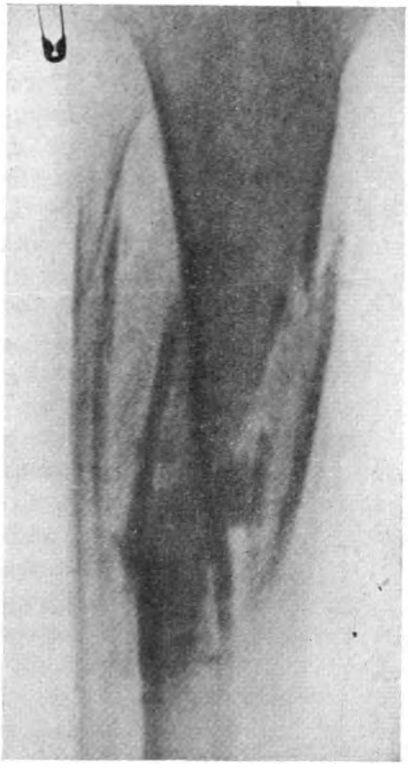

A

FIG. 287. *A*. SHELL WOUND OF TIBIA WITH MUCH COMMINUTION; LARGE POSTERIOR FRAGMENT SEEN DISPLACED. Associated with this fracture is an indirect fracture of the fibula just below the head.

B

FIG. 287. *B* SHOWS DEGREE OF UNION WHICH FINALLY RESULTED FROM THIS METHOD OF TREATMENT. A small bone cavity formed as described in text.

These cases illustrate the essential points as regards the holding of fractures in position by means of Sherman's or Lane's plates in the presence of infection.

Technique. The technique is important in all those cases in which the bone plate is inserted in the presence of infection, for if certain

general principles are not strictly adhered to, untoward results may occur and the conditions be rendered worse. In large lacerated wounds the operation may often be done without enlarging the wound, as this may already be large enough to give sufficient exposure.

After the patient has been anæsthetized, the wound should be thoroughly disinfected with iodine and alcohol or carbolic acid followed

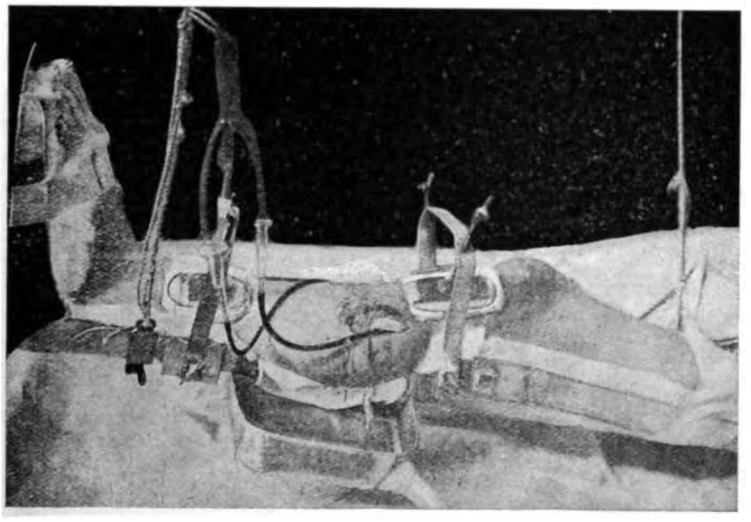

C

FIG. 287. *C* SHOWS ESPECIALLY CONSTRUCTED SPLINT TO HOLD LEG IN POSITION, AS IT WAS FOUND NECESSARY TO REMOVE THE PLASTER ON ACCOUNT OF THE MASSIVE ŒDEMA. This splint was constructed with a drip pan underneath to carry away any irrigation. Carrel tubes seen in position. Leg held immobilized by means of the padded plates on either side just above ankle and just below knee; these pads can be adjusted by means of the turn-screws in order to correct any displacements which might occur.

by alcohol, and all soft granulation tissue removed—preferably by means of curetting with gauze. The fracture should be sufficiently exposed to allow of thorough inspection and also an easy application of the plate. The condition of the bone should be carefully inspected and the amount of necrosis noted, and whether or not the bone has been denuded of periosteum.

As little trauma as possible should be done to the bone fragments. The ends of the shaft, which are usually necrotic, should be removed, just sufficient of the ends being resected to remove the necrotic tissue. Even if the bone be denuded of periosteum, no attempt should be made to remove this portion, as it will be needed for the insertion of the

screws to hold the plate and, even if it is not viable, spontaneous sequestration will later take place.

Necrotic and detached fragments of bone, which are lying loose in the tissues, should be removed; but all fragments which show any viability or any attachments of periosteum should be left alone.

After the loose fragments have been removed and the necrotic ends of the bone resected, the exposed portion of the medullary cavity should be disinfected with carbolic acid and by alcohol or iodine followed by alcohol, and any necrotic detritus removed. The ends of the bone should then be brought into apposition and held in place by an adequate plate. It is important, however, in these cases, that a close approximation of the ends of the bone should not be made, as otherwise an increased amount of necrosis and possibly an osteomyelitis will result, owing to the imperfect drainage of the medullary canal. In many instances, and especially in those cases where there is a V-shaped fracture, adequate drainage will be established by this type of fracture; but if the fracture be oblique or transverse and the fragments come closely together, it may be necessary, after the medullary cavity has been disinfected and the bones have been placed in apposition and fixed, to drill a hole into the cavity which has already been disinfected in order to establish free drainage at this point.

After the plate has been applied, the wound should again be thoroughly disinfected.

Unless the wound be very extensive, no attempt at closure should be made, and even in the larger wounds the closure should be partial and only at the ends. The fixation apparatus—preferably of bridged plaster or a specially constructed splint—is then applied; if plaster is used, the bridges should be so arranged that the wound is readily accessible for frequent dressings. Following the operation the wound should be consistently dressed with hypochlorous acid solution, or with Dakin's solution. Constant irrigation, until such time as the infection clears up, gives us the best results.

As soon as there is sufficient callus formation to immobilize the fracture, the plate should be removed, but on no account should an attempt be made to remove any more bone fragments until spontaneous sequestration has occurred.

These points are of importance, and good results may be obtained if these few general principles are followed. If due care is not given to technique, especially in regard to free drainage in the medullary canal and the early removal of the plate, and the limitations of this procedure are not fully recognized, poor results may occur.

2. **Bone Grafting.** In some cases, owing to extensive necrosis or

to loss of bone following a severe comminuted fracture non-union or only partial union may result. In such cases union may only be secured following the insertion of autogenous bone grafts. This method of treatment combines the benefits of immobilization with the osteogenetic influence of the newly implanted bone on the separated fragments.

The important considerations in these cases are that the wound should have been healed for a sufficiently long time to eliminate the possibility of a recurrence of infection in the operative wound, and that the physical condition of the patient should be such as to favor a prompt and speedy recovery. The frequency of failure of union or of recurrence of infection following operation on patients who have spent many months in hospital is too well known to need comment.

The importance of an aseptic technique, as emphasized by Lane and Albee, is well known. Operations of this character should only be attempted under suitable conditions, that is, in a well equipped operating room with an adequate number of assistants, and in a hospital where patients can be retained until recovery is complete.

After operation has been successfully performed and union has taken place, the problem of restoring function in wasted and flabby muscles, and in stiff and painful joints will still demand the attention of the conscientious surgeon for a considerable period of time.

SECTION XVII

THE TREATMENT OF WOUNDS OF THE HEAD AND FACE

THE SURGERY OF GUNSHOT WOUNDS OF THE SKULL AND BRAIN

BY

GILBERT HORRAX, M.D.

Associate in Neurological Surgery, Peter Bent Brigham Hospital, Boston; Major Medical Corps, U. S. Army

PLASTIC REPAIR OF WOUNDS OF THE FACE AND JAWS

BY

VILRAY PAPIN BLAIR, A.M., M.D., F.A.C.S.

Associate in Surgery, Washington University Medical School; Professor of Oral Surgery, Washington University, Dental Department; Visiting Surgeon, St. Luke's Hospital; Assistant Surgeon, Barnes and St. Louis Children's Hospitals, St. Louis

CHAPTER I

THE SURGERY OF GUNSHOT WOUNDS OF THE SKULL AND BRAIN

As THE present war has been a training school for the development of a more perfect treatment for wounds in other parts of the body, so in wounds of the skull and brain have operative procedures emerged from a haphazard and indiscriminating chaos to an increasingly sounder and more rational form. One has only to turn the pages of articles written on this subject in earlier times to realize with what hopelessness cerebral wounds have always been regarded. Some appreciation of recent progress may be gained when one remembers that in 1898, during the war between Spain and America, a man who lived with a metallic foreign body lodged in his brain was looked upon as a surgical curiosity, whereas during the great war it was a matter of common occurrence to have half a dozen such patients in a single hospital at the same time, all of whom were eventually discharged quite fit, and in excellent physical and mental condition up to one or two years thereafter.

At the beginning of the recent conflict, the indications for operative treatment of cranial wounds were in a very hazy state. The fragments of depressed fractures were removed in any way that seemed feasible to the operator, and sometimes a simple elevation of the loose bone was practised with no attempt to look for further trouble within the bony envelope. Soon it was found that a better policy was to trephine outside the damaged area and work toward the broken fragments, so that a field could be secured for the control of hæmorrhage (Gray,[4]). Finally, the method of removing the whole depressed fracture area, either by a bone-flap or by encircling with cutting forceps, was devised, the former by De Martel ([6]), the latter by Cushing ([2]); so that these procedures or modifications of them have become the standard methods at the present time.

Optimum time for operation. So far as can be ascertained there are two directly opposed views upon this subject. The French school, headed by De Martel and backed by the opinion of Marie, adhered to the belief that cranial wounds should be operated upon late. De Martel's statement, to which Marie subscribes, is this: "In the ordinary way, it is not urgent to operate on a skull and in my opinion those surgeons who consider that they should operate on a skull as they would

on an abdomen are mistaken. If the abdomen contained only solid organs as does the skull, instead of hollow organs full of septic material, it might be treated in the same way."

The British school and the American, the latter with Cushing as sponsor, believed firmly in early operation. In his study of a series of brain wounds at a British casualty clearing station, Cushing says: "The clinical histories of the 219 operative cases have shown clearly that a large number of the recorded fatalities were avoidable—not only by the employment of a still more perfect technique, but by its more prompt application. The bad repute of craniocerebral operations from the standpoint of infection is, without question, largely due to delay" ([3]).

From our own experience we must agree entirely with the latter school. There may be a period during the first three or four hours after the reception of the wound during which an operation could conceivably add to the original shock, but when one realizes that the greatest factor to be combated in cerebral wounds is infection, it does not seem to us that the slight improvement in general condition, which is sometimes obtained by waiting, can at all out-balance an early operation, when one can attack a wound which, although dirty, is at least only potentially infected. In comparing a series of 200 cases seen in a forward area, with a series of like number at the base, the writer has become convinced that many of the patients who reached the base could certainly have been saved by an earlier operation, because it was the advanced stage of infection alone which caused their death.

In discussing the advantage of delayed operation, De Martel points out that in operating shortly after the receipt of injury the surgeon disseminates infection by "forcing into the subdural space the septic products contained in the damaged area limited by the adhesions." This result he ascribes mainly to the use of clumsy instruments. Therefore, with the elimination of such instruments, and careful handling of the dural edge so as not to break down the adhesions, it would seem that the disadvantages of an early surgical interference were overcome. Having gotten rid of the difficulties, the early treatment of a potentially infected wound is obvious.

Preliminary preparation. This consists essentially in three steps, each of which is of great importance.

First, X-ray plates of the entire skull should be made, preferably stereoscopic plates, if an apparatus for examining them be at hand. With a little practice a very accurate idea of the fracture can be obtained, as well as the position of the indriven fragments, both bone and metal (Fig. 288). If a stereoscope cannot be had, anteroposterior and lateral plates should be made, although these are often very deceptive. In the

average case the more refined methods for exact localization of intracranial fragments seem superfluous, at least in so far as concerns cases which are receiving their primary operation after injury. All that the operator wishes to know is whether there be indriven bone fragments or pieces of metal; their number; their relative relation to and approximate distance from the wound of entrance. The removal of such fragments should always, or practically always, be accom-

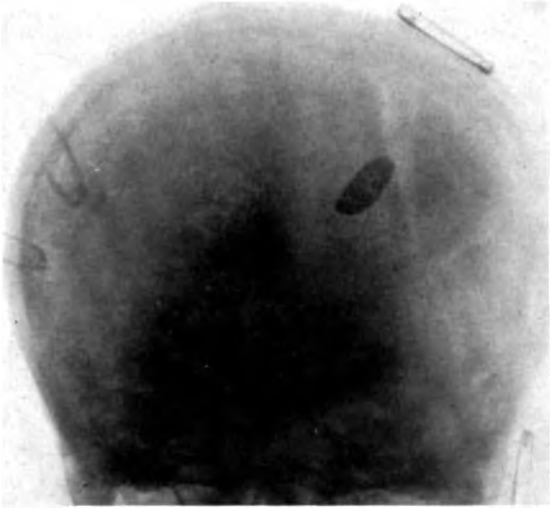

FIG. 288. RADIOGRAM OF SKULL SHOWING RETAINED METALLIC FOREIGN BODY.

plished through the track they themselves have made through the brain, and not by counter approaches through previously uninjured areas.

In the second place, every patient with a wound of the head should have a neurological examination previous to operation. This is even more important in those cases in which the wound appears slight than in the more severe cases, because it is only by this means that one can tell the extent of the cerebral damage, and thus have a basis for judgment as to trephining, or as to opening an intact dura to evacuate the clot or disorganized brain which results from severe contusion.

The third step in the preparation of patients with head injuries is the shaving of the entire scalp. This should be an absolute rule for many reasons. In the first place it gives a far more perfect operating field than can be secured by localized shaving around the injured area, especially when one considers the possibility of having to extend the original

incisions. In the second place it eliminates the chance of overlooking other small wounds which, having escaped notice under the hair, may prove to be of a serious nature. Finally, in the after-treatment, the accumulation of a purulent discharge in unshaved areas forms not only an unsurgical environment for a wound, but is also a constant irritation to the patient because of the exceedingly disagreeable odor which emanates therefrom.

Anatomical considerations. There are five features relative to the special anatomy of the cranial chamber to which reference should briefly be made. First, the position of the longitudinal sinus, lying beneath the median sagittal plane of the vertex; second, the position of the lateral sinus, underlying the postauricular region just above the mastoid process. In all wounds in proximity to these areas involvement of the sinuses should be anticipated. A third consideration to be noted is the relation of the middle meningeal artery to its adjacent structures (Fig. 289). Emerging from the foramen spinosum, it usually enters the dura immediately and divides into its various branches. Sometimes, however, it cuts a deep groove in the skull after leaving the foramen, and because of this fact it can in such instances easily be torn when removing the bone in the temporal or subtemporal region. A fourth point is that relative to the lateral cerebral ventricles (Fig. 289). These may or may not have been opened by the offending missile. If undamaged, it is of the utmost importance that they should not be entered by the operator in his search for foreign bodies or pieces of bone. Such an accident can practically always be avoided by the method of catheter palpation to which reference will be made, but it is well also to recall that the distance of the anterior horn from the dural surface is 5-5.6 cm., that of the posterior horn 5-5.2 cm., and that of the temporal horn 4.8-5 cm. Lastly, and perhaps more important than any of the preceding, is the relation of the cerebrospinal fluid spaces to the enveloping membranes of the brain. This relationship is well shown diagrammatically by De Martel in his treatise on *Wounds of the Skull and Brain,* a copy of whose figure is given (Fig. 290).

The surgical application of the relationships shown in the diagram is important. Leaving out of consideration the pia-arachnoid membrane, which lies closely approximated to the brain itself, it will be seen that the cerebrospinal fluid lies in the form of a lake between the dura and the brain. This fluid space is continuous with the spinal cord space and also communicates with the cerebral ventricles through the foramina of Luschka and Magendie. When a missile enters the brain, it of necessity breaks through these various layers. Within a very short time, however, perhaps an hour or two, adhesions begin to form between the dura and the brain surface as represented by the arachnoid layer. It

is evident, therefore, that infection of the meninges and ventricles, unless the foreign body actually enters the latter, can occur only by breaking down these adhesions and letting the septic material into the cerebro-spinal fluid space. It is for this reason that the dural edge of a gun-

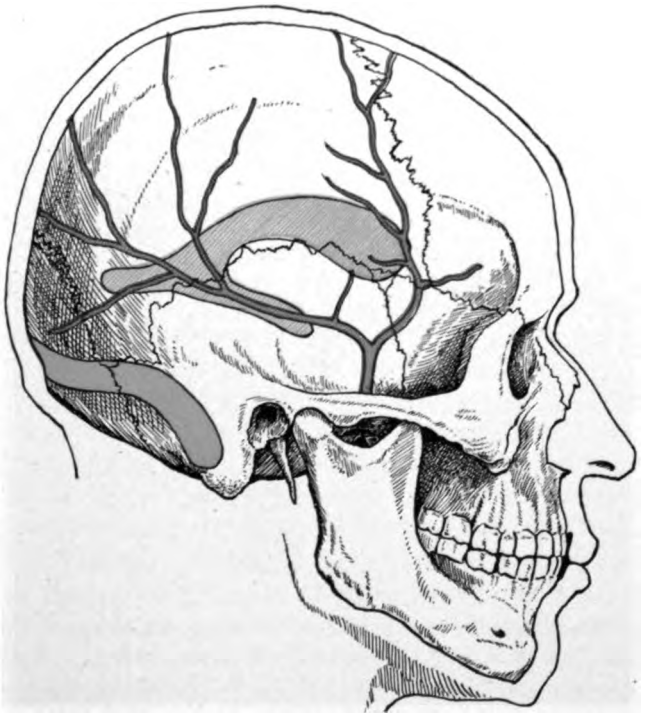

FIG. 289. DIAGRAM SHOWING THE POSITION OF THE LATERAL VENTRICLE. (*After Piersol.*)

shot wound should be handled with all the delicacy possible and never under any consideration cut away.

Anæsthesia. Should a local or a general anæsthetic be used in operating upon wounds of the skull? This question has been discussed in many articles dealing with the subject in hand, and has formed a much mooted topic at various meetings on war surgery. There are distinguished advocates on both sides of the argument. Adie and Wagstaffe (1) of the British Medical Service are very much in favor of general anæsthesia. The principal reasons for this choice are, first, because a more rapid operation can be performed, and, secondly, because the operator is not worried by any complaint from the patient.

De Martel of the French school, Gray of the British(4), and Cushing of the American are the main advocates of local anæsthesia in the form of one per cent novocaine, with adrenalin added in the amount of thirty drops to the ounce. The writer is heartily in favor of this method. The advantages which we believe that it has over ether are the following:

1. Hæmorrhage from the vessels of the scalp is reduced to almost

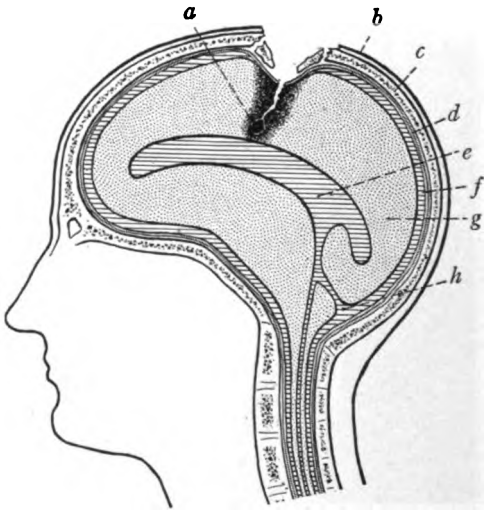

FIG. 290. DIAGRAM SHOWING THE RELATION OF THE VARIOUS PARTS OF THE BRAIN. (*After DeMartel.*) *a*, Projectile; *b*, scalp; *c*, cranium; *d*, dura; *e*, third ventricle; *f*, subdural space; *g*, cerebral cortex; *h*, foramen of Magendie.

nothing, owing to the action of the adrenalin contained in the mixture. This not only conserves the blood of the patient, but it also saves time spent in checking the free bleeding with which one always has to deal when operating under a general anæsthetic.

2. The use of novocaine does away with any tendency on the part of the operator to hurry through his task, and therefore perform an incomplete operation. As will be seen in the subsequent remarks on operative procedures, it is only by the most painstaking and thorough methods that the best results can be secured. If one feels hurried because of the knowledge that the patient is under general anæsthesia, it often happens that small fragments of bone will not be found and removed, whereas under local anæsthesia, without time as a factor, they would be disclosed after a more careful search.

3. A local anæsthetic encourages more delicate handling of tissues

than does the use of ether. This point is of unquestioned value in dealing with tissues anywhere, but it cannot be too strongly emphasized as regards the brain, where often the slightest roughness will result in serious hæmorrhage, which, even if not fatal, may require considerable added time for its control.

4. A fourth advantage of local anæsthesia is seen in the hours immediately following operation. The sight of retching and vomiting of patients after ether anæsthesia is familiar to all, and when one realizes the enormous elevation in intracranial pressure resulting from such straining, it is easy to see how serious, secondary cerebral bleeding often results, to say nothing of the discomfort to the patient, or of the added care required of the nurses.

5. Not at all negligible is the greater safety of local over general anæsthesia. The solution of novocaine and adrenalin, in the strength mentioned above, can be used in almost unlimited quantities. From 30 to 50 c.cm. is the amount usually necessary, but the writer has seen up to 120 c.cm. given without the slightest deleterious effects.

6. Lastly, certain assistance can be obtained during the course of an operation from a conscious patient. This may consist in changes of position for one thing, but a more important help is that mentioned by Colonel Gray of the British Medical Service. This writer has frequently encouraged his patients to cough or strain when the track is being cleaned out. This process raises the intracranial pressure and forces out through the opening in the dura softened tissue as well as in-driven bone fragments, and sometimes even metallic foreign bodies. By this means it is quite possible to clean out a track very considerably, and it should always be attempted before taking up further means, such as catheter suction.

From what has just been said, it must not be inferred that every case of gunshot wound of the head can be operated upon under a local anæsthetic. One has often to deal with patients having multiple wounds. in which novocaine would obviously be out of the question. Again, some patients are so nervous as to be unable to withstand even the relatively slight discomfort of an operation under novocaine, especially when this involves the rather ominous sound necessitated in removing portions of the skull. A third type of cases in which it is often extremely difficult or even impossible to operate under local, includes those patients who have extensive wounds of the frontal lobes. Such patients have usually lost all of their normal inhibitions and may not even tolerate the introduction of the injection needle into the scalp.

In this connection it is well to mention the combined use of morphine with novocaine. While this drug or its derivatives should be

used with caution in head cases, at the same time there is usually no contra-indication to a preliminary injection of ¼ gr. of morphia. If given 15 to 20 minutes before the novocaine is to be used, most patients will become sufficiently calm not to mind any of the discomforts of an operation under local. In our experience, at least 90 per cent of all head cases were operated upon under novocaine combined with the preliminary morphine or omnopon injection.

OPERATIVE PROCEDURES

Before entering into the details of operations, mention should be made of a few general considerations. As gunshot wounds are essentially war wounds, one is always confronted with the problem of having to operate upon a large number of patients in as brief a time as possible. For this reason, the ordering of the operating room is most important. An excellent scheme is to have two tables for the use of a "team" doing head cases. In this way, while one case is being operated upon, another patient can be placed on the second table, where his head can be shaved by an orderly. Then, while the first case is being finished, either the operator or his assistant can infiltrate the second patient's scalp with novocaine, and prepare the operative field.

In regard to the operating table, it should have an arrangement by which the patient's head can be elevated, as this aids materially in the reduction of venous hæmorrhage from the brain. De Martel employs the sitting posture entirely, and it is possible that this method should be adopted more extensively.

At least one assistant is essential in operating upon wounds of the head, as it can never be foretold what difficulties one may encounter, and situations almost always arise with which it is impossible to cope with only a single pair of hands. The assistant, moreover, should be familiar with neurological surgical methods, and able to examine a patient neurologically, thus saving the time of the operator by going over the patient while he is being prepared for operation.

Lastly, it should be pointed out that an infinite amount of patience is demanded of any operator who wishes to obtain the best results with gunshot wounds of the head. The opening of the skull and removal of the superficial parts of the fracture are usually relatively simple procedures, but the thorough and careful cleaning of the track of the missile, and the delicate search for and extraction of the numerous small pieces of indriven bone constitute a task which in itself frequently takes an hour to accomplish properly.

As a basis for describing the operative methods suitable for different

types of wounds of the skull and brain, some classification of such wounds is necessary. Cushing ([3]) has already suggested a gradation, according to the degree of cerebral damage, but for purely operative purposes a somewhat simpler grouping can be made, as the type of operation performed in several of his groups would be practically the same. The following scheme will therefore be used in discussing the operations:

I. Scalp wounds.
II. Fractures of the skull without penetration of the dura.
III. Fractures of the skull with penetration of the dura.
  a. Dura slightly punctured.
  b. Dura widely torn; bone fragments or metallic foreign bodies driven into the brain.
  c. Through-and-through wounds.

I. Scalp wounds. Practically without exception, all simple scalp wounds should be operated upon under local anæsthesia. After infiltration of the area the wound, including all dirty or contaminated tissue down to the pericranium, should be completely excised. This excision should be *en bloc;* the track of the wound should not be touched with instruments or fingers. This fact cannot be too strongly emphasized, as upon it depends the technique of the operation. In teaching operators unaccustomed to war surgery, Major S. C. Harvey has told me that he used to direct those under his instruction to pack a small bit of gauze soaked in iodine into the wound, thus preventing a flow of dirty material from the wound over the scalp, and giving the surgeon something definite to keep away from. The pericranium may or may not have been touched by the missile. If the skull has not been exposed it depends upon the severity of the patient's neurological symptoms as to whether further investigation should be made. If symptoms such as partial hemiplegia, aphasia, etc., are marked, and the case has come to operation early, that is within twelve hours of injury, a decompression at the site of the wound should be made, although the skull is intact, and the dura examined. In such cases, this membrane almost always appears dark-colored and is tense, and it is in this type of condition that one is justified in incising an intact dura. The usual finding is a moderate amount of semifluid subdural clot and a superficial layer of disorganized brain tissue. Both can be washed out easily with a stream of normal (physiological) salt solution, the temperature of which should be from 105° to 110° F. The dura should then be carefully sutured with fine silk. Patients upon whom this procedure has been correctly carried out clear up very rapidly from their intracranial symptoms and regain function of their limbs or speech, as the case may be, far sooner than

when an incomplete operation has been performed. If the operator's technique of excising the dirty scalp wound has been what it should be, the danger of a subsequent meningitis is practically negligible. It must be understood, however, that what has just been said applies only to cases coming to operation early, when the wound is merely dirty and infection has not started. If attempted at the base, where, as a rule, patients do not arrive until 24 or 48 hours after the reception of their wounds, the danger of meningitis is exceedingly great, and the best policy is to excise the scalp wound only, and be content with a more gradual and less satisfactory disappearance of symptoms through natural processes of absorption. This is contrary to Roberts(7) and Tabuteau (9), who advise opening the dura in such cases even when operated upon at the base.

II. Fractures without penetration of dura. These cases vary in degree from a slight crack in the outer table to an extensive comminution with depression of the inner table. The operative measures vary with the condition found. No matter how small or insignificant the crack may appear, a small trephine or burr opening of the skull should be made. If no serious intracranial symptoms exist and no depression of the inner table be detected, this is sufficient; and the scalp may be closed. The reason for the burr opening, aside from its necessity in detecting depression, is to supply drainage. In a certain number of cases, if such an opening is not made, infection will creep in through the crack and a brain abscess will result. This sad catastrophe has only to be seen once to be convincing, but should not, from our present knowledge, be seen at all.

If the patient has marked signs of injury to the brain, the same indications should be used for guidance as were discussed under simple scalp wounds. If the fracture is found to be depressed, such an area should be removed entirely, whether large or small. The two latest and most approved methods for accomplishing this are those of De Martel and of Cushing. The former lays down a large bone flap around and including the fracture, the comminuted fragments of which are then removed from the inside by bone-cutting forceps (Fig. 291). At the end of the operation this flap is reflected. In our opinion this rather extensive procedure should be used only in exceptional instances by the most skillful neurological surgeons. Otherwise there is the probability that the bone flap would be made too large and would be infected, when the situation would be the same as in elevating depressed fractures and leaving the fragments in. Cushing's method is to make a series of small burr-openings around the depressed area, usually four in number. This is accomplished by the simple means of a perforator and burr

(Figs. 292 and 293). These holes are connected by a cutting forceps, —preferably of the Montenovesi type, as these push the dura away much less deeply than forceps of other design (Fig. 294). The block of bone thus encircled can then be lifted out gently and easily, and an

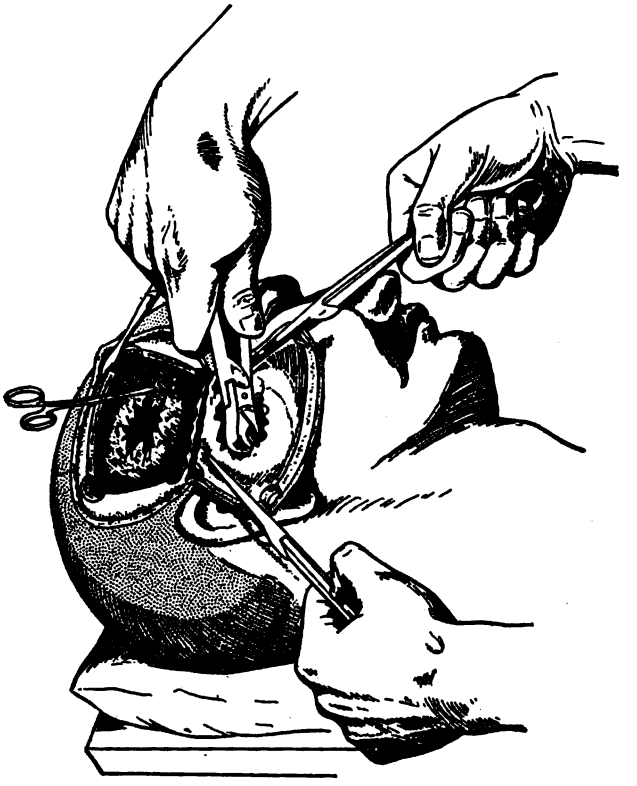

FIG. 291. BONE FLAP METHOD OF TREATMENT OF A GUNSHOT WOUND OF THE BRAIN. (*After DeMartel.*)

immediate free field secured for the control of any hæmorrhage which may have been produced by spicules of the inner table which have pierced branches of the meningeal artery (Fig. 295). When the dura is uninjured and there are no indications for incising it, the removal of the block completes the operation, with the exception of closure. The latter is effected with or without a small rubber-tissue drain, according to whether the case is an early or late one. In early cases also, a more perfect cosmetic result is obtained by using a layer of fine silk sutures

for the galea, and the same for the skin. In late, and consequently infected cases, silkworm gut is preferable.

III. Fractures with penetration of the dura.

a. Dura slightly punctured.

When it is found that one or more spicules of inner table, though not detached, have pierced the dura, the case should as a rule be treated as those in which the dura is intact. In early cases the scalp may be sutured tightly. In very dirty or late cases a rubber-tissue drain should be left. Ordinarily the small hole in the dura should not be touched, but very occasionally one sees a case at the base in which infection has

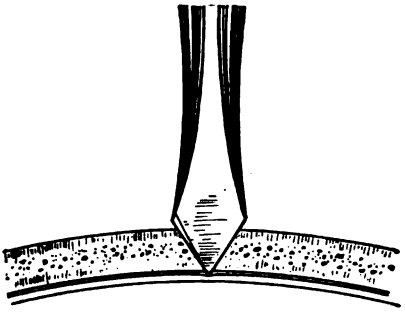

FIG. 292. ILLUSTRATION OF THE USE OF THE CRANIAL PERFORATOR. (*After Cushing.*)

already made its way into the brain tissue, resulting in a marked encephalitis and great intracranial tension. The only hope in such a case is to open the dura widely and leave it open; to close the scalp only partially or not at all. Such cases simulate the serious and truly penetrating type, the details of which are to be taken up under the next heading. The mortality in patients in whom the dura has only been slightly pierced should not be over 10 per cent.

b. Dura widely torn; bone fragments or metallic foreign bodies driven into the brain.

Under this heading we come to the really serious type of cranial wounds. The degree of severity may and does vary tremendously. In forward areas one sees cases in which the whole frontal or occipital areas have been shot away, and yet the patient has lived to arrive at a field ambulance or casualty clearing station. At the base, even after two or three days of transit, cases frequently arrive with large open wounds of the skull, out of which has emerged in the form of a hernia brain tissue up to the size of a large orange. Such cases, however, do not offer the detailed operative problem which is afforded by others of a somewhat

milder, but still extremely severe nature. Two problems usually confront the surgeon when in the presence of patients with wounds of the former character. Is it not better, first, to operate on other cases who have a greater chance of recovery; and again, should one try to save a life, when, if the attempt is successful, one knows that permanent idiocy, and either a state or family burden will result? These questions must be decided by the individual conscience, but one should always remember that the recovery of function in cases of wounds of the brain is often far greater than could possibly have been supposed from the character of the neurological findings. Time and again the writer has seen patients

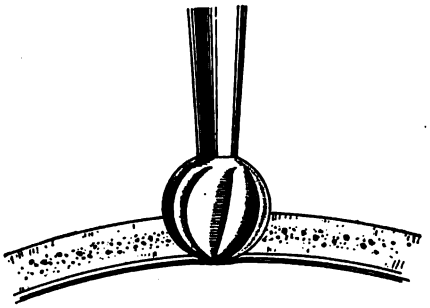

FIG. 293. ILLUSTRATION OF THE USE OF THE CRANIAL BURR. (*After Cushing.*)

with partial or total hemiplegia, or with all degrees of motor or sensory aphasia, come back to almost absolutely normal physiological and mental function. The most striking example of this statement in my experience was that of a lieutenant in the 2nd London Regiment. He had a large depressed fracture over the left parieto-frontal region, with bone fragments driven into the brain and penetrating the left lateral ventricle. Neurological examination before operation revealed a complete motor aphasia with the exception of the response of "No," while the right arm and leg were totally paralyzed. Operation was performed in September, 1917, some eight or ten hours after the reception of the wound. Before leaving the casualty clearing station four weeks later, he was beginning to carry on a fair conversation, and his paralyzed side was showing slight movement. In July, 1918, he wrote me a letter in which there was no trace of any aphasia, saying that for two or three weeks he had been playing tennis!

Coming back to the more usual types of cerebral gunshot wounds, it will be well to describe a little in detail some of the varieties most frequently encountered in order to gain a better idea of the operative measures adopted.

1. In the so-called "gutter-wound" (Fig. 296), the missile has cut a deep furrow through the scalp and skull, driving fragments of bone into the brain at right angles to its course. These fragments may lie fairly superficially in the cortex just beneath the dura; they may lie deeply and penetrate one of the ventricles, or they may have been driven far inward, sometimes crossing the falx cerebri to the opposite hemisphere. The great point is that in all cases they leave a perfectly definite track of disorganized soft tissue behind them, and it is through this track that they must be sought and extracted (Fig. 297).

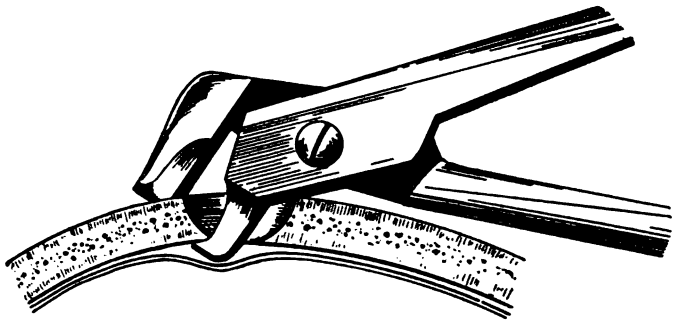

FIG. 294. ILLUSTRATION OF THE USE OF THE MONTENOVESI FORCEPS. (*After Cushing.*)

2. The small round wound is usually caused by a missile which has entered and lodged in the brain (Fig. 298). The hole in the skull usually corresponds roughly to the size of the metallic fragment. Small pieces of bone are also carried in and are distributed along the track. Here again the missile may lie superficially, or it may traverse nearly the entire length of a hemisphere, sometimes lodging in or passing through one or both lateral ventricles (Fig. 299).

3. The widely lacerated wound is usually caused by a large, jagged piece of shell-casing. In these there is practically always a marked comminution of skull and a great amount of extruding brain tissue.

Having shaved the entire head and cleaned it carefully with soap and water it is then washed with a 1 : 1000 bichloride solution, the wound itself being washed out with the latter also. The operative field is then anæsthetized with novocaine. After this process it is well to clean the scalp still further with alcohol, followed once more by the bichloride. The next step is to make scratch marks on the scalp, as indicators for the proposed operative incisions.

This brings us to the actual technical details of operations for pene-

trating wounds of the brain. The earlier writers on this subject during the war (Roberts,[7]; Tabuteau,[9]; Sargent,[8]; Gray,[4]), had pretty generally adopted the following scheme: The scalp wound was excised down to the bone; a trephine opening was made at one side of the fracture, and working from this, the damaged area was removed by the use

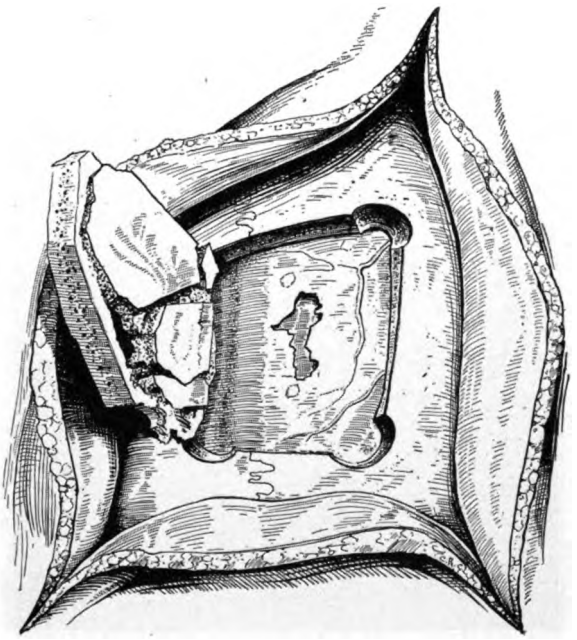

FIG. 295. REMOVAL OF AN AREA OF CRANIAL INJURY. (*After Cushing.*)

of gouge-forceps or rongeurs. As much as possible of the disorganized brain and superficial bone fragments was washed out by a stream of saline. A finger was next introduced through the dural opening, and foreign bodies or further bone fragments were searched for and withdrawn with forceps. The wound was then closed, usually with some form of drainage, either down to the torn dura, or extending into the damaged portion of the brain.

Since this early method, De Martel ([6]) has described his technique of laying down a bone flap in those cases in which there are no radiating fracture lines running off from the site of penetration. A rectangular skin flap around the wound is incised, and a corresponding bone flap laid down by the use of either the Gigli saw or by mechanical motor-driven instruments (Fig. 291). The next step consists in chipping

away the broken pieces of the skull in the middle of the bone flap by working from the inside. The remainder of his operation is practically identical with the method outlined briefly above, namely the washing out of the track in the brain with a stream of normal saline and the digital exploration, palpation and removal of bone or metal fragments from the cerebral tissue. The bone flap is now reflected and a cigarette drain left through the original wound, which has been excised. This procedure

FIG. 296. EXAMPLE OF A GUTTER WOUND, SHOWING PARTIAL CLOSURE AFTER OPERATION.

has the advantage of removing permanently the least possible amount of the patient's skull, but it also embraces the unwise principle of putting back and covering up an area of bone tissue which must have become contaminated with septic material during the course of the operation.

The most recent, and, we think the most surgically sound operative technique for penetrating head injuries is that worked out by Cushing (²) in 1918. A description of this author's method is as follows:

Novocaine is used as an anæsthetic, preceded by the administration of 1/3 or 2/3 of a grain of omnopon hypodermically. After the scalp has been completely shaved and prepared, scratch lines are made to outline the incisions to be used. These are preferably "tripod" in nature, radiating from the wound center (Fig. 300). By this means, a reflection of the three flaps gives ample exposure, and unless the

wound is very large, there is usually sufficient play for a neat closure without undue tension. It brings the mid-point of the closed or unclosed wound directly over the damaged area, and therefore if infection occurs, or a hernia develops, it can be treated much more easily and satisfactorily than if it be entirely or even partially overlaid by a flap of skin.

The wound is next excised down to the bone, after which the instruments used for this purpose are discarded. The flaps are then retracted and undermined sufficiently to expose completely the injured bone.

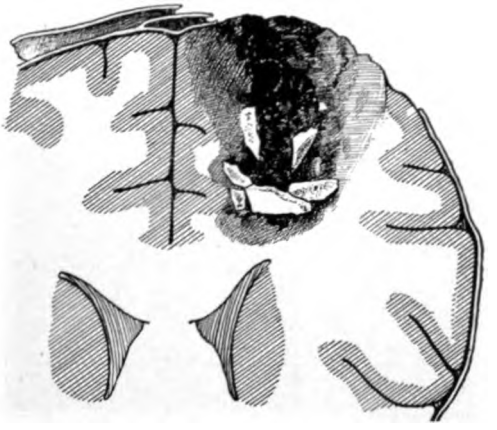

FIG. 297. DIAGRAMMATIC SKETCH OF THE CEREBRAL DAMAGE IN A GUTTER WOUND. (*After Cushing.*)

Around the damaged skull area several holes are bored with a perforator and burr (Figs. 292, 293). These holes are then connected by a linear cutting forceps, by preference those devised by Montenovesi, as they can be used with the least attendant shock, and are the most satisfactory for going around corners (Fig. 294). The block of bone thus encircled can then be lifted out as a whole (Figs. 295, 301, and 302). In this way the contaminated bony area is excised just as was the scalp wound, without working through an infected area at any point.

The next and most important step is the treatment of the track of the foreign body or bone fragments in the brain. The dural edge around the point of penetration should not be excised. By so doing the sealed-off cerebrospinal fluid spaces are reopened for infection, as was pointed out earlier, and in addition, very troublesome bleeding is practically always started from the cerebral vessels adhering to the edge.

Instead of digital palpation and exploration of the damaged brain area, Cushing has introduced the use of a fairly small-sized, very soft rubber catheter. Before using the catheter, however, the patient should be urged to cough or strain. By this means the intracranial pressure is raised and frequently surprising amounts of soft, dirty tissue from the track are pushed out through the dural opening. Not uncommonly,

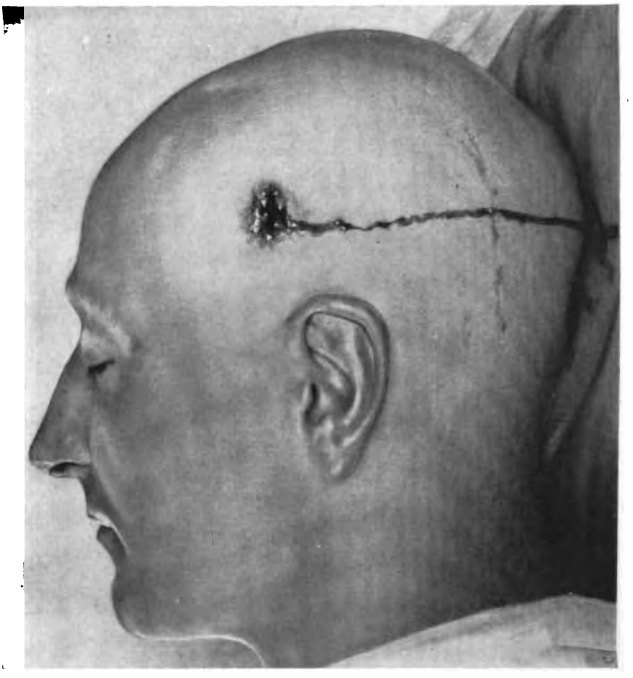

Fig. 298. Illustration of the Small Penetrating Type of Cranial Wound. (*After Cushing.*)

large and small indriven bone fragments and even superficial metallic fragments have been evacuated in this simple way. It should always be attempted before any other method of track cleansing. The catheter is then inserted gently into the track of disorganized brain tissue and with it the small bone fragments and foreign bodies can be palpated with almost as much ease as with the finger, by the sensation transmitted along the rubber (Fig. 303). When thus palpated they can be extracted easily with alligator forceps. The small, soft catheter will be found to follow the track perfectly, the normal cerebral tissue surrounding it being suffi-

ciently resistant to prevent the catheter from entering it, unless undue force is used.

In spite of this resistance operators who are unused to the palpation of brain tissue may force a catheter beyond the end of the track even when they think they are using great care. In some instances this may not entail very serious damage, provided the mistake is recognized and the catheter not introduced again beyond the track limits. However, if the bottom of the track is not far from the ventricle, the catheter may be forced into it, and this is a most serious error in technique, reducing at once the patient's chance for recovery probably 30 per cent.

If the finger be used for palpation, at least two undesirable things are almost certain to happen. First, unless the hole in the dura is ex-

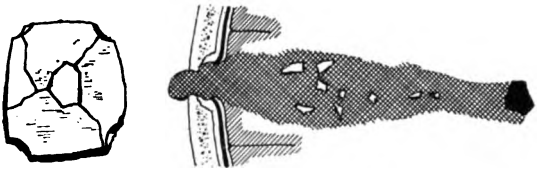

FIG. 299. DIAGRAMMATIC SKETCH OF THE CEREBRAL DAMAGE DUE TO PENETRATION BY A METALLIC FOREIGN BODY. (*After Cushing.*)

tremely large, the dural edge will be stretched or torn, and the adhesions between it and the cerebrospinal fluid space opened up. Secondly, anything so large as a finger is sure to push the contaminated, disorganized brain tissue out into the surrounding normal brain, an event which should be most strongly guarded against. This dead, disorganized tissue is the very thing one wishes to keep confined to the track and to remove, as it is this which offers the best possible soil for infection. Its removal also can be accomplished most satisfactorily by the catheter. By attaching a Carrel-Gentile syringe to the free end of the catheter the soft, pulped cerebral tissue can be sucked up into its lumen (Fig. 304). The catheter is then withdrawn and its contents evacuated. This process of sucking out the track must be repeated over and over again, until every available bit of disorganized tissue has been gotten out. Sometimes small bits of bone or metal will be found to have been sucked out in this way, as well as the pulped brain tissue and clots. By this method a track can be cleaned to a depth of 5 or 6 inches, whereas by the older means of washing out with a stream of saline, only the most superficial parts of the track can be reached, while the positive pressure thus exerted forces infected material into the brain. The suction exerted by the bulb of the

Carrel-Gentile syringe is not sufficient to bring away the resistant normal brain lining the track.

One becomes familiar with this method of catheter palpation very easily after a little practice, and very often it is possible to appreciate not only the difference between a piece of bone and a small, formed clot, for instance, but even that between bone and metal.

After the prolonged and thorough cleansing of the track in this

FIG. 300. ILLUSTRATION OF THE TRIPOD INCISION. (*After Cushing.*)

manner, the previously existing increased cerebral tension will be found to have been greatly reduced, if not actually brought down to normal, and instead of a herniation of brain tissue through the dural opening the surface of the brain will be level or depressed. If the case has come to operation within the first six or twelve hours after being wounded, primary closure is usually desirable. The three flaps are brought together, preferably by a layer of buried, fine silk sutures in the galea, thus taking all the tension off the skin sutures. A small rubber tissue drain may be left to take care of any collection of serum, but this should always be removed after twenty-four hours. If the operation is performed at the base, *i. e.*, after an interval of eighteen hours or more, it has been found better to make only a partial closure, leaving the flaps open in the middle, directly over the dural perforation. Thus if a

hernia develops, it can be dressed and treated directly, which is far preferable to having it obscured and held in under a flap of skin. If no hernia develops, no harm is done, as a fibrin layer quickly forms over the dural opening if rubber tissue is used as a dressing, and the ends of the skin flaps fold down in due course, leaving eventually only a small granulating area in the centre (Fig. 305).

The efficacy of this method of partial closure in cases operated upon one or two days after injury, was strikingly illustrated in the writer's series at a base hospital in France. Out of one hundred cases of penetrat-

FIG. 301. PHOTOGRAPH OF A BLOCK OF BONE REMOVED FROM A CASE OF GUNSHOT WOUND OF THE HEAD.

ing wounds twenty conformed to a type sufficiently similar so that comparisons could be drawn. These were of the usual gutter type of wound, with a large hole in the dura and bone fragments showered into the brain. In eleven of these patients a primary closure was attempted with the result that seven died. In the other nine, partial closure only was made, and the wound left open over the dural penetration. All of these patients made excellent, and so far, permanent recoveries. That these cases could be left open and thus recover was due in no small measure to the very great care used in the subsequent dressings. It is of extreme importance to emphasize this, because no matter how carefully a cerebral operation has been done, if a hernia develops, or exposed brain tissue is purposely left, the future avoidance of fatal complications depends on the minutest details in the dressing methods. These will be more fully discussed later.

The technique just recited is applicable in general to all cases where the dura has been penetrated. There are, however, certain points to be

emphasized, and certain types of cases to be further discussed. During the process of cleansing the wound track it is well to have the X-ray plates at hand, so that the number and relative position of all the small indriven bone fragments can be ascertained as nearly as possible. It is of the greatest importance that every one of these be removed, as it is they, rather than retained metallic bodies, which are apt to give rise to subsequent abscesses.

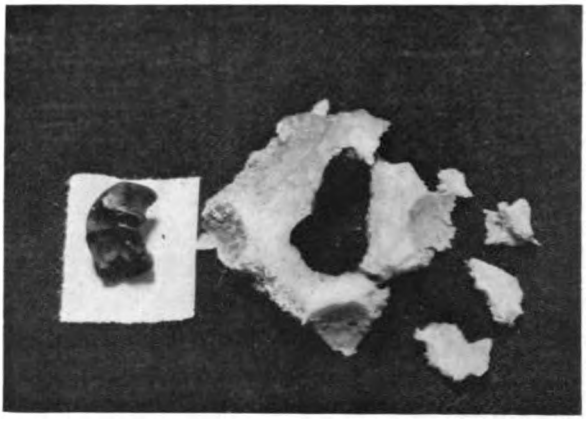

FIG. 302. PHOTOGRAPH OF A BLOCK OF BONE REMOVED, WITH THE FOREIGN BODY AND THREE BONE FRAGMENTS.

as possible, i. e., at right angles to the table rather than more or less consensus of opinion at the present time seems to be about as follows: If the missile is easily accessible, as determined by X-ray examination and palpation with the catheter, it should unquestionably be removed, either with alligator forceps if it be lead, or with a magnet if it be iron or steel. If it has been driven some distance into the brain, let us say up to 3½ or 4 inches, even then by passing a round-ended nail down the track and bringing the magnet up to the head of the nail a successful extraction can very often be made (Fig. 306). Beyond this distance it is difficult to handle the nail, and there is the added danger of getting off the track at so great a depth. Therefore it is probably much sounder policy to leave inaccessible missiles, especially as the available statistics show that only relatively few patients with such pieces retained ever have any further difficulties([8]).

It need hardly be said that the use of alligator forceps or of the round-ended nail in the extraction of foreign bodies requires the most

delicate manipulation. The track of the missile must be followed with exceeding care and with extreme caution, lest the slightest deviation be made into unharmed areas. Upon introducing the nail it should not be pushed, but allowed by its own weight to slide along the track. This, of course, presupposes that at this juncture, the patient's head should be turned into such a position that the track will be as nearly vertical

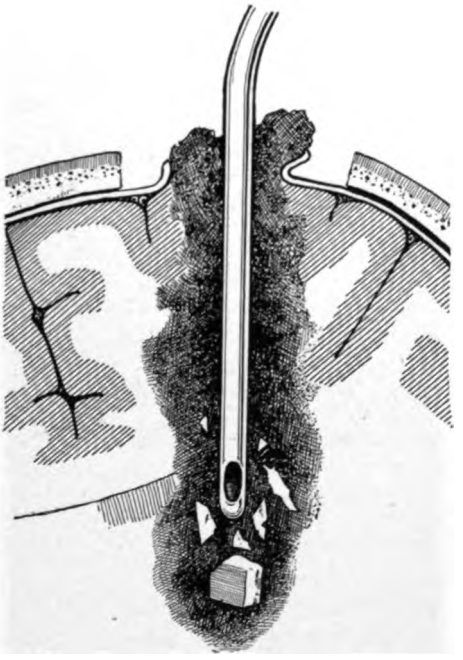

FIG. 303. DIAGRAMMATIC ILLUSTRATION OF THE CATHETER METHOD OF CLEANSING THE WOUND TRACK. (*After Cushing.*)

as possible, i. e., at right angles to the table rather than more or less parallel to it.

Mention was made under anatomical considerations of the special hazards attendant upon sinus cases. Wounds over the median sagittal plane at the vault, and over the superior mastoid region are likely to involve the superior longitudinal and lateral sinuses respectively. The greatest care should be exercised in the removal of the block of bone over these areas, so that no additional damage may be done. If the sinus is found to have been pierced or torn by a bone fragment, the best method for the control of hæmorrhage is to place a piece of the

patient's own muscle over the rent and hold it there with a flat spatula for a few minutes. Some writers advise sewing this muscle to the dura, but in the author's experience this is unnecessary, as the muscle has never failed to adhere by itself, even in the most extensive tears. In all wounds over these areas it is well as a prophylactic measure to prepare a place on the patient's leg from which a piece of muscle may be quickly secured by an assistant. Usually, however, a sufficiently large

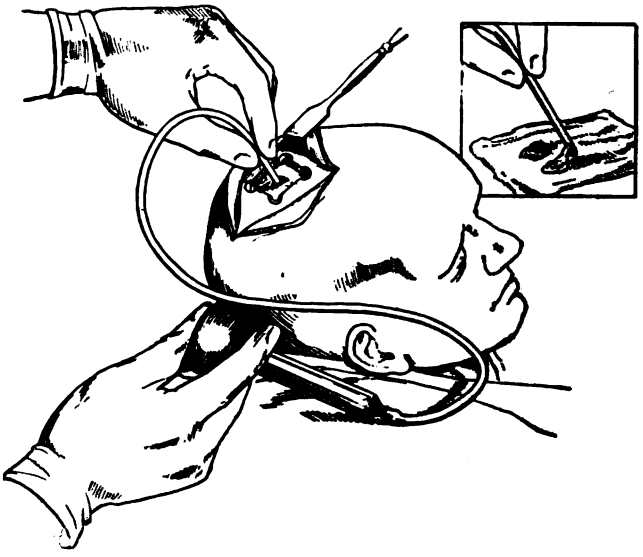

FIG. 304. SKETCH SHOWING THE USE OF THE CARREL-GENTILE SYRINGE WITH A CATHETER FOR SUCTION. (*After Cushing.*)

piece can be obtained from the temporal region. It is especially important in dealing with sinus cases to remove a block of bone sufficiently large to give ample room for the control of hæmorrhage. Many surgeons are fearful of making an adequate exposure because of the proximity of the large blood sinuses, not realizing that the greatest danger is in a restricted field of operation.

Packing with gauze for the control of sinus or other hæmorrhage from the brain is practically never necessary, and is extremely dangerous, not only because of the almost certain destruction of normal brain by its use, but also because of the added risk of infection by thus plugging up spaces which should be left free. Likewise no attempt at ligation of a sinus should ever be made. It cannot be done without further brain destruction and further hæmorrhage, and the use of muscle

is almost always adequate. The special features of sinus cases have been most excellently discussed by Holmes and Sargent ([5]). These authors, however, advise against operation, which we believe is wrong provided experienced surgical attention can be obtained.

Another type of case requiring special discussion is that in which

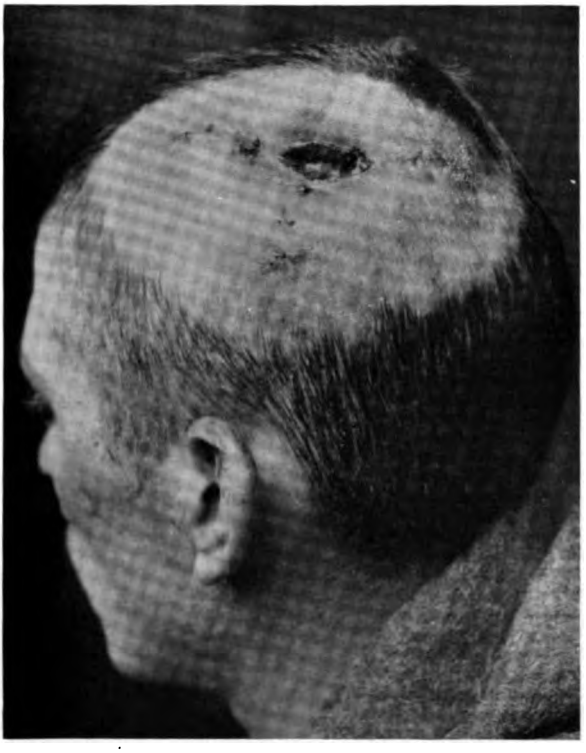

FIG. 305. PHOTOGRAPH OF A CRANIAL WOUND WHICH HAD BEEN LEFT WIDELY OPEN AT OPERATION.

a cerebral ventricle has been entered by a missile or bone fragments. These cases, although among the most serious, are by no means hopeless. In addition to the careful cleansing of the track, removal of bone, débris, etc., the bloody contents of the ventricle should be evacuated completely with the catheter. Permanent recoveries have frequently followed such a procedure, and in a recent series at a base hospital, one patient in whom both lateral ventricles had been traversed by the missile made an unexpected convalesence.

There are at times wounds in the subtemporal or suboccipital region in which it is obviously impossible to apply the method of encircling and block removal. Probably the best way to attack such a fracture is by making a burr hole at one side and working in toward the dam-

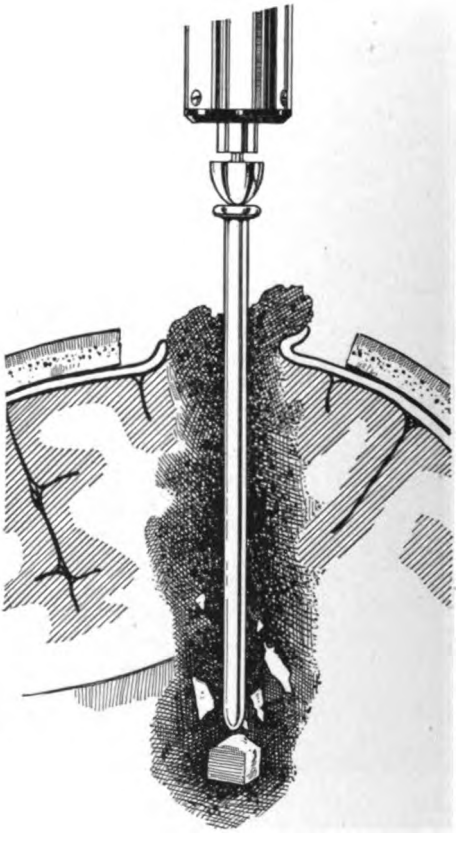

FIG. 306. SKETCH ILLUSTRATING THE USE OF A NAIL AND MAGNET IN REMOVING A METALLIC FOREIGN BODY.

aged area, taking it out piecemeal. Having exposed the opening in the dura in this way the treatment of the track can be carried out as outlined.

c. Through-and-through wounds, i.e., those traversing the cranial chamber.

Here we have to do with two distinct cranial injuries. Most writers advocate excising both the wound of entrance and that of exit, with the removal of bone fragments, etc., as in other cases of dural penetration.

Through-and-through wounds, however, have certain special characteristics (Fig. 307). They are commonly caused by high velocity bullets, either from rifle or machine-gun fire. The entrance wound is very small and the hole in the skull clean cut. The exit wound, on the contrary, is large, with many elevated, and strangely enough, depressed bone fragments around it. Statistics from this war and from the American Civil War show that whether this type of wound is operated

FIG. 307. PHOTOGRAPH OF A THROUGH-AND-THROUGH WOUND OF THE BRAIN.

upon, or whether it is left unoperated, the mortality is approximately 80 per cent. The writer has been accustomed to operate upon the exit wound only. In no case which has come to autopsy subsequently has any sign of trouble been found at the entrance wound. The small bone fragments at this site are apparently carried through and out at the wound of exit. The exit wound should be treated like all other penetrating injuries, and the track cleaned as deeply as possible. This can often be accomplished nearly through to the wound of entrance. The scalp is then closed or left open, depending upon whether the case has been operated upon early or late.

SURGICAL TREATMENT OF COMPLICATIONS

There are four conditions which may follow wounds of the brain that call for surgical intervention of one form or another. These are meningitis, encephalitis, ventriculitis, and abscess. All are extremely serious, but recoveries sometimes take place after appropriate treatment.

Meningitis. If this is localized to the immediate vicinity of the wound, and the wound has been left open at operation or opened up promptly thereafter, the condition is fairly hopeful. If it be of the basilar type, repeated lumbar punctures are the only means of drainage, and these are usually of no avail.

Encephalitis. This is seen in its worst form in cases of gas bacillus infection. The whole area of the wound becomes a softened, stinking mass of fungus. Before any great protrusion has taken place, the wound should be opened up widely, if it has not been left open at operation. A catheter should then be re-introduced into the track, which can usually be found quite easily, and as much more of the softened brain sucked out as possible. This will very often reduce the size of the protruding mass considerably. In these gas cases, too, the author has frequently made use of the anti-gas gangrene serum, applying it locally to the encephalitic mass on pledgets of cotton, as well as giving it intramuscularly. Although the serum has no bactericidal qualities it has been shown by repeated laboratory examinations that the organisms in the wound have a tendency to die out much more quickly when the serum is applied in this way than when no serum is used. In all these encephalitic cases, a careful search should also be made for any small bone fragments which may not have been removed at operation. It is almost unnecessary to add that the elaborate dressing procedures, which are required in such instances as those just detailed, can hardly be carried out successfully with the inadequate facilities usually found in a hospital ward. The patients, therefore, should as a rule be taken to the operating room, where circumstances will permit, even though this becomes a daily or bi-daily process.

Ventriculitis. Cases which develop a ventricular infection are well-nigh hopeless, though even here in certain instances recoveries have taken place. If no small bone fragments have been retained in the ventricles or in their walls, and the ventricle has been drained either by leaving the wound open down to it, or by the subsequent spontaneous drainage of cerebrospinal fluid, certain cases in the acute stage, where the laboratory reports have shown streptococcus or staphylococcus aureus, have been known to recover. The author has seen three or four

patients with subacute ventriculitis who lived from two to eight weeks after the receipt of their original wound. All these cases died, and at autopsy one or more small pieces of bone were found embedded in the ventricular wall. Both lateral ventricles, the third and fourth ventricles, and the central canal of the cord contain in these subacute cases a thick creamy pus. A very thick fibrino-purulent exudate also overlies the whole base, and this is undoubtedly the ultimate cause of death. The

FIG. 308. PHOTOGRAPH OF A HEALING ABSCESS TRACK.

two out-standing symptoms of a subacute ventriculitis are persistent vomiting without signs of intracranial pressure, and a greatly fluctuating temperature. It is possible, when a positive diagnosis can be made, that the ventricle should be reopened through the old track and drained. So far, in our experience, no case of this type has ever recovered.

Cerebral abscess. Abscess of the brain subsequent to a gunshot wound is, of course, one of the complications which one would expect to find in a certain percentage of cases (Fig. 308). It may develop around a retained metallic foreign body, but more frequently results from retained bone fragments or other particles of débris. The more careful the *débridement* at the primary operation, the less likely is an abscess to eventuate. It may develop within a week or within many

months, even a year after the original wound; and the symptomatology, diagnosis and treatment are exactly the same as in cases in civil life, except that in the case of gunshot wounds, one may have the added help of localization because of a retained foreign body which is shown by X-ray examination.

Postoperative measures. In addition to the usual after-treatment of any patient who has undergone an operation, a few special points should be brought out in regard to cases of head injury.

As complete rest and quiet should be obtained as is possible under the circumstances by the cautious use of morphine combined with bromides. Many patients in the days just following operation are entirely irrational and very unruly, constantly thrashing around in bed, talking and crying out incoherently, and sometimes attempting to get up and walk. Morphia may have little or no effect upon such cases, but other sedatives such as hyoscine or scopolamine should be tried, and when circumstances permit, there should be a special attendant to see that the patient does himself no harm. The attendant should not, however, use any considerable force with the patient, as this always tends to aggravate the situation rather than to relieve it. It is hardly necessary to add that in cerebellar injuries, morphia should be used only in the most extreme circumstances, owing to the proximity of the respiratory center.

Dressings, with special reference to hernia cerebri. Where primary closure of the wound has been made, the patient's general condition should be followed with the greatest care, and if the temperature becomes elevated even one or two degrees at the end of twenty-four hours, the dressing should be removed, and the wound inspected. If there is any bulging, several stitches should be removed, all serum evacuated, and a rubber tissue drain left in place. If the patient then does well, nothing further is necessary; but if a hernia develops, the utmost care and very particular dressing methods are absolutely essential. If the hernia remains small, it should be covered simply with gutta-percha tissue and a dressing which is not too tight. Frequently, however, a very large herniation may take place, especially in cases infected with the Welch organism. This may be true either after a primary closure, or when the wound has been left open. Here one has to deal with a mass of soft, delicate tissue, often as large as an orange, and the problem becomes one of painstaking and tedious care. From the first, the whole of such a fungus should be completely surrounded with gutta-percha tissue, not letting gauze touch it at any point. To keep pressure from the dressing away from the hernia a ring of cotton in the shape of a doughnut should be placed just outside of the gutta-

percha, resting on the patient's scalp. Over this the dressing can then be put on (Fig. 309). In a few days a certain amount of sloughing will occur from the superficial layers of the hernia, ridges simulating convolutions will appear, and between these there will be furrows and crevasses from which pus and the secretions of the sloughing tissue

FIG. 309. PHOTOGRAPH ILLUSTRATING THE METHOD OF DRESSING A CEREBRAL HERNIA.

exude. These furrows should be kept open by placing in them little pledgets of cotton soaked in eusol, and similar pledgets should be placed around the base of the hernia to prevent its adhering to the scalp. Over the whole should be placed again the gutta-percha and the ring of cotton. It is of great importance to emphasize the keeping of pressure off the hernia, as so many surgeons persist in trying to force the mass back by the use of tight bandaging. A hernia is a mechanical development, due to the increased cerebral tension caused by infection and œdema. It must come out, as there is no room for it inside, and therefore any attempt to force it back is not only fruitless, but is actually an hindrance to the natural healing process already at work.

If the patient does not succumb to encephalitis or ventriculitis in this active stage of a fungus, after several days the latter will begin to show some signs of cleaning up, and eventually granulations will appear over its entire surface. The gutta-percha and ring of cotton should be continued until the entire hernia has subsided to the level of the scalp (Figs. 310, 311). This may occur at any time from a week

FIG. 310. PHOTOGRAPH OF A HERNIA THREE WEEKS AFTER OPERATION.

to a month or six weeks after operation. In the later stages, sitting up in bed often hastens the recession. In the active stages of the hernia, repeated lumbar puncture is probably of benefit, as it temporarily reduces the intracranial tension, and at the same time possibly gets rid of toxic products.

Prognosis. Under some of the group headings, mention has been made of the expectancy of life after certain types of cranial wounds, but a few brief general statistics should be added.

During the first two years of the great war, 1914-1916, statistical surveys of series of wounds of the skull and brain showed a mortality

verging on or exceeding 60 per cent. (Abadie, for 102 cases with opened dura, 56 per cent mortality; Cuneo estimated 60 per cent mortality; Lapointe, 58.75 per cent for all cranial injuries treated at a forward hospital; Sencert, 63.5 per cent for a series at the front, including 24 deaths occurring after evacuation.)

FIG. 311. PHOTOGRAPH OF THE SAME PATIENT THREE WEEKS LATER.

Cushing([8]), working at a British casualty clearing station in 1917, records a very distinct improvement in mortality for cases with penetration of the dura. The first 44 cases of this sort in his series showed a death rate of 54.5 per cent; in the second 44, this was lessened to 40.9 per cent, and of the third 45 cases, only 28.8 per cent succumbed. Thus the average for the three series was 41.4 per cent of deaths. For cases without dural penetration, but with skull fractured, he gives a 9.2 per cent mortality.

Adie and Wagstaffe ([1]), in 1918, say in their summary that "mor-

tality is approximately 50 per cent for cases with penetration of the dura."

In a recent series at a British hospital in Boulogne, the writer([10]) had 132 cases of cranial fracture with a mortality of 36.3 per cent; of this number, 101 had dural penetrations with a 46.5 per cent mortality. This series represents cases operated upon from twenty-four to seventy-two hours after injury.

It is extremely difficult, and often misleading to make any general statement from a review of statistics. However, one is probably justified, from the surgical experiences of the recent war, in saying that the mortality in cerebral gunshot wounds has been reduced from approximately 60 per cent to a point close to 40 per cent, and in some instances perhaps to even less than this figure.

BIBLIOGRAPHY

1. Adie and Wagstaffe. Medical Research Committee, 1918, Statistical Report No. 1.
2. Cushing, H. Brit. M. J., 1918, i, 221.
3. Cushing, H. Brit. J. Surg., 1918, v, 558.
4. Gray, H. M. W. Brit. M. J., 1916, i, 261.
5. Holmes, G. and Sargent, P. Brit. M. J., 1915, ii, 493.
6. De Martel, T. Wounds of the Skull and Brain. London, 1918.
7. Roberts, J. E. H. Brit. M. J., 1915, ii, 498.
8. Sargent, P. and Holmes, G. Jour. R. A. M. C., 1916, xxvii, 300.
9. Tabuteau, G. G. Brit. M. J., 1915, ii, 501.
10. Horrax, G. Brit. J. Surg., 1919, vii, 10.

CHAPTER II

PLASTIC REPAIR OF WOUNDS OF THE FACE AND JAWS

THE first consideration in the treatment of serious injuries of the face and jaws is the preservation of life; the second, repair of the damage. The earlier proper treatment is instituted the lower will be the death rate, the better the ultimate result, and the shorter the time of recovery.

Both the character of battle wounds and the circumstances of their treatment necessitate that they pass through the hands of the general surgeon, but the earlier the dental surgeon is associated in the work the better, for it is the latter who will ultimately carry the major part of the burden in the greater number of the cases. Suitable special equipment that meets the requirements of the work is second in importance only to personnel.

Death following a wound of the face or neck without cranial or other complications is due to obstruction of the upper air passages resulting in immediate suffocation, in exhaustion, or in aspiration of blood and mucus; to hæmorrhage; or to sepsis, either local or pulmonary. Primary shock is rarely a factor; secondary hæmorrhage is always due to sepsis; pulmonary infections follow aspiration.

The factors that delay and complicate repair are sepsis and the displacement of tissue. Displacement results, first, from gravity and muscle pull, and, later, from infiltration and scar tissue formation. In but few cases is the amount of tissue actually destroyed by the missile the dominant factor.

Effective treatment should be instituted in the early hours after injury, before exhaustion has occurred and before induration and sepsis have developed. These conditions in war treatment are dependent upon the interruptions incident to evacuation. In proportion to the effectiveness of transport will the problems at the base and reconstruction hospitals be simplified.

The treatment may be divided into three stages for descriptive purposes: The stage of early treatment, extending over the first ten or twelve days after injury; the stage of later treatment, when the acute symptoms have subsided, and permanent deformities have not yet occurred; and the stage of reconstructive treatment. This division, however, is purely arbitrary and the individual procedures will vary greatly in the time and order of their application.

EARLY TREATMENT

Care of the vital forces. Dyspnœa may be caused by a fracture of the lower jaw that allows the tongue to press back on the glottis; by closure of the oral pharynx due to valve-forming wounds of the tongue, soft palate, or pharyngeal wall; by direct wounds of the larynx or trachea; or by hæmorrhage into the pharynx.

The simplest and most universally applicable treatment of dyspnœa is to place the wounded man in the sitting posture until the cause can be removed; many who can maintain respiration as long as they are erect will immediately succumb on lying supine. If the patient must lie down he should be placed semi-prone with the face inclined downward. Direct traction or drawing forward a shattered lower jaw will keep the tongue from falling backward. A half-inch rubber tube, or a Connel airway passed through the mouth well into the oral pharynx, or possibly one or two well placed sutures will relieve pharyngeal obstruction. Aspiration of blood is prevented by posture and by control of hæmorrhage.

Tracheotomy is rarely required except for tracheal or laryngeal wounds and for œdema of the glottis, but in hurried evacuations it is indicated in cases of doubt.

In case of hæmorrhage the bleeding vessel should be tied when possible, even if this necessitates enlarging the wound. Wounds of the upper jaw lend themselves to packing, while those of the anterior part of the tongue, the floor of the mouth, cheeks, and lips may be sutured directly or over a pack. After tracheotomy the whole pharynx may be packed, but before doing this a feeding catheter or small tube should be passed into the œsophagus through the nose and properly fixed.

Ligation of the common carotid artery should be the operation of last resort, both on account of the possibility of brain ischæmia, and because the recurrent circulation may defeat its object. Ligation of the external carotid is little better, except under ideal conditions, on account of the danger of secondary hæmorrhage from this vessel. If a ligation must be made at a distance it is better to choose the branches of the carotid, as far from their origin as possible; and if the asepsis is not ideal it is better to pack or at least drain the ligation wound as a preventative of secondary hæmorrhage.

Secondary hæmorrhage is always due to sepsis, and the means adopted for its control should include the treatment of sepsis. The wound should be cleaned out; foreign bodies, dead bone, and sloughs removed, and proper drainage instituted. If possible the bleeding vessel should be identified. Ligature of the vessel at the site of bleeding is usually difficult

since the tissues are indurated and friable; ligation of the vessel at a proximal point is usually the safest plan. Ligature *en masse* by passing a curved needle through the tissues may be practicable, but either of these are but temporary expedients if the sepsis is not controlled. In bone cavities and in deep wounds where the bleeding is from a medium-sized vessel, packing may, if necessary, be sutured into the wound to maintain tension. Since tight packing may further infection it should not be left in place more than twenty-four hours even if bleeding recurs while changing it.

Secondary hæmorrhage from the carotid may not be immediately fatal, but will recur in twenty-four or forty-eight hours and continue to do so until death occurs or the common carotid is ligated. Even after ligation bleeding may continue from the recurrent circulation, but there is a fair possibility of controlling the latter with packing or by ligation of the distal vessels in the wound.

Before ligating the common carotid artery a definite diagnosis of the source of bleeding should be made. The safest procedure is to enlarge the wound and find the bleeding vessel. This cannot always be done since wounds internal to the ramus of the jaw are inaccessible. Intermittent pressure of the common carotid against the carotid tubercle may give valuable information as to the source of the hæmorrhage. With a wound traversing the base of the skull in an anteroposterior direction either the carotid or the vertebral artery may be the vessel injured. If it can be determined that the carotid artery is the source of secondary hæmorrhage ligation should be performed immediately, without waiting for further bleeding.

Saline hypodermoclysis or blood transfusion may be indicated and provision should be made for the giving of fluids. After a free airway is provided morphine is usually beneficial, as it not only controls pain but prevents exhaustion and helps to control bleeding.

Removal of foreign bodies. Foreign bodies such as bits of shell, bullets, totally detached pieces of bone, teeth, and gold crowns, if of sufficient size to make it practicable, should usually be removed at once; when buried in the body of the sphenoid, the ethmoid, the posterior part of the orbit, or the pterygoid fossa it may be better to postpone their removal until later. Some foreign bodies are very small; the inaccessibility of others often necessitates special skill and equipment for their safe removal. If drainage is maintained they are not apt to do harm except that a persistent fistula may be formed.

When the foreign body cannot be removed through the entrance wound it should be approached by the most accessible route, with due regard for the motor nerves and salivary ducts.

Treatment of bone injuries. Every remaining piece of bone should be immediately restored as nearly as possible to its normal position, but in doing so the contour of the bone or segment as a whole is of more importance than the position of the individual fragments. One should not remove any attached bone, nor be too diligent about removing detached fragments that lie within the normal contour. Fixation should be adequate and comfortable. Immediate and sufficient dependent drainage should be provided for every open fracture.

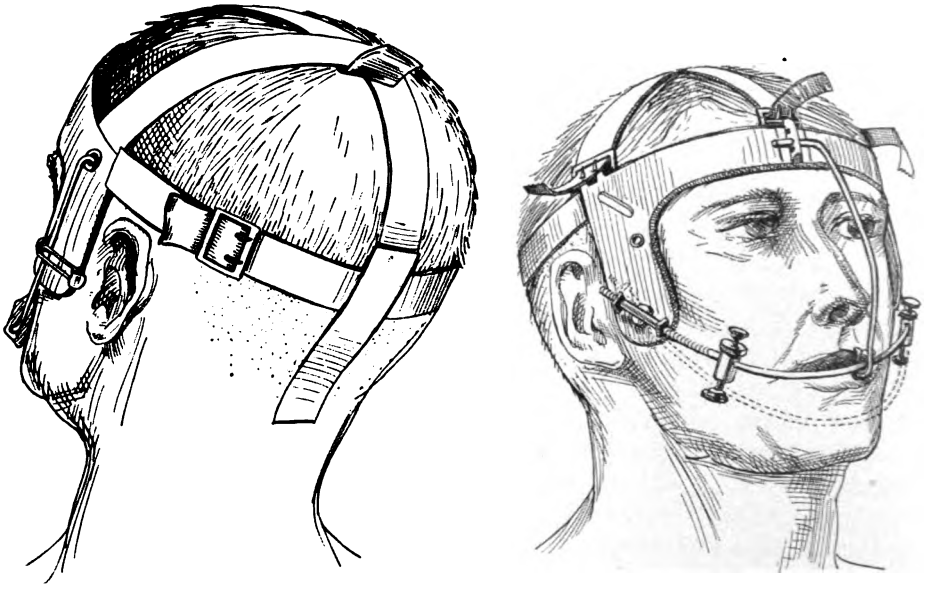

FIG. 312. APPARATUS FOR IMMOBILIZING INTRAORAL SPLINTS, NASAL SPLINTS, OR FACIAL SUPPORTS. (*Kazanjian.*)

Fractures of the bones of the face demand much more accurate adjustment than any other part; fortunately, the teeth or the alveolar process afford anchorage that admits of accurate restoration. This method of fixation is applicable not only for the jaws but for the nose as well. Fixation appliances may also be attached to a head band, either used alone or as an adjunct to dental splints (Fig. 312).

Fractures of the body of the jaw are practically always open; in war wounds this is also true of fractures of the rami and processes. Displacement results chiefly from muscular pull, though the original violence may play a part. Except in cases with extensive loss of muscle the gen-

eral direction of displacements of the body fragments is downward and toward the midline; that of the ramus and condyle forward; and that of the coronoid process upward.

All fragments of the body of the bone should be assembled in their proper position and held by intermaxillary wiring or by temporary splints, rather than by direct bone wiring. Spaces resulting from loss of bone should be maintained, as it is probable that some periosteum and spicules have remained which, if properly cared for, will fill the defect by the production of new bone. At the angle it is permissible to allow the ramus to come forward to fill a defect, but anteriorly the space must be left to be filled by bone regeneration or bone graft.

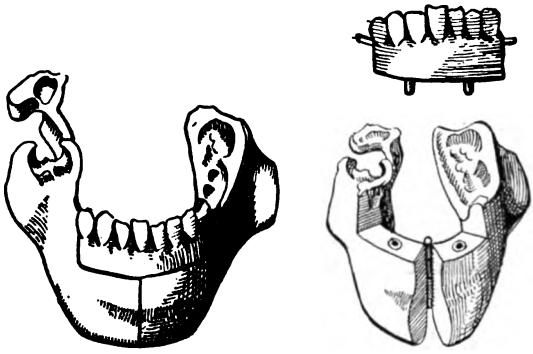

FIG. 313. PROSTHESIS FOR REPLACING A LOSS OF BONE IN THE LOWER JAW. (*Kazanjian.*)

Two plans have been devised for maintaining the position of the ramus where there is comminution or loss of substance at the angle, but neither have proved universally satisfactory. One plan is to press the ramus back by means of an intra-oral appliance attached to a dental splint; the anterior border of the fractured end is engaged by a saddle of vulcanite or metal, or a metal pin is passed through the soft tissues and engaged in a shallow hole in the bone. For pressure on the anterior border of the ramus the pin does less damage. The other plan, proposed by Pickerel, consists in restoring the ramus to its position and fixing it by passing a screw through the soft tissues and the zygoma to engage the coronoid process.

Comminuted fractures above the lower limit of the mandibular attachment of the masseter and internal pterygoid muscles present some peculiar functional problems for the oral surgeon. If there is sufficient separation of the fragments on opening the mouth the chin will deviate

toward the affected side. For fractures of the ramus it has been our common practice to fix the jaws together with the teeth in occlusion, but for fractures through the neck of the condyle better relation of the fragments is usually obtained by fixing the jaw well open, with the body held in the normal plane. If, however, there is a fracture-dislocation of the condyle the more practicable plan is to fix the jaws in occlusion and to free the joint later if necessary. Coronoid fractures may in themselves be disregarded. George Villain, of Paris, has included all the fractures through or above the masseter attachment under the term "postelevator fractures," and treats them by ingenious appliances that allow free function from the beginning and at the same time control the position of the distal fragments.

Displaced body fragments that do not contain firm teeth may be drawn into place by a circumferential wire passed completely around the fragment, the body of the bone, and the splint. The ends of the wire are twisted together over the splint and inferior drainage is then provided to the wire. With bad comminution, parts of the inner plate of the body are apt to be drawn toward the body of the hyoid and it is particularly important that these be restored to their proper position by circumferential wiring. Only displaced and absolutely loose teeth should be removed at this time. In the emergency, if the body of the bone is restored to position, the fracture of the ramus and its processes may also be disregarded.

Drainage is instituted by incisions underneath and parallel to the body extending into the fracture line, usually with a small tube or rubber dam sutured in place.

Displacements of the upper jaw are due to the force of the original injury and to gravity. All fragments, including those of the palate, should be replaced; this process may be facilitated by passing a strong sharp hook into the tissues and engaging the fragments. Except in extensive fractures, there is little tendency to recurrent displacement. The fractured dental arch is anchored by intermaxillary wiring or a splint. Transverse fractures of the face through or just below the orbit require support if there is displacement. This is furnished by the reversed Kingsley splint or other supports attached to a head-band, or by a chin bandage applied in conjunction with an open bite splint. With much comminution, simple upward pressure may overcorrect the displacement. A simple chin bandage without an open bite splint should not be used, as swelling may block both oral and nasal respiration.

The displacements associated with nasal fractures fall into two general classes, lateral and backward; and these may be complicated by the loss of any amount of bone, cartilage, or soft parts.

All the impactions should be released with a hook or small chisel,

the remaining tissues should be restored to their normal position and immediately supported by splints or pads attached to a head-band or the upper dental arch. Where it is applicable the latter is preferable.

Displacements of the zygoma, antral wall, and orbit are caused by direct force, except for the downward displacements of the zygoma due to traction of the masseter muscle. Impactions should be released and the fragments restored to position, if necessary, by circumferential or direct bone suture.

Repair of the soft tissues. Except to obtain a clean surface for immediate suture, no *débridement* of the soft tissues of the face should ever be done, and then only the hopelessly damaged tissues should be removed.

The floor of the mouth, the submaxillary, and submental regions are particularly vulnerable to serious indurating infections, while the face itself may be sutured with impunity as far as danger to life is concerned.

Billroth pointed out long ago that one should never perform a primary suture of the floor of the mouth, or of a submaxillary wound that communicates with the mouth, if it can be avoided, on account of the danger of secondary hæmorrhage and indurating infections. In military surgery, however, the exigencies of the situation often demand suture repair. If free inferior drainage is provided, it may be practicable to unite the mucous and submucous tissues and leave the remaining parts packed from the skin surface. The central, submental part of the wound is more apt to demand suture than the lateral on account of the necessity of breathing and swallowing; fortunately, this is the least vulnerable part. As one approaches the carotids, the danger from closing an infected submaxillary wound increases.

Packing the floor of the mouth is efficiently done with iodoform gauze saturated with balsam of Peru; applied to a fresh raw surface where there is no comminuted bone the packing will often remain clean for a week, and form a water-tight union with the tissues that will prevent fluids from leaking into the wound. The Mikulicz form of pack is often desirable.

Above the border of the lower jaw the soft tissues may in appropriate instances be closed to advantage, but good surgical judgment must be exercised. The angle of the mouth, the ala of the nose, the ear, the eyelid, and the lip should be immediately repaired whenever practicable. Healing is more apt to occur here than in other parts of the face. Flaps of the cheek, lips, chin, ala of the nose, eyelid, and ear that have lost part of their attachment, retract rapidly unless sutured. Restoration later is always more difficult. Beyond this, unless the conditions are very favorable, an effort to lessen the extent of the defect is apt to produce better results than immediate complete closure.

Every wound that extends to the bone should be drained in its deep part if it is sutured. With wounds that extend to the mandible this may be done advantageously through a counter incision at the lower border of the jaw; those involving the upper jaw may be drained through an incision into the mouth.

If there is extensive damage and devitalization of the deeper tissues, especially about the upper jaw, primary union in superimposed wounds is apt to fail unless very efficient drainage, supplemented by frequent cleansing irrigation of the damaged area, is maintained. Suturing over shattered bone that has lost its periosteum is seldom successful and apt to do harm if very careful after-treatment cannot be given. Where direct approximation cannot be made, direct suturing of the skin to the mucosa to cover the raw edge will save considerable scar formation.

Evacuation. This is controlled by military necessity so that the type of primary treatment must be modified according to circumstances. Usually a certain proportion of beds in advanced hospitals are reserved for nontransportable cases. In the American army certain maxillofacial cases were designated as nontransportables. Besides those whose general condition required continuous care all recently sutured wounds except simple wounds of the cheek and lips were, where possible, held until safe union of the soft tissues had occurred.

Patients should not be evacuated with the jaws wired together unless there is a free opening to allow for vomiting and swelling, and unless the wires are so applied that they may be easily released in an emergency. No patient should be evacuated until a free airway is assured and provisions made for the taking of fluids. If there is an opening in the floor of the mouth, or if for any reason the patient cannot swallow, a No. 18 catheter can be passed through the nose into the upper part of the œsophagus and fastened to the upper lip with a piece of adhesive tape. If fluids regurgitate through the catheter this can usually be corrected by withdrawing it a few inches. If there is regurgitation around the catheter into the mouth it means that the tube should be placed deeper into the œsophagus.

Anæsthesia. If one has the time, skill, and equipment, there are few injuries about the mouth and face that require a general anæsthetic. With gentle manipulation, nerve blocking, and infiltration with a local anæsthetic all but the extreme impactions can be replaced and the proper repair made.

Where available, novocaine in physiological salt solution, with 6 minims of 1:1000 adrenalin chloride solution per ounce, is the local anæsthetic solution of preference. A 2 per cent solution of novocaine may be used for nerve blocking and bone infiltration, and a ¼ or ½ per cent

solution for infiltrating the soft tissues. In quiet sectors this plan is advantageous if the proper ether apparatus is not on hand, but with multiple wounds and in times of stress time-consuming measures are impracticable. Under such conditions ether is preferable for any but minor injuries.

The chief danger of a general anæsthetic in a mouth wound is from the aspiration of blood and mucus. By providing a free airway, by lowering the head over the end of the table so that the blood will drain away from the pharynx, and by sponging the pharynx carefully, ether can be given with safety, The much preferred method of administration is the intratracheal method, for it is difficult to keep these patients anæsthetized with ether on an open mask, though it is easier with chloroform. For injuries of the anterior part of the mouth the intrapharyngeal method with the aid of nasal tubes may be useful.

LATER TREATMENT

Sepsis and the subsequent formation of scar tissue are the factors that are responsible for almost all the delays in recovery, therefore the effort to control sepsis should begin at the very outset and should never cease until recovery is complete. While the tissues of the mouth are definitely exposed to infection they possess a high resistance and this resistance can always be conserved, not so much by antiseptics as by surgical procedures. The response to good and to poor surgery about the mouth is as great as that of an injured gut. The ideal preventative of infection is protection by immediate closure, as outlined under "Early Treatment," with subsequent rest of the part and of the patient. When infection has occurred the most important consideration is drainage. This may be accomplished by incisions, simple irrigation, or packing in appropriate places, and the elimination of crusts that harbor organisms. Antiseptics fill only a minor part; Dakin's solution is not well tolerated; antiseptic washes, tincture of iodine, the milder silver salts, dichloramine-T, and antiseptic packing, all have a very distinct use, but the mode of application is of more importance than the selection of the antiseptic.

Acute spreading infections will rarely occur if proper treatment has been given; if they do occur they are to be treated by attention to the original focus, the application of ice or heat and the drainage of pus when it forms.

Indurating infections of the floor of the mouth and submaxillary regions (Ludwig's angina) which are extending or which embarrass respiration, should be freely incised from the skin surface through all layers, including, if necessary, the mylohyoid muscle. Such an incision

will allow drainage from all the intermuscular planes and immediately release tension by allowing the tissues to roll outward. Though less extensive incisions are necessary for collections of pus within the floor of the mouth, the submaxillary approach is perferable for drainage in these cases also.

Wounds may become foul from sloughing tissue, from infection occurring before the patient reaches the hospital, or during subsequent transit. After the acute condition has subsided there should be neither pus nor odor about these cases. Sloughs should be trimmed and mild antiseptic packs applied; all pockets should be given dependent drainage or controlled by packs or irrigation. A pack of balsam of Peru and iodoform gauze, or irrigation with a 0.5 per cent solution of formaldehyde will rapidly destroy all odors.

Foreign bodies, including exposed tooth roots and devitalized bone, should be removed as early as practicable; the tooth may for a time be considered essential to the splinting, and devitalized bone may be attached to a live section so that it is necessary to await natural exfoliation for its removal.

Delayed union of fractures. As outlined above, all fragments should be immediately restored to and maintained in their proper position. Only acute spreading infections should delay this procedure. Fixation tends in itself to control sepsis. If restoration has been delayed until the bones have become somewhat fixed in their abnormal positions, it is often better to use appliances that draw the fragments gradually into place during a period of several weeks. This causes less disturbance to the patient and tissues and is more apt to be followed by bony union than when the bone-forming tissues are immediately torn asunder.

The delayed union that so frequently follows comminuted fractures, especially of the lower jaw, is due mostly to the low-grade sepsis that is kept up by fragments of dead bone or exposed tooth roots. As soon as they are no longer essential for fixation, all teeth, the apices of which are in the fracture line, should be removed. Later, if without any other apparent cause the union still remains weak or springy long after firm consolidation should be expected, the removal of teeth in the neighborhood of the fracture should be considered, even though no direct connection can be demonstrated and the teeth be vital. It has been frequently observed under these circumstances that the roots of teeth are "worm eaten," and that firm union quickly follows their removal. It is certain that a focus of infection which may be very difficult of demonstration, can indefinitely delay union in either jaw.

Cleaning up an infected fracture may be expedited by removing all

detached bone even six or eight weeks after the injury. In the lower jaw, especially if there is an external fistula or scar, this is best accomplished by an incision along the border. In approaching the bone it should be determined on which surface regeneration of the bone is proceeding more rapidly, so that the cavity may be invaded from the other table. The cavity should be exposed by rongeur or bone-biting forceps. Spicules still attached should not be disturbed, and the granulations in which the dead pieces rest should not be scraped down to the bone from which they grow, though the exuberant masses may be trimmed with the curette. Under no circumstances should the newly forming bone of both tables be cut through at the same site. Blind curetting through a small opening is rarely effective at this stage and may do much harm. After all denuded bone has been removed, if by further removal of the scar and part of one table the cavity can be so arranged that the soft tissues will fill the dead space, then the external scar can be excised and the wound sutured with a small drainage tube in place. After an interval of three months or so, the fragments can be removed by engaging them with a curette inserted into the fracture line from the mouth.

Syphilis may be the cause of delayed union.

Isolated reports have been made of cases of nonunion that have quickly consolidated when properly splinted. Our own observation leads us to believe that removal of the splint when there is still some elasticity in the union does not delay consolidation but rather hastens it. If within a month after removal of the splint union has not progressed satisfactorily, we seek some other cause for the delay before again restoring the fixation. Removal of the splint is a much more reliable way of determining the quality of the union than the X-ray. From three to six months or even longer may be required for union of the body of the lower jaw where there has been much comminution and loss of bone.

Delayed suture. This procedure may be considered in any case where the tissues to be united are free from active infection or induration, and are not in direct contact with an infected pocket or an infected fracture line. Even a mildly infected fracture line is not necessarily a contraindication, as a piece of soft rubber dam may be placed between the bone and the soft tissues so as to furnish dependent drainage away from the suture line. Delayed suture is most applicable for wounds of the cheeks, chin, and lips.

With proper conditions, extensive repairs can be made shortly after injury. At the time of injury there may have been too much bruising and laceration to permit immediate repair, or surface infection may have already occurred. Careful after-treatment may clear this up within from one to three weeks, leaving a healthy granulating surface with only a thin,

indurated layer at the base. If the conditions outlined above are right, the granulations with their indurated base may be cleanly excised and the tissues sutured. This must be done without any tension, as these tissues do not tolerate sutures as do normal tissues. When necessary, undermining of the flaps may be done. If after a few days it is seen that there is a tendency for the sutures to cut through, the suture line may be supported by pasting closely woven gauze on either side, ¼ or ½ inch from the line; thin rubber bands are sutured to the borders of the gauze strips at ½-inch intervals and fastened across the suture line with proper tension. If the suture line is clean and dry, one thickness of gauze may be pasted directly over the wound.

Trismus. This has been applied as a general term to limited opening of the jaws after injury. It is only incidentally related to fracture and is the result of tender or granulating wounds; of reflex irritation dependent upon extramuscular infection; and most commonly of an infected wound or retained foreign body in the temporal, the masseter, or the internal pterygoid muscle.

Early treatment consists in the removal of the foreign body and proper care of the muscle wound. Free movement should be permitted as early as possible or the open bite splint should be used.

Later treatment similarly includes removal of the foreign body and proper care of the muscle wound. For slightly affected cases one may use intermittent dilatation; if this does not produce satisfactory results within a week, it is better to maintain increasing dilatation by covering each dental arch with a fitted splint and interposing wedges or jack screws between them. Dilatation is accomplished by separating the jaws as far as comfort will permit and, after maintaining this separation until all acute discomfort and reaction have subsided, again increasing the dilatation. This process is repeated every three or four days until the desired separation is obtained. It is usually rapidly successful but presupposes that the cause of reflex irritation has been removed. If complicated by a postelevator fracture, the relation of the two jaws to each other should duplicate the normal at every stage of the dilatation, and the relation of the fragments should be checked by X-ray examination.

Resisting scar bands, ankylosis, and other mechanical obstructions must be dealt with by accepted methods.

Traumatic fistulæ. These may be of three kinds. In the first there is an abnormal communication between two epithelial lined cavities, such as the antrum and mouth, or between an epithelial lined cavity and the external surface, in which the two epithelial surfaces become united either directly or by scar tissue formation. If the opening is large it is spoken of as a defect rather than as a fistula. A second type is one in

which there is a communication between the skin or an epithelial surface and a normal duct or cavity, the flow of the secretion from which keeps the opening patent. The parotid duct fistula is usually of this kind. A third, and the most common example, is one in which there is a track leading to a foreign body, to dead bone, to a tooth root, or to a poorly draining abscess. The latter type is usually called a fistula.

In the first instance, excision of the scar or mucous membrane lining the track, and suture of the raw surfaces without tension should produce healing. If the length of the track is considerably greater than its diameter, destruction of its walls with a fine bladed cautery will serve.

For fistulæ of the second type, it is necessary to control the secretion or furnish some other outlet for the fluid. Parotid duct fistulæ may be of the first type, and then the lining of the track must be destroyed in addition to furnishing an outlet for the saliva. With rare exceptions, however, the cases we encountered closed with such simple procedures as wiring the jaws together and applying pressure over the opening; as the wound granulated, the saliva was turned into the normal channel. In only two instances that I know of among our battle casualties was it necessary to do the classic operation of converting the external into an internal fistula. French surgeons frequently ligated the parotid duct to cause atrophy of the gland. Even excision of part or all of the gland may be necessary for cure of a gland fistula. For fistula of the lachrymal duct, the sac may be excised or a free opening into the nose provided.

The treatment of the third type is removal of the cause of irritation; until this is done the vent should not be closed. When the cause is removed the fistula closes spontaneously, and it is rarely necessary to remove the scar tissue lining the track except for cosmetic reasons. However, if there is a heavy ring of scar tissue and the cause of the irritation cannot be identified, the most certain plan is to make a free incision and dissect out all the scar; in doing this it is probable that the irritant, usually a foreign body or an abscess pocket in the scar itself, will be removed at the same time. This plan is useful in treating a fistula of the neck where X-ray examination shows a number of scattered foreign bodies, each too small to demand removal, and where the particular offender cannot be identified. By carefully following a fistula one may find an area of diseased bone or cartilage that can be completely removed. It is not always possible to follow a fistula with a probe. In operating upon one of unknown course, particularly in the neck, the incision should be so planned as to follow the tract in any direction it may run. With the aid of stereoscopic X-ray plates made after a bismuth injection, or with a staining solution injected just before operation it may be possible to follow a devious track with comparative ease.

RECONSTRUCTION

Reconstruction includes both the surgical repair of cases that have healed or are healing with defects, malposition, or impaired function, and the after-treatment which will lead to a restoration of function.

Bony defects and malpositions. Malpositions of the lower jaw should be corrected as far as possible. If the bony union is not firm, correction can be accomplished in appropriate cases by gradual force with threaded bars, elastic bands, or inclined planes attached to dental splints or a head-band. This plan may have the added advantage of avoiding a cutting operation. In cases in which there is an actual defect bony union will often follow gradual dilatation, whereas if the callus were cut out and the bones immediately spread, bone grafting would be necessary.

With a defect at the site of the second and third molars, it is permissible to allow the ramus to tilt forward until the defect is obliterated, but the body should not be allowed to move back to meet the ramus. The forward tilt of the ramus may be increased by removing the corresponding, now useless, upper molars and even the maxillary tubercle (Collier). With a defect of considerable size or extensive comminution, at or above the angle, it may be difficult to prevent the forward tilt of the ramus even when so desired. (See section on Early Treatment.)

True malunions, when sufficiently marked, require bone section and, when restoration necessitates it, bone grafting. In a few instances permanent prostheses are more practicable than bone grafts.

The same principles hold in the treatment of malpositions of the upper jaw—replacement by traction splints, and rarely by cutting the bone. The upper jaw does not lend itself to bone grafting, so that after the remaining parts are replaced, a prosthetic restoration is employed to fill the defect. Openings into the antrum or nose are either blocked by the prosthesis or closed by a plastic operation on the soft tissues.

Some observers of war injuries are of the opinion that transverse fractures of the face are not followed by bony union; this is not in accord with our civil or war experience. If such a failure of union had occurred, we had planned to place one or two bone splints as a truss across the weak line, but, so far as I know, the necessity for this did not occur.

For the simple filling out of defects, such as the borders of the orbit or the bridge of the nose, cartilage is preferable, but where real bony union is necessary, as in the lower jaw, bone is required. In either instance the perichondrium or the periosteum and endosteum must be preserved over as much of the graft as possible. The greatest danger to grafts is not failure of primary healing but subsequent absorption. A piece of car-

tilage with perichondrium over the greater part of its surface is very apt to resist absorption, but bone will always be absorbed unless there is firm osseous union, and unless it is subjected to functional strain. Under these circumstances it may even increase in bulk and density.

The grafts should be living and autogenous. Much experimental evidence has been adduced as to the utility of preserved, heterogeneous and even cooked tissues, but until these points are settled beyond cavil, it is better to accept the known surgical facts. Whether the successful graft itself ultimately remains in place, or is replaced, is not the important factor either to the surgeon or to the patient.

There are other general rules, the observance of which further success. A pattern of the desired graft of lead or vulcanite, as nearly exact as possible, should be prepared beforehand and available at the operation. Neither the free graft nor the bed prepared for it should be touched by even the gloved finger. The graft should be manipulated by forceps with long teeth that will not strip its covering nor allow it to slip. The graft should not touch the skin while being placed in position. It should be fixed in its bed and the bleeding controlled, but the fewer sutures that come in contact with the graft the better; bleeding may be checked by first preparing the bed and pressing the sides firmly together while the graft is being cut; at the same time the pattern can be fitted into the bed, and any discrepancies may be noted.

Under no circumstances should blood clot or serum be allowed to collect in the wound. There is considerable prejudice against drainage of these wounds but, when carefully done, I believe it a good practice. The drain should not come in contact with the graft and should be removed in twenty-four hours.

The immediate object to be attained in placing a bone graft in the lower jaw is to get firm contact of uncovered bone, to have the graft remain in place, and to accomplish this without infection. If the graft can be wedged in place and held by suturing the superimposed tissues, this is ideal; but fancy, mortising operations have inherent dangers of infection and give the largest proportion of failures. The partially overlapping rib graft is a practical compromise. Drilling and wiring the bone is the common and most practical procedure. Wire always causes some absorption of the graft, but I am not sure that kangaroo tendon has any real advantages over wire.

The tissue into which a graft is placed should be completely healed and free from infection. The rule of the British in their war work was to wait six months after the original wound had healed, but we have operated upon selected cases after three months. The graft should be embedded in normal, not in scar tissue, therefore it may be necessary to

do a preliminary plastic operation and allow the wound to heal again before grafting. If possible, the suture line should not be directly over the graft.

The desired graft may be obtained from the costal cartilages, the ribs, the crest of the tibia, or the crest of the ilium—whichever is best adapted to give the shape of graft required in the individual case. The bone to which the graft is to be united should be fixed and remain so until the graft unites. In the lower jaw this requires a previously applied splint.

In the face direct bone grafting is most applicable for defects through the full thickness of the body of the lower jaw. The indications are a defect through the full thickness of the body or through the body and angle, where X-ray examination shows absence of bone-forming effort after several months, or that the bones are becoming rounded off. While the operation should not be performed before the necessity is certain nor before it is probable that the scar is free from septic germs, when these conditions are assured, the sooner the operation is done the better.

When possible the incision is made from ¾ to 1 inch below the border of the body, so as not to leave the suture line over the graft. It should be curved and sufficiently long, the ends approaching the jaw. The superficial flap of skin and platysma is dissected up until the bone is well exposed, but the periosteum should not be separated from the bone. If the mouth be accidentally opened the operation should be discontinued.

Indirect bone or cartilage grafting is applicable for defects of the jaw bones, the borders of the orbit, and particularly of the nose. It is especially indicated when there is not only a defect of the bone but of the overlying tissues as well, and when it is desired to correct both at one operation. For the nose and orbital borders cartilage is best; for the jaw, bone is necessary and rib is usually most suitable. The flap for the plastic operation is outlined, and the graft is buried in it in such a position that when the flap is swung into place the graft will take its proper position. In the forehead, for a nasal or orbital defect, the graft is buried between the subcutaneous tissue and the aponeurosis. For a defect in the lower jaw, bone is placed between the skin and the platysma, after the bone has been drilled for future wiring.

The manner of implanting the graft is as follows: an incision large enough to admit the graft easily is made through the skin and subcutaneous fascia at one end of the space in which the graft will lie; then with a pair of small Mayo dissecting scissors a tunnel is clipped at the proper level of sufficient width and length; the point of the scissors felt under the skin serves as the control. Scissors are more accurate then blunt dissection and the graft is more easily introduced after their use. The

direction of the skin incision should be such as not to interfere with the nourishment of the flap when the latter is cut and raised from its present bed. External pressure is applied until bleeding ceases. The borders of the wound are held apart by retractors or nasal forceps so that the graft does not come in contact with the skin while being inserted. A long-bladed nasal speculum inserted deeply into the tunnel will often greatly facilitate the introduction of the graft. After ascertaining that there is no hæmorrhage, the incision is closed with interrupted sutures that do not touch the graft. If there is slight bleeding, a drain may be left between the sutures for twenty-four hours. Cartilage so implanted may be left indefinitely before the flap is turned, but this is usually done at the end of three weeks. If the graft is of bone, the latter should be transferred to its ultimate position within two or three weeks, as bone and its periosteum are rapidly absorbed if not functionating and in contact with other bone.

The osteoperiosteal grafts became very popular with the French during the war. They illustrate the transplantation, not of bone, but of bone-forming tissue, with the expectation that bone will be produced. The indications for such grafts are the same as for free, direct bone grafts but they are not applicable for long defects.

The manner of preparing the bed is the same as that described above, except that the lingual, as well as the outer surface of the jaw bone, is exposed. The graft itself consists of periosteum and a layer of subperiosteal bone-forming cells that are obtained from the inner surface of the tibia. The periosteal flap is outlined with the knife on the inner surface of the bone and raised with a sharp flat chisel, so that minute particles of bone are raised with periosteum. Sibelu, whom I first saw do this operation, used two such grafts about ¾ inch wide and 1½ inches longer than the defect after the bone was trimmed. One was placed on the inner surface of the bone across the defect, the other on the outer surface, in such a manner that the osteal cell surfaces lay toward each other. The grafts were held in place with a few sutures. In about six months, or in even a shorter time, there is usually a firm bone formation.

If a pedicled bone graft is used the graft is taken from some neighboring structure such as the clavicle or the lower jaw, usually the latter, and transplanted with a pedicle of soft tissue to carry the blood supply to the bone. With an assured blood supply a mild infection is not so apt to cause failure as in the free graft.

Besides the indirect graft, which in the second stage is essentially a pedicled graft, there are three types of pedicled graft applicable to the lower jaw.

Transplantation of a section of the lower border of the body of the

jaw into the defect was first practised by Percy Cole of London. The bed is prepared in the usual manner except that in the area from which the graft is to be taken the incision does not go through the platysma; the skin and subcutaneous fat only are raised in the flap. After preparing the bed and determining the size of the graft required, the skin and superficial fascia of the graft-giving area are dissected from the lower half of the body; then, starting at the defect, without having cut through the platysma, 1cm. of a sufficient length of the lower border is detached with a motor saw. After the bone is cut through, the platysma below the jaw

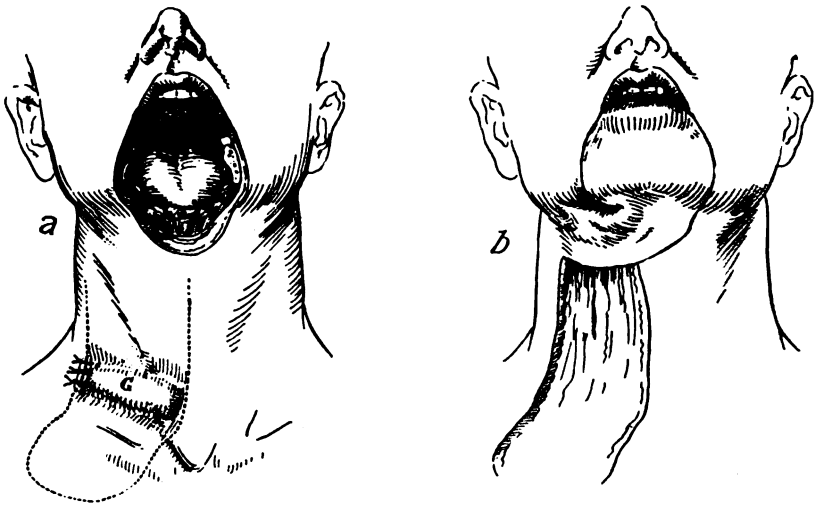

FIG. 314. INDIRECT BONE GRAFT FOR THE REPAIR OF A DEFECT OF THE SYMPHYSIS OF THE JAW AND CHIN.

is incised in the direction of its fibers so as to permit the graft to be shifted into its new position without detaching it from its muscular pedicle. At least a part of the digastric muscle, with the intervening cellular tissues, are included *en bloc* in the pedicle. If bone sutures or wires are used, the holes should be bored in the graft before it is separated. A graft about 4 cm. long can usually be obtained in this way.

A graft from the angle and lower part of the ramus is very useful in filling a defect in the molar or bicuspid region that is not more than 2 cm. in width, after the ramus has been tilted forward to the fullest extent. The defect is exposed in the usual manner, the bone ends are freshened over a broad flat area, and each is drilled 0.5 cm. from the freshened end and as far from the lower border as practicable. The graft, consisting

of the lower part of the ramus and the adjacent part of the body, is detached. A heavy silver wire is passed through the holes in the bone ends and the fragments are brought firmly together; the ends of the wires may be left protruding between the sutures, and, even if the wound communicates with the mouth, the result is not materially influenced, as it is really an open fracture. It may be that bands of scar tissue within the mouth will prevent the posterior fragment from moving forward; if so, these will have to be cut. In the first and second types of pedicled grafts described above, bony union of both cuts usually takes place in about twelve weeks. In the grafts described the skin is not included in the pedicle; in

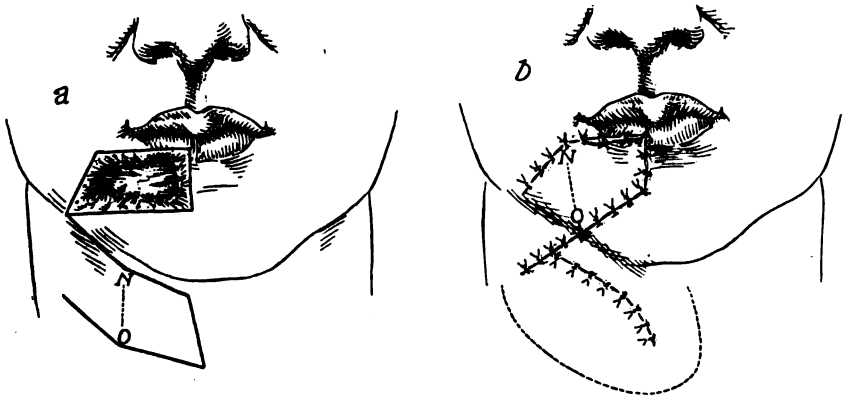

FIG. 315. PEDICLED FLAP FROM THE NECK FOR THE REPAIR OF THE SOFT TISSUES. The shape of flaps with short pedicles is considerably modified by the change in position.

the clavicle graft the skin and platysma are included (Fig. 314). For this reason the latter is best applicable to a defect in the lateral part of the body of the jaw where the soft tissues are missing. The soft tissue defect, bone and bed for the graft are prepared as for a plastic operation. The mucous defect in the mouth should be closed, as in these cases the mucosa will have been drawn toward the skin by scar tissue, and after this has been undermined, it will probably be found that there is enough for closure. If there is not, the mucous membrane defect should be closed by turning a skin flap into the mouth and postponing the grafting until healing of the defect has occurred.

The graft is obtained as follows: a skin flap is outlined over the clavicle that will carry enough bone to cover the bone defect, furnish enough skin to fill the soft tissue defect, and carry the graft in such a

position in the flap that when they are rotated into place both the bone and soft tissues will fall into position without tension. The skin incision goes through the platysma to the bone at the point where the cut crosses the clavicle. The part of the flap below the clavicle is dissected up to the lower part of the clavicle so as to include the tissues superficial to the pectoral muscle. With a circular motor-saw the clavicle is cut half way through at both places where the incision crosses the bone. The skin and platysma are then gently retracted and, without tearing the subplatysmal connective tissue, holes are drilled through the cortex of the bone at the ends of the proposed graft. The saw is then applied to the inferior

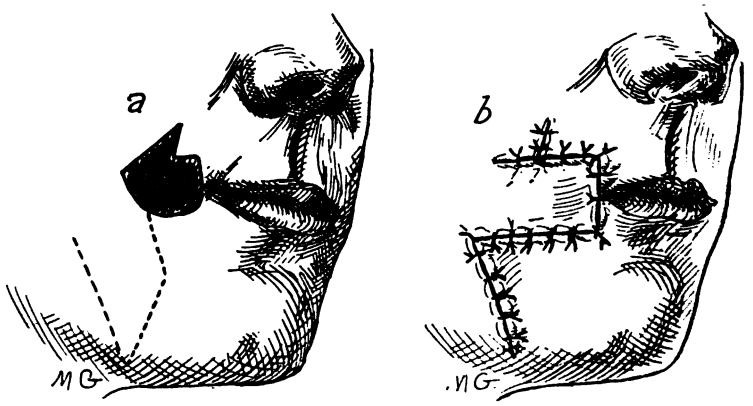

FIG. 316. PEDICLED FLAP FROM THE CHEEK FOR THE REPAIR OF THE SOFT TISSUES.

border of the bone between the transverse cuts, and the superficial half of the bone removed without detaching it from its pedicle. The graft and the flap are grasped by forceps and the remainder of the pedicle dissected up to the base. If part of the clavicular attachment of the sternocleidomastoid muscle is attached to the graft the muscle fibers should be cut at a little distance from the graft. If the defect in the mucosa has been closed at the same operation the wound should be swabbed with iodine. The graft is wired in place with the ends of the wire sticking out below for drainage, and the skin flap is sutured in place with dependent drainage. The subsequent treatment of the pedicle and the closure of the neck defect are described later.

Bone splints are useful to strengthen a weak union of the lower jaw or a transverse fracture of the face. After raising the periosteum a graft of the proper size and shape is placed across the weak line in immediate contact with the bone either by open incision or by tunneling.

Plastic operations for repair of the soft tissues. In the repair of soft tissue defects function as well as appearance should be considered.

Either a free transplant of fat or the full thickness of the skin may be grafted into a clean area. Thiersch grafts can be applied to relatively clean areas, and they may even replace the mucous membrane of the mouth or the eyelid. Aside from these instances, practically all grafting is done with flaps of tissue whose blood supply is undisturbed.

In making flaps it is usually necessary to free the tissues from the

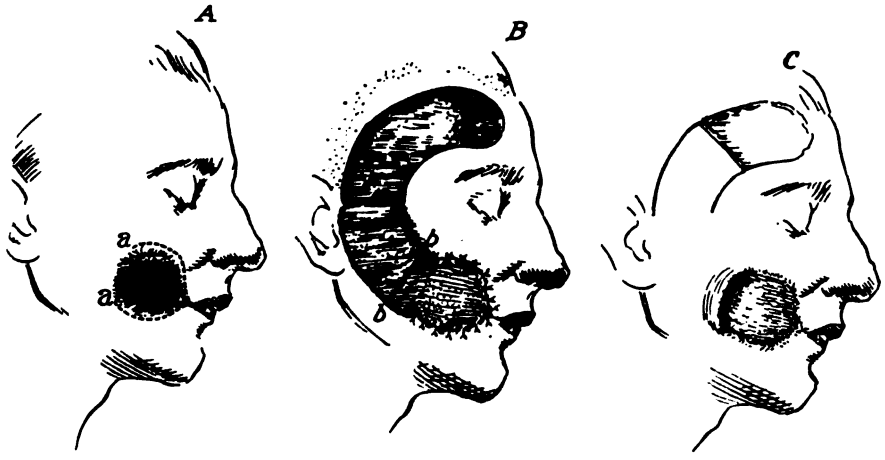

FIG. 317. PEDICLED FLAP FROM THE FOREHEAD FOR THE REPAIR OF THE SOFT TISSUES. The flap was sutured into the defect of the cheek with the skin surface inward; two weeks later the flap was cut and the skin of the cheek drawn together over the flap.

deeper structures by undermining the flap. The use of the gliding or sliding flap constitutes the simplest form of flap operation. A pedicled flap is one in which a mass of tissue is freed from its original site and left attached at one border only. This attached border may be much narrower than the greatest diameter of the flap.

Flaps for repair of the soft tissues of the face may be obtained from neighboring areas, as the neck, cheek, or forehead (Figs. 315, 316, 317), or from a distance, as the arm or hand, or by secondary transplantation from the abdomen, leg, or foot. As a general rule flaps should be obtained from the nearest available source, as there is apt to be more conformity in function and appearance.

The possibility of obtaining flaps to close defects depends chiefly on the redundancy and elasticity of the skin and subcutaneous tissues. Flaps should be of suitable tissue, and of such a size and shape as to avoid undue or irregularly distributed tension. The blood supply must be sufficient, but nutrition depends both upon the inflow of blood and an uninterrupted venous return. Few flaps are lost on account of ischæmia, but venous stagnation must be constantly guarded against, as it is the

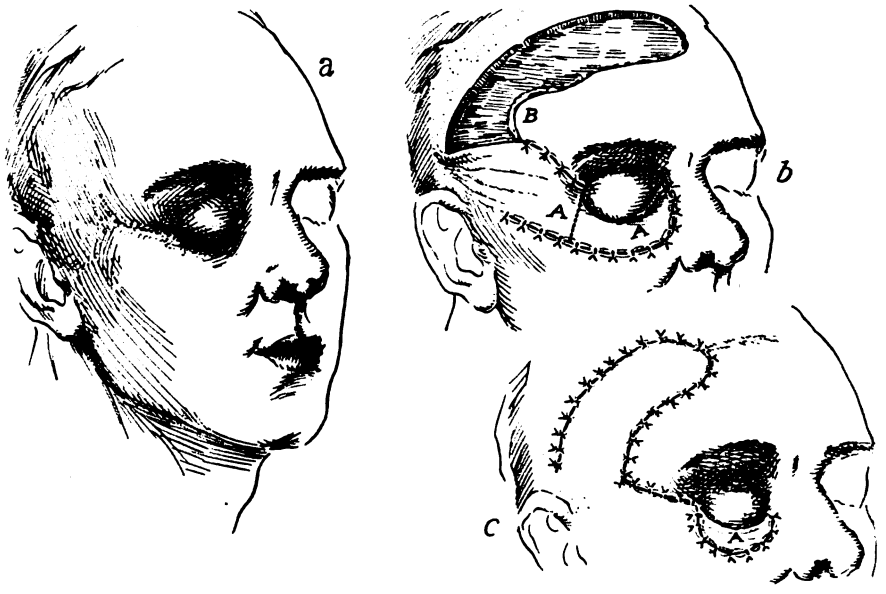

FIG. 318. PEDICLED FLAP FROM THE FOREHEAD FOR REPLACING A DEFECT OF THE ORBIT AND LOWER LID.

cause of most failures. Lymph stasis, caused rather by infection than by section of the lymphatics, is apt to interfere further with healing. If there is any doubt as to the vitality of a flap, it is best to suture it back in its original bed immediately and wait until the circulation is established. In turning very long flaps this may well be a routine procedure. In three or four days, if the wound is clean, the flap will be nearly as pliable as when first cut. If, after the flap is sutured in its new bed, it appears ischæmic, the application of moist heat, or the repeated use of a cupping glass (Gillies) tends to increase the blood supply; the close proximity of an electric globe is dangerous, as the flap has no sensation and may be burned. If it is bluish in color, a number of shallow cuts with a sharp

knife will relieve the congestion. This procedure may have to be repeated at intervals. The application of gauze saturated with a 2 per cent solution of sodium citrate will prolong the bleeding from one scarification for several hours. The necessity for depletion of a flap may be recognized 12 or 24 hours after operation, and the flap or the greater part of it still be saved.

In turning a flap with a narrow pedicle, the base should be placed so as to assure a good blood supply. If an artery and vein such as the

FIG. 319. FLAP FROM THE FOREHEAD WITH A PEDICLE OF SUBCUTANEOUS TISSUE CONTAINING THE TEMPORAL ARTERY AND VEIN. (*Horsley.*)

temporal or the angular can be included a large flap with a relatively small pedicle can be made with safety (Fig. 318). There are some conditions, probably associated with anomalies of the blood vessels, in which the flaps will slough regardless of the precautions taken. In one of my cases a short flap with a broad pedicle was totally lost through ischæmia, and later it was learned that the same thing had happened with this child in the hands of another surgeon. In another child two neck flaps sloughed at different times from venous stasis while still sutured in their original bed. A rare condition after a harelip operation in a baby is failure of wound healing without evidence of infection; Gilmer had one such experience and I another.

In cutting a flap the knife blade should be vertical to the surface. When the proper depth is reached, the flap should be dissected neatly and

evenly from the deep structures in a definite plane without hacking its under surface. The thickness of the flap may be determined by the depth of the defect, but it should contain enough tissue to insure its blood supply. On the face, ⅛ inch of subcutaneous tissue is enough for moderate sized flaps; large forehead flaps should include the aponeurosis or the tissues just superficial to it; large flaps from the neck should contain all the tissue superficial to the deep fascia, including the platysma

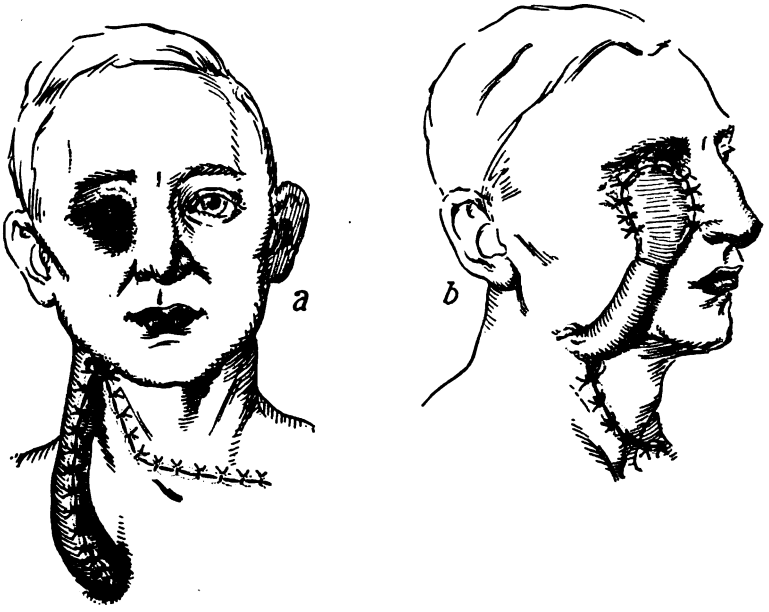

FIG. 320. TUBULAR FLAP FOR REPAIRING A DEFECT OF THE ORBIT AND LOWER LID. Subsequently the portion utilized was separated and the redundant portion sutured to its former bed.

where present. In mucous flaps the blood supply is so good that only the immediate submucous tissue need be included.

With a long flap, only the distal part of which is to be utilized to fill a defect, Gillies immediately sutures the skin edges of the pedicled part so that no raw surface is exposed. The pedicled part naturally assumes a tubular form, but immediate suture saves considerable scar formation.

Large flaps from the chest, scalp, or forehead may have a pedicle at each end as in the old hammock operation for ectropion of the eyelid. Gillies used a double pedicled flap from the chest to cover the whole face.

Esser uses a combined neck and check flap for areas above the oral

fissure (Fig. 321). The pedicle is narrow and contains the facial artery.

Hairless skin flaps may be substituted for mucosa and are usually very satisfactory; if too redundant, a warty thickening may develop and

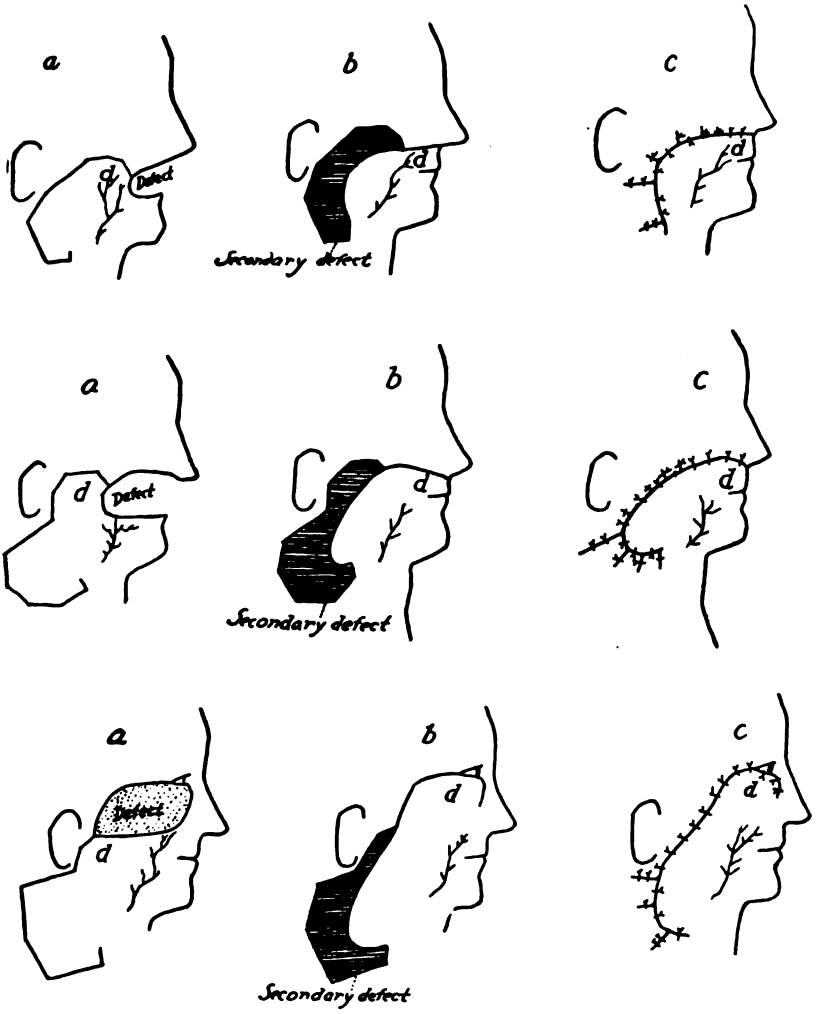

FIG. 321. ESSER'S PLAN OF OBTAINING A COMBINED NECK AND CHEEK FLAP FOR DEFECTS ABOVE THE ORAL FISSURE.

necessitate a partial excision of the flap. Hair will continue to grow when transplanted into the mouth; depilation of the skin can be done by the X-ray before transplanting it, but it is not always permanent.

The location and direction of the motor nerves should be considered in face operations.

There are parts of the face such as the forehead, the nose, the eyelids, and the lips where the amount of subcutaneous fat does not vary greatly in the individual under ordinary conditions of nutrition, but the amount of fat in flaps taken from the chest, arm, abdomen, and possibly the neck, may increase if the person becomes fleshy, causing subsequent embarrassment.

Before attempting to outline the flaps or scheme of operation, the size and exact nature of the defect should be determined. One should also determine how far the repair that has occurred is to be disturbed for it is sometimes difficult radically to improve the results of natural healing, particularly in the presence of extensive scar tissue formation.

With few exceptions, wounds and defects decrease considerably as they heal. This results not from the mass of scar tissue formed but from the tension of the scar upon the neighboring tissues. It may be that in this process, tissues that were widely separated by the injury are brought nearly to their normal positions, so that a large wound heals with but little distortion and requires relatively slight adjustment. On the other hand, where there is simply a tear through the tissues with little loss of substance originally, through this same scar contraction the tissues may become so distorted as to create a large defect. This latter condition frequently occurs following wounds through the full thickness of the lip, chin, and lower jaw, and also following wounds through the wall of the nose and eyelid. Where the loss of tissue is large, the neighboring structures are in most instances drawn into the defect, so that it becomes but a fraction of its former size, but with a deep cut of the face gravity and muscular pull may cause the cheek to sag so that the defect appears larger than it actually is.

Usually the best results follow the elimination of all scars, but when this is done the tissues retract to or near their natural positions, leaving a gap that is as large as it was at the time of injury.

The ability to visualize the size of the gap before excising the scar is essential for the performance of expeditious plastic surgery. This is done by estimating the distance that the neighboring tissues will have to retract to reach their natural positions, and by adding to this the area of the scar to be excised and the area of the defect present. For example, there may be a small opening into the antrum surrounded by scar tissue, and the entire area may not be a half inch in diameter, but the lid is drawn down, the corner of the mouth is elevated and the ala of the nose drawn outward; when the scar is excised and the tissue released the defect may be 1¼ inches wide.

The amount of distortion of the neighboring tissues is estimated by determining the location and relations of the component parts of the individual features. With a pencil, draw a diagram of the normal position of all distorted parts, including especially the alæ of the nose, the oral and palpebral fissures and their angles, the eyebrows, chin, and ears. Then study the individual features, for instance with reference to the nose: (a) Is the bridge flattened or laterally displaced? (b) Are the columella and alæ intact? (c) Are the openings abnormal as to size and shape, or is part of the floor of the nostril or its lining missing? (d) Is the septum deviated or is there other deep obstruction?

Within the mouth, besides the grosser lesions, one should search for obliteration or infringement upon the depth of the bucco- and labio-alveolar sulci. These are easily overlooked, but attention will instantly be called to them when the case reaches the dentist.

In the highly moulded features such as the nose, the chin, the ear, and even the lip where, from the size and shape and the presence of a scar, it is known that a part is missing, a fair estimate of the defect can be arrived at in the following manner: Make a plaster cast of the face, and by pressure of the fingers and an instrument mould a piece of medium weight tinfoil to conform to the nose or chin to be corrected; then on the plaster cast, have one skilled in modeling build up the damaged features with clay to the desirable configuration; next cut up the tinfoil form in the lines of the scar without altering the shape of the pieces, lay the pieces on the built-up clay features in their proper relative positions, and gently conform them to the model. The gaps remaining will indicate the size and shape of the actual defect.

With the ear and lip a different procedure is more practicable. From a plaster negative make a positive cast of the damaged part in stiff gelatin. When this has hardened remove and cut the line of the scar, place the pieces in their relative normal position and the gaps will represent the defect.

Before operating on the soft tissues all underlying bony defects or malpositions should be corrected or their corrections planned. Before making the first cut each major step of each successive operation should be planned, at least in a general way; patterns should be made of the proposed flaps and the whole plan recorded.

In operating on a defect of the lip which has a corresponding defect in the alveolar process, most operators prefer to have a permanent or temporary prosthesis in place before doing the plastic operation. If one is careful to build up the mucous lining and reconstruct the sulcus this is not necessary; but the permanent prosthesis is more easily inserted if the plastic closure is made over a form. The use of the form is objectionable

only when the flaps are very tight; then it is better to use forms of increasing size to stretch the lip and sulcus after healing has occurred.

It is a mistake to attempt to do too much at one operation. Certain steps are necessarily very extensive, but these especially should be made as simple as possible. It is better to plan the operation so that minor corrections can be expeditiously carried out at a later period rather than to attempt to carry out the gross and the finer adjustments at one operation. Prolonged operation is always a serious procedure, and may even threaten the life of the patient. The fact that the two-stage operation is not so apt to give the best cosmetic results cannot outweigh the dangers of an extensive and prolonged operation, particularly since it is often accompanied by a considerable loss of blood.

Another argument for repeated operations in selected cases is that in this way simple steps will often accomplish the desired end. After excising a large scar, closure of the gap by immediate suture may cause considerable distortion, but there is a tendency for the features to assume their natural positions, and after the tissues have been under tension for several months final correction may be done with a very much smaller flap than would have been required in the first instance.

Except for minor deformities, it is seldom practicable to attempt to reproduce the missing or distorted features in exactly their original form but an acceptable compromise should be the goal. Where there are large areas missing, to undertake to restore them according to a previously taken photograph is impracticable.

As a general rule the patient and the local tissues to be operated upon should be in the best condition, scars should be healed and the tissues free from congestion and œdema. Departure from this rule will result in at least occasional disappointments, but there are many conditions where much time can be gained by not waiting for the scars to heal entirely,—for example where operation on a granulating field is necessary, or where the operation is done to improve function and the health of the patient. One should never operate in the presence of an active infection.

Between operations the patient should live an outdoor life, preferably away from the hospital, until all postoperative depression has disappeared, until the scars have softened and the tissues have become pliable.

Having determined the general plan of operation and the size and shape of the defect, and having made a tentative pattern of the flaps, the next step is to find a suitable location from which to obtain the required tissue, and to determine the manner of closing the resulting gap.

The whole of the skin and subcutaneous tissues of the forehead may be turned down to any part of that side of the face on a narrow pedicle containing the temporal artery and vein (Fig. 318); in reconstructing

the cheek, its skin surface may be turned into the mouth. With a pedicle containing the angular artery and vein, a large flap may be turned for the nose and lesser ones for the eyelid. With double temporal flaps a large section of the scalp may be brought down as far as the chin. The defects resulting from any of the above can be obliterated wholly or in part by extensive undermining and, if this is not sufficient, by grafts of the whole thickness of the skin, by Thiersch grafts applied immediately, or by Thiersch grafts applied after the raw surface has granulated.

A flap 1 inch wide and 2 inches long, including the full thickness of the cheek with its mucous lining, may be obtained from the face, but if it

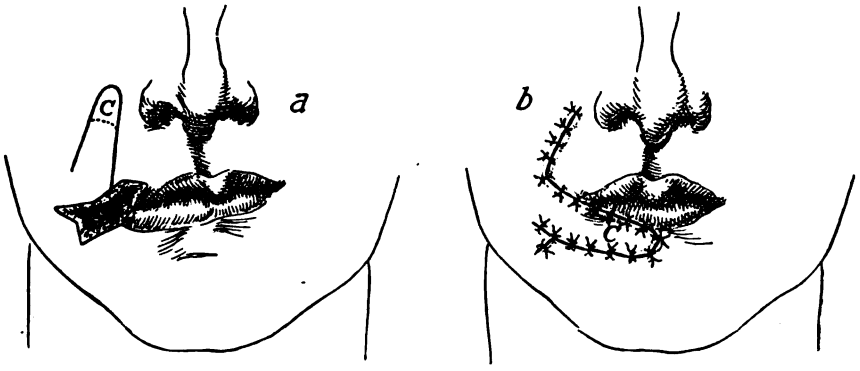

FIG. 322. REPAIR OF A DEFECT OF THE CHEEK AND LOWER LIP. The distortion of the upper lip, due to an injury of the facial nerve, is corrected at the same time.

be taken from too close to the angle of the mouth or lower lid it may cause distortion that may need correction later. Such flaps are very useful in reconstructing the lips (Fig. 322).

A flap of almost any size may be obtained from the neck and chest with a double or single pedicle attached near the angle of the jaw or submaxillary region (Fig. 323). Such flaps include the tissues down to the deep cervical fascia. A very useful double-pedicled flap attached at the lower border of the jaw may be taken transversely from under the chin and the upper part of the neck. If it is not more than 2 inches wide the gap can be closed by simply drawing the edges together, and as the scar is in the direction of skin cleavage it is but slightly noticeable. If a vertical flap not over 2 inches in width is taken from the neck the gap can usually be closed by simple suture (Fig 323). If the tension is too great it can be released by one or two parallel incisions made 2 inches from the

sutured gap on one or both sides. Larger gaps may require plastics to close them or may be immediately grafted with skin.

In taking a flap from the arm (Italian method) the arm must be firmly fastened in such a position that the flap will fall into place easily and be accessible for suture and subsequent attention. The simplest way of accomplishing this is by the use of plaster-of-Paris bandages. A better method is to make a removable head and forearm splint after the plan of a celluloid jacket. After the arm has been held in place for a few days

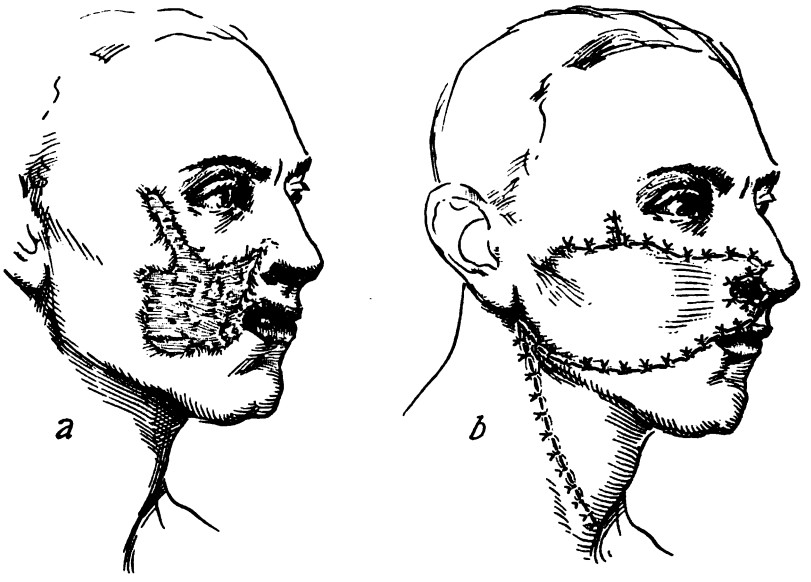

FIG. 323. REPAIR OF AN EXTENSIVE INJURY DUE TO A BURN. (*Schaeffer.*)

the splint can be removed temporarily to wash and powder the confined parts. If the patient is gradually accustomed to holding the arm in the required position for a few days before the flap is attached the confinement will not be so irksome.

By successive operations a toe, or a section of a rib with its soft tissue coverings (E. G. Blair), or flaps from any part of the body can be attached to the hand or forearm and thence to the face; or a finger itself can be used for reconstructing the nose, but as a general proposition the simpler the plan that will serve the more apt it is to be satisfactory.

At the time of operation the previously made pattern will most probably have to be modified. The usual plan at operation is to excise the

scar and then compare the defect with the pattern. If conditions permit, the borders may be undermined and the size of the defect lessened by tension on the surrounding skin and subcutaneous tissues. When the amount to be gained in this way is determined, a new pattern can be cut from which the pedicled flap is made. If a flap is to be sutured on all its borders, as for a defect in the cheek, it should be cut the same size as the defect to be filled; but where one edge is to remain free, as for the lower part of the nose or eyelid, it should be larger in this diameter to allow for shrinkage.

A flap with a short broad pedicle will not be the same shape when it is swung into place as when cut, and this change in shape should be allowed for in planning the flap.

If after cutting a flap of reasonable width with sufficient subcutaneous tissue there is a question as to the circulation, the flap may be sutured temporarily into its original bed. With the help of this procedure the flap may be made of almost any length desirable.

A flap ½ inch wide and 2 inches long may be cut from the cheek or brow. To repair a damaged orbit I have cut from the neck a flap 2½ inches wide that extended from below the jaw on one side to a point just above the axilla on the opposite side. The flap was immediately sutured in place. The following day, as the sutured end looked blue, the flap was taken down and attached by its end to a small flap raised from the chest. Later it was again attached to the orbit and healed without trouble.

The best material for suturing the skin or mucosa is coarse horsehair. It is elastic, better tolerated than silk and is not so apt to leave suture scars. The sutures should be interrupted and be just sufficient in number to produce perfect approximation. Each should transverse its part of the wound vertically. At the point of the flap they should not be so placed as to cut off the circulation nor should they be drawn tighter than necessary. If, on the face, the tension is too great to be overcome by horsehair, the wound should have deep supporting sutures of silkworm gut which are tied over a section of rubber tubing, or over a button of lead or vulcanite. These deep sutures may enter on one side, transverse the free part of the wound, and emerge on the other side, being held taut by buttons fastened at the ends; or they may enter on one side and, after engaging the structures of the opposite wall, emerge ¼ inch from the point of entrance to be tied over a tube or a button. Placed in this way they can be left longer without making suture scars, and have the advantage of increasing the depth of the wound since they raise the surface rather than depress it. For building up the depth of the wound they are superior to catgut, as they cause less reaction, particularly in wounds

which are not clean. In the cheek and lip the stay sutures can often be placed from the mucous surface.

If all suture marks are to be avoided, skin sutures should be removed on the third or fourth day; narrow strips of gauze, ⅛ inch wide, may be pasted across the wound with thin flexible collodion at ½ inch intervals.

If there is tension and danger of the edges separating, all the sutures should not be removed at once, but a strip passed across the incision as each one or two are removed. If the wound is not clean enough for this, strips of gauze with the selvedge toward the incision may be pasted on either side of the wound ½ inch from the line of incision. After they are thoroughly dried, interrupted silk sutures can be passed from one strip to the other with a fine cutting curved needle.

A sutured wound that extends to an infected bone area should be drained in its deepest part. If there is danger of blood or serum collecting in the depth the wound should be drained for at least 24 hours. Rubber tubing or dam is the best drainage; gauze should never be used.

If deep infection develops in the wound one should not be too hasty about removing the sutures; there may be much œdema and tension without the presence of infection and the application of an ice bag may prevent its development. If it is believed that drainage is necessary one should try to establish it between the sutures rather than remove too many of them.

Unless pressure is needed, dressings should not be used on the face. If the wound is kept free from secretions until it dries it will need little further attention, but no crusts or clots, not even minute ones, should be allowed to form on the wound or sutures. This is prevented by repeatedly sponging the secretion away with 4 per cent boric acid in alcohol until no more forms. If there is bleeding or more secretion a damp dressing may be applied until the oozing ceases, and then the above treatment carried out. This requires patience in the early part of the after-treatment, but simplifies the latter part and well repays in the final result. We have used almost every kind of dressing from compresses to pastes, and I believe the above method, if faithfully carried out, will give the best results. The postoperative treatment should be carefully carried out by one who understands and is interested in the work.

The amount of scar formation and contraction varies with the individual, and depends upon whether the incision is made with or across the line of cleavage of the skin. Aside from these considerations and barring an inherent tendency to keloid, the scars of well-approximated wounds on the face will be noticeable in proportion to the infection that occurs in healing. The greatest danger of infection is from surface bacteria harbored under crusts or dirty dressings.

All scars contract, so that a scar that looked perfect the day the sutures were removed will not be so pleasing two weeks later, and will look still worse in two months. On the face there is a strong tendency to adjustment in the right direction, and after six months or a year the result is usually much better than when the sutures were removed, except in cases where nose, eyelid, or lip flaps were made too short.

SKIN GRAFTING

Full-thickness grafts. To secure a full-thickness graft the skin is cut from the underlying fascia by a sharp broad-bellied scalpel, the edge of which is turned toward the skin so that no fat or fascia is removed with the skin. In doing this the raw surface should not be touched with the finger. The knife edge should always be applied where the cleavage line is most tense. Before cutting the graft, the outline is marked from a pattern with the point of a knife and is cut a trifle smaller than the defect to be filled; when it is freed it will be very much smaller. With the epidermis down, it is laid on a towel or clean board and punctured with the point of a knife every ½ inch for drainage. It is then placed on the defect and sutured to the edge of the wound with horsehair. If possible, fairly firm pressure should be applied to the surface by the dressings. The surface of the graft may subsequently turn black, but if clean, some part of the depth will survive. Such grafts are useful on the forehead, scalp, cheeks, temple, and behind the ears, and some oculists use them in lid repair.

Skin may be taken from the pubic area to replace an eyebrow; in doing this, the hair bulbs that protrude through the skin should not be damaged.

Thiersch grafts. For convenience of cutting, Thiersch grafts are usually taken from the front and outer side of the thigh. Esser insists that they be taken from the inner side of the arm. An ordinary razor with a straight edge but rounded at toe and heel, a hand microtome knife, or an amputation knife may be used, but one of the two former are preferable as a keen edge is most important.

In cutting the grafts a straight, steel spatula, 10 or 12 inches long, is grasped firmly in the left hand and pressed against the anterolateral surface of the thigh. The razor is held flat against the skin ¾ inch behind and parallel to the spatula. The operator stands in an easy position and moves the spatula forward, maintaining an even pressure as the razor follows with a slicing motion. In this way a graft 2 inches wide and almost any length can be cut with an ordinary razor. Parker has advocated applying vaseline to the surface before cutting, both to make the spatula slide easily and to keep the graft from curling. The graft is transferred directly from the razor blade to the bare area or to the form on which it is to be used, without touching the raw surface with the finger. Whether the graft is the thinnest possible or of some thickness is probably of little importance as long as the skin is not penetrated.

Such grafts may be placed on a freshly cut surface, on a granulating surface from which the granulations have been sliced, not scraped, or directly on the surface of firm, clean, healthy granulations. Bleeding should be controlled.

When the graft is applied to a granulating surface, one may provide drainage by cutting the graft into narrow strips. The graft with the epidermis down is placed upon a sheet of gutta percha tissue; the edges of the gutta percha are trimmed to correspond to the size of the graft, and with sharp scissors the graft

and tissue are cut into strips ¼ inch wide but attached to each other at one border. The tissue and graft are then transferred to the raw surface. To the surface from which the graft has been cut a damp, mildly antiseptic gauze pad is applied until bleeding and active discharge of serum ceases. The wound may then be exposed to the air until thoroughly dry and protected with a dry gauze pad; it will need no further attention.

After extensive burns in children, where large areas may require to be grafted from a limited supply of skin, repeated crops may be cut at intervals from the same surface.

Numerous methods of caring for Thiersch grafts after operation are in vogue. but one cannot help feeling that they are often overtreated; probably the most important points are to maintain complete rest of the grafted part, an even pressure, and drainage. The pressure maintains rest and either helps the drainage or negates its necessity by not allowing secretions to collect under the graft.

If the grafted surface is clean, dry dressings may be applied with an even pressure and left undisturbed for a week. If the surface is not clean and there is considerable secretion the dressings should be merely dampened to facilitate absorption. To prevent the possibility of grafts being raised in changing the dressings, strips of gutta percha ¼ inch wide may be laid ⅛ inch apart on the grafted surface, and the ends fastened to the firm skin by touching them with a drop of chloroform. Much successful grafting is done by exposing the grafted surface to the air without pressure or dressing. If this method is used crusts should not be allowed to form at the edges of the graft as they interfere with drain age and harbor septic organisms.

Epithelial inlays. This is a general term that has lately been applied to the process of applying a graft to a form, raw surface out, and either burying the form in the tissues or pressing it into a freshly cut groove or against a fresh raw surface. Rest and pressure are the factors depended upon in the after-treatment.

Though this procedure is not new in principle some of its applications are innovations. Rotter of Munich grafted skin upon the under surface of a forehead flap as a preliminary to turning it into the mouth for the repair of a palate defect. Skin grafts have been applied to an artificial eye form and inserted into newly cut pockets behind the lids to remedy obliteration of the conjunctival sac. Esser probably first used a truly buried inlay. For the relief of scar bands within the mouth, he made a tunnel from the outer skin just under the band for its full width. Into this he inserted a form covered with a skin graft and sutured the external wound. After some days the scar band was divided from within the mouth down to the form and the latter removed so as to leave an epithelial lined pocket.

We first saw the epithelial inlay used by Gillies and his associates at Queen's Hospital for the relief of ectropion of the eyelid. They were at that time releasing intra-oral scar bands and relieving obliteration of the bucco-alveolar sulcus by cutting from within the mouth, and placing a graft covered form in the newly made groove. We have successfully followed these methods and have also immediately grafted the inner surface of a reconstructed nose by draping the grafts over the intranasal splints.

A suitable form is made of vulcanite, metal, gutta percha, dental moulding composition or stent. If it is to be a buried inlay, the whole surface extent of the form should be slightly larger than the raw area; if the form is to be applied to a surface or groove, the surface or surfaces of the form that are to support the

graft should be larger than the surface or groove to be covered. For the buried inlay, the whole form is covered by the graft, which may conveniently overlap itself. If necessary, a few silk sutures may be used to hold the graft to the form. For the surface inlay the graft is simply laid over the form. The buried inlay form is held in place by suturing the tissues over it; the surface inlay form may be attached to a dental splint or held in place by sutures passing completely through the cheek and tied over a tube on the outside. These forms are left in place a week or ten days.

PLASTIC OPERATIONS

The general principles of making and placing flaps have been dealt with at some length in the preceding paragraphs because one cannot do successful plastic surgery by mechanically copying the classic operations as represented in the various texts. Every case is a problem in itself and must be dealt with individually. Unless one has the persistence to study each case thoroughly, and the imagination to perceive the principles upon which the operations are based, he cannot reasonably hope to secure the best results. In the following pages the correction of certain of the more common deformities and defects are presented in the spirit of suggestion rather than dogmatism. The word plastic as applied to surgery refers to mobility and adaptability of the tissues, but it should characterize even more definitely the surgeon's technique.

Resection of a depressed scar. The scar is excised in its entirety so as to include its greatest depth, but before doing this the manner of filling the defect should be determined. If not of great width, this can be done by drawing its lateral walls together after undermining the tissues, and building up the walls in suturing. It is better to build up the wall in such a way that on completion of suturing, the skin edges are slightly elevated; subsequent scar contraction will level them. If the scar is irregular in outline the excision is so planned as to utilize the tissues to the greatest advantage.

If the scar extends through the full thickness of the cheek it is excised all the way through and the cheek built up to its proper thickness. Before suturing the cheek it may be expedient to do a flap operation on the mucosa to give freedom to the jaws. Sometimes a deep scar runs obliquely into the face so as to allow the cheek to slump downward or forward. In these cases, after the excision of the scar, the tissues are superimposed in their proper position.

Certain depressions, due to the loss of the underlying support, can be corrected by simply building up the tissues. When there has been a loss of bone such depressions not infrequently occur over the angle of the jaw; the angle of the mouth and the anterior part of the cheek move

forward, and the lower half of the attachment of the ear is depressed medially. Correction can be made by excising a narrow strip of skin just in front of the ear and behind the angle of the jaw and, after dissecting deeply between the anterior border of the sternomastoid muscle and the mastoid process behind and the partiod gland in front, superimposing the muscle and its fascia on the gland.

If the wound is clean, depression from scars or other causes may be filled by a transplant of fat from the abdomen or limb; in doing this the graft should be of a proper size and an approximate shape, though it tends to conform itself to the space in which it is placed. The fewer sutures inserted into it the better. The deformity should be over-corrected as there will be some subsequent absorption. Muscle flaps from the sternomastoid or temporal muscles may be used for the same purpose as pedicled grafts, but a muscle that has lost its motor nerve supply will atrophy, and if the nerve supply is retained it may cause facial contortions in the region of the transplant.

In operating during the quiescent stage on a fistula opening into a depressed scar, the scar may be excised and the defect repaired at the same time that the cause of the fistula is removed, but deep drainage should be provided. The scar may also be treated at the time of placing a bone graft.

Large surface scars usually result from burns and may involve the whole face and the neck as well. The ridges and cords in recently healed scars tend to become less noticeable as time goes on; radium helps to soften and reduce these, but the contraction is objectionable. If the play of the muscle is limited and the features are distorted, excision of parts or all of the scar is the best treatment; the resulting defect is covered with flaps from the neck, chest or arm, or, if not deep, by skin grafting. In turning large flaps for this purpose they should be of just sufficient size to maintain the normal tension of the skin when sutured; if too lax the transplanted skin is of an opaque, unnatural appearance.

Plastics upon the lip. The lips are very distensible; half of either lip can be lost and the remainder stretched over the defect without producing a very uncanny appearance. The resulting tension will subsequently relax considerably, and this can be expedited by daily stretching with the finger or by a prosthesis of increasing size.

The normal prominence of the upper lip is due to the subjacent teeth; that of the lower is rather dependent on its fullness. Either lip may be excessively prominent on account of the tension of the other. In young people with regular features it is better, if the defect is not too great, to confine the operation to the lip tissue and especially to preserve the normal angle of the mouth. An extensive plastic operation extending

into the cheek may greatly improve the condition and may be necessary, but will never reproduce the normal appearance.

The oral fissure is normally situated just above the line of occlusion of the teeth; the angle of the mouth is opposite the first premolar. There is a great deal of variation in the types of normal lips, which gives one latitude in their reconstruction. Displacing the center of the lip and the philtrum laterally is not very objectionable, but the corners of the mouth should be symmetrically placed and the fissure should be transverse.

FIG. 324. REPAIR OF A DEFECT INVOLVING THE FULL THICKNESS OF BOTH LIPS.

One of the functions of the lips is to form a water tight joint; the continual dribble of saliva is most annoying. This complication is most apt to occur after injuries to or operations on the corner of the mouth, and should be provided against in its reconstruction.

Too great an exposure of the mucosa of the lip is more noticeable than too little. Excessive exposure is due to a deficiency in the skin covering, constituting an ectropion, much more common in the lower than the upper lip. One way of dealing with this in cases of the milder type, where the loss is confined to the skin adjoining the mucosa, is the insertion of a buried epithelial inlay, just as for an ectropion of the eyelid.

A puckering scar at the angle of the mouth in most cases represents a surprisingly large loss of tissue. After the scar is removed what

appeared as a simple procedure at the outset may prove to be an extensive plastic operation. Before making the repair the jaw should be opened ¾ inch with a previously made splint or a block of wood between the teeth. If the scar or the defect involves the skin and subcutaneous tissues only, and not the mucous lining of the angle, it is simply a matter of

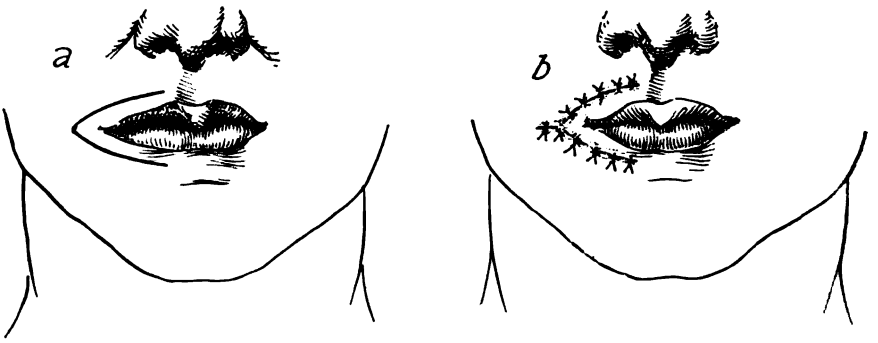

FIG. 325. RESTORATION OF THE ANGLE OF THE MOUTH. The angle has been drawn abnormally outward.

FIG. 326. RESTORATION OF THE ANGLE OF THE MOUTH. The angle has been drawn abnormally inward.

switching a skin flap from the cheek. If the defect involves the full thickness, but three fourths of each lip still remains and the cheek defect is not too large, the lips may be sutured to the cheek border with the angle at the proper level (Fig. 324). It may be necessary to surround the upper lip partially with a circumferential incision to prevent distortion of the nose.

The visible mucosa of the lip normally tapers as it approaches the angle of the mouth. If each partial lip is sutured to the cheek the visible

mucosa is apt to end abruptly instead of tapering off gradually. This is obviated by first suturing the cut end of each mucocutaneous junction securely to its fellow with a trial suture, and drawing this new angle to the position it is to take. If it is found that the mucous tissues tend to protrude at the angle, a triangular piece of mucosa and submucous tissue is removed and the borders of this wound sutured. The section removed should be on the inner surface of the lip, not closer than ¼ inch to the mucocutaneous junction. There must be a good pad of tissue above and below for apposition or the angle may leak. The mucous flaps re-

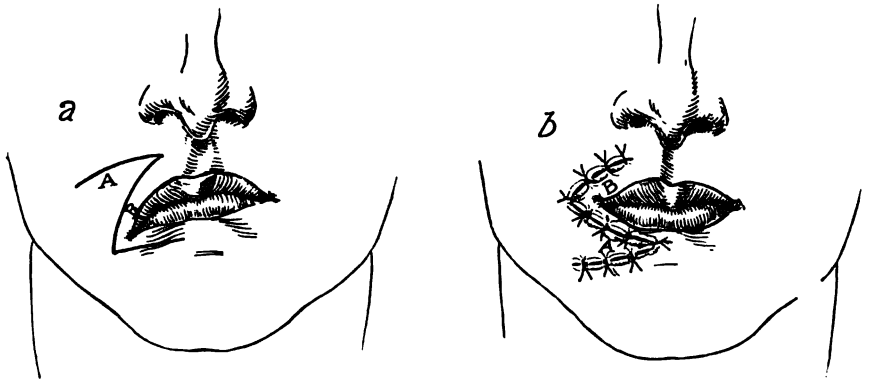

FIG. 327. RESTORATION OF THE ANGLE OF THE MOUTH. The angle has been drawn abnormally downward.

moved may be left attached by part of one border, and used to piece out the mucosa behind the angle when that is deficient. If after the wound has healed the oral slit is too wide on this side, it can be diminished by excising the mucous border above and below for a sufficient distance and suturing the raw surfaces.

In order to reproduce the natural appearance of the mucosa at the angle, the denuded area should extend further mesially at the mucocutaneous junction than on the deeper part of the border. If the lips are tense, the sacrifice of the mucous border can be obviated by converting a V into a Y (Fig. 325). If the oral slit is not sufficiently wide it can be extended laterally by converting a Y into a V (Fig. 326), but if the angle of the mouth is displaced medially a distance equal to one-third of the width of the oral fissure, a different procedure is necessary. In such a case the cheek is split laterally for a sufficient distance and the lining mucosa undermined in all directions for about an inch. Above and be-

low sufficient tissue is removed from the thickness of that part of the cheek which is to form the lip to make it correspond to the proper thickness of the lip, but no tissue is removed at the outer end of the cut which is to be the new angle. The mucosa is then sutured to the skin all

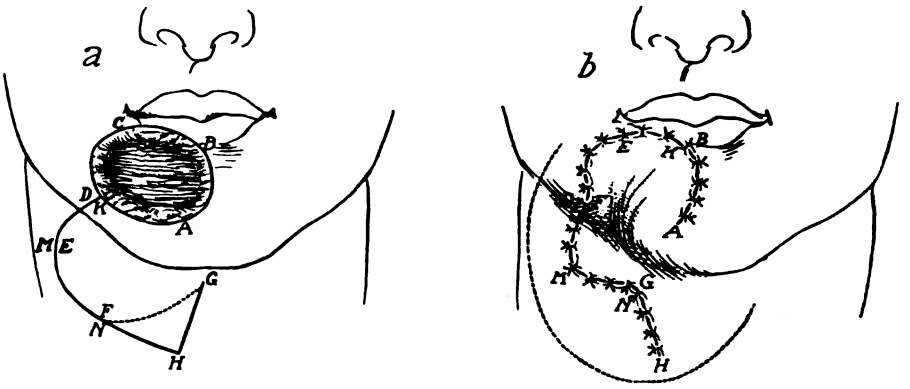

FIG. 328. REPAIR OF A CIRCULAR DEFECT OF THE FACE.

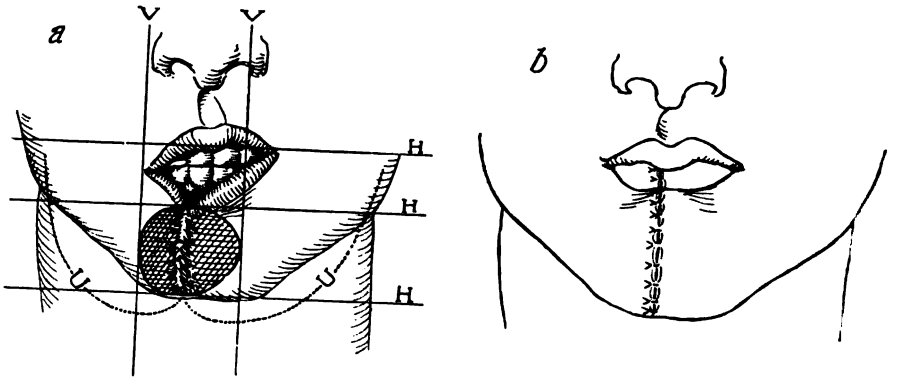

FIG. 329. REPAIR OF A CIRCULAR DEFECT INVOLVING THE LOWER LIP.

the way round. If the defect in the cheek is too large to be closed by simply suturing the borders to the lips, a full-thickness flap can be turned from another part of the cheek.

If one lip is very tight and the other disproportionately full, a piece of the whole thickness of the skin or mucosa can be switched from one lip to the other.

The corner of the mouth can be simply raised or lowered by making a Z incision and switching the flaps (Fig. 327), but if the displacement of the angle is due to a loss of tissue in the lateral part of either lip, it may be remedied by inserting a flap from the cheek.

For extensive injuries about the mouth the methods illustrated may be used or flaps turned from lower down on the neck or arms (Figs. 328-333).

If the defect *abcd* (Fig. 328) is to be filled from a neck flap, such as *kefg*, the latter is not cut the shape of the defect, but approximately of

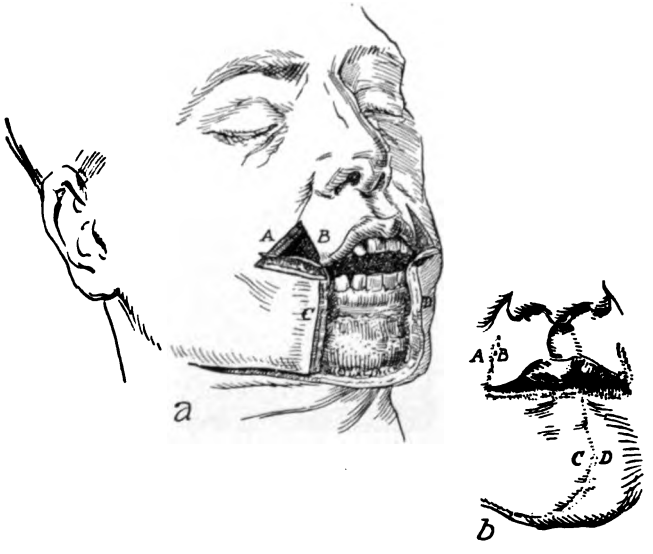

FIG. 330. REPAIR OF AN EXTENSIVE DEFECT OF THE LOWER LIP AND CHIN BY BURROW STEWART'S OPERATION.

the form shown in order that it may swing on the base *ag*. The flap borders will be sutured as indicated, after which the raw surface left by the removal of the flap is covered by swinging a triangular flap downward and forward (*mnh*, Fig. 328).

In planning such a closure the base of the pedicle is visualized and tentatively marked on the skin; the distances that various parts of the flaps must reach are calculated and the pattern cut accordingly.

The flaps for circular or oval defects may be calculated in the same manner. The circumference of the defect *abcd* (Fig. 328) is divided into four equal distances after measuring the defect with a steel tape. The flap *adefg* is calculated as follows: *ad* is the same distance on a

curved line as *ab* to which it is attached, *de* corresponds to *bc*, and *fe* to *cd*; *g* is so placed that the distance *gf* equals the distance *gd*, and *eg* equals *cg*. The base *ac* must be broad enough to furnish nutrition to the flap, and the area *adef* must be as large as the defect *abcd*.

The closing of the remaining gap will be simplified if the triangular flap *fg* is included in making the original flap, so that the border *fh* can be sutured along the line *gh*.

Rose's plan of operation for hare-lip may be applied to certain defects, particularly of the lips and eyelids; in such an operation the edges of the

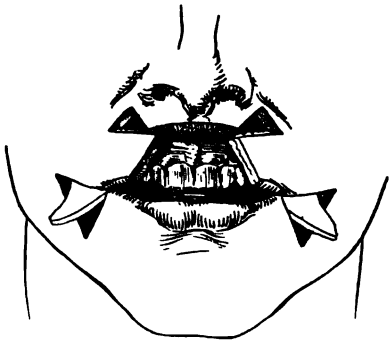

FIG. 331. RECONSTRUCTION OF THE UPPER LIP BY BURROW STEWART'S METHOD. The operation is possible only when the tissues are very lax.

flaps are cut in a concave direction and sutured in a straight line. If necessary a flap is freed by undermining. In the defect of the lower lip and chin illustrated in Figure 329, the lower lip and the right angle of the mouth must be elevated. In order to correct a V-defect by a Rose operation, the concavity of each incision must extend laterally to a vertical line dropped from the outer limit of the defect on each side. The length of the curved incisions must be the same and equal to the distance to which the tissues are to be raised, and there must be sufficient tissue to allow suturing them in a straight line. In the case illustrated the tissues are forced upward as the curved incisions are sutured. In some cases it may be desirable to have the tissues move in two directions, and the length of the curved incisions will be calculated accordingly. It will be noted in Figure 329 that the lateral extent of the defect is further to the left of the suture line than to the right, therefore the curved incisions are not symmetrical.

A distinct advantage of the Rose type of operation, where applicable, is

that if the deformity is not entirely corrected by the first operation it can be repeated later without making another scar.

In certain cases of facial defects the destruction of the skin is much more extensive than that of the mucosa, the latter meeting the skin on the external surface. After the scar is removed and the mucosa freed, there may be enough of the latter to line the defect, so that only a surface flap need be transplanted.

For defects between the oral fissure and eyebrow, including those of the upper lip, Esser cuts a combined neck and cheek flap with a pedicle

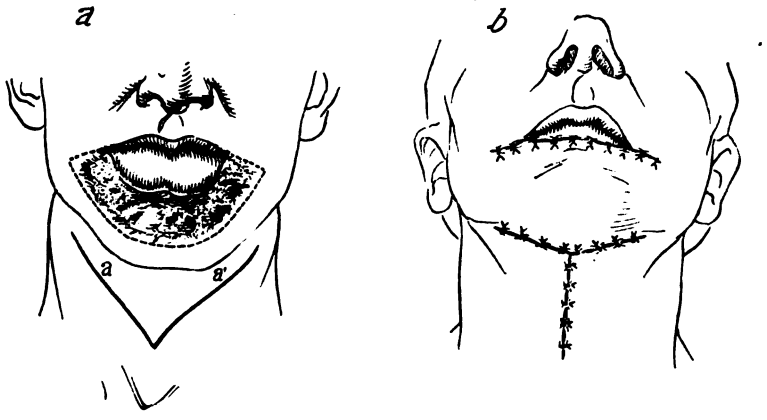

FIG. 332. REPAIR OF AN ECTROPION OF THE LOWER LIP DUE TO A BURN.

containing the facial artery, varying the size of the flap according to the defect to be filled (Fig. 321). The dissection of the cutaneous flap is made superficial to the motor nerves and the parotid duct, but must contain the artery. The incision for the mucous lining corresponds to the upper part of the cutaneous flap, but swings anteriorly to the opening of Stenson's duct. (*Ann. Surg.*, xlv, 297.)

Defects within the mouth. The mucous membrane of the mouth stretches more than the skin, so that a defect of half the lining of the cheek may be compensated for; but if there is a loss in the bucco- or labio-alveolar sulcus with a corresponding loss of the mucosa of the gums, the raw surfaces will adhere with obliteration of the sulcus. Similarly, the palate and the pillars of the fauces may adhere to the pharyngeal wall. Loss of much of the lining of the lip will cause inversion, and loss of the mucosa near the angle of the mouth will cause deformity.

In correcting a deformity or defect of the cheek or lips, the condition of the mucous lining must always be considered: an intra-oral scar may

be the chief element in the disfigurement. The mucosa of the lips and angles should always be well repaired. Much can be done by undermining, and when this procedure furnishes sufficient material flaps of the mucosa may fill the deficiency. The opening of Stenson's duct should not be damaged.

If a narrow band impinges into the sulcus, it may be corrected by a plastic operation, but it is better to insert a permanent prosthesis immediately. For an obliteration of any extent an inlay graft is best. By

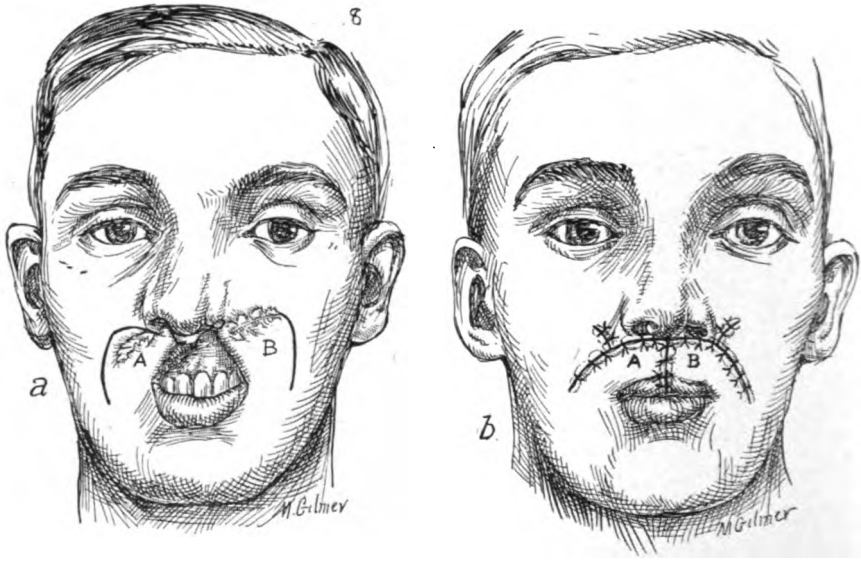

FIG. 333. RESTORATION OF THE UPPER LIP BY CHEEK FLAPS.

cutting between the bone and cheek while leaving some tissue on the bone, the sulcus is made deeper than normal. Into the newly made sulcus is inserted a form carrying a skin graft, held in place either by attachment to a dental splint or by a suture passed through the cheek and tied over a button or tube on the outside. A defect in the center of the cheek or lip can be repaired in the same way, the form being left in place a week or ten days. Besides having a clean cut surface free from active bleeders, the most important point is to have sufficient evenly distributed pressure to prevent mouth secretions from seeping under the graft. The possibility of necrosis of the graft from excessive pressure should not be forgotten. The importance of keeping the mouth free from infection and from decaying food particles need only be mentioned.

A flap from the neck or forehead can be turned into the mouth to replace a mucous defect (Fig. 317).

Defects of the palate. A small opening into the nose, if there is good palate tissue on either side, can be closed by a Von Langenbeck operation. A long incision is made to the bone on either side close to the teeth, and the soft tissues of the palate, including the periosteum, are freed from the bone so that the borders of the defect are easily approximated. If possible, the descending palatine artery is preserved on both sides. The borders of the defect are freshened and sutured with horsehair (Fig. 334). A strip of rubber dam, inserted into one lateral incision, will

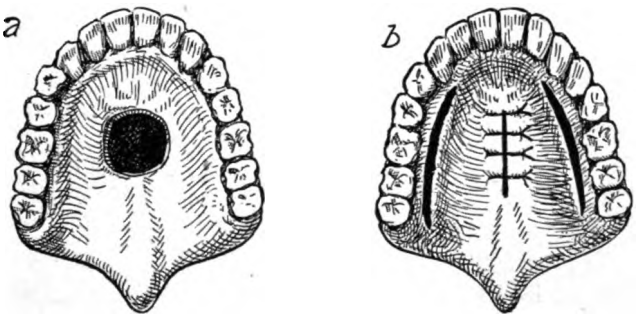

FIG. 334. CLOSURE OF A DEFECT OF THE PALATE BY APPROXIMATING MUCOPERIOSTEAL FLAPS.

serve as a drain and help protect the suture line. A large defect can be closed by including flaps from the cheek.

An opening into the antrum, in which the soft tissues come in contact, but which is kept from closing by the mucous membrane, may be closed by destroying the mucosa and scar with the blade of a red hot cautery. Fistulæ of the above character are usually found high in the sulcus between the cheek and gum, or palate.

A patent sinus leading to the antrum or a laterally placed opening in the palate can, if not too large, be closed by undermining its mucoperiosteal borders until it is freely mobilized all the way round, and turning in a flap from the lining of the cheek considerably larger than the defect. The base of the flap should lie close to the defect. The mucous surface of the flap is turned toward the antrum and nasal cavity, and its borders are tucked under the mobilized gum and palate tissues, raw surface to raw surface, and sutured. If the defect is too large to be closed by the available intra-oral tissue, hair-free skin flaps may be used. Blasius used a strip from the forehead, but a flap from the neck and chest is better.

In freeing adhesions of the tongue to the floor of the mouth, usually enough mucous membrane can be obtained to cover the raw surface, but if not, a buried epithelial inlay can be implanted.

Defects of the orbit and eyelids. Extensive destruction of the orbital border can be restored by a transplant of cartilage after a soft tissue covering has been provided for the reception of the graft. A limited area, ¾ inch or more, can be compensated for by building up

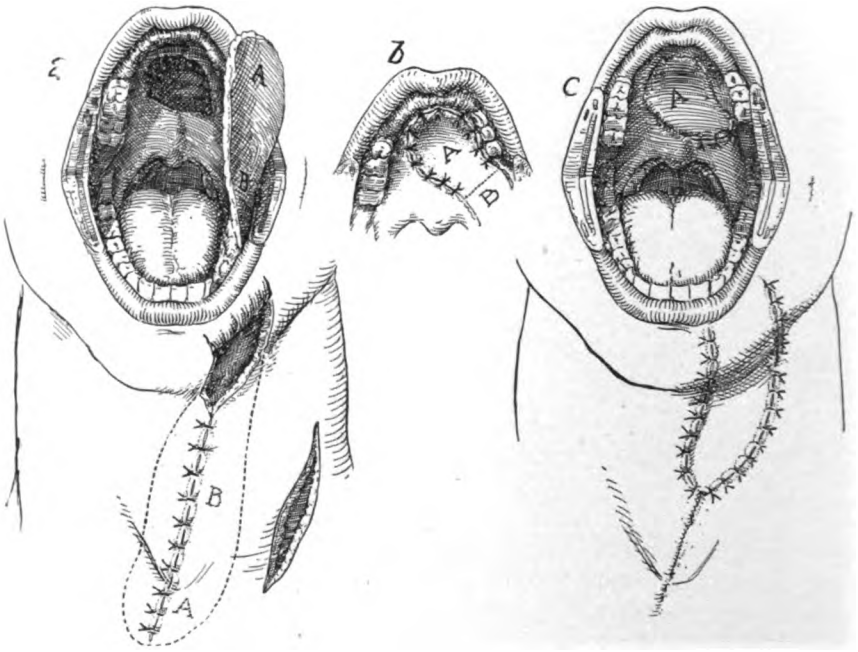

FIG. 335. REPAIR OF A DEFECT IN THE PALATE BY A PEDICLED FLAP OF SKIN AND PLATYSMA FROM THE NECK.

the soft tissues. Complete destruction of the contents of the orbit and lid, with wide communication into the nasal fossa, may be covered with a flap from the forehead or chest. From such a flap lids can be built and a socket for a specially shaped artificial eye constructed. Where the ocular muscles are intact but the contents shrunken so that an artificial eye is not well worn, a glass ball or a ball of cartilage can be implanted in the depth, and the distal ends of the muscles sutured together in front of the implant. Where the conjunctiva is deficient it must be restored as well as the lid. For lesser defects of the conjunctiva a plastic can be

done by undermining the mucosa, but the sac must retain sufficient depth to hold an artificial eye. If much of the lining is missing it is best restored by an epithelial inlay. This procedure constituted one of the earliest uses of the inlay graft. In preparing the sulcus to receive the graft it should be made considerably deeper than it is expected to be ultimately, and the graft can be draped over an artificial eye larger than

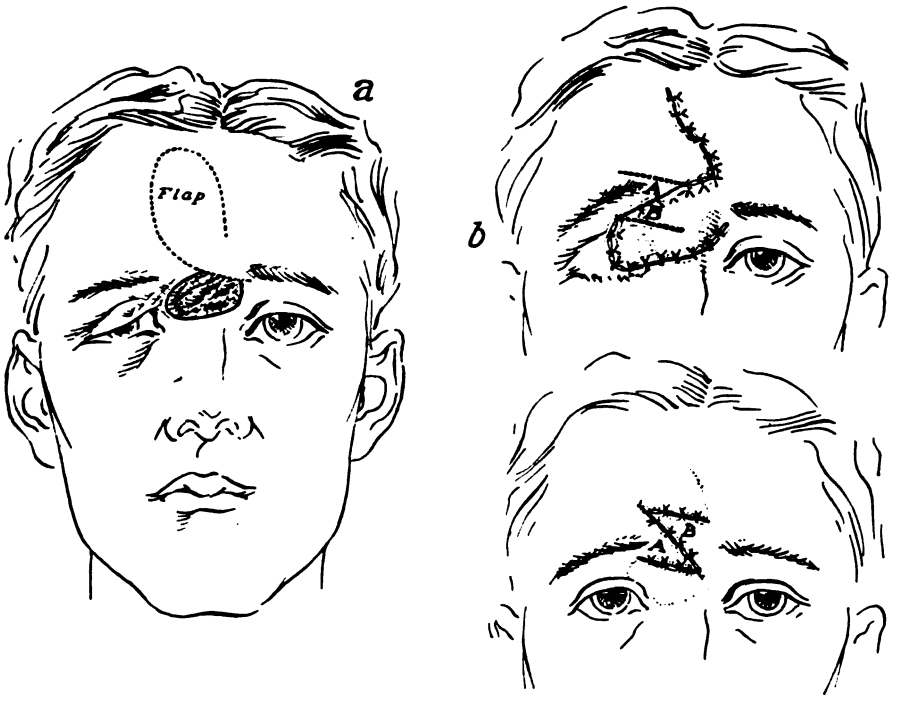

FIG. 336. REPAIR OF A DEFECT OF THE FOREHEAD AND EYELID BY A PEDICLED FLAP.

is to be worn later, or over a form. Wiener uses a form made of paraffined cardboard which is very satisfactory. The operation frequently has to be repeated on account of the subsequent shrinkage of the sac. The form is worn for a week and the eye inserted immediately. To help overcome the shrinkage where there is conjunctiva available, Wiener has utilized this to line the lid, suturing the edge of the conjunctival flap to the depth of the new sulcus and inserting a graft on a form to cover the posterior wall. Esser inserts a graft-covered form through a cutaneous incision made just above or below the border of the lid, and sutures the

cutaneous wound. Later the newly formed epithelial sac is opened and the form removed by an incision made from the conjunctival surface.

For small defects of the full thickness of the lid a plastic on the lid itself may be sufficient. An operation of the Rose type for the lip or of the V-Y type may be applicable. In approximating two parts of a lid, one suture should be placed in the tarsal border. In certain cases with loss of the lid, after the conjunctiva is freed there is sufficient tissue carrying its own blood supply to line the new lid. After the conjunctiva is put on tension, Thiersch or Wolf grafts can be applied to its raw external surface, but the result is not apt to be as good as from a flap operation.

For large defects flap operations are required and, except in the inverted V-Y type of operation which gives a firm base to support the flap, pedicled flaps are better than sliding flaps, at least than those that are slid towards and not parallel with the palpebral fissure. Since there is no support for the flap at the fissure border, there may be a tendency for it to slide back again.

In planning a plastic repair of the eyelid, the same principles apply as in other parts, but it is well to plan the vertical depth of the lid one third longer than is apparently necessary, and the lid part of the flap as thin as possible. Inversion of the lid is due to a deficiency in the vertical depth of the lining, which may be only a narrow scar band. It is most logically treated by piecing out the conjunctiva after all scars are released. Ectropion of the eyelid is due to a defect in the vertical depth of the outer tissues, but the defect or contracted scar may be in the cheek or brow.

Besides the various standard flap operations for defects about the eye the inlay graft became popular during the war, especially in cases of extensive facial burns in which little tissue was available for skin flaps. Before operating all infection should be controlled; there may be a mucopurulent discharge from the conjunctiva when no artificial eye is worn. This is often difficult to eliminate, but it may be helped by a very weak alum wash. A suppurating lachrymal sac should be cured or excised, the latter being the simpler procedure. The earlier an artificial eye can be worn the better, for until it is worn there is a progressive shrinking of the sac and atrophy of the lids.

SECTION XVIII

GUNSHOT WOUNDS OF THE TRUNK

WOUNDS OF THE THORAX

BY

J. L. YATES, PH.B., B.Sc., M.D., F.A.C.S.
Chief of Surgical Staff, Milwaukee County Hospital; Attending Surgeon, Milwaukee Children's and Columbia Hospitals

WOUNDS OF THE ABDOMEN

BY

BURTON J. LEE, PH.B., M.D., F.A.C.S.
Clinical Professor of Surgery, Cornell University Medical College; Associate Surgeon, New York Hospital

CHAPTER I

WOUNDS OF THE THORAX[1]

It was inevitable that important advances should have been made in thoracic surgery during the war. The large numbers of chest wounds furnished an incentive for study and opportunities for observation which had previously been lacking. Antebellum experience favored conservative methods in treating penetrating chest injuries, because such wounds were comparatively simple, were not liable to virulent types of infection, and because thoracotomy, except in the hands of a very few surgeons, had not been a safe operation. Expectant treatment was consequently in vogue in the early period of the war and long survived its usefulness since suitable surgical methods were developed slowly, as they included all the detailed procedures applicable to other wounds, plus special means to safeguard respiration and circulation. The most severe types of injury which had given uniformly bad results under conservative treatment were finally treated surgically, and the successes obtained led to a constantly widening application of operative measures.

In this connection one may recall similar evolutionary phases in the treatment of penetrating injuries of the abdomen, the skull, and the joints. Wounds of all these structures were at one time held to be best treated expectantly, and this opinion prevailed until they could be invaded surgically without the development of infection upon their lining membranes. Safe thoracotomy in a similar way depends primarily upon the prevention and control of pleuritis. If one remembers that the great majority of deaths, not due immediately to injury, and virtually all of the late disability, are to be attributed to acute and chronic pleural inflammation, it will make possible a just appreciation of the importance of restricting pleural irritation. Chest wounds provide all of the conditions favorable to the development of pleural infection: tissue laceration, hypertension due to hæmothorax and the diffuse exudate it provokes, and the presence of bacteria.

Intrathoracic resistance to infection. The different degrees in the resistance of serous cavities to infection depend upon variations in their size, in the richness and source of their blood supply, and in the

[1] The work upon which this section is based was done by a group detailed by General J. M. T. Finney to study the problems of chest wounds. The investigation was assisted by the Research Division of the American Red Cross under the direction of Colonel Alexander Lambert.

rigidity of their parietes, and not upon variations in the reactions of serous mesothelium, which is everywhere extremely resistant and possessed of correspondingly high powers of regeneration. Secondary factors in determining resistance are the rate and range of dissemination of irritants through motion, capillarity, and gravity, and the effects of subserous reactions.

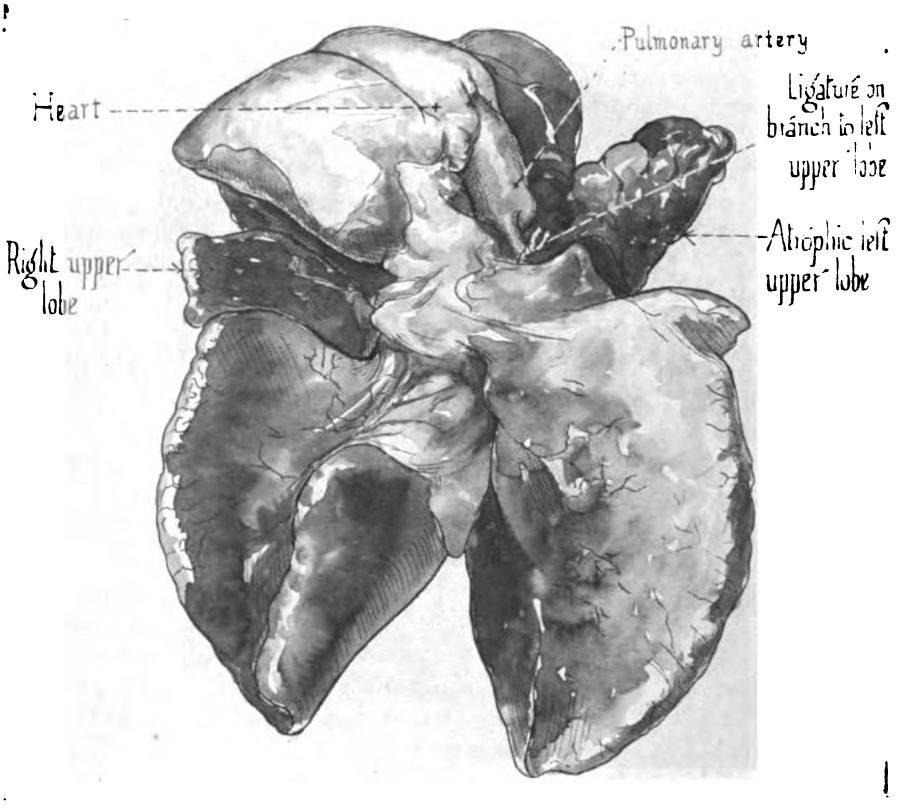

FIG. 337. SHEEP'S LUNG FIVE WEEKS AFTER LIGATION OF THE ARTERY SUPPLYING THE LEFT UPPER LOBE.

The degree of resistance of the pleural cavity to infection occupies an intermediate position between that of the peritoneum and the joints. The extent of its parietal serous surface is comparable to that of the abdomen in size and in blood and nerve supply. Its visceral surface, upon which depends the large part of its defensive strength, is very much smaller, is less richly supplied with blood than is the visceral

peritoneum, and this supply is prone to further and very marked reduction under the pathological conditions consequent upon injury.

The mechanism governing the blood supply of the lung and visceral pleura is incompletely determined. The blood pressure in the pulmonary artery is about one-sixth of that in the systemic circulation. The volume of blood delivered to the lung depends upon the activity of respiration and the integrity of the general circulation. Ligation of a pulmonary artery causes atrophy in the area of lung affected, with collapse of the air cells (Figs. 337, 338). An increased flow of blood on the other hand produces an immediate increased dilatation of the air cells. The interdependence of respiration and pulmonary circulation is due to the capillary meshwork surrounding the air cells. The lung parenchyma is in effect an erectile tissue, and exerts considerable influence upon pulmonary inflation and deflation and therefore upon respiration. Respiratory function also influences the blood supply through the bronchial arteries which nourish the lung structure and the pleura. Ligation of a bronchial artery supplying a lobe causes necrosis in that lobe. Ghoreyeb and Karsner's work shows that when the pressure in the bronchial or pulmonary artery is reduced to zero, blood will pass over from one to the other. This interchange is too slight to be more than moderately effective in influencing conditions developed by injury.

Adaptability of the thoracic walls is virtually restricted to the positions which may be taken by the diaphragm. Dissemination of irritants such as effusions, blood, toxins, and bacteria occurs rapidly in the chest because movements cannot be inhibited, because limiting adhesions form less rapidly and because physical conditions are such that gravity and capillary attraction make for an early and generalized diffusion. The rapidity and extent of dissemination are illustrated by the effects of a limited, uncomplicated hæmothorax in the presence of which, as was first demonstrated by the studies of Denny and Minot, and amply confirmed through observations upon the wounded by Elliott and Henry, intrathoracic movements are so active as to defibrinate the blood that has not coagulated spontaneously, and to spread the exudate over the entire pleura unless adhesions have been formed previously. Some coagulation of a hæmothorax is a regular occurrence; the amount and rapidity of clotting depend upon the extent of tissue laceration and the liberation of substances favoring fibrinogenesis. Middleton and Delrez have shown that blood is so irritating to the serous membranes of joints or chest as to cause a serofibrinous serositis. Middleton found that the chief irritants were fibrin and fibrinoplastic substances. Not all of the latter are removed when coagulation occurs, so that serum remains an active irritant. These facts explain the diffuse pleural reactions, varying

from a serofibrinous to an organized exudate, which are noted when thoracotomy is performed hours, days, or weeks after hæmothorax has been caused by injury. A generalized pleuritis is the rule where a corresponding generalized peritonitis is the exception.

An understanding of the effects of pleuritis, to be of practical value, must include an appreciation of its influence upon respiration and cir-

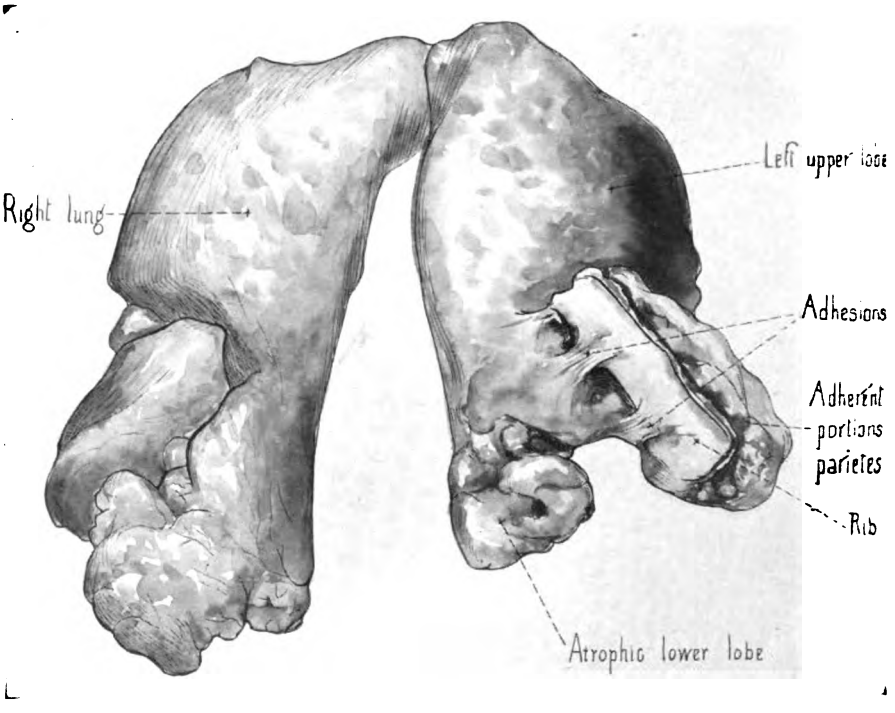

FIG. 338. SHEEP'S LUNG FIVE MONTHS AFTER LIGATION OF THE ARTERY SUPPLYING THE INFERIOR MARGIN OF THE LEFT LOWER LOBE, SHOWING ADHESIONS PRODUCED BY SIMPLE THORACOTOMY.

culation. The mechanism of normal breathing requires undiminished intrapleural negative pressure, unimpaired elasticity of the lung, and unrestricted movements of the chest wall, including the diaphragm. In acute pleuritis there is reduced homolateral negative pressure because of the inevitable exudate. As the negative pressure on one side is reduced there is in living men and animals of the thick pleural category an increased contralateral negative pressure, due to circulatory compensation which persists up to the point of decompensation. Graham and Bell have shown that in dogs, which are animals with a thin pleura, and in

human cadavers as negative pressure decreases, there is a progressive diminution in the efficacy of inspiratory efforts affecting both lungs in equal measure, since the mediastinal contents do not form a rigid, unyielding wall but move freely to one side or the other. These observations upon an animal of the thin pleura type, and upon a dead man without the influence of the circulation upon pulmonary inflation, are not directly applicable to the conditions here considered. The basic differences between animals with thin and thick pleuræ was established by Miller.

Pulmonary elasticity is impaired by the external compression of the exudate and by changes within the parenchyma. The parenchymatous changes are hæmorrhagic infiltration due to injury and cortical inflammation resulting from pleural irritation. Cortical pneumonitis fails to develop if pulmonary deflation reduces the blood supply to a point where a defensive reaction is impossible. Under these conditions the lung so affected becomes a foreign body whose presence predisposes to the development of empyema. This is an additional indication for maintaining pulmonary inflation and some degree of respiratory activity in the presence of an intrapleural exudate.

Irritation of the pleura interferes with both costal and diaphragmatic movements of the thoracic parietes by reflex pain inhibition, which becomes more complete as the pleural reaction increases in intensity and extent. Early immobility and a high position of the diaphragm is a constant accompaniment of hæmothorax, noted by roentgenologists previous to operation and repeatedly remarked by Bradford, Elliott, and Soltau, who warned against low aspiration for hæmothorax because of the high position assumed by the diaphragm. The observations of Steiner upon the effects of pleurisy, whether due to pneumonia or to injury, and the important contributions of Pryor show that this diaphragmatic immobility is constantly present and tends rather to persist than to disappear.

Both the systemic and pulmonary circulations are influenced by abnormal pulmonary inflation and deflation. Cloetta has apparently demonstrated that the circulation within the lung is most favorable when the main subdivisions of the pulmonary vessels are straight, and not elongated by abnormal inflation nor compressed and made tortuous by abnormal deflation. When effusion takes place into the pleural cavity the circulation in the compressed lung is first impeded by the increasing pressure and finally suppressed. Karsner and Ash have proved that pulmonary infarction occurs only when the circulation is impaired in such a manner at the time the embolism occurs. Compression of a part of a lung causes compensatory hyperæmia and emphysema in the balance of the lung. The compensatory changes are greatest nearest the zone of

compression, but are present everywhere and are easily demonstrated in the contralateral lung.

Emphysema increases the peripheral resistance in the pulmonary circulation by compressing the capillary bed, and at the same time demands a larger total volume of blood. Both factors call for greater cardiac effort. Under normal conditions the wide and sudden variation in the amount and distribution of blood in the lesser circulation required by rest or activity takes place with little distress. After a severe intrathoracic injury, particularly if the exæmia of shock is added to the anæmia of hæmorrhage, the margin of safety is so reduced that re-establishing the nearest approximation of normal physiological relationship becomes imperative to protect a heart already overworked and to assure adequate circulation for defense and repair.

PRINCIPLES OF TREATMENT OF THORACIC INJURIES

The capability of maintaining spontaneously the normal apposition of the lining membranes in a serous cavity is a gauge of its powers of absorption, and roughly measures its resistance to infection. An accumulation of fluid or air means the formation of dead space, hypertension within the cavity, diminished blood supply, and decreased resistance. The method of treatment that prevents separation of serous surfaces, or, after separation has occurred, re-establishes and maintains surface contact, provides the best opportunity for immediate recovery.

The degree of ultimate recovery is determined by the completeness of restoration of function. Since the factors that control respiration also govern the circulation, measures must be adopted which restore the mobility of the thoracic walls and re-establish normal intrapleural negative pressure and pulmonary elasticity.

The most important part of treatment is restriction of pleuritis; the next most important is overcoming its effects. The specific objectives are:

1. Parietal healing. Permanent, air-tight parietal closure is imperative because the worst complication, particularly if it occurs early and before the formation of limiting adhesions, is an open pyothorax. Smooth healing of parietal pleura is especially desirable as it limits pleural effusions, and offers the most effective barrier to the extension of inflammation either from without or within, and is the best protection against persistent or recurrent empyema.

2. Restriction of effusions. Pleuritic effusions decrease resistance, restrict parietal mobility, and compress the lung. They can be reduced by restricting pleural irritation, and removed by closed interrupted or continuous drainage.

3. Pulmonary inflation. Lung tissue which cannot be inflated loses its function and lacks the blood supply required for defense and repair. In general, such tissue is a direct menace and should be removed.

4. Pleural adhesions. Early fibrinous adhesions are inevitable but desirable to limit the extension of pleuritis. Experience in combating peritoneal adhesions, and the work of Delrez and of Willems in overcoming the adhesions due to arthritis, have proved that the principle of active motion, induced as early as the acute infectious process permits and continued to the limit of pain inhibition, gives the best functional results. The same principle applied in the treatment of pleurisy is similarly efficacious. It is based upon the fact that serosa cells persist beneath an exudate even after its organization, and if motion disrupts the adhesions gradually, the serosa cells which have been exposed can overgrow the defects thus produced. This makes possible a restoration of the pleural cavity after pleuritis, which can be so nearly perfect as to permit of normal function.

If these four points are kept in mind, the details of treatment to be described will not seem petty or unreasonable. They are methods which secure the tissue repair upon which function depends.

TYPES OF CHEST INJURIES

Injuries to the thorax affect the parietes alone, both the parietes and viscera, or, more infrequently, the viscera alone. The last are due to indirect violence, or to sudden and considerable changes in atmospheric pressure caused by near-by explosions. Wounds, perforating, penetrating, or tangential, are similar to those involving other structures, but are distinguished by one peculiarity—their liability to produce an open thorax. They are also complicated by wounds of the abdomen and spine more commonly than are wounds elsewhere.

In general, shell fragments cause greater tissue injury than bullets, and more commonly carry other foreign bodies and bacteria with them into the tissues. The anatomical injuries to the thorax are of the same type as injuries elsewhere; they include a central zone of tissue destruction, an intermediate zone of tissue injury, and a surrounding zone of hæmorrhagic infiltration, which merges into an outer margin of active hyperæmia in the tissues still capable of defensive reaction. They are subject to the same bacterial contamination, the same implantation of foreign bodies, as are other wounds.

Injuries of the thoracic parietes alone. These comprise about 10 per cent of chest wounds, and consist of contusions, lacerations and punctures, with or without simple or compound fractures of the ribs, scap-

ula, spine, clavicle or sternum. They are caused by crushing injuries, by the direct impact of spent missiles, and most commonly by tangential injuries from various types of projectiles.

In general such injuries require the same treatment as similar wounds elsewhere—thorough cleansing by a resection of the necrotic and dangerously injured tissues. The most important consideration is to avoid opening the pleural cavity and to protect the parietal pleura from infection. The contused skin and subcutaneous fat do not heal well, particularly if suture is necessary. As a rule wide cutaneous resections are avoidable, but when indicated some plastic flap closure can be made.

Except in the muscles of the erector spinæ group and the muscles attached to the scapula there is relatively little danger of gas gangrene, because the chest muscles are not surrounded by unyielding structures, and are less liable to the pressure anæmia caused by swelling after injury or the constriction of bandages. As a consequence less radical excisions of injured portions of the chest musculature are required than in similar injuries elsewhere.

Fractures are treated upon the same principles as are employed elsewhere. With compound fractures of the ribs particular care is necessary to resect the damaged tissue widely and to avoid additional injury to intercostal structures. Injuries to nerves and blood vessels about the clavicle are repaired as accurately as possible.

Perforating wounds of the parietes occurring so low in the lateral aspects of the chest as to affect only the costophrenic sinuses may occasion negligibly slight intrathoracic disturbances, and yet require thoracotomy to effect deep repair.

Injuries of the spine without cord lesions require particularly careful excision because of the liability to infection due to muscle injury and the presence of bone fragments. Lesions of the cord may demand laminectomy. When paralysis is complete, efforts to obtain primary healing are particularly desirable in order to reduce subsequent distress.

Injuries involving both parietes and viscera. In 10 per cent the visceral injuries are due to force transmitted from the parietal injury without penetration of the parietal pleura. In the remaining 80 per cent the visceral lesion is caused by the projectile or indriven rib fragments. In these cases, whether it has been opened by the primary injury or at operation, it is important that an air-tight closure of the pleura be secured. Minor variations in methods of operation upon wounds of the chest wall, from those outlined above, are determined by the extent of intrathoracic injury, the necessity for performing thoracotomy, and the general condition of the patient. Ideal repair of defects in serous membranes is obtained by an accurate approximation

of serous surfaces without undue tension, because anything foreign to serous surfaces, including other living tissues, is an irritant. When the defects in the parietal pleura cannot be closed by approximation, as frequently occurs with multiple rib injuries, makeshifts must be provided. The best substitute for parietal pleura is visceral pleura. Distended lung is easily stitched to the margins of the defect in the parietal pleura. Injuries low in the flanks quite often require this type of closure; frequently the diaphragm can be utilized, either alone or in conjunction with the visceral pleura. Adhesions about an injured area are unavoidable and their immediate establishment by suture is desirable to reduce the intrapleural effusion. The next best substitute is accurate apposition of the smoothest obtainable muscle surfaces. Failing these a covering may be obtained by using a pedicled skin flap.

Wounds of the diaphragm are always serious because of the added intra-abdominal complications and the occasional pericardial involvement. Those on the right side are commonly associated with a flow of bile from the injured liver into the thorax, which is generally followed by a severe empyema. On the left side there is liability to diaphragmatic hernia. On both sides there may occur a back flow of urine from injured kidneys.

Diaphragmatic defects are best closed so as to effect approximation of serous surfaces on the chest aspect. On the right side the edges everted against the lacerated liver aid in hæmostasis; on the left, the irritation from exposed muscle is better tolerated by the peritoneum than by the pleura. Excision of lacerated edges of wounds in the diaphragm need not as a rule be extensive and should be as limited as conditions permit. Lockwood and Nixon believe that repair of these wounds is more important than that of any hollow or solid abdominal organ. Transpleural repair of the diaphragm is simple and accurate when transperitoneal repair may be impossible.

A consideration of injuries to thoracic contents may be almost restricted to wounds of the lung. Cardiac, intramediastinal, and vascular injuries seldom come to operation. The effects of traumatism, direct or indirect, upon the lung are intrinsic and extrinsic, as they occasion pressure and irritation to the surface by hæmothorax and inflammatory exudates, or pressure within the parenchyma through interstitial infiltration with blood or transudate and by pneumonia. Tissue destruction, injury and infection of the lung are of relatively little importance because of the natural powers of resistance of lung tissue and its remarkable powers of repair, provided it has an adequate blood supply—a factor determined principally by the degree of compression. Operations upon the lung are required to protect the pleural cavity and to make possible an immediate resumption of respiration, rather than to prevent complications in the lung itself.

Injury to the lung, whether caused directly by a projectile or an indriven rib

fragment, or indirectly by the impact of a high velocity projectile, or by sudden variations in atmospheric pressure, is evidenced by parenchymatous bleeding. If the parenchymatous injury is superficial and extends through the pleura a hæmothorax results. Bradford showed that the injured lung is the principal source of hæmothorax.

Though some hæmoptysis is constant, intrapulmonary hæmorrhage is mainly interstitial and usually is limited, since lung tissue is capable of a high degree of spontaneous hæmostasis for bleeding from pulmonary vessels. Hæmorrhage from a freely opened bronchial artery, carrying six times the pressure of the pulmonary circulation, produces a very much more extensive infiltration before the extravascular tension suffices to check the bleeding.

Interstitial hæmorrhage may vary from a slight, limited, plum-colored effusion, which barely interferes with normal aeration, to a true, bright red, traumatic infarction or splenization. The danger from splenization arises from its interference with aeration and with pleural blood supply. Experimental evidence in this respect (Fig. 339) confirms clinical observations. If this brawny hæmorrhagic infiltration extends to the pleura, an intense reaction results. If such an area cannot be aerated with the aid of increased intratracheal pressure the affected portion of the lung is probably permanently injured, even if it be viable. The immediate danger is the production of empyema, a danger sufficient to warrant excision of the affected lung in case of reasonable doubt.

Wounds of the large bronchi are seldom seen as they are usually associated with rapidly fatal injuries. Such wounds produce the rare examples of extensive pneumothorax. A limited pneumothorax constantly accompanies all lung wounds. Occlusion of a large bronchus causes not only a complete atelectasis of the corresponding lung, but leads to a fatal bronchopneumonia and purulent pleurisy by damming back secretions in the affected lung structures. Occlusion of a smaller bronchus causes only an atalectasis in the portion of lung supplied by that bronchus, which is evanescent if the obstruction is not permanent. Compression of bronchi, possibly in part due to muscle spasm, aided by the presence of intrabronchial mucus and blood, leads to a peculiar type of collapse, particularly where there is added some degree of external pulmonary compression. A part of a lobe or an entire lobe may be affected. The lung is flat and quite bloodless, the pleural surface is in puckered ridges and it feels like meat. Reinflation is impossible. There is, as a rule, an associated crushing injury of the overlying parietes without direct injury of the affected lung. This type of injury, carnification, demands excision. Infection of such tissue with anaerobes is the usual cause of the stinking types of pulmonary gangrene.

Wounds of the pericardium and heart and of the vessels within the mediastinum are rarely seen at operation. Hæmopericardium, in addition to causing serositis, diminishes the effectiveness of the heart action. Foreign bodies within the pericardium or mediastinum are obviously dangerous. Injuries to the blood vessels and thoracic duct are recorded. Such early treatment as is possible is too obvious to require discussion.

Injuries involving viscera alone. These are limited to pulmonary collapse and intrapulmonary hæmorrhages with or without a complicating hæmothorax. Their treatment by conservative or radical methods is determined by their severity.

FIG. 339. EXPERIMENTAL SPLENIZATION IN A DOG'S LUNG. The thick fibrinous exudate which formed over the area of splenization in two days indicates a defensive reaction against the irritant.

INDICATIONS FOR OPERATION

The problem may be reduced to two fundamental questions: Does the injury warrant intervention, particularly intrathoracic intervention; and if so, what methods are indicated?

Immediately arise the questions of diagnosis and of prognosis. The nature of intrathoracic injuries can be more accurately and rapidly determined by fluoroscopy than by any other means. The prognosis may be established at the same time.

Injuries involving the chest wall alone usually cause a reduction of motion upon the affected side, and can easily be mistaken for penetrating or perforating wounds if the patient is not examined under the fluoroscopic screen. The danger in injuries of the thoracic walls lies in the liability to subsequent pleurisy by extension, if infection with a virulent organism develops. This danger can be reduced by immediate excision, which is rarely to be regretted and is too often a source of serious consequences if omitted. Exploration of the tracks of rifle bullets showing clean wounds of entrance and exit frequently reveals severe tissue lacerations and unsuspected rib fractures, and occasionally also discloses foreign bodies in addition to the tar drop blood-clots constantly present.

Wounds of the parietes associated with intrathoracic injuries, even more than those involving only the parietes, demand accurate excision and primary suture to prevent the development of empyema. The larger the wound and the greater the destruction the greater the urgency for intervention. Differences of opinion arise over the treatment of lesser injuries. Injuries to the lower margins of the ribs often cause hæmorrhage from the intercostal vessels with bleeding into the chest. Penetrating or perforating wounds caused by small shell fragments and bullets not infrequently cause incomplete fractures of the ribs, with the result that bone fragments are driven through the pleura or into the lung. Even at the wound of exit from the chest bone fragments may project into the pleural cavity, and the intercostal vessels be injured. These slight rib injuries cannot be recognized under the fluoroscope, and frequently escape detection when plates are made. From these considerations it is believed that virtually all wounds of the chest wall should be treated by radical operative methods, though not necessarily by thoracotomy.

Indications for performing thoracotomy to cope with intrathoracic lesions are of three groups: (1) Those based upon pre-operative findings; (2) those based upon operative findings; (3) uncomplicated hæmothorax.

Indications based upon pre-operative findings. This group includes retained foreign bodies, unless very small, particularly if they are free in the pleural cavity; extensive splenization (Duval), or serious hæmorrhage appearing externally; suspected wounds of the diaphragm (Lockwood and Nixon); and acute infection (Gask).

Indications based upon operative findings. Gask in particular advocated proceeding with operation within the chest when parietal operation disclosed serious internal lesions. Duval's axiom, "The general rules of surgery must be applied to wounds of the lung," gained wider recognition as the timidity of surgeons decreased.

Hæmothorax. If hæmorrhage may be called a wound complication hæmothorax is the commonest and most important complication of chest injuries. Reports upon thoracic injuries by internists center about hæmothorax, its physical signs and symptoms, the best time and method of aspiration, and the late complications. Lockwood during his active work saw its dangers, although he felt they were insufficient to warrant thoracotomy. Gask in a postbellum report was unprepared to say that simple hæmothorax of moderate size should be treated by operation. At the close of the war there was a growing sentiment in favor of open operation in the treatment of extensive hæmothorax, particularly if massive clotting had occurred. With a limited hæmothorax aspiration remained the method of choice, as it led to an early recovery and return to duty.

The arguments against operative treatment of hæmothorax are that conservative treatment, early aspiration with air replacement as advocated by R. Bastianelli, or aspiration after from seven to ten days with or without oxygen replacement, give better results, particularly a lower immediate mortality rate, and reduce the pressure upon surgical facilities during periods of active fighting. The indications from the standpoint of morbid physiology are definitely for the earliest elimination of pleural irritation and pulmonary compression, the inevitable consequences of hæmothorax and pneumothorax.

Hæmothorax is of itself seldom sufficient to cause death either through pressure or acute anæmia. The large amount of bloody fluid which is present after a few hours, its dilution as compared to normal blood, its liability to increase after active hæmorrhage has ceased, prove that a pure hæmothorax has a transient existence, and that it is only a few minutes before a secondary pleuritic effusion is added. In the presence of clots there is still more intense irritation, a fact which led Elliott, Davies and others to advocate open operation for their removal.

Later results of hæmothorax are equally serious. Bradford noted a decreased absorption rate of fluid and gas from the pleura attributable to the fibrinous exudate and possibly to decreased motion. Delayed absorption of hæmothorax has been repeatedly mentioned, and, according to Davies, it is far from being the exception. Absorption is not always promoted by aspiration, as evidenced by the case reported by Tuffier of a hæmothorax which persisted for fifteen months in spite of 29 aspirations.

As the result of pulmonary compression, vicious adhesions, thickened pleura and an immobile diaphragm, there is deficient expansion, shoulder drop, scoliosis, parenchymatous sclerosis (Tuffier), and incapacitating dyspnœa. This dyspnœa may last for months or even years and, according to Leslie, is largely dependent upon the degree of permanent collapse of lung tissue.

The possibility of secondary infection of a hæmothorax adds another and more dangerous complication. Gask found that nearly all war wounds are con-

taminated. Soltau, in his studies of empyema, found gas producing organisms in 48 per cent, streptococci in 40 per cent, and organisms from the lungs in 12 per cent of cases. According to Elliott one-fourth of the cases of hæmothorax became septic no matter what type of missile caused the wound; of these one-half died, and one-third of those who recovered were invalided out of the service, making a total of 16 per cent in which death or incapacity was due to infected hæmothorax. Moreover, it is difficult to recognize the presence of infection in a hæmothorax since a simple hæmothorax usually runs a febrile course and because the bacteria, as pointed out by Leslie, may be in the clotted portion of the exudate, so that the fluid portion obtained by aspiration may remain sterile. Open drainage was generally held to offer the best chance of recovery from this type of pleurisy, though Gask recommended thoracotomy with mechanical pleural cleansing and immediate closure. Statistics are not available to indicate the proportion of the 75 per cent of cases of hæmothorax which did not become infected and yet contributed to death and incapacity through pleural irritation and pressure. The total loss in man power due to hæmothorax can be reasonably estimated at from 25 to 35 per cent of those receiving intrathoracic injuries.

If it be granted that thoracotomy has become a safe operation, then cumulative evidence indicates that immediate open operation is the sane treatment for all but the limited degrees of hæmothorax, even if restricted to the removal of the liquid and coagula. In addition the lung injuries can be accurately repaired, foreign bodies removed, the inside of the thorax inspected and needed attention given to additional injuries not otherwise recognizable. It is still more significant that after these precautions have been taken the lung may be inflated to normal limits and the chest closed, with an immediate return of nearly normal respiration and circulation, factors which provide the most favorable conditions for defense in a contaminated pleural cavity, and assure the earliest resumption of activity.

The splendid results reported by Bastianelli in treating chest wounds by immediate aspiration and air replacement, reinforced by the wide acceptance of the value of artificial pneumothorax in the treatment of certain types of pulmonary tuberculosis, demand a reasonable answer.

According to Bastianelli, the cushion of air separating the visceral and parietal surfaces prevents the formation of pleural adhesions, and the positive intrapleural pressure controls hæmorrhage from the wounded lung. Recovery is prompt because vicious pleural adhesions are prevented, and the repair of the lacerated lung is fostered by its immobility and collapse.

Opposed to these theories are definite facts. Air is a serous membrane irritant and elimination of irritation is a basic principle in the prevention as well as the treatment of pleuritis. Positive intrapleural pressure high enough to stop hæmorrhage by pulmonary compression, collapses the homolateral lung, produces contralateral emphysema, and interferes with pulmonary circulation. Collapsed lung means contracted lung which is difficult or impossible of reinflation. If reinflation occurs a universal adhesive pleuritis is certain. The exact conditions for minimizing the resistance to the flow of blood through the lung as established by Cloetta, a reduction of mean pulmonary inflation, are met by diaphragmatic paralysis. Diaphragmatic paralysis lasting four or five days can be established by infiltrating the phrenic nerve trunk with 1 per cent cocaine. If this procedure be coupled with closure of the chest without residual pneumothorax, the best conditions for repair and defense have been provided for both lung and pleura.

SURGICAL METHODS

Pre-operative treatment. An individual with a recent chest wound is in need of immediate physical and psychic rest. This can be provided by administration of a full physiological dose of morphine (gr. 1/3 to 1/2) to reduce the coughing and to minimize respiratory effort. Care should be taken in examining and dressing the wound to permit the most comfortable position and to avoid exertion on the part of the patient. First aid should be restricted to hæmostasis in the parietal wound, and temporary closure of an open thorax. The latter is best accomplished by strapping a firm, thick broad pad over the wound with adhesive plaster, and then fixing a tight swathe about the chest. Provisional suturing of these wounds often leads to tissue emphysema, which interferes with the circulation and materially reduces resistance.

A second dose of morphine, from 1/4 to 1/2 grain, is given one-half hour before operation. If there is no question of an abdominal wound water or hot drinks should be given freely, even just before anæsthesia begins. Smoking is a great solace and does no harm if coughing has ceased. Anything to reduce distress is desirable.

Uncomplicated chest wounds are not prone to produce shock, but when there is considerable pulmonary compression they cause a high venous pressure due to interference with pulmonary circulation. If intravenous medication is indicated it must be given very cautiously in order to protect an overburdened right heart. It is often wiser to give a transfusion of blood after reinflation has been established at operation. A grave anæmia is often masked by an unusual distribution of blood because of the reduced content of the compressed pulmonary vessels. A blood transfusion after the evacuation of a large hæmothorax and after satisfactory hæmostasis has been effected will materially reduce danger.

A diagnosis of the probable nature and extent of intrathoracic involvement is furnished by physical and fluoroscopic examinations. One should determine if possible the extent of hæmo- and pneumothorax; the presence of extensive intrapulmonary hæmorrhage, the presence of extensive clots, the evidence of contralateral injury, the size, position, and motility of retained foreign bodies, the presence of bone injuries, the position and mobility of the diaphragm, the size and position of the heart, and the probable path of the missile.

A moderate sized hæmothorax where there are no adhesions darkens the whole side of a chest when these patients are examined in a recumbent position. Clots when visible are apt to be seen low along the spine and do not move. Intrapulmonary hæmorrhages can only be seen when the

hæmothorax is limited. The shadow corresponds to a lobe and moves with respiratory effort. Contralateral involvement, except for mediastinal displacement, is uncommon. Gask warns against operation when there is evidence of contralateral collapse, but the danger of this complication is avoided when positive pressure anæsthesia is used. The location of foreign bodies is important when they are small and show by transmitted motion that they are close to important vessels or the heart. Otherwise there may be a temptation to omit removing them. Their position usually changes when the chest is opened, but as a rule foreign bodies are easily found. Positive evidence of bone injury is valuable; negative evidence is worthless. Its presence must be assumed until disproved by actual exposure at operation. The position and movement of the diaphragm help to determine the presence of injury of that structure and the level of operative incisions.

The heart's position is an excellent index of mediastinal deviation; the size of its shadow may tell of cardiac or pericardial injury. Projection of lines between the wounds of entrance and exit in perforating injuries or between the wound of entrance and the missile in penetrating injuries indicates the structures probably involved. The character of the injuries may be guessed from the size and shape of a retained shell fragment or, in the case of a bullet, from its shape and path.

Anæsthesia. It is usually held that the use of differential pressure is unnecessary. We do not hesitate to express our conviction that positive pressure anæsthesia, or better analgesia, is the most important single factor in successful thoracotomy under war conditions.

A full pre-operative dose of morphine permits induction of an even, deep analgesia with nitrous oxide and oxygen without increasing the gas-oxygen ratio above 3:1. This was proved by Cannon's observations to be the limit of safety in the presence of shock. After the induction stage the proportion of nitrous oxide can be reduced occasionally to less than 50 per cent.

The American Red Cross nitrous oxide-oxygen apparatus devised by Gwathmey fulfilled every requirement. A rough gauge to measure the flow of gases, a mixing bag to serve as a pressure indicator, and a close-fitting face piece are the only essentials. Pressure is furnished by the gas and oxygen tanks, controlled by regulating the flow of the gases and delivered to the trachea by holding the face piece snugly in position. The pressure can be varied as gradually or as suddenly as desired. The physical effort required is not great.

The dangers are real. Anæsthetics delivered under pressure are more rapidly taken up by the blood. The more rapid absorption is due to increased ventilation and not directly to the pressure itself. Anæsthetics

when given under pressure in undue concentration produce toxic effects which can appear suddenly and be rapidly fatal. A second danger is too great pressure. Normal heart and lungs can tolerate an excess pressure, but when the heart muscle and pulmonary circulation are both impaired the margin of safety is much narrower. In general, positive pressure up to 16 mm. of mercury is safe and suffices for all purposes. Beyond that point compression of the pulmonary capillary bed can provoke an acute dilatation of the right heart. A few control observations with a manometer in the circuit show the degree of distention of the mixing bag which corresponds to a pressure of 16 mm. of mercury. It is rarely necessary to exceed this limit.

In practice the analgesia and hypertension are gradually induced with the patient in position for operation (Fig. 340). During the induction stage nothing is done to the wound. When deep analgesia has been reached dressings are cut away, and the skin prepared by dry shaving and scrubbing with ether. By this time inflation has been accomplished, so that uncovering a sucking wound occasions little increased respiratory distress.

Various stages of operation can be carried out under the same light anæsthesia and the pressure varied as required. Repeated inflation and deflation do not cause variations in the systemic blood pressure which can be detected by clinical methods. Both sides of the chest can be opened without evident distress to the patient. Graham and Bell showed that if an opening in the chest wall of dogs exceeds certain dimensions the aspiration of air into the lungs ceases. The exact estimations of the size of the opening compatible with life in dogs hold relatively true for men and are the more accurate as man's circulation is deficient, *e.g.*, with shock or acute anæmia, where the powers of circulatory compensation are materially reduced. The use of positive pressure obviates this complication, as well as most of the coughing and dyspnœa which occur when a chest is opened, particularly when a considerable hæmothorax is present.

Another important point is the avoidance of traction upon the mediastinum. Traction upon a lung can cause a rapid drop of blood pressure of 40 mm. or even more. A deflated lung cannot be dislocated, nor brought outside of the chest from a position of collapse without traction, but a deflated lobe can be guided toward the thoracotomy opening and delivered without the least traction as inflation is produced.

Clinical results are confirmatory. Patients anæsthetized under positive pressure as a rule leave the operating room in better condition than at entrance, and the improvement is not evanescent. Operations need not be hurried. After the wound is closed the nitrous oxide is stopped and oxygen under decreasing pressure is given for the few minutes required for the return of consciousness.

The contrary opinions held by other surgeons, notably Gask, Duval, Depage, and Lockwood, who advocate open anæsthesia or local anæsthesia, are not to be discredited by mere assertions. Surgeons using their methods worked in the same units with operators using positive pressure gas and oxygen analgesia. According to medical officers in charge of chest wards patients of the former were less comfortable and had a more protracted convalescence.

Excision of parietal wounds. Among the objections to routine excision of all chest wounds are the dangers of anæsthesia, and the time and extra nursing required. The use of gas as described is a satisfactory answer. Positive pressure is a cure and preventative of pulmonary collapse. Pneumonia after its use is infrequent. Excisions can be done more thoroughly, rapidly, and without the distress of local anæsthesia. Accidental opening of the pleural cavity is of little moment, as deflation does not occur and the pleural rent can be accurately repaired.

Disclosure of unsuspected deep injuries is a common experience when parietal wounds are excised as a routine. Frequently a sucking wound is hidden by change of posture so that an open thorax may be suddenly encountered. Parietal excision should always be undertaken with a view to primary closure; with a penetrating injury this becomes obligatory.

A satisfactory method of muscle excision consists in splitting between muscle bundles on either side of the injured area and carrying this splitting for some distance in both directions before dividing transversely. This block resection permits the later approximation of smooth surfaces at the point of injury, removes the cut fibers farthest from this point and interferes least with blood and nerve supply. Excision done in this manner, often restricted so that bruised muscle was retained in order to make closure possible, was not followed in our experience by gas gangrene in chest wounds in a single instance, though gas gangrene occurred in other wounds in several patients with multiple injuries.

Fractured ribs should be widely resected and, when possible, the cut ends should be snugly covered with soft tissue, periosteum, or muscle, to reduce the chances of bone infection by obliteration of the dead space. Fractures of the scapula, particularly those caused by shell fragments, are less easily managed. Wide resection is indicated, but the bony framework and periosteum should, if possible, be preserved to make regeneration possible. Denuded bone must be removed; pockets should be collapsed to obliterate dead space. Injuries to the sternum are easily cleansed with gouge or rongeur. Compound fractures of the spine require adequate exposure, radical resections, and great care in removing loose fragments. Bone fragments are the most dangerous foreign bodies in the presence of infection. Excision of skin should secure a clean margin that bleeds freely and nothing more. It is safer to take chances with slightly traumatized skin than to run the risk of necrosis from excessive suture tension.

Thoracotomy. Positive indications for thoracotomy will generally be recognized before operation. Occasionally a decision will rest upon operative findings. A bullet may perforate a rib without causing a complete fracture and carry with it splinters of the compact, inner layer into the lung; or, there may be an unrecognized comminuted fracture of the ribs associated with pleural and pulmonary lacerations and only a moderate hæmothorax. Similar and even more extensive injuries may be found in the wound of exit. Usually the question is how to proceed rather than whether or not to operate. Three possibilities are offered: first, to do a limited thoracotomy at the entrance and exit wounds, a compromise between radical operation and aspiration; second, to proceed through the wound and resect the ribs widely enough to give the approach needed for deep repair; third, to repair the entrance and exit wounds and then to open the chest through uninjured tissues at a point of election.

1. By limited thoracotomy we mean intrathoracic operations performed through the wounds of entrance or exit with little or no additional enlargement, never enough to permit exploration of the pleural cavity. It is indicated when wounds are small, when destruction is relatively slight, and when the lung can be reinflated. In the absence of hæmothorax inflation of a deflated lung causes the wounds of entrance and exit in the visceral pleura to approximate the corresponding wounds in the parietal pleura. A metal nozzle (Fig. 344) attached to a Potain aspirator is introduced through the opening in the parietal pleura, and the fluid blood removed by directing the tip into various dependent pockets while the lung is partly deflated. When inflation is produced the visceral injury floats up to the parietal. If it is small and dry it need not be repaired. If it is bleeding the lung can be secured by forceps at the margin of the wound, and a cone of lung with the wound at the apex can be gently brought out through the opening in the parietal pleura. A purse string suture closure as in intestinal perforation suffices. If there has been some rib injury, and bone fragments have been driven into the lung, a small incision through the posterior layer of periosteum exposed by the rib resection will permit excision of the lacerated lung tissue and removal of the bone fragments. After the lung is repaired it is wise to suture the lung wound into the defect of the parietal pleura. Adhesions between these areas are certain under any condition and are restricted by this fixation. This simple method is particularly useful in through-and-through wounds, but less so in penetrating wounds. It can be applied in about 40 per cent of all chest injuries, the proportion varying with the type of fighting. The defects of this method lie in the possibility of leaving clots behind and of overlooking rib fragments.

2. The majority of more serious chest injuries permit no latitude in selecting the most desirable route for surgical approach. Parietal excision and repair alone are a burden to a man in weakened condition, so that the intrathoracic repair must be attempted by enlarging the wound of entry. This avenue of approach gives a more or less unsatisfactory deep exposure, usually better for diaphragmatic injuries than for pulmonary because a retracted, compressed, and uninflatable lung cannot be manipulated readily. As a rule there is a tendency to do too little under these trying conditions. A desire to avoid immediate death is apt to prevent the removal of injured lung whose presence is incompatible with ultimate recovery.

Methods of gaining deep exposure are determined by the necessity of

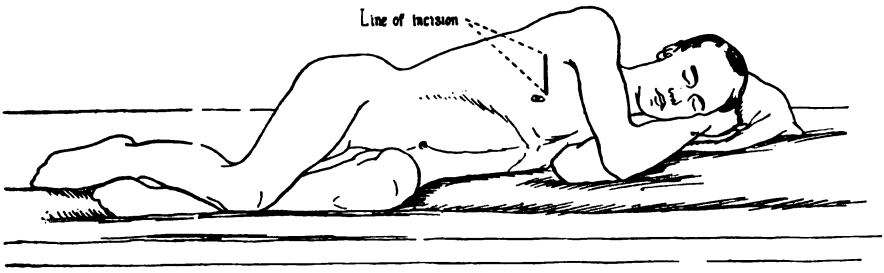

FIG. 340. PATIENT IN POSITION FOR OPERATION. Line of incision for a thoracotomy of election.

getting a satisfactory parietal closure. The preservation of parietal pleura is most essential. This layer is no more amenable to plastic surgery than a wet drum head. Each injury is a separate problem, the most desirable solution of which is an approximation of the type of repair described in the elective operation.

3. Thoracotomy of election is designed to give free access to one side of the chest in order to permit the dislocation and manipulation of each lobe of the lung, and repair of the diaphragm. It may be performed before or after the parietal excision, depending upon the type of injury. The chest must be opened on a level with the root of the lung and in a manner favorable to closure. Intercostal incisions are easiest to make but give less satisfactory exposure, and their healing is less certain. Cowell designed an intracostal incision which has much to recommend it when deflation is present, but which is not applicable when inflation is relatively normal. Rib resection can be done very quickly and safely, gives a maximum exposure with minimum damage and provides the best opportunities

for repair. A piece of the fourth or fifth rib, slightly longer than the width of the operator's hand, is removed so that the mid-point of the

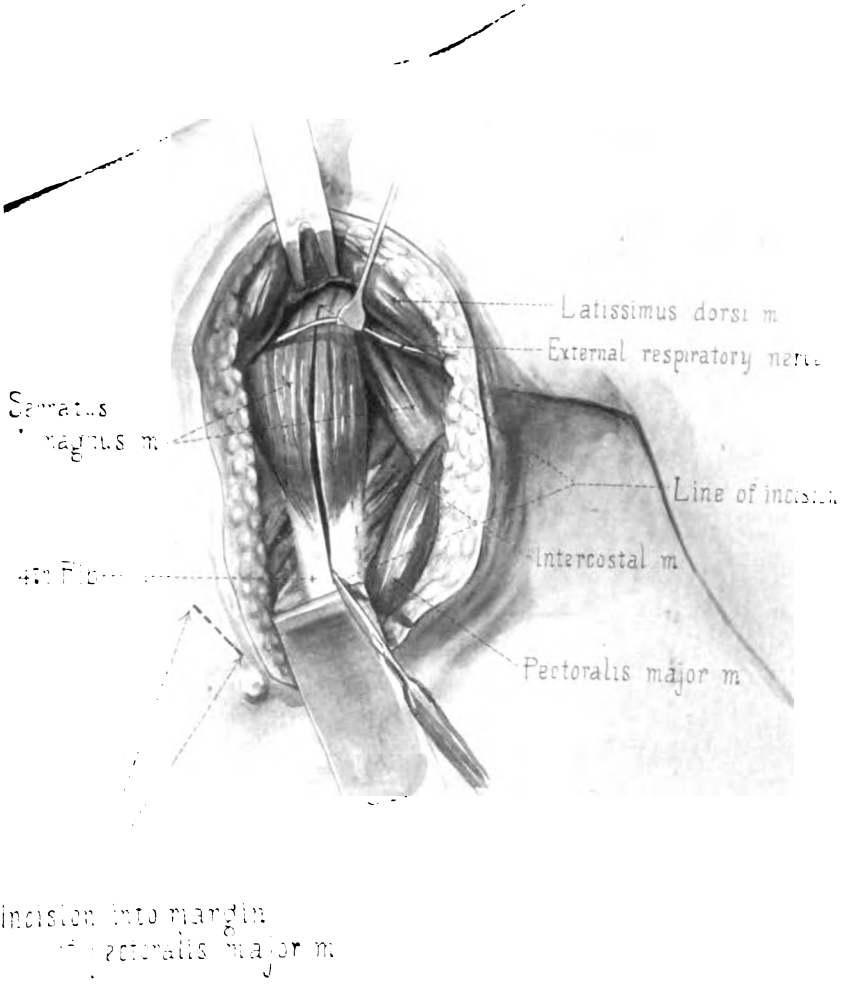

FIG. 341. METHOD OF EXPOSING A RIB FOR RESECTION. The serratus is incised parallel to its fibers; the long thoracic nerve is retracted posteriorly.

defect is slightly nearer the angle of the rib than the sternum. In this area one may secure the maximum effects of rib rotation with the greatest separation for operation and the greatest approximation for closure.

The skin is incised directly over the rib selected (Fig. 340) and the rib exposed. A short cut in the lower margin of the pectoralis major permits this muscle to be retracted medially. The latissimus dorsi is easily freed and retracted laterally. The long thoracic nerve can usually be saved. Incision of the periosteum along the midline of the rib is continued posteriorly between the fibers of the serratus magnus (Fig. 341). The periosteum is separated with care to avoid injuring the intercostal vessels and nerve. After rib resection the posterior periosteum and

FIG. 342. *a*, SIMPLE TYPE OF RIB SHEARS. *b*, BONE BITING FORCEPS FOR CHEST SURGERY. The severed bone fragments are held in the bite of the forceps and cannot be sucked into the pleural cavity.

parietal pleura are incised along the midline, the incision extending to within a half inch of the rib ends (Fig. 341). The release of tension by this incision permits the intercostal muscles to retract and allows the ribs next above and below the incision to be rotated upon their axes and increase the exposure. A wider opening can be obtained by increasing this rotation by outward traction. Exposure thus obtained is quite as good as that provided by a mechanical rib spreader (Fig. 343, *a*), which crushes the intercostal muscles and thus interferes with subsequent healing. Lockwood believes that the use of rib spreaders adds to shock. A headlight makes it possible to continue most of the intrathoracic work under visual control.

It must be borne in mind that this operation is undertaken in addition to excision and suture of the parietal wound or wounds. Its advantages are obvious. The disadvantages are the longer time required, and the creation of another wound in the parietal pleura opposite to normal visceral pleura, which assures the formation of dense adhesions in an area where otherwise only slight adhesions would develop (Fig. 338).

Cleaning the pleural cavity. Removal of the uncoagulated blood and exudate is effected without delay as clotting occurs very rapidly

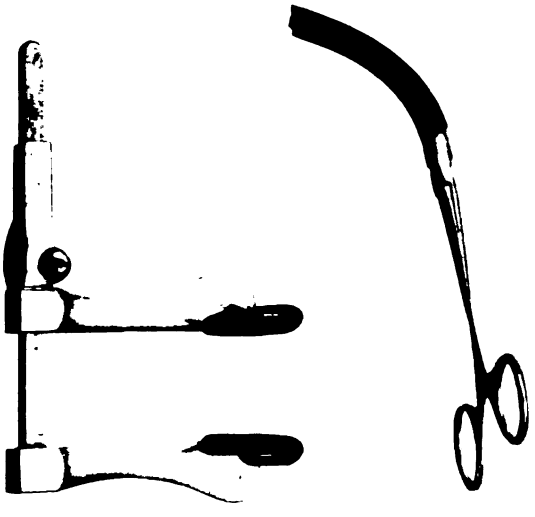

FIG. 343. *a*, TUFFIER'S RIB SPREADER. *b*, THIN BLADED CLAMP USED TO SECURE HÆMOSTASIS, AND AS A TRACTOR.

after operation is begun. A curved metal or glass nozzle (Fig. 344) fitted to a Potain aspirator, which is long enough to reach all parts of the chest, is satisfactory if the distal end is flanged and protected by a coarse meshed sieve to prevent the aspiration of large clots which would plug the tube and to prevent injury of the pleura.

The first aspiration is done with the lung deflated in order to facilitate introducing the tip of the nozzle into the various depressions where fluid may accumulate. During the period of deflation it is wise to remove clots which may be covering injuries or foreign bodies and may be less accessible later. Dense clots can be lifted out with forceps or manually. The balance must be mopped out with moist gauze. However gently this is done an undesirable irritation is produced.

An important part of cleansing is the prevention of soiling. Skin edges should be covered with moist gauze. As soon as the pleura is opened the parietal wound should be covered with more gauze, which is held in place by the retractors and by clips. The field of operation should be isolated by gauze pads even more carefully than in abdominal surgery.

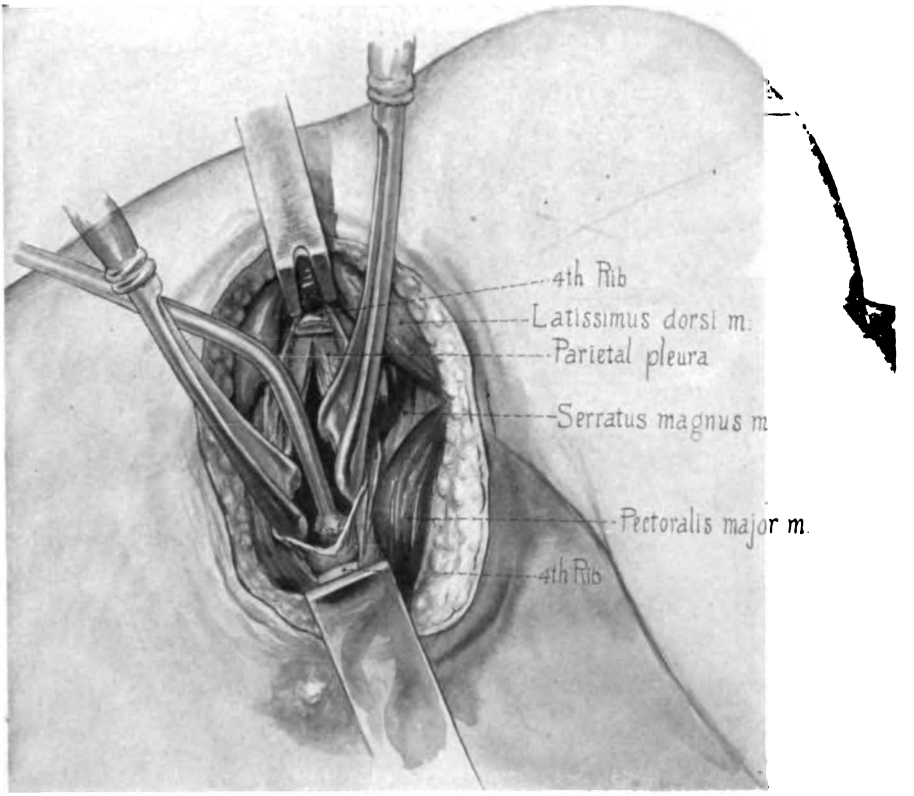

FIG. 344. THORACOTOMY OF ELECTION. A rib has been resected; the tip of an aspirating nozzle is being introduced into the pleural cavity.

Thoracotomy, however simple, is followed by the production of excess serous exudate. Every effort should be directed to the limitation of this effusion and to protect it from infection. The chest should be made clean and dry before closure and no irritants, like bone fragments, clots, bare ribs, or exposed muscles, should be overlooked. Washing out the pleural cavity is a temptation to be resisted as the subsequent healing is poor. Mopping gently with moist gauze gives the best results.

Blocking the phrenic nerve. Natural methods of defense have proved that immobility of the diaphragm provides conditions essential to pleural resistance. These consist in providing an adequate reduction of



FIG. 345. *a*, COW HORN RIB STRIPPER. *b*, TUFFIER'S LUNG FORCEPS. *c*, PERIOSTEAL ELEVATOR.

motion and in assuring the optimum circulation of blood in the lung. Cloetta's experiments show that the least resistance to pulmonary circulation is present when the maximum negative intrapleural pressure is reduced to 20 mm. of water (1.5 mm. of mercury), and that at this pressure the lung contains the largest volume of blood. Middleton found that in dogs an immobilized diaphragm provides this reduction. Experimental

and clinical observations prove that recovery from thoracotomy when the phrenic nerve is blocked is more rapid, more certain and less painful than when it is not blocked. Operation is less difficult in the presence of an immobile diaphragm, particularly because acute pneumothorax causes increased respiratory efforts.

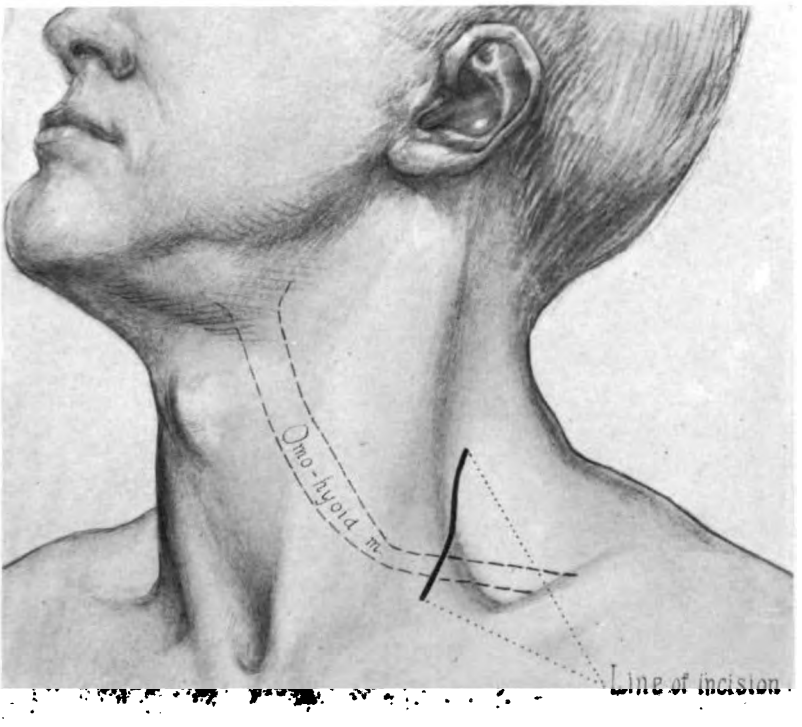

FIG. 346. INCISION FOR EXPOSURE OF THE PHRENIC NERVE.

One per cent cocaine injected in the trunk of the phrenic nerve causes a paralysis for four or five days. It materially reduces distress by blocking the sensory fibers described by Capps. Novocaine, quinine and urea hydrochloride, and magnesium sulphate are unsatisfactory for this purpose.

When the phrenic trunk can be reached through the thoracotomy exposure it should be injected before intrathoracic operation is attempted. If it is suspected before operation that intrathoracic injection will be impossible the nerve may be injected in the neck. Cervical exposure of the nerve is exceedingly simple and can be accomplished with little dis-

tress under local anæsthesia. The illustrations (Fig. 346 and 347) show a larger exposure than required. It may be accomplished largely by blunt dissection with little hæmorrhage. Relief of much of the intrathoracic pain following injection of the nerve suggests that blocking of the phrenic

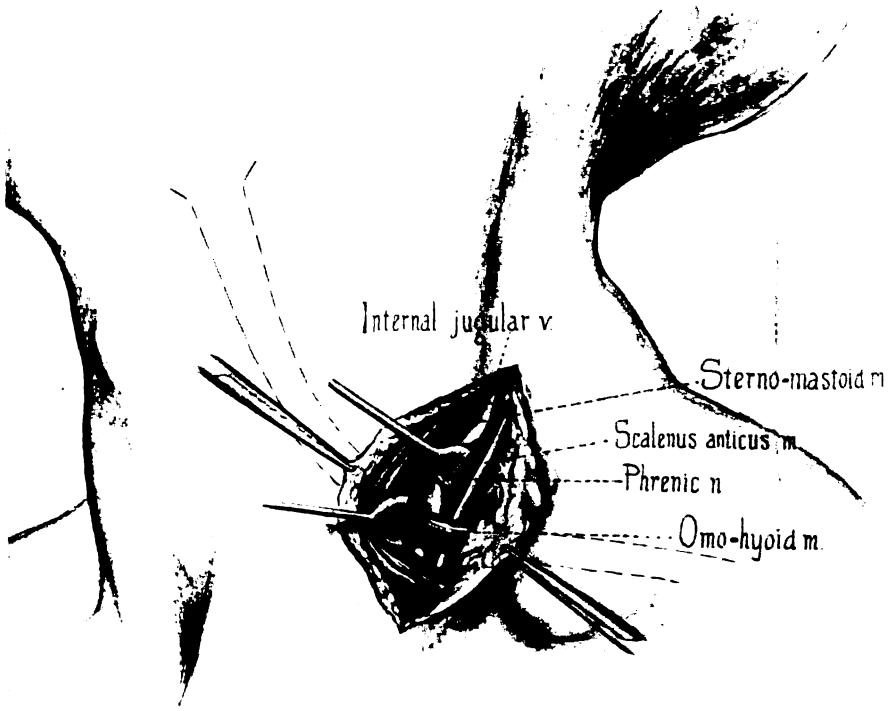

FIG. 347. EXPOSURE OF THE PHRENIC NERVE.

nerve should be considered an important step in postoperative treatment, if it has been neglected at operation or if convalescence is delayed.

Blood transfusion. The indications for blood transfusion are largely those of acute anæmia, so that the use of gum salt solution is to be considered only when suitable donors are unavailable. Transfusion should be started as soon as hæmostasis is complete and inflation can be maintained. The blood must be introduced slowly. No harm comes from transfusion given in this way. Many lives can be saved. Army medical

organizations should undertake further studies of methods of preserving blood for transfusion and develop a system for providing donors in the forward areas where they are most needed.

The large amounts of blood removed in cases of hæmothorax suggest the possibility of aspirating it into sterile bottles containing sodium citrate, filtering, and giving it as an autotransfusion. Tests, however, showed that the attendant risks are too great.

Operations upon the lung. Operations upon the lung are undertaken primarily to protect the pleura. Accordingly accurate hæmostasis and surgical repair must be obtained in such a fashion that immediate inflation and resumption of respiration may be established in order to insure re-apposition of pleural surfaces and an unimpaired blood supply. These conditions require freedom from internal and external compression. In general, lung tissue which cannot be inflated or which is devoid of blood supply is actually or potentially a foreign body whose presence is virtually certain to produce an empyema. Excision of such lung, whether or not it has been directly injured, must be considered the ideal treatment, and is demanded whenever the location and extent of the affected area indicate the probability that the consequent empyema will be fatal. Our personal experience is the basis for this radical statement. No individual recovered where there was failure to excise permanently injured lung. Not all individuals recovered where this excision was done. Postmortem evidence showed that the unexcised lung had contributed to the fatality, but not that excision *per se* could be blamed for the death.

Perforating wounds caused by rifle bullets and small shell fragments require closure of the pleural defects only when there is bleeding after inflation. They may be inverted with a purse string suture if they are accessible. Penetrating wounds are similarly treated. The missile is usually found without difficulty and frequently lies close to the surface. A small pleural incision and a little dissection with a pair of blunt nosed forceps makes removal easy. Small shell fragments close to big vessels should be carefully removed to obviate the dangers of late hæmorrhage.

Large lung wounds are usually tangential and are surrounded by more hæmorrhagic infiltration than the smaller. The amount of excision required is determined by the degree of internal compression (infiltration). If the lung reinflates completely, trimming the shaggy margins of the defect with scissors and wiping them off with gauze is sufficient. If there is a zone of splenization about the wound which does not inflate or bleed freely, resection must be carried back to margins which are comparatively normal. It is not merely the repair of lung parenchyma which is to be considered. The integrity of the corresponding visceral pleura is of far greater immediate significance.

A lung is collapsed when it does not expand with the restoration of negative pressure. An atelectatic lung is airless because of the failure of air to enter the lung and the absorption of the air previously present. Carnification is a permanent atelectasis plus a virtually complete anæmia, a traumatic anæmic infarction. Intratracheal hypertension anæsthesia makes a positive diagnosis of these lesions. Lung tissue which is atelectatic and cannot be inflated must be removed.

These intrapulmonary lesions are well shown in a drawing (Fig. 348) of a right lung removed at autopsy from a man who arrived dead at a field hospital. A jagged tangential wound was present in the inferior margin of the lower lobe. There was splenization of nearly the whole lobe. The middle lobe, except for one irregular area of hæmorrhagic infiltration, and the entire upper lobe were emphysematous. The upper part of the lower lobe was atelectatic, brownish in color and was approaching carnification. The colored diagram (Fig. 339) shows the effect of experimental splenization. The marked fibrinous exudate upon the pleura over the area of hæmorrhagic infiltration is proof of a defensive reaction. The limitation of the exudate to the damaged lung is evidence that such lung is especially dangerous in the presence of infection.

Resection of a part of a lobe should be roughly pyramidal or wedge-shaped with the narrow aspect of the wedge toward the hilus, in order to remove only the parenchyma supplied by a bronchus and its associated vessels. It may be likened to cutting a dead branch out of a bush. Positive pressure makes this possible by clearly outlining the limits of normal lung.

Resection is only difficult when exposure is unsatisfactory. In the thoracotomy of necessity dislocation of a lung is difficult because these operations are usually done at a lower level, and since the lung is generally less pliable because of more severe injury. Under these conditions some traction is unavoidable. It may be secured by a loop of gauze placed around the root of the lobe to be dislocated and caught with a clamp; or a special forceps (Fig. 343, *b*), like an enterostomy clamp, may be placed proximal to the margin to be removed and the resection carried out distal to the clamp. This is a makeshift procedure but makes possible fairly accurate work.

Thoracotomy of election presents the most satisfactory exposure of the lung. After the chest has been opened as described above and the lung injuries have been determined, the lobes can be delivered into the wound for operation without traction. During deflation a free margin of a lobe is grasped gently with forceps of the Tuffier type (Fig. 345, *b*) and guided toward the parietal opening. As the anæsthetist increases the positive pressure this lobe follows the forceps into the wound (Fig. 349). Ma-

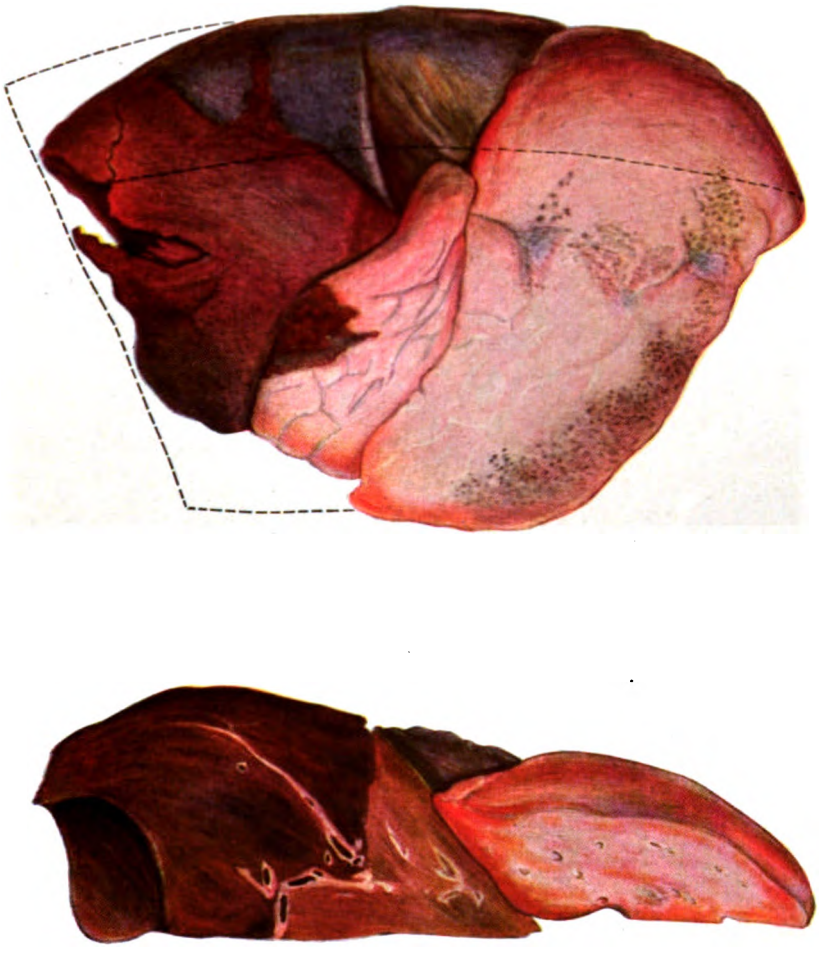

FIG. 348. LACERATED WOUND OF THE LOWER LOBE OF THE LUNG. The lower lobe is almost entirely splenized; the upper portion of the lower lobe is carnified; the upper lobe and middle lobes, except for one area of hæmorrhagic infiltration, are emphysematous.

nipulation with suitable variations in pressure allows the selection of the most satisfactory position for operation. Little traction is required to maintain this position, which is preserved by the requisite inflation and the gauze packed between the lobe and the superficial wound.

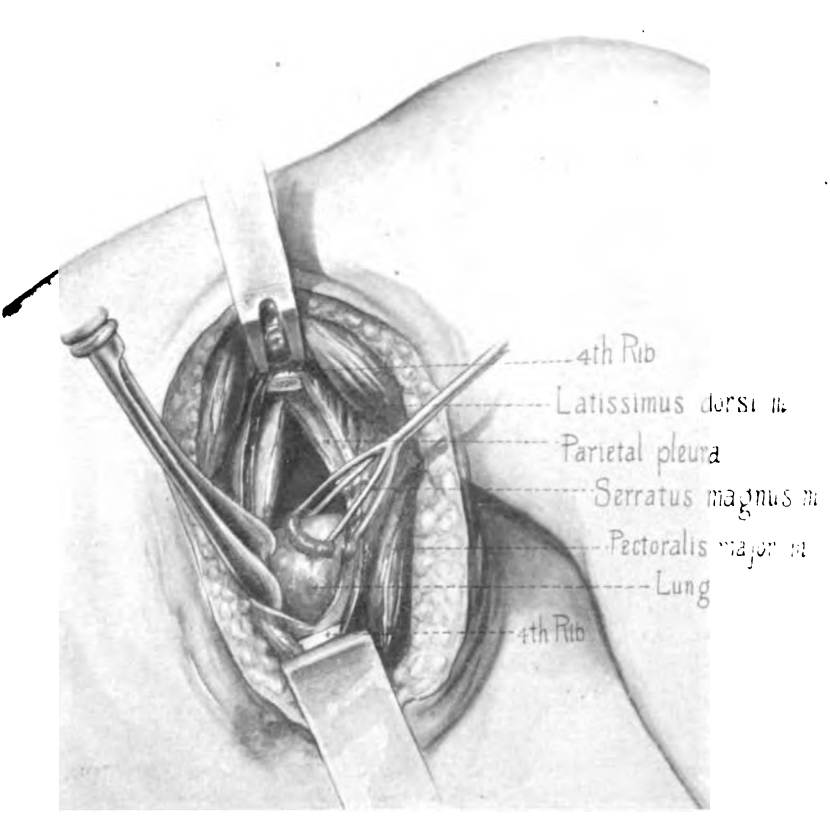

FIG. 349. THORACOTOMY OF ELECTION. The margin of the deflated lung being guided toward the wound with Tuffier's forceps.

A wedge-shaped resection is made through the margins of normal or relatively normal lung. Hot compresses to the cut surfaces check excessive bleeding while clamps are applied. Severed bronchi that can be seen or that provoke active bubbling must be secured. All branches of the bronchial artery spurting red blood under high pressure must be clamped. It is necessary to secure only the more actively bleeding branches of the pulmonary artery and but few branches of the pulmonary veins.

Pulmonary inflation makes possible the accurate clamping of these various structures, which would be difficult or impossible to find in deflation. Mass sutures inserted and tied while the lung is inflated would become too loose in deflation; if tied in deflation they would be too tight during inflation. Consequently multiple fine sutures must be used to approximate the cut surfaces.

The number of sutures required may be reduced if the vessels which have to be tied are ligated in conjunction with a suture (Fig. 350). The

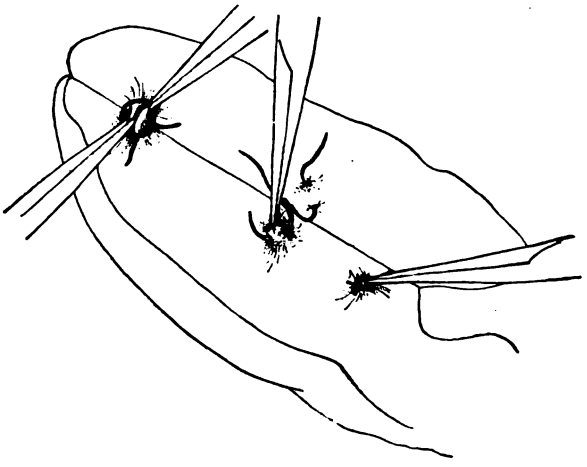

FIG. 350. METHODS OF REDUCING THE NUMBER OF STITCHES USED IN REPAIR AFTER A RESECTION. At the right is a simple ligature; in the middle, a suture on one surface is combined with a ligature on the opposite side; on the left a double ligature is being made to serve as a suture.

pleural repair should become an exaggerated serosa to serosa approximation as a safeguard against air leakage. A fine catgut stitch of the Cushing type introduced one-half inch from the margin of the incision accomplishes this satisfactorily. Little puckering of the lung need result and only one knot should appear upon the pleural surface (Fig. 351). When resection includes two surfaces of a lung it is easier to suture the dependent pleural layer first, when it can be done more rapidly and from the inside, and then to reconstruct the lung upon this plane.

Lung repaired by this method heals splendidly and with the minimum of scar tissue. Duval states that the scar may be impossible of detection microscopically. There is in consequence little influence upon pulmonary elasticity. Vicious union is prevented so that the functional result is nearly perfect.

Complete lobectomy is indicated when an entire lobe is carnified. The possibilities of recovery are slight, not because of the operation but on account of the other serious injuries which are usually associated with these lesions. Treating the stumps of bronchi is a simple procedure in military surgery because, aside from the injury, tissues are normal and individuals healthy. Crushing with forceps and ligation seems to be satisfactory if an ample flap covering is provided. The unusual wounds of large bronchi should be sutured directly, and the suture line reinforced by a pleural graft to give additional protection against empyema from leakage.

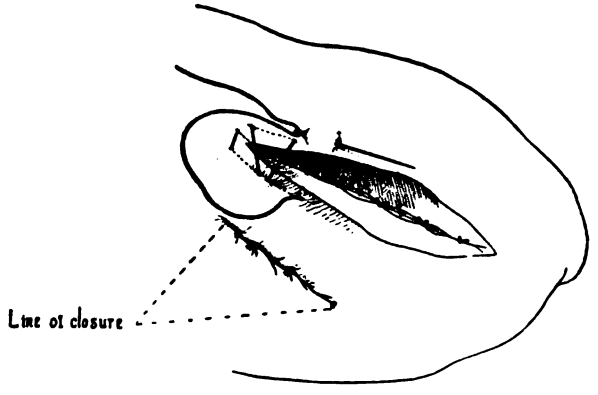

FIG. 351. CLOSURE OF THE VISCERAL PLEURA WITH AN EXAGGERATED CUSHING STITCH.

Operations upon the heart and mediastinum. Early operations upon the heart and pericardium have been few because wounds affecting them are either promptly fatal or treated expectantly. Such injuries as are disclosed by operation are easily remedied as they require little more than simple suturing.

Wounds of the mediastinum are always serious, particularly because of liability to infection. Bleeding from mediastinal vessels, even from the azygos veins, is not easily checked. Foreign bodies should be removed with the least traumatism and the resulting defect carefully repaired. Wounds of the thoracic duct have usually been fatal, even when the duct has been ligated.

Operations upon the diaphragm. When excisions are necessary they should be as limited as safety permits and adapted to spare the branches of the phrenic nerve. Usually all serious diaphragmatic injuries are well exposed by a thoracotomy of necessity. In the repair of

defects of the diaphragm and in suturing it to parietal defects care should be taken to avoid including nerve branches in the sutures. Adhesions do not cause persistent immobility, but diaphragmatic immobility commonly permits permanent adhesions.

When abdomino-thoracic injuries are suspected it is easier to attend to the chest injury first, as this operation is better tolerated and will establish more favorable conditions for laparotomy. Occasionally the entire abdominal repair can be completed through the diaphragm.

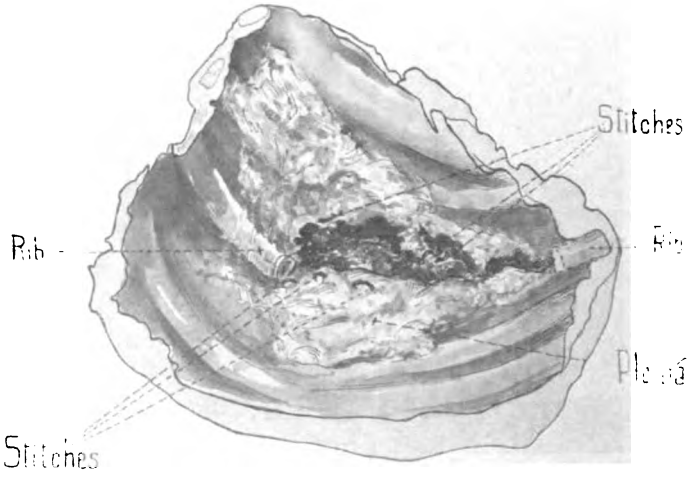

FIG. 352. INNER ASPECT OF THE CHEST WALL OF A FATAL CASE OF PURULENT PLEURISY. Suture tension necrosis has permitted separation of the margins of the parietal pleura with exposure of the muscle and bone.

Closure of the chest wall. Next to positive pressure, analgesia with nitrous oxide and oxygen, accurate closure of the chest wall, and particularly the repair of the parietal pleura, is the most important phase of the entire operation. No matter how excellent the rest of the care may be, a failure to obtain air-tight healing of the parietes results in an open pyothorax. The parietal pleura heals more rapidly than the more superficial tissues, and offers greater resistance to the extension of inflammation either from within or without. Failure to secure smooth healing of this layer may lead to a severe and persistent empyema even though the more superficial wound heals firmly.

An illustration of the result of imperfect healing of the parietal pleura is found in Figure 352. The pleural sutures had caused tension necrosis

so that separation occurred with exposure of the muscle and rib ends to the pleural cavity. This accident occurring in a dog is exactly comparable to conditions seen repeatedly at human necropsies.

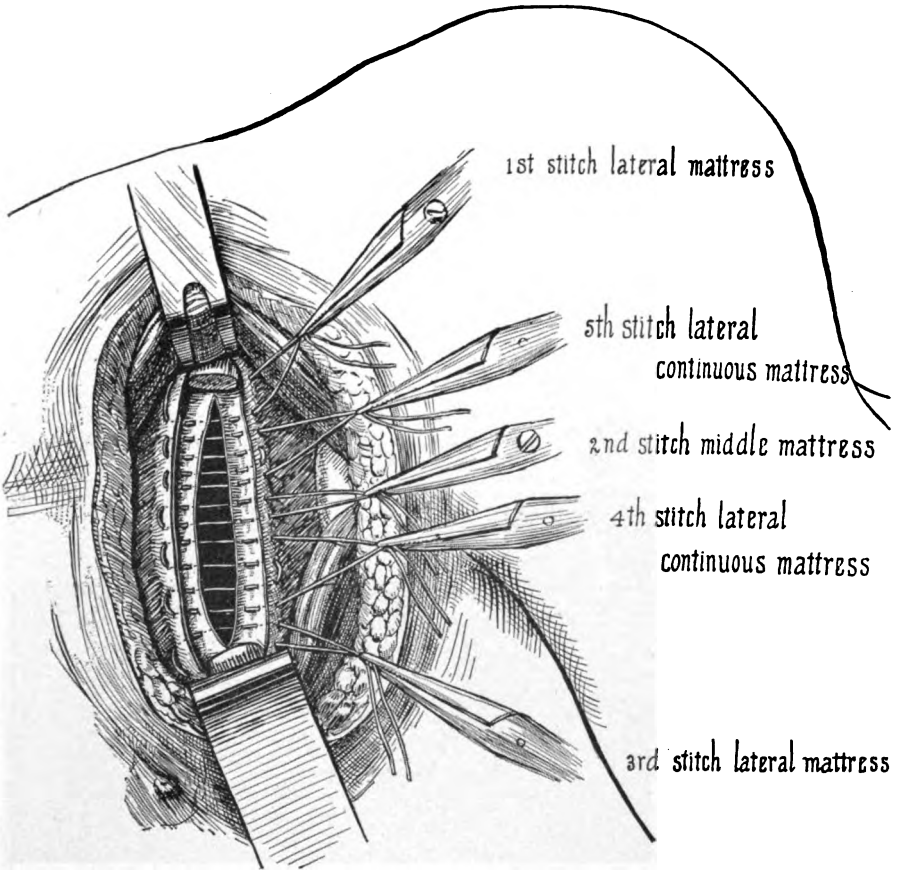
1st stitch lateral mattress
5th stitch lateral continuous mattress
2nd stitch middle mattress
4th stitch lateral continuous mattress
3rd stitch lateral mattress

FIG. 353. CLOSURE OF THE CHEST WALL AFTER THORACOTOMY. Single and continuous mattress sutures are inserted through both periosteal margins on either side. The lateral sutures have the outer loop of the stitch placed beyond the rib ends.

A well controlled series of clinical and experimental observations show that smooth parietal healing is assured only when there is accurate pleural approximation in the absence of suture tension. A closure of this type is possible only when the ribs next above and below the defect are brought abnormally close together. The pleural approximation must

extend beyond the rib ends at either angle of the incision in order to make certain that no denuded rib be exposed or become exposed within the pleural cavity.

The method of suture has been illustrated diagrammatically to show the steps in the closure of a thoracotomy of election. During the period of

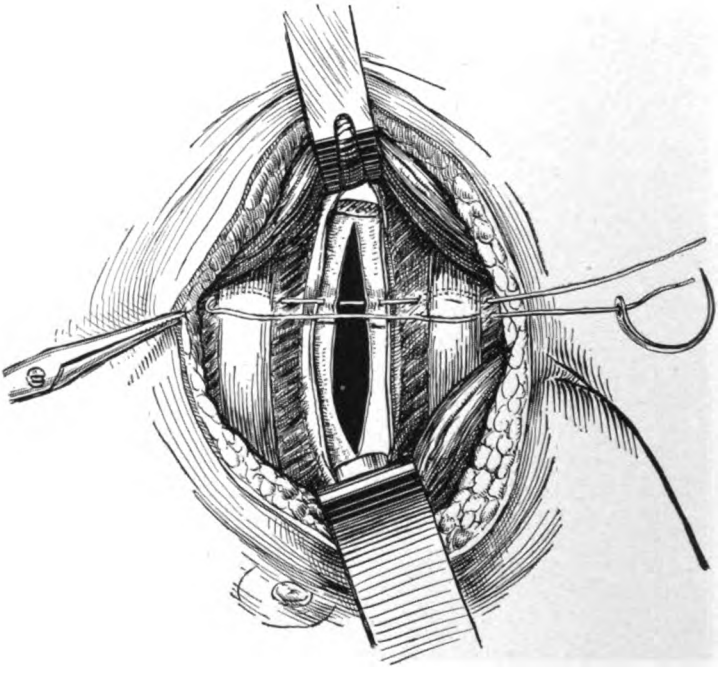

FIG. 354. CLOSURE OF THE CHEST WALL AFTER THORACOTOMY. In inserting a wire rib stay the posterior loop includes the periosteum, so as to aid in approximating the parietal pleura. The anterior loop does not penetrate the intercostal tissues.

closure the anæsthetist gradually increases the positive pressure to produce a slight degree of hyperinflation, so that when the parietal pleura is hermetically closed there shall be the least residual pneumothorax. Under these conditions approximately normal negative pressure is immediately re-established.

Mattress sutures are preferable for reuniting the parietal pleura, and

usually can be inserted through both margins of the cut periosteum, so as to gain double support (Fig. 353). When this is impracticable the sutures should be placed far enough below the lower margin of the incision to avoid the intercostal vessels. Single mattress sutures are placed at each angle and in the middle of the incision. The spaces between these are closed with continuous mattress stitches. As indicated in the diagram

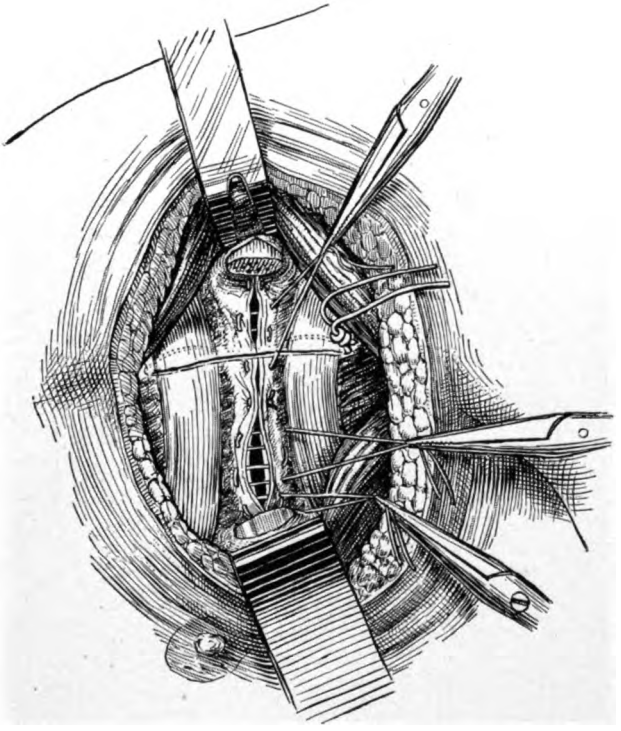

FIG. 355. CLOSURE OF THE CHEST WALL AFTER THORACOTOMY. The rib stay is drawn taut and fixed so that it can be easily removed.

the outer loop of each lateral stitch is inserted behind and lateral to the cut rib end. When the stitch is tied, pleural approximation external to the rib end is secured and the denuded rib excluded from the pleural cavity.

An attempt to tie these sutures without overapproximation of the ribs next above and below results either in the stitches pulling out immediately or sloughing out later. The ribs are pulled together by means of a wire stay passed about them, as indicated in Figure 354, from which for the sake of clearness the mattress sutures have been omitted. One

loop is passed beneath the rib, and, if possible, kept outside of the pleura by hugging the rib with a needle which has been made slighly blunt. As this loop of the stitch crosses the pleural incision it takes in the margins of the parietal pleura and intercostal muscles to promote their subsequent apposition. The other loop is passed over the rib and does not include the intercostal structures.

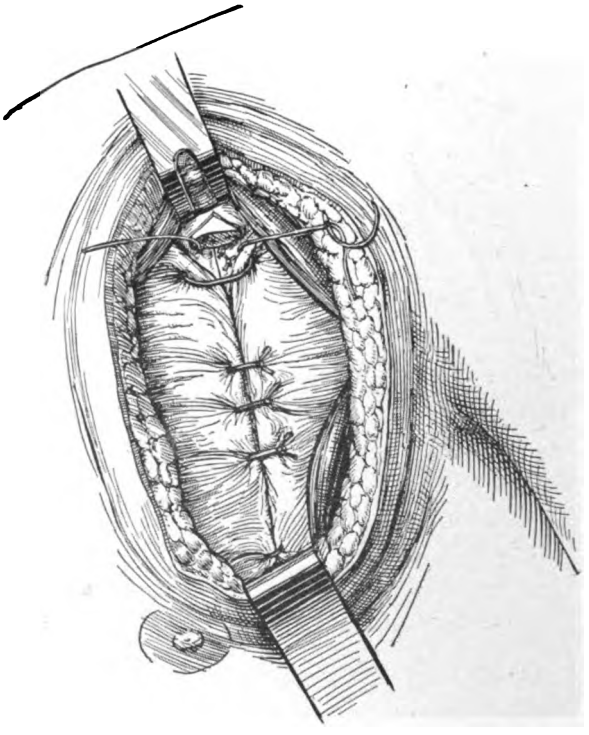

FIG. 356. CLOSURE OF THE CHEST WALL AFTER THORACOTOMY. The layer of fat and muscle is closed over the defect caused by rib resection.

When this wire stay is drawn taut the ribs are so approximated that it becomes possible to appose pleura to pleura without tension by drawing upon the mattress sutures. The three single stitches are tied (Fig. 355): the continuous stitches are pulled tight, and tied at either end and in the middle to an end of a single stitch. This closure is air-tight if the suturing is done accurately. If there is a leak, it will be revealed by escaping air and must be corrected by a stitch or two to prevent tissue emphysema.

Overapproximation of the ribs provides an abundance of muscle tissue for the next layer. Healing is better if there is no dead space at the rib ends. A single suture, placed near the rib ends, as indicated in Figure 356, is tied and one end is cut. The other end is now tied to the end of the lateral mattress stitch in the parietal pleura. The tissues are thus held snugly over and against the end of the rib. The balance of this layer is closed with interrupted stitches, which promote better healing than continuous stitches.

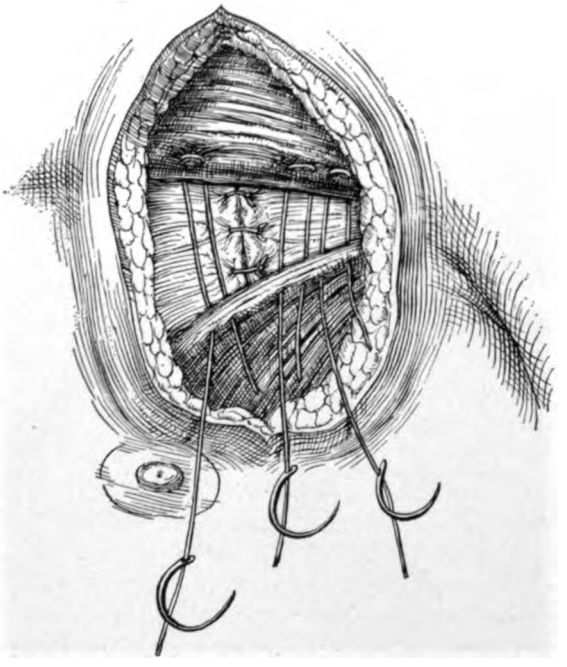

FIG. 357. CLOSURE OF THE CHEST WALL AFTER THORACOTOMY. The margins of the pectoralis major and latissimus dorsi are united with mattress sutures to protect the deep wound.

The margins of the pectoralis and latissimus dorsi muscles are approximated with mattress sutures to safeguard the layer beneath from the dangers of suppuration in the subcutaneous fat (Fig. 357). The deep layer of the superficial fascia is united by interrupted stitches (Fig. 358), inserted opposite to the usual manner so that when tied the knot is not exposed superficially. The skin is closed with interrupted stitches to permit the escape of serum.

These exact methods are open to the criticism of being time consuming and unnecessary. In a considerable proportion of individuals this may be true, but there is a proportion which is not negligible in which it is not true. Neglect of details during a drive resulted in less satisfactory healing. The wire rib stay is particularly undesirable, but absorbable sutures do not hold and silk or linen are unreliable. The wire should be removed in from four to six weeks as it will eventually cut through the ribs, and should be inserted so as to facilitate exposure of the twisted ends.



FIG. 358. CLOSURE OF THE CHEST WALL AFTER THORACOTOMY. The deep layer of the superficial fascia is closed with buried stitches.

Methods of closing the chest in limited thoracotomy and in thoracotomy of necessity are based upon the same principles.

Drainage. The use of primary and even of early drainage after operation was generally condemned because open methods were employed, and because with them collapse of the lung is inevitable. Gray cited figures to show that closure was safer than open drainage. The postoperative accumulation of serum was recognized as a constant occurrence, and routine aspiration, repeated as required, was adopted as a necessary precaution against its dangers. Lockwood and Nixon found

that interrupted drainage by aspiration reduced the need for subsequent rib resection and open drainage. Gask is of the opinion that drainage of the chest is comparable to amputation and both are confessions of surgical failure.

Experience in the early and late treatment of pleurisy shows that air-tight insertion of drainage tubes provided with some device to prevent the entrance of air is the most satisfactory procedure, and that the earlier such drainage is established the better the results. It is evident from the writings of Elliott and Henry, Dobson, Mozengo, Blankenhorn, Whittemore, McKenna and Roberts, and from our own experiences, that a catheter drain inserted intercostally by trochar and cannula, and provided with an automatic one-way check valve, is the method of choice (Fig. 359). By this means negative pressure can be maintained until full inflation in secured. Employment of fluctuations in intrathoracic pressure to provide the expulsive force is better than using suction, as it is in keeping with normal physiological movements. It is also very much simpler, and being automatic is not dependent upon constant attention for its success.

Duval advised against operating more than thirty hours after injury. The dangers of empyema after that time are very great but are less with operation than without, especially if primary drainage is used. We found that early operation, conducted by methods described above, gave a mortality rate of 4 per cent in an unselected consecutive series of fifty-two early cases. When operation was delayed beyond twenty-four hours the mortality rate was increased ten fold. It seems now that had primary drainage been used more as a routine many of these lives could have been saved. It is certain that primary drainage after operation for the large wounds with open thorax, foreign bodies, and lacerations of liver and diaphragm, would have been effective in limiting disastrous pleurisy.

Postoperative treatment. The use of positive pressure anæsthesia is the most important factor in simplifying the postoperative care, because of the decreased distress due to the abolition of pneumothorax, the better general condition of the patient, and the elimination of complications.

Morphine in generous doses is useful in reducing pain, in limiting the rate of respiration, and in controlling coughing. The value of posture has been overrated. Patients naturally take the most comfortable position. Other things being equal lying upon the sound side is preferable.

The chief interest is in the postoperative effusions. If primary drainage has been instituted there is only need to see that the tube is free. If the chest has been closed tight one of two courses is open: either aspiration should be done the second day and repeated often

enough to prevent any considerable reaccumulation, or it should be done when signs of pressure or of infection develop, or when absorption is unduly delayed. There are objections to all methods, least of all to primary drainage.

The most important feature, next to safeguarding life, is the earliest re-establishment of full pulmonary functions. No breathing exercises



FIG. 359. *a*, TROCAR, CANNULA, AND CATHETER FOR INTERCOSTAL DRAINAGE. *b*, FLAP VALVE USED TO SECURE AUTOMATIC ONE WAY DRAINAGE.

should begin until the patient is afebrile, and then if a rise in temperature should follow they must cease until the temperature is again normal. Holding the breath, slow breathing, and blowing against pressure are valuable, with particular attention given to abdominal breathing in order to reactivate the diaphragm. Patients should be encouraged to get out of bed as early as safety permits and to exercise the muscles of the thorax. Recovery is protracted as early activity is delayed. Active duty within six weeks of an injury serious enough to require resection of part of a lower lobe was achieved by one soldier, and indicates the possibilities.

Complications. Pleurisy is to be regarded as a natural and constant sequel of an intrathoracic injury, including thoracotomy. Empyema

is the commonest and most significant complication. There is no sharp line separating the two and none should be assumed. The best treatment of empyema is to limit the initial pleurisy, and this is more certainly accomplished by primary drainage than by any other method. When primary drainage or routine aspiration is impossible exploratory puncture is indicated by signs of sepsis or by signs of a sudden increase in the exudate. The probability of subsequent development of an empyema can be established by the soiling and reaction of the pleura present at the time of operation, and by the length of time elapsing between injury and operation. As a rule, the more virulent the infection the more rapid the development of postoperative empyema and the less the likelihood of limiting adhesions being formed.

Open operation for empyema performed without differential pressure is dangerous if done before adhesions form, and may be futile if delayed. Catheter drainage should be the first resort and will usually be sufficient. If more radical intervention is required thoracotomy with positive pressure analgesia will permit of all necessary manipulations without the dangers of pulmonary deflation, and with the least danger of disseminating infection. The wound may be closed completely, and tube or catheter drainage established elsewhere, or a tube may be closed in hermetically at an angle of the incision. It is understood that some form of valve is provided so that subsequent irrigations may be given without permitting air to enter the chest. Slight constant suction will often prevent coagulation of serum within a catheter. This suction and a receptacle to catch the discharge may be provided by a simple apparatus (Fig. 360, *a, b*). Fluoroscopic control makes it easy to do the work accurately and safely.

Pneumonia is usually contralateral and of the bronchial type. It is rare, as is contralateral pleurisy, when gas-oxygen pressure analgesia is used. The probable explanation is the less urgent dyspnœa and consequent failure of aspiration of blood and mucus which are expelled from the bronchi of the injured side into the bronchi of the sound side.

Contralateral collapse, which has been so well described by Bradford, does not occur when positive pressure is used. Experiments done since the war indicate that this alarming complication is of an atelectatic nature and that spasm of the bronchial muscles is the probable cause. The collapse obtained experimentally by thoracotomy without positive pressure is incomplete and yields, as does atelectasis, to intratracheal hypertension.

The presence of a foreign body may prove a serious handicap to permanent recovery. It has been said that every man harboring one foreign body suffers from two, one physical and one mental. Small shell fragments and bullets imbedded in the lung may cause pain and dyspnœa because they are sources of chronic traumatism, and because their re-

moval is occasionally curative. The distress is more often due to the effects of pleurisy, restricted motion of the parietes, reduced intrapleural negative pressure, or to impaired motion of the diaphragm. Under such conditions the foreign body is an incident and its removal can change the mental attitude only. The indications for removing these intrapulmonary foreign bodies is a matter of opinion.

Three methods are available for the late removal of intrapulmonary foreign bodies: First, the use of forceps of the alligator type introduced



FIG. 360. FORM OF TRAP TO BE ATTACHED TO A CATHETER DRAIN. It provides both a receptacle for the discharge and a flap valve. If slight suction is needed, it can be provided by collapsing the trap.

intercostally and manipulated under fluoroscopic control. Petit de la Villéon introduced this procedure and reported remarkable results. Its dangers, particularly when the foreign body is at the root of the lung, are obvious. It is a blind procedure. A second method, also a compromise, consists in a short costatectomy, suture of the parietal to the visceral pleura, and removal of the foreign body with forceps guided by a Hirtz compass. Like the method first described this method is best applicable in the case of small superficial fragments. When the foreign bodies are deeply placed, near the large vessels or mediastinum, an open operation should be done, the foreign body removed and the incidental damage accurately repaired. The best treatment would have been removal of the missile at time of injury.

Foreign bodies in the pericardium, in the heart muscle, and in the cavities of the heart have been removed. Aside from the possibilities of civil surgery suggested by these highly dramatic operations a very practical hint has been given toward selecting the method of approach. Most operators have attempted to keep out of the pleural cavity and have generally succeeded in provoking an empyema. An open operation, such as a thoracotomy of election, if done with differential pressure, gives a very satisfactory cardiac exposure, and would make possible better surgery and smoother recoveries.

Late, persistent or recurrent empyema suggests the possibility of some chronic irritant like a foreign body or a costal osteomyelitis, both of which must be excluded with the least possible delay. Much has been and will be written about methods of treating open pyothorax, and various methods of irrigation and decortication. All have one object, to convert an open into a closed thorax by pulmonary inflation. The essential factor is the re-apposition of visceral and parietal pleura, whether attained operatively as proposed by Roux-Berger, or by breathing exercises. The general plan of procedure is based upon the elimination of infection, and reduction of irritation; solutions which favor disintegration of fibrin are indicated. To date nothing superior to Dakin's solution has been found.

Treatment of closed pyothorax is being advanced by the application of principles established by Bowditch. Instead of an immediate costatectomy and the formation of an open pyothorax it is far better to introduce one or two catheters by means of a trocar and cannula. Intermittent irrigation and continuous drainage, which protect and increase pulmonary inflation, may effect a rapid cure. If this method be partially unsuccessful, a less forbidding operation is ultimately required. Encapsulated pockets may be tapped safely if the manipulations are done with the aid of a fluoroscope. The best treatment of empyema is that proposed by Roux-Berger, early and complete operation after injury.

Reports by Rist, Hardin, Bernard, Sommerville, Péhu and Daguet all show that chest wounds are unlikely to favor early development of tuberculosis. Tuffier noted that the disease is prone to appear on the opposite side. The reasons are clear. The injured side is apt to be incompletely expanded and is in a condition, according to Cloetta, to offer hypernormal resistance. The opposite side, constantly affected by compensatory emphysema, is in a state of reduced resistance.

Physical disability will persist in the wounded in proportion to the interference with the respiration and circulation. The interference may be so slight as merely to reduce the powers of compensation and become apparent only under stress, or it may cause dyspnœa, palpitation and cyanosis with slight exertion. If there is incapacity, attempts should be made to determine the cause, and such treatment, operative, medical or physical, be employed as will improve function. It is easy to make a diagnosis of neurosis or malingering in individuals who have sustained chest injuries, and do them a grave injustice. Complete physical examination before and after exertion, controlled with a fluoroscope, will generally disclose reasons for the complaints of pain and disability.

It is impossible to give the credit justly due to the various men who have contributed to the advances made in treating thoracic injuries. It is equally impossible to escape an obligation to the chief contributor, the wounded soldier. The medical profession should see that the knowledge bought with so much suffering and distress shall be applied in reducing the disability incidental to the pleuropulmonary diseases of civil life, and that the wounded in conflicts to come shall receive square treatment through more effective organization and better equipment of army medical corps, and adequate training of personnel.

BIBLIOGRAPHY

BASTIANELLI, R. Surg., Gynec. & Obst., 1919, xxviii, 5.
BLANKENHORN, M. A. J. Am. M. Ass., 1918, lxxi, 1994.
BRADFORD, J. R. Quart. J. M., 1919, xii, 127; War Medicine, 1918, ii, 10; Brit. M. J., 1917, ii, 141.
BRADFORD, J. R., and ELLIOTT, T. R. Brit. J. Surg., 1915, iii, 10.
CAPPS, J. A. Am. J. M. Sc., 1916, cli, 333.
COWELL, E. M. Brit. M. J., 1917, ii. 581.
CLOETTA. Arch. Exp. Path. & Phar., 1911, lxvi, 409; lxx, 407; Arch. f. d. ges. Physiol., 1913, ciii, 339; Arch. f. klin. Chir., 1912, xcviii, 835.
DAVIES, H. M. Lancet, 1916, i, 232; Brit. M. J., 1917, ii, 875.
DEAN, C. Quart. J. M., 1918, xi, 59.
DELREZ, L. Arch. méd. belges, Brux., 1918, lxxii. 602.
DENNY, G. P., and MINOT, G. R. Am. J. Physiol., 1916, xxxix, 455.
DOBSON, J. F. Brit. M. J., 1918, i, 148.
DUVAL, P. War Medicine, 1918, ii, 21; Surg., Gynec. & Obst., 1919, xxviii, 1.
ELLIOTT, T. R. Brit. M. J., 1919, i, 448.
ELLIOTT, T. R., and HENRY, H. Brit. M. J., 1917, i, 413 and 449.
GASK, G. E. Brit. M. J., 1919, i, 445.
GASK, G. E., and WILKINSON, K. D. Brit. M. J., 1917, ii, 781.
GHOREYEB, A. A., and KARSNER, H. T. J. Exp. M., 1913, xviii, 500.
GRAHAM, E. A., and BELL, R. D. Am. J. M. Sc., 1918, clvi, 839.
GRAY, H. M. W. Brit. M. J., 1917, ii, 580.
GREGOIRE, R., and COURCOUX, A. Presse méd., 1917, n. s. lxvi, 673; 1919, p. 355.
HUTCHINSON, W. Brit. M. J., 1918, i, 196.
KARSNER, H. T., and ASH, J. E. J. M. Research, 1912, xxvii, 205.
Laboratory of Surgical Research, Central Medical Department Laboratory, A. E. F., France. Boston M. & S. Jour., 1919, clxxx, 405.
LESLIE, R. M. New York M. J., 1916, civ, 625.
LOCKWOOD, A. L. War Medicine, 1918, ii, 6.
LOCKWOOD, A. L., and NIXON, J. A. Brit. M. J., 1918, i, 105 and 145.
MARION. Presse méd., 1915, xxiii, 353.
MCKENNA. Bull. Chicago M. Soc., 1920, xix, 22.
MILLER. Bull. Robert Koch Soc., etc., 1913, 123.
MOZINGO, A. E. J. Am. M. Ass., 1918, lxxi, 2062.
NIXON, J. A. Brit. M. J., 1919, i, 399.
OLIVIER, R. Lyon chirurg., 1918, xv, 339.
PÉHU, M., and DAGUET, M. Lyon chirurg., 1918, xv, 251.
PRYOR, M. New York M. J., 1916, ciii, 781.
RIST, E. War Medicine, 1919, ii, 982.
ROUX-BERGER, J. L. Presse méd., 1918, xxvi, 269; Lyon chirurg., 1918, xv, 330.
SOLTAU, P. B. War Medicine, 1918, ii, 1.
TUFFIER, T. War Medicine, 1918, ii, 16.
VILLÉON, E. P. DE LA. War Medicine, 1918, ii, 24.
WHITTEMORE, W. Boston M. & S. J., 1919, clxxxi, 575.
WILLEMS, C., and DE CAESTECKER, J. Arch. méd. belges, Brux., 1918, lxxi, 588.

CHAPTER II

WOUNDS OF THE ABDOMEN

THE man with an abdominal wound presents one of the serious problems which the military surgeon has to face. No other group of cases furnishes anything comparable to it in testing the medical resources of an army or the technical skill of its surgeons. Although cases with abdominal wounds comprise but 2 per cent of the total wounded, the severity of the lesions encountered and their complex nature call for the highest surgical judgment in diagnosis and treatment. The problem is full of interest to every surgeon and challenges his best thinking.

In the recent war, the attitude of surgeons with reference to abdominal wounds underwent a marked change. In the Spanish-American war and the Boer war the expectant treatment was followed and few surgeons then had the courage to argue for and practice operative interference in these cases. The occasional patient in whom operations had been attempted almost invariably succumbed, chiefly because intervention had been too long delayed. This inevitably resulted from fighting over an open country with a rapidly shifting line, for properly equipped hospitals could not be placed near enough to the firing line to be of any service to the seriously wounded soldier.

During the early months of the great war, conservative management of the wounded abdomen was still generally advised and practised, but early in 1915 there began to be evident a movement, both among the surgeons of the allies and German surgeons, for surgical intervention and this effort gained rapidly in favor. Among the pioneers for immediate operative interference in abdominal cases were Bowlby, Wallace, Gray, Archibald, and Walters with the British; Depage, Neumann, and Willems with the Belgians; Leriche, Gosset, Fiolle, Rouvillois, Quénu, Mathieu, Murad, Schwartz, Mocquet, Duval, Chavannez, and Vouvier with the French; and Enderlen, Sauerbruch, Körte, and many others with the Germans.

The reasons for this change in surgical attitude lay largely in the growing appreciation of the truth of three factors: First, that the man with a wound of the abdomen, nonoperated, usually dies. Gibbon has stated that in nineteen months' active service abroad he did not see a single instance of recovery following nonintervention in penetrating or perforating abdominal wounds. Second, that the time factor is vitally

important because of the frequent presence of serious hæmorrhage, and, with a hollow viscus injury, the rapid development of spreading peritonitis. As Bowlby and Wallace said, "abdominal surgery to be successful must be done at once." Third, that the intra-abdominal wounds in the war just ended were definitely more grave than in preceding wars because of the nature of the projectiles used. Machine-gun bullets and high-explosive shell fragments in particular often caused extensive lacerations of the bowel wall, sometimes completely severing it, and at other times excavating large areas. These lesions were in marked contrast to the clean-cut, punctured rifle wounds of former conflicts.

Before proceeding with a detailed study of the wounds themselves, it is important and essential that we should consider certain subjects which are vital in the proper care of the abdominally wounded.

Transportation and the time factor. It becomes evident at once that whether with a fixed or moving line, the abdominally wounded man must be rapidly evacuated to the hospital where surgical treatment may be applied. Transportation, therefore, becomes an exceedingly vital problem. The motor ambulance made possible much of the advance in abdominal surgery by cutting down materially the time elapsing between the receipt of the injury and operation.

Various factors, however, interfere with rapid evacuation, such as the severity of the fighting, the number of wounded men, the mobility or immobility of the line, the terrain, and the condition of the roads as to number, surface, and traffic requirements. Bowlby and Wallace found that out of 200 consecutive evacuations of abdominal cases to a casualty clearing station 78 arrived within the first six hours, 56 within the second six hours, 35 within the second twelve hours, and 31 after twenty-four hours. Only those evacuations accomplished within the first six hours were considered good.

Ambulances should be provided with heating facilities, such as the British used, that patients may be evacuated in cold weather, warmed and, therefore, less shocked and with better chances of recovery following operation. I have taken many a dead man from an ambulance in which the other occupants were stiff and cold, with the firm conviction that some of those lost might have been saved had the ambulance been provided with a heating appliance.

At times horse-drawn ambulances have demonstrated their usefulness, when with roads absolutely blocked, and motor evacuations at a standstill, the horse-drawn vehicle has been able to carry patients over an open country and bring the seriously wounded where surgical aid was available. A certain number of such ambulances should always be included in a divisional organization, that such special evacuation emergencies may be successfully met.

A well-organized front line evacuation is essential to the proper surgical care of the abdominal case. This effort is difficult enough when trench warfare exists, but during an advance it requires the best in organization and heroism in order to ensure the least possible delay. The most capable surgeon and the best equipped hospital are of no avail if the wounded do not reach the hospital within twelve hours.

The time factor is recognized as an all important element. In general, the patient must be seen in the first twelve hours if a wounded hollow viscus is to

be successfully treated surgically. Those operated upon within the first eight hours yield definitely better results. No other consideration compares in importance to the element of time; recovery percentages are inversely proportional to the time factor, rather than to the organ involved or the number of lesions encountered.

The nontransportable hospital. Special provision had to be made far forward where abdominal cases could receive early and adequate surgical care. With a fixed line small hospitals naturally came into being, placed six or eight kilometers from the firing line. They were well housed, usually in wooden huts or châteaux with completely equipped operating and radiological units and well organized wards. A surgeon of ability was placed in charge of such a unit and the staff requirements, including a small nursing quota, were limited. The French and the Belgians made this type of hospital an integral part of their organization, and as time went on each sector of their line had its advanced hospital for nontransportables, to care for the abdomens especially, the chests, and those suffering from shock or hæmorrhage. Leriche, Fiolle, Rouvillois, and many others with the French, and Neumann with the Belgians, were early active workers in these advanced abdominal hospitals.

The British organization directed that in quiet sectors all surgical cases, including abdominal cases, should be concentrated in the casualty clearing stations. Here their best surgeons were placed and here they believed the best hospital care could be furnished. They felt that it was better policy to bring the wounded man farther back to a well-equipped hospital than to run the chance of a hurried evacuation from an advanced hospital should military necessity require it. In times of great stress, however, certain small units were sent farther forward from the casualty clearing stations to care for the abdominal cases. Wallace, particularly, early appreciated the desirability of the advanced operating unit for abdominal cases.

The mobile unit. No consideration of abdominal military surgery can be complete without taking into account the necessity for well organized mobile units for the care of the seriously wounded. When the war of movement began in the spring of 1918 a different type from the stationary non-transportable hospital had to be evolved, so organized that it could move with an advancing or retreating line and still provide satisfactory surgical care for the severely wounded. The French had devised this type of advanced hospital and had made use of it on numerous occasions. These units, known as mobile units, rendered wonderful service. The housing was in Bessonneau tents, and the surgical and X-ray equipment was of the best. The American army included a number of these units. They were controlled by a capable abdominal surgeon with adequate assistants, and usually with trained nurses. The bed capacity varied from 150 to 200; about 200 tons of trucking were required to move them. In addition, one or two divisional mobile units were developed in the American army with two field hospitals as a basis. The bed capacity was 125, but the amount of trucking required to transport one such unit was but 36 tons, the amount assigned to two field hospitals in the American army.

Such a hospital should be placed as far forward as is compatible with reasonable safety to patients and personnel, but no farther. It is very difficult to maintain morale and surgical efficiency when such a unit is under shell fire. Under these conditions the patients become terrified, it is exceedingly difficult to carry on any effective work, and a hasty evacuation of all patients may be imperative. I

have knowledge of several abdominal cases who had done well after operation in such a mobile hospital, but who died following their evacuation to the rear.

It has been claimed that proper postoperative care could not be provided by the mobile unit if an offensive with an advancing line were in progress, as military necessity would compel the moving forward of the hospital and the evacuation of all postoperative cases. The organization of such a unit may include a rear echelon consisting of a certain number of officers and enlisted men who may be left behind with a portion of the tentage and supplies to complete the eight or ten days of postoperative care required for abdominal cases. When these patients are finally evacuated the echelon moves forward to join the major portion of the unit. Another effective way of dealing with this problem consists in making use of a second mobile unit, which passes the hospital already established and establishes itself in a more advanced position, while the unit behind completes the postoperative care of the nontransportable cases.

Incidence of abdominal wounds. The percentage figures for abdominal injuries in comparison with the total number of wounded vary as the figures are taken far forward in a regimental aid post, or somewhat farther back in the *triage* or field hospital, or still farther to the rear in a mobile unit or evacuation hospital. The exact figures can never be known, as many men wounded in the abdomen die upon the field of battle from rapidly fatal hæmorrhage. Battalion and regimental surgeons see some such cases whose records never come to the *triage*. Nevertheless, the incidence in *triage* work is perhaps the most nearly accurate record to draw upon, for some hopeless abdominal cases reach this point which do not live to go back to the surgical hospital. The percentage of abdominal cases in the *triage* is between 1.5 per cent and 2 per cent; farther back, between 0.5 per cent and 0.75 per cent. Of all the seriously wounded, abdominal penetrations constitute from 2.6 per cent (Chalier and Glénard) to 12 per cent (Rouvillois), the percentage varying with the type of *triage* work done in the forward area, the character of hospitalization provided, and the classification followed.

Military importance of abdominal wounds. At first thought one would say at once that from the military standpoint the soldier with an abdominal wound is much less important than the man slightly wounded. The latter may be reasonably expected to return to the firing line at an early date while the former may be months in the rear or never return to the front. Further, the small proportion of intra-abdominal lesions encountered would seem to make them of decidedly less military importance. But, as a matter of fact, the proper care of abdominally wounded men is exceedingly important from the side of the morale of any army, for it gives the rank and file of its soldiers the conviction that any man badly wounded will receive the best chance for his life that surgery can give him. Humanity dictates that every combatant seriously hit by enemy fire shall have a chance to live.

Abdominal injuries may be classified as follows:

1. Nonpenetrating wounds:
   a. Wounds of the abdominal wall.
   b. Retroperitoneal visceral injuries.
2. Subcutaneous rupture of viscera.
3. Penetrating or perforating wounds:
   a. Without visceral injury.
   b. With visceral injury.

NONPENETRATING WOUNDS

Nonpenetrating wounds involving the abdominal wall. These include gutter wounds; perforating wounds running at a tangent to the parietal surface without penetrating the peritoneum; and penetrating wounds, with the missile lodged in some portion of the anterior or lateral abdominal wall or posteriorly in the retroperitoneal tissues or muscles of the back. Any type of projectile may cause such a wound.

The gutter abrasions make their own diagnosis. They call for complete *débridement* of the wound with primary closure if the case can be held under the operator's observation for at least one week, during which time any symptoms of wound infection may be quickly recognized and promptly met. In times of great activity where a possibility exists of an early evacuation of the case, the wound, after *débridement*, should be left widely open and treated with Carrel-Dakin dressings, a delayed primary or a secondary suture being done at a later date. It is well to remember that some apparent gutter wounds are really penetrating wounds, the gutter in these cases growing deeper as the course of the projectile is followed. When any doubt exists, X-ray diagnostic aid must be made use of.

With a perforating wound of the abdominal wall the shorter the track the less likely is one to encounter a visceral perforation. With a through-and-through wound the missile may change its direction, after entering the soft tissues, without any impact with bone, and travel along the abdominal wall, emerging at some distance from the point of entrance. Under these circumstances had the *trajet* been a straight one perforation of visceral contents must almost surely have occurred. Such a case may present great difficulties in diagnosis, for the two most important local signs of a visceral lesion—muscular rigidity and tenderness—are marked, as a result of muscle traumatism, even when no abdominal perforation has been made. The patient's general condition, with lack of pulse elevation and gastro-intestinal symptoms, is the important guide to a correct diagnosis. It is well for the surgeon to bear

in mind that in visceral perforations seen very early, general signs may be absent. The X-ray examination is of little aid in the differentiation. With clean cut rifle wounds no intervention is necessary, but if definite doubt of abdominal perforation exists it is necessary to operate without delay. Wounds caused by shell or grenade fragments or machine-gun bullets should be completely dissected, and the rule for or against primary closure outlined for gutter wounds should be followed.

The penetrating wounds of the parietal wall are at times as difficult to diagnose as the perforating ones. The same local signs are frequently present and the differentiation from cases of visceral penetration must be made in a similar manner. The radiological findings, however, usually make the diagnosis for or against peritoneal penetration and too much stress cannot be placed upon the necessity for this type of examination. Dissection of the tract with removal of the foreign body is the course to be followed. The rules for suture are the same as with a perforating wound.

Retroperitoneal visceral injuries. In this type of wound the organ most frequently involved by far is the kidney. Out of 24 extraperitoneal wounds treated by Rouvillois et al, 14 showed an injury of the kidney, 7 of the bladder, 1 of the colon, and 1 of the rectum. When the wound is a perforating one, the direction of the track usually guides the operator correctly; when a penetrating one, X-ray findings may suggest extraperitoneal visceral involvement.

Kidney wounds may be associated with an alarming and sometimes fatal degree of hæmorrhage. A retroperitoneal hæmatoma may be of considerable size and occasion a marked degree of tenderness on abdominal examination. The differential diagnosis from an intraperitoneal perforation may be very difficult, but the absence of marked muscular rigidity and gastro-intestinal symptoms usually lead to a correct diagnosis. Subsequently, septic degeneration of a hæmatoma may result in a serious retroperitoneal infection.

Extraperitoneal bladder wounds result in early urinary extravasation but usually not in urinary leakage. Such an injury may be associated with fracture of the pelvis. The diagnosis of bladder injury is readily made, but in the early hours distinction from cases with peritoneal penetration may be difficult. Bladder drainage by perineal section or suprapubic cystotomy and bladder suture, whenever possible, yields excellent results in the majority of cases. Sepsis may ensue later in the area of extravasation. Ample drainage of this region is the best form of treatment.

Retroperitoneal rectal injuries may be difficult to detect, for they may exhibit few early signs. Many of these wounds have their point

of entry in the back or buttock and the proof of rectal injury may be difficult to determine. These cases are very apt to develop a septic cellulitis in the perirectal tissues. Adequate drainage is the chief indication and the rectal wound should be sutured whenever accessible.

The detailed data concerning the symptoms, diagnosis, and treatment of these extraperitoneal visceral injuries will be found under the paragraphs in which injuries of these organs are discussed.

SUBCUTANEOUS RUPTURE OF VISCERA

The literature of civil surgery and of former wars has yielded many examples of this sort of abdominal lesion and the recent conflict has been equally prolific. Barnes and Otis in their medical history of the Civil War recite in great detail numerous types and variations of subcutaneous abdominal injuries. In war, as in civil life, injuries of this sort are caused by the kick of a horse or a mule, by blows upon the abdomen during a fight, or by falls from a height, the man landing upon the abdominal wall. In military surgery injuries of this type are also caused by shell explosions in the immediate vicinity of the soldier (the so-called "wind-injuries" of the Civil War); they may be caused by flying pieces of wood or other solid objects in connection with shell bursts; they may result from crushing injuries from falling timbers or earth incident to the bursting of a projectile.

Two modes of injury which are especially important because of diagnostic difficulties are laceration of the abdominal wall by a missile without penetration of the cavity, but with sufficient explosive force to rupture a viscus within; and visceral perforations from flying bone spicules without peritoneal penetration by a projectile.

The former injury if unrecognized leads frequently to a fatal result; the latter should always be thought of in connection with rib fractures in or about the hepatic or splenic areas or with comminuted pelvic fractures where the pelvic portion of the small intestine is the most frequently injured viscus, while injury of the bladder, rectum, and colon is less common.

The organs most often ruptured are the liver, spleen, kidney, and small intestine; the mesentery is not infrequently torn. The colon, rectum, and bladder are less often injured.

The lesions encountered may be grouped under the headings injuries of hollow viscera, and injuries of solid viscera. Hollow visceral lesions may include contusions of the wall, minute perforations, extensive lacerations, or even complete division in the case of the bowel or its mesentery. Solid visceral lesions comprise subcapsular rupture of solid organs,

especially the liver, with usually a small hæmatoma beneath the capsula, slight tears, and extensive lacerations.

The diagnosis of subperitoneal rupture of any viscus or of the mesentery must be made by a consideration of the site and mode of injury, the presence of more or less anæmia from hæmorrhage, especially with solid visceral and mesenteric lesions, and, where a hollow viscus has been opened, the usual signs of peritoneal irritation with subsequent symptoms of a rapidly advancing peritonitis. Patients with serious injuries frequently come to the hospital in considerable shock, particularly when the degree of hæmorrhage is severe or the small intestine or mesentery has been seriously injured.

Rupture of a hollow viscus calls for immediate intervention; the principles of treatment outlined under penetrating abdominal wounds should be followed. A torn mesentery with signs of hæmorrhage requires immediate operation; resection is usually necessary.

With a suspected rupture of a solid viscus but without alarming symptoms of hæmorrhage, an expectant attitude should be adopted. Most of these patients recover unoperated. If the hæmorrhage has been severe in such a case the best working rule is to operate if the patient is seen very early, but to watch and observe for a few hours if the patient is seen six or eight hours after injury. If then the anæmia is not apparently progressive one should not operate, for the hæmorrhage has to all intents ceased and laparotomy will cause a renewal of the hæmorrhage with a probable fatal result. If there are signs of progressive bleeding the abdomen must be opened at once.

Control of hæmorrhage from a ruptured liver may be accomplished by packing or by mattress suture inserted with a large needle, blunt end first. Suture near the diaphragm or far back on the inferior surface of the liver is difficult and frequently impossible. Packing with sterile gauze should be resorted to when suture cannot be effectively carried out.

In general a rupture of the spleen should be treated by splenectomy. The objection raised that convalescence is hampered by the impairment of the patient's blood forming mechanism is practically unimportant.

In all cases in which hæmorrhage has been a serious symptom transfusion should be carried out as soon as possible after the bleeding has been controlled. The ease with which this procedure may be carried out, either with the aid of paraffin coated tubes or by the citrate method, the prompt and striking improvement in the wounded following transfusion for hæmorrhage, and the abundance of robust individuals among the slightly wounded who may serve as donors should serve to make this operation a routine procedure early in the treatment of hæmorrhage.

PENETRATING AND PERFORATING WOUNDS

The general principles of the surgery of abdominal penetration differ but little from those practised in civil life. The surgeon's constant effort should be to make his war surgery approximate as closely as possible to his prewar standards. Many factors come in, however, to make the problems of abdominal surgery complex and difficult, and each case must be studied in the light of accumulated experience in the war zone.

General considerations. Before the types of injuries involving special organs are discussed certain general principles influencing the diagnosis and management of abdominal wounds must be considered. As the patient is admitted to the hospital the first questions which arise are:

1. What is the man's general condition with respect to shock?
2. What is the diagnosis?
3. Is operation indicated?

Several factors contribute to bring the soldier with an abdominal wound to the hospital in a condition of shock. These are: Lack of sleep, lack of food, exposure to cold and wet, difficult evacuation to the hospital, traumatism of abdominal and visceral walls, hæmorrhage, pain, and infection, the latter being especially important in those arriving late. Hæmorrhage, save in the late cases, is the great factor in the production of shock, and the degree of shock is usually proportionate to the severity of the hæmorrhage. Undoubtedly many combatants die on the battlefield from rapidly fatal intra-abdominal hæmorrhage. The abdominal cases reaching the hospital show most extensive hæmorrhage when the mesenteric or pelvic vessels or when the liver, spleen, or kidney have been injured.

Hæmorrhage may also occur from the abdominal wall, the omentum, and from the retroperitoneal tissues. In the latter case the loss of blood may occasionally be alarming and diagnosis very difficult. Hæmorrhage is one of the principal causes of fatal issue in the abdominally wounded and therefore an important argument for the earliest possible intervention. Inactive hæmorrhage from a solid viscus does not constitute an indication for operation.

Pain is usually a distinct symptom. The pain in the wounded parts, increased by difficulties in evacuation, and the pain caused by an advancing peritonitis both contribute to the shocked state of the wounded. Moreover, the degree of shock found is in approximate ratio to the time elapsing before the administration of morphine.

Cases with infection of the retroperitoneal tissues may show rather pronounced shock. Infection due to the presence of anaerobic micro-organisms in badly lacerated muscles of the abdominal wall may be an important factor. The shock which accompanies an advancing peritonitis is readily recognized.

A hurried examination having been made to assure the surgeon that no progressive hæmorrhage is present and that no splint readjustments are necessary, immediate treatment directed toward the relief of shock must be instituted. The pre-operative ward of a hospital for seriously wounded should be organized to deal particularly with this condition.

Various means have been used to warm the patient and to keep him warm. One method utilizes an oil stove beneath the stretcher which is placed on saw-horses. The blankets covering the stretcher fall on either side to the ground, creating a warmed air chamber beneath it. Another method makes use of a large tin butter can conducting heat from a lamp into an air chamber formed by placing a stretcher upon a cot. The legs of the stretcher raise it about six inches above the cot and thus form an air chamber whose sides are protected by blankets. In less mobile hospitals an electric light warming chamber beneath the stretcher has proved very effective. Where no stoves are available a large open fireplace may prove a most efficient source of heat for shocked men and I have seen no more rapid or lasting reactions than that followed by this method of applying heat.

Morphine should be administered to those in pain or profound shock, providing a previous dose has not been recently given. All morphine dosage, wherever applied, must be carefully noted upon the man's diagnosis tag in order that a serious overdose may be avoided. Too great emphasis cannot be placed upon the necessity for early morphine administration as far forward as possible, for rest and quiet are essential.

Fluids (salines, sodium bicarbonate, or glucose) should be administered by rectum, or salt solution may be given beneath the skin or intravenously. A man who has been without fluids for a long time may receive a drink of hot coffee by mouth, but operation should be withheld for a couple of hours. If hæmorrhage is progressive the saline infusion should be avoided and transfusion should be deferred until the hæmorrhage has been controlled. Where the hæmorrhage has ceased, but the amount of blood lost has been considerable, saline solution given intravenously will tide the patient over for only a few hours, and subsequent transfusion should be performed.

Bound up with the question of an accurate diagnosis are the questions of abdominal penetration and visceral injury. A tangential abdominal wound, especially if the track is a short one, as pointed out by Eastman, frequently gives no peritoneal penetration. With such wounds, where peritoneal irritation is lacking, the probability of abdominal entry is small. As demonstrated by Wallace, a wound above the pyloric level with entrance and exit to the right of the median line seldom results in visceral injury though the peritoneum may have been entered. Other through-and-through wounds mean certainly that the peritoneum has been penetrated but occasionally without visceral injury.

With only a wound of entrance, diagnosis becomes more difficult, and under these circumstances the X-ray may give the greatest aid to the surgeon. Accurate information quickly obtained by means of a roentgenological examination is often the most important guide to the character of the wound with reference to visceral injury and to the exact situation of the missile. Too high commendation cannot be made of the aid rendered the abdominal surgeon in front areas by the radiologists of our own and allied armies. The manipulation in the roentgenological room should be limited to the minimum, for several times I have seen a good operative risk, after a prolonged X-ray examination, return to the preoperative ward in a state of shock which persisted and resulted disastrously.

The following principles laid down by Wallace as to the probable organs injured with wounds of the various abdominal regions are valuable working guides for the surgeon:

1. Wounds above the transpyloric line usually cause visceral penetration.

Transverse wounds are usually serious and may perforate stomach, liver, spleen, pancreas, or kidney.

2. Wounds below the transpyloric line and above the anterior superior spines are invariably serious. Above the navel the organs injured are similar to those encountered with wounds above the pyloric level, while below the navel the small intestines are almost always perforated. With anteroposterior wounds above and in the lateral aspects the colon is frequently hit. Wounds through the back are more often dangerous on the left side, as the small intestine overlies the colon in the left lumbar region. Transverse wounds are exceedingly dangerous, as both small and large intestines are frequently wounded. There may be, however, no visceral penetration with such a wound.

3. Wounds below the anterior superior spines are always serious. With anteroposterior wounds in the hypogastric region the small intestines are usually hit, the rectum and colon sometimes, the bladder seldom. The great vessels are practically never injured. Perforating lateral wounds may penetrate any of the pelvic viscera, intra- or extraperitoneally. The small bowel is frequently wounded and occasionally the large. Wounds of the pelvic vessels may give rise to a severe or fatal hæmorrhage. Vertical wounds usually have the wound of entry in the buttock, perineum, or thigh, and the surgeon must always bear in mind the possibility of abdominal penetration with such a wound. I have seen a minute wound of the popliteal space in a patient suffering from serious abdominal symptoms, in whom laparotomy disclosed a small wound of entry in the peritoneum and multiple perforations of the small intestine. No other wound could be found upon this man's body.

The symptoms of visceral injury. The general symptoms are those of shock, hæmorrhage, pulse acceleration, and vomiting; the local ones, abdominal pain, tenderness, rigidity, and distension.

The symptoms of shock are well known and its causes in abdominal injuries have been already enumerated. There may be no symptoms of shock even in the presence of serious visceral injury.

Hæmorrhage has been briefly discussed under the paragraph on shock. Though it may produce little in the way of physical signs, the cardinal symptoms are a rapid, soft pulse, a low blood pressure, and obvious anæmia. Patients with hæmorrhage may exhibit excessive thirst, and frequently show signs of air hunger. With any amount of bleeding intra-abdominal fluid may be detected in the flanks, and local peritoneal signs may be moderately marked.

The face is blanched and listless when the degree of hæmorrhage has been considerable; it is anxious when infection in the peritoneum is progressive.

Whether there is hæmorrhage or not pulse elevation is the rule. With a peritonitis in progress the pulse rate steadily rises, and this sign is one of the valuable guides in demonstrating hollow visceral lesions. It is especially important in excluding a parietal wound with considerable muscle injury where local signs of peritonitis may be closely simulated.

Vomiting is usually present with a hollow viscus penetration and becomes more marked as peritonitis becomes more severe. Gastric wounds give earlier vomiting, with a vomitus frequently containing blood, but I have seen several wounds of the stomach with an entire absence of vomiting, so that this symptom cannot be termed characteristic of gastric injury.

There is a great variation in the degree of abdominal pain, and the surgeon cannot pass judgment upon the severity of the visceral lesion from the amount of pain the patient suffers. The location of the pain usually gives little aid in the attempt to localize the viscus injured. The most important feature of the pain from a diagnostic standpoint is its inception simultaneously with the receipt of the wound. The soldier abdominally wounded may have received a considerable dosage of morphine prior to admission, and if this has been promptly given his complaint of pain may be absent, particularly if he is seen early.

The local tenderness is the most pathognomonic sign of a ruptured hollow viscus and is the most constant physical symptom of peritonitis. It is always present and is localized over the region involved. It may be masked somewhat by morphine but it never disappears completely. Tenderness is also present with parietal wounds and contusions, but the other signs of visceral penetration are lacking.

Muscular rigidity is a very important physical symptom of visceral injury but it is less constantly present than tenderness. Charles has seen cases of multiple perforation with an entire absence of muscular rigidity and again has encountered board-like rigidity in severe wounds of the abdominal wall. Wallace and many others have enumerated certain injuries which may be accompanied by marked rigidity without injury of an abdominal viscus. The more important are chest wounds with no abdominal lesion, wounds of the abdominal wall, and hæmorrhage into the retroperitoneal tissues. The rigidity of an advancing peritonitis is generally progressive and increasing in intensity, while rigidity from intra-abdominal hæmorrhage is less marked, and usually diminishes gradually if the hæmorrhage has ceased. Muscular rigidity as well as local tenderness may be all important symptoms in diagnosing a visceral perforation when the wound of entry is in some remote region and the possibility of an abdominal lesion seems very unlikely.

Abdominal distension is not an early nor important symptom of visceral penetration. It becomes more pronounced as peritonitis develops, but it is then of little value in diagnosis.

Indications for operation. Certain groups of cases come to the hospital in which operation is contra-indicated and these may well be considered here.

Moribund patients should be made as comfortable as possible with morphine. A so-called moribund ward is practicable and fills a good purpose. The patients in it must not be left surgically unattended but should be followed through to the end.

Cases with general peritonitis from a hollow viscus injury twenty-four or more hours old are generally hopeless subjects for radical treatment, and the expectant plan should invariably be followed. Rouvillois reports a 100 per cent mortality in such subjects after operation and other observers give the same results. I have never seen such a patient recover after laparotomy. Morphine in liberal doses, Fowler's position, heat, rest, alkaline fluids, sugar solution by rectum and saline solution beneath the skin are the lines of treatment to be followed. These cases must be carefully separated from the moribund class. Unless they are kept under constant supervision the rare individual whose peritoneal defense mechanism may bring him into the operable class may lose his only chance for life, because the psychological moment for operation is passed unnoticed.

Except for the individuals in whom shock is due to progressive hæmorrhage the badly shocked man should be treated as already outlined in the paragraph on shock. He should be kept in the pre-operative ward under the eye of the ward surgeon, but the final decision as to operability or nonoperability must rest with the operating surgeon. When there is no amelioration of the symptoms of shock, operation should not be performed. As a working rule, the patient who shows no tendency to reaction within two or three hours never reacts.

Cases with through-and-through wounds of solid viscera without progressive hæmorrhage do well without surgical intervention, and the recovery percentages are better when no operation is performed. The presence of hæmorrhage in these patients is usually differentiated from an advancing peritonitis by the a pulse rate of 80 or 90. Such a patient should not be interfered with. Intervention frequently results in a renewal of the bleeding when the abdomen is opened and disaster may follow. Fluids by rectum or by hypodermoclysis with moderate morphine dosage are the indications. If the loss of blood has been considerable, transfusion may be resorted to when a fair degree of certainty exists that hæmorrhage has ceased.

Short tangential wounds with unimportant abdominal symptoms, seen eight to ten hours after injury, are best left unoperated, but no such patient should be sent from the pre-operative ward to one of the postoperative wards. When a push is in progress such an individual may easily escape the eye of the ward surgeon, and a case in which operation may have become definitely indicated may be overlooked.

The basic indications for immediate operation are symptoms pointing to progressive intra-abdominal hæmorrhage or hollow visceral penetration. Walters and other surgeons speak of the obvious necessity for operation in cases with visceral or omental protrusion; in cases with escape of gas or fæces through the wound; and in cases with subcutaneous emphysema from the escape of intestinal gas, usually from the large bowel, into the tissues adjacent to the wound. Emphysema of such origin appears shortly after the receipt of the injury in contradistinction to the emphysema of gas gangrene.

In a time of great stress the problem of the seriously wounded may be very difficult to handle. Practically it must be managed by first operating upon the best operative risks. When the stream of badly wounded becomes tremendous, severe cases with wounds other than abdominal, and with better hope of recovery, must have the chance of life which operation gives. A frequent revision of the cases in the preoperative ward must be made that the surgeon may assure himself that no soldier with a fair chance of recovery with operation is passed by.

A good working principle is to operate if doubt of a hollow visceral lesion exists, for the mortality of such operations is exceedingly low when no visceral penetration is found. Walters in a series of 500 cases gives a mortality for this type of operation of 7.1 per cent; other writers place the figures between 5 and 8 per cent. Exploration of the abdomen with negative visceral findings is, therefore, attended with little risk, compared to the uncertain possibilities of a serious advancing peritonitis if the man is left unoperated.

Operative technique. No type of war wound presents such a complex problem as the penetrating wound of the abdomen, and the details of surgical technique must be studied with the greatest care.

There is little doubt that nitrous oxide-oxygen is the least toxic and the best borne of all the narcotizing agents but, unfortunately, it does not give the complete muscular relaxation which is essential to efficient abdominal surgery. Its administration requires a skilled anæsthetist and a bulky apparatus.

Ether is the agent universally employed and is by all odds the anæsthetic of choice for abdominal cases. The ordinary open method of administration gives reasonably satisfactory results; the equipment required is the minimum. Marshall, with an extensive experience, found fewer complications when a warmed ether vapor was used, but in the American army this method was not given a trial.

The shorter the period of anæsthesia the less the degree of toxæmia that will be produced and the better the prognosis for the patient.

Two general rules may be followed to aid the surgeon in his choice

of an incision: (1) Plan the incision to meet the visceral injury suspected; (2) avoid, if possible, the projectile wound site, and so diminish the liability to wound infection. Always make the operative wound sufficiently ample to ensure an unhampered exploration. A wound of 8 or 10 inches usually suffices. Some advise the paramedian incision as the one for general use, while others favor an opening in the median line either above or below the umbilicus, depending upon the organ probably injured. I feel that the latter is the incision of choice in most cases. For the upper abdomen some operators prefer a transverse incision or an oblique one parallel to the costal margin. This gives excellent access to wounds of the spleen, liver, kidney, or upper colon. The greatest objection to this type of incision is the difficulty in making a neat, rapid, and satisfactory closure. With a lesion below the umbilicus, and a wound in the flank, a transverse or oblique incision should be made. Such an incision affords good access to the retroperitoneal tissues and wounds of the posterior aspect of the large bowel. Transverse incisions in connection with abdominothoracic injuries will be discussed when these lesions are considered.

The general principle of wound disinfection by careful dissection must be as carefully observed in abdominal surgery as in wounds of the extremities. Careful excision of all soiled tissues must always be carried out if the patient's condition permits. At times this is best done before the abdomen is opened, and the instruments used should then be discarded. Sutures may be placed if the patient may be held for 8 or 10 days, but it is safer not to close the skin. It may, however, be wiser in very serious cases to defer the abdominal wall dissection until the suture of the operative wound has been completed. Failure to carry out an efficient *débridement* will result in an infected abdominal wall with the possibility of serious consequences.

Speed is important, but make no false moves. Remember that an operation of more than one hour's duration usually means a shocked patient with little chance for recovery. Try to determine what organs may be excluded from the possibility of injury, but err on the side of thoroughness and keep the surgical traumatism to a minimum. Protect the skin adjacent to the wound with towels and skin-clips to avoid contact of the cutaneous surface with abdominal contents. Do as little as you can but be sure the operation is a thorough one.

If hæmorrhage has been progressive or if upon opening the peritoneum there is more blood than was anticipated, seek at once for the source of hæmorrhage and check it by clamp, packing, or suture. Considerable hæmorrhage from the mesentery means inevitable resection.

Throughout the operation make the traction upon the abdominal wall

as light as is compatible with proper manipulation of viscera. The detailed treatment to be applied in wounds of the various organs will be found below, where wounds of these viscera are discussed.

Closure should be done carefully in layers except in cases doing badly on the table, when through-and-through sutures may be employed. If the wound by the missile has crossed the line of operative incision it is better to leave the skin without sutures or but partially closed; and the same precaution against infection of the abdominal wall should be observed if a period of stress prevails, and the work is necessarily somewhat more hurried.

No drainage should be employed in sutures of the small intestine, unless a very active peritonitis has developed. Charles advises complete closure when no more than twelve hours have elapsed following the injury to the small gut. No drainage for stomach cases is necessary. On the other hand, drains of rubber dam (never gauze except to check hæmorrhage) should always be used in wounds of the colon and rectum, especially those complicated by retroperitoneal injury. Gauze drainage for liver or spleen should be employed solely for hæmostatic purposes. Drains are used to provide an outlet for leakage from the large bowel or to check hæmorrhage, but should never be thought of as effectively draining the general peritoneal cavity.

Postoperative treatment. Practically every one of these patients has suffered a loss of body fluids and the administration of fluid is the chief indication. For wounds of the solid viscera, stomach, and small intestines a Murphy drip of 5 per cent sodium bicarbonate solution, with or without 5 per cent glucose, is the method of choice; or similar enemas at four or six hour intervals may be substituted. For wounds of the colon and rectum hypodermoclysis with saline solution meets the indications. Saline infusion may be used in any case where considerable hæmorrhage has occurred, but only as a temporary measure to tide over the man for a few hours until blood may be obtained. Transfusion in this latter group is frequently essential to recovery, and it may be necessary to repeat it. Blood grouping should always be done before transfusion, as it takes but a moment when Vincent's macroscopic test is used. Group IV donors (Moss' classification) may be employed for a recipient of any of the four groups. Citrated group IV blood may be collected at a distance and transported to the hospital in sterile bottles, and such blood may be kept for upwards of twenty-four hours without fear of clotting. If there is no vomiting, water or very dilute alkalies may be given by mouth, but no fluid food should be taken for the first twenty-four hours. Restoration of the physiological activity of the bowel probably requires a still longer interval.

Pain is a constant postoperative symptom and morphine is a very important therapeutic agent for its relief. It should be given freely during the first twenty-four hours, moderately during the second, and sparingly or not at all during the third twenty-four hour period. If the patient is doing badly such a rule cannot be adhered to and morphine should be given freely to the end.

Distension of the abdomen is a variable symptom, but is generally fairly marked and contributes much to the patient's discomfort. It is best treated by colonic irrigation, pituitrin, and local heat, when the latter may be applied without discomfort to the patient. Fowler's position is particularly valuable in wounds of the lower abdomen since it helps to localize the inflammatory process. It also helps to relieve the distension, especially when a rectal tube is made use of from time to time. The position may be maintained fairly continuously for the first forty-eight or seventy-two hours.

Vomiting is usually present and may become a distressing symptom. It is caused by the postoperative ether toxæmia, the peritoneal traumatism incident to the wound and the operation, to an advancing peritonitis, or to a dilated stomach. If withholding of fluids by mouth for a few hours does not result in an early cessation of vomiting, gastric lavage with warm water, with or without sodium bicarbonate, repeated at two or four hour intervals, is the most effective means of treatment. In all the conditions named, except the advancing peritonitis, lavage usually gives effective relief.

The length of stay in the hospital in which operation has been performed and definitive treatment given should be from seven to ten days, or longer if military necessity will permit it. The period named brings the average patient far enough along in his wound healing and general convalescence to permit a safe evacuation to the rear. A certain small number of evacuated cases may develop postoperative complications, but military exigencies will usually allow only the really bad cases to be retained forward for a longer period than the time named. Enderlen and Sauerbruch advised four weeks' postoperative stay, but this is generally impractical.

Above all, careful nursing and continuous care on the part of the surgeon must be available, or many patients will suffer and a certain number succumb who otherwise might be saved. The dressings must be done by the most experienced hands available, the operator or his assistant doing this work whenever it is physically possible. If a ward surgeon dresses the wounds the surgeon himself must supervise his work and personally direct the patient's convalescence.

Postoperative complications. The more frequent and, therefore, important complications are infection, and the development of fæcal and urinary fistulæ; secondary hæmorrhage, nephritis, and pulmonary complications are less often seen.

Infection is encountered in the form of local wound infection, as a localized peritoneal abscess, or as general sepsis. The wound healing is good or bad in direct proportion to the amount of infection present in the abdominal wall. The surgeon's first effort, therefore, in combating wound infection is the prevention of it by painstaking surgery at the time of operation. Careful *débridement* of the abdominal wall and proper placing of the abdominal incision with respect to the wound, combined with the nonsuture of skin and subcutaneous tissues in doubtful cases, are the most important details to be observed. He must also carry out only partial skin closure in the presence of an active purulent peritonitis, as the

parietal wall will necessarily be more or less contaminated. Very disastrous gas and streptococcus infection of the abdominal wall may develop, usually early in the postoperative course, and such a condition calls for wide incision, combined where possible with Carrel-Dakin treatment. Evisceration of considerable intestinal contents may occur with an infected abdominal wound and such cases usually do badly. Immediate replacement of viscera must be accomplished with rapid resuture of the peritoneal, muscular, and fascial layers.

Localized peritoneal abscess is more often a later complication, occurring from a few days to two or three weeks after operation. It may complicate a fæcal fistula. It is the most favorable outcome to be looked for in a case of diffuse peritonitis. Considerable difficulty in making a proper diagnosis of the location of the purulent collection may be encountered. It may be placed in practically any portion of the peritoneal cavity and may point in the buttocks, perineum, or flanks. Cases of infection following local leakage into the retroperitoneal tissues are the most difficult ones to diagnose and treat successfully. The indication in all these cases is drainage by the simplest possible procedure.

General sepsis is relatively infrequent. The fatal cases of peritonitis usually die within a few days before sepsis has become general. It may occur in connection with retroperitoneal infection or with badly infected operative or projectile wounds. No effective treatment has been found to combat general sepsis successfully.

Fæcal fistula is a frequent complication of wounds of the small and large intestine, being encountered most often after suture or resection of the latter. It also follows operation for inaccessible rectal injuries. It may occur at any time in the postoperative course of the abdominal wound, and the fæcal discharge usually appears in either the operative wound or along the original wound tract where inaccessibility has made a careful dissection impossible. Makins cautions us to bear in mind that a bruised intestinal wall without complete entry of the lumen may at times break down with the formation of a fæcal fistula. Such instances have been verified by the findings of a previous exploratory operation. Frequently a fæcal fistula will close spontaneously, particularly one complicating operation. In a small proportion of cases, however, suture or resection may be required to relieve the condition. Every precaution must be taken in such an operation to isolate the general cavity from the operative field; and adequate drainage, preferably with rubber dam, should be provided. Such a type of operation is usually done in the base hospital when it has become evident that the fistula will not close spontaneously.

Secondary hæmorrhage is rare as a sequel to abdominal injuries. It may occur from septic erosion of a large vessel, or from a reopening of a partially healed wound of a solid viscus. The treatment is the same as for primary hæmorrhage.

Any of the inflammatory processes of the lung or pleura may complicate the postoperative course of an abdominal lesion; they are, however, comparatively infrequent. The most striking pulmonary complications encountered by the writer were four cases of pulmonary embolism (diagnosis being made by symptoms since no autopsy could be performed) which were fatal in from one-half to two hours after the intravenous injection of gum solution. The further use of this agent was discontinued by the writer and his associates.

Nephritic complications are comparatively infrequent. The indications for treatment are the same as in civil surgery.

THE TREATMENT OF VISCERAL INJURIES

In a certain proportion of cases the peritoneal cavity is opened without any injury of the viscera. Practically this group may be considered in connection with nonpenetrating wounds of the abdominal wall. The possibility of an infection of the peritoneum from the retained projectile, or from foreign material carried into the peritoneal cavity, makes them definitely more serious than the nonpenetrating wounds. The missile, however, usually becomes encysted, when it may give no symptoms whatever. In rare instances a localized peritoneal abscess may result.

Cases with short tangential wounds, and the occasional cases in which after eight or twelve hours no alarming abdominal symptoms have developed and in which the patient's general condition is excellent, are particularly the ones in which the question for or against operation may arise.

The writer operated upon a case of this type showing a wound in the right portion of the epigastric region passing in an obliquely transverse direction to the left. The wound had been received ten hours previously and only a slight degree of abdominal rigidity and tenderness was present; the man's general condition was excellent. Arguments for and against intervention were made but I finally decided to operate as it seemed very improbable that no hollow viscus had been penetrated. Laparotomy revealed a tract passing slightly downward to the lesser omentum in which a minute shell fragment had lodged, but there was no visceral injury.

When any doubt of the wisdom of intervening exists, operate. It is far better to open every abdominal case which is questionable as to visceral injury than to abstain, for the mortality after operation where no visceral lesion is found is very small and the hazard is a tremendous one if a true perforation of a hollow organ is left without operation. Further, operation always furnishes an opportunity to search for and often to remove the foreign body itself.

Wounds of the stomach. Stomach wounds comprise from 8 to 10 per cent of all abdominal injuries coming to the hospital for treatment. Two-thirds of all gastric lesions show no other accompanying visceral injury discoverable at operation. Wounds of other organs most often encountered are those of the small gut, liver, colon, spleen, and kidney, in the order of their frequency.

The wounds are usually two in number and are most often situated on the anterior and posterior walls. If the anterior opening is small and

the organ was not distended at the time of injury there may be no protrusion of mucous membrane and no escape of gastric contents. Leakage may, however, occur into the lesser sac when none is present anteriorly. If but a single wound is present it is usually of the anterior wall. Under these conditions, great care must be exercised in excluding a posterior wall perforation, for in comparison with the injury of the anterior aspect that of the posterior may be much more difficult to detect. Lesions of the borders and orifices are comparatively infrequent. Considerable damage to the gastric wall is more often seen with wounds of the lesser curvature and those parallel to the walls of the stomach. The more ragged and larger wounds are usually caused by shell and hand grenade fragments and machine-gun bullets fired at close range.

There are local signs of peritoneal irritation but these are definitely less marked than with injuries of the small intestine. Only moderate shock is present in most of the cases; where a severe hæmorrhage has occurred the degree of shock is profound. Exceptionally, there is no gastric leakage into the peritoneal cavity. The cardinal symptom is early and persistent vomiting. Rarely, however, vomiting may be absent. Escape of gastric contents or gas may take place from the abdominal wound. Cannon has shown that bile is a normal constituent of gastric juice and bile may be recognized in the discharge from the wound.

Very rarely, recovery has been reported without intervention. The safe rule to follow is operation in practically every case. The best incision is the median or paramedian. The perforation of the anterior wall of the stomach is readily recognized. The opening in the posterior wall is best sought for through the gastrocolic omentum just below the stomach. Pauchet's approach, recommended by Eastman and some French surgeons, is made through an opening in the mesocolon, the line of dissection passing just above the transverse colon. This frequently gives good access, but it is not recommended for general use as repair work is more difficult when this technique is used. A ragged wound should be trimmed off rapidly before suture. The greatest difficulty in accomplishing a good closure of the stomach wall will be found with wounds involving the lesser curvature and those high up near the cardiac orifice. Gastro-enterostomy should be avoided if possible, for a higher mortality results in the cases in which it is performed. Drainage in gastric cases should be employed only where a fairly well developed peritonitis is present, or if suture of the stomach wound is difficult or impossible. The most important precaution to be observed in the post-operative care of these cases is careful feeding. Only water should be allowed by mouth during the first twenty-four hours, and liquid diet for the following three days.

The seriousness of gastric lesions is in no wise comparable to the grave conditions caused by wounds of the small intestine. A favorable outcome may be possible even if the case is seen a considerable time after receipt of the injury, as peritonitis advances comparatively slowly. Numerous cases have recovered where operation has been performed from twenty-four to thirty-six hours after the receipt of the wound.

The mortality of all gastric wounds is approximately 60 per cent. Uncomplicated wounds of the stomach give a mortality varying from 25 to 50 per cent.

Wounds of the small intestine. Of 688 laparotomies for wounds of the abdomen reported by Abadie 25 per cent were performed for uncomplicated wounds of the small intestine. Wallace in a study of 965 operated abdominal injuries gave a percentage of 26. The proportion of total small intestinal wounds, complicated and uncomplicated, to all abdominal lesions is, according to Abadie, 38 per cent, and according to Wallace 37 per cent.

Wounds of the colon are much more frequently encountered than those of any other complicating visceral lesion. The injuries next in order of frequency are those of the stomach and bladder, while wounds of the liver, kidney, rectum, and spleen are still less often encountered.

Duodenal injuries are fairly infrequent, comprising approximately but 4 or 5 per cent of all small gut wounds. Injuries to the jejunum and ileum are difficult to differentiate in many case reports, and exact figures to determine their percentages are not available. Multiple lesions are almost universally encountered, at times reaching the number of 15 or 20, but the average number to be expected is from 4 to 6. The wound may be small or large depending upon the character of the missile, the velocity at which it is travelling, and the angle of entry into the gut. When the projectile strikes the intestine vertically, two perforations are almost invariably found. As a rule there is a certain protrusion of the mucous membrane, but if the wound is a small one there may be no pouting and such cases may show no leakage. The more nearly parallel the wound is to the long axis of the gut, the more the damage to the visceral wall, and the larger and more ragged is the wound itself. Extensive laceration of the intestinal wall and even complete division of the gut are not so very unusual; in such cases a considerable tearing of the mesentery is frequently found. The mesenteric lesions are especially important from the standpoint of hæmorrhage and because of the necessity for resection with its added shock and operative hazard.

It is generally best to begin the exploration of the gut at the ileocæcal valve, but if the wound is high up the duodenojejunal junction may be first examined. Work rapidly upward, if beginning at the

ileocæcal valve, or downward, if beginning at the duodenojejunal angle, being careful to replace within the abdomen every 8 or 10 inches of segment after its examination. In this way the entire ileum and jejunum with their mesentery are carefully examined for perforations. When a wound of the intestine is encountered clamp the opening tightly, protect it with a pad, and hold it outside the abdomen, and as each lesion is discovered, treat it in the same way. It is a good general rule to refrain from repairing any perforation until the entire length has been examined. I have seen a small gut suture requiring fifteen minutes performed upon a segment of small intestine that later had to be resected because of mesenteric injury. Exception to this rule may be taken when normal bowel and mesentery are present several inches to each side of the lesion or where a large number of perforations with their pad coverings would form a serious obstacle to efficient technique.

Careful search for complicating wounds of the stomach should then be instituted and the lesions appropriately treated. Other visceral injuries should be sought for and the colon should as a rule be the last one explored, as lesions here may necessitate performing a colostomy. If, during the course of an operation, a wound of the colon is encountered, it is wiser to treat it immediately if suture only is required.

The vast majority of small intestinal wounds are satisfactorily closed by a single purse-string suture of silk or chromic gut. Suture should always be practised if possible, as resection is attended with far greater hazard. With numerous small lesions close together, suture is preferable; if gut damage has been considerable, resection may prove to be the better procedure. The best rule is to perform a resection only where suture is impracticable. A double row of sutures should be always employed when resection is done.

The postoperative care of cases of small gut injury has been previously outlined under the general discusssion of penetrating abdominal wounds.

The frequency of wounds of the small intestine and the high mortality attending operation for their relief make these injuries the big problem in abdominal military surgery. Wounds of the ileum give definitely poorer results than those of the jejunum. Rouvillois, in 1917, gave a mortality of 71 per cent in 39 operated cases of uncomplicated wounds of the small intestine. Where these wounds were complicated by injuries of the large intestine the mortality was 58 per cent; by injuries of the stomach, 66.3 per cent; and by injuries of the bladder, 83.3 per cent. Various operators have also testified to the extremely high mortality after operation for associated lesions of the small intestine and bladder. Wallace gives a mortality in uncomplicated small gut

injuries of 65.9 per cent; in injuries complicated by other visceral lesions, 74.1 per cent. Resection gives regularly a mortality 50 per cent higher than does suture.

Wounds of the colon. Wounds of the colon represent about 25 per cent of all intra-abdominal visceral injuries; approximately two-thirds of all colon lesions are uncomplicated ones. The frequency with which the various parts of the large intestine are involved and the associated hollow viscus injuries with lesions of various segments are well shown in a table published by Wallace. Less frequently, complicating

Site of wound	Alone	With involvement of stomach	With involvement of small gut	Total
Cæcum	16	2	13	31
Ascending colon	36	0	5	41
Hepatic flexure	24	1	7	32
Transverse colon	15	4	22	41
Splenic flexure	18	0	3	21
Descending colon	17	2	9	28
Pelvic colon	23	0	18	41
Position not stated	6	4	12	22
Totals	155	13	89	257

lesions of the solid viscera, particularly the liver, kidney, and spleen are encountered.

Perforating wounds of the colon are much less often multiple than those of the small gut because of the lack of numerous intestinal coils. The multiple lesions that occur usually involve the pelvic colon. Some of the smaller perforations may be due to minute bone spicules penetrating the bowel wall, and this type of lesion is much more difficult to recognize than an injury primarly due to a missile. Some of the wounds are large and ragged and a complete division of the bowel may be found, but less frequently than in wounds of the small intestine.

Retroperitoneal perforation with its consequent fæcal leakage and cellulitis constitutes one of the difficult problems to be dealt with. The posterior perforation may be a minute one which is difficult to recognize. Injuries of the portions of the gut which are without a mesentery, the ascending and descending colons, are particularly liable to be accompanied by a serious retroperitoneal infection. Retroperitoneal injury of the transverse colon may only be detected when the lesser sac is explored.

The symptoms and diagnosis of wounds of the colon have already been considered in the discussion of abdominal wounds, under the heading of "Diagnosis." The special factors which make diagnosis difficult are the liability to retroperitoneal infection and the inaccessibility of

the splenic and hepatic flexures, particularly the former. A grave acute sepsis may rapidly develop in connection with retroperitoneal cellulitis. Further, the type of peritonitis which the surgeon encounters in connection with perforations of the colon is very likely to produce more aggravated local and general symptoms than that associated with the involvement of the small intestine.

No one incision will satisfy all requirements with wounds of the colon. A median or paramedian incision is best used when a lesion of the transverse or pelvic colon is to be dealt with. The best incision for wounds of the cæcum or of the ascending and descending colon is a transverse one in the flank, for this allows an easy access to the posterior portion of the bowel and a better chance of discovering a posterior perforation. The incision of choice for either of the colonic flexures is a subcostal incision on either side, prolonged vertically downward if additional space is required. This incision is particularly valuable on the left side because of the posterior position and inaccessibility of the splenic angle. The general principles to be followed are:

1. Suture whenever possible to secure a satisfactory closure, and always employ a double row of sutures.

2. Avoid resection; colostomy is to be preferred. If a colostomy is performed a resection done at a later date sometimes gives a satisfactory result.

3. Colostomy is to be advised with large ragged openings, particularly those occurring in the cæcum, descending colon, and sigmoid.

4. Drainage is a most important factor with wounds of the large bowel. Always drain when any doubt of the integrity of the suture line exists, and in every case of proved or questionable retroperitoneal injury.

There is a slightly lower mortality record with wounds of the large intestine than with those of the small bowel, the figure for the former being 58.7 per cent (Wallace). The cases that do badly die from retroperitoneal sepsis, which may be most acute, or from a peritonitis secondary to fæcal leakage, preceding or subsequent to operation. The wounds that are sutured do better than those in which an artificial anus is employed; the latter group gives the high mortality rate of 70 per cent.

Wounds of the rectum. Injuries of the rectum are comparatively infrequent, constituting about 2 per cent of the lesions of abdominal viscera. They are more often uncomplicated by other injuries. Associated lesions which may be encountered are those of the bladder and pelvic colon, or, less frequently, injuries of the small bowel.

The lesions vary in size from small perforations caused by a minute projectile or a fragment of bone, to large extensive lacerations. Wounds of the rectum often show a wound of entrance in the buttock or upper

portion of the thigh, or in the perineum. If the wound is an extraperitoneal one, fæcal leakage posteriorly may occur, with the rapid development of a grave cellulitis.

Intraperitoneal injury of the rectum gives rise to a rapidly developing acute peritonitis which is still more aggravated if complicating lesions are present. A wound of entry through the buttock or perineum in a patient exhibiting symptoms of peritonitis in the lower portion of the abdomen should always make the surgeon suspicious of a rectal injury. Local tenderness in the posterior rectal wall made out by the examining finger in the rectum and associated with evidences of infection in the perineum always suggests an extraperitoneal rectal wound, especially when associated with general symptoms of a septic type.

The extraperitoneal injuries are best treated by careful *débridement* of the buttock or perineal wound, the dissection being carried upward and into the rectum. It may be necessary to open widely the lower segment of the bowel in order that complete dissection of the tract may be accomplished, and that adequate drainage may be most effectively placed in the retroperitoneal tissues. Extensive lacerations of the lower segment may require a colostomy. Intraperitoneal injuries are treated by a median laparotomy with suture of the opening wherever it is possible to accomplish it. Drainage through the lower angle of the operative wound should always be practised, rubber dam being the best material for the purpose. If a suture cannot be made, owing to the depth of the rectal wound in the pelvis, a colostomy should be performed.

The mortality with wounds of the rectum is a high one, figures varying from 65 per cent to 79 per cent. Death is usually due to a rapidly advancing sepsis in retroperitoneal tissues, or to a severe spreading peritonitis. The difficulties in diagnosis and the poor access afforded the surgeon from the position of the rectum in the pelvis are the reasons for the high mortality rate.

Wounds of the liver. Wounds of the liver comprise from 15 to 20 per cent of all abdominal injuries. Approximately three-quarters of all liver lesions are uncomplicated ones. Associated wounds to be considered are, in the order of frequency, wounds of the stomach, kidney, and colon; injuries of other organs are much less often found.

As Eastman has pointed out, clean-cut liver wounds are very unusual. There may be any type of lesion from a small perforation to a slit or a large ragged excavation, and in some cases a loss of liver substance is encountered. Whatever the type of projectile a large wound of exit is to be expected, and lacerations in all wounds is the rule.

Hæmorrhage is always present, varying from a slight oozing to a severe and rapidly fatal hæmorrhage. More often the bleeding tends

to subside spontaneously. Peritoneal symptoms are to be expected from the presence of blood in the peritoneal cavity. A dulness in the flanks, particularly on the right side, may be made out if the amount of bleeding has been considerable. A case seen two or three days after the injury frequently shows a slight degree of jaundice; late jaundice usually means sepsis. Where the loss of blood has been considerable the patient exhibits a marked degree of shock.

The diagnosis of liver injury is made from the position of the wound and the symptoms of intra-abdominal hæmorrhage. The early appearance of jaundice should make one suspicious of liver injury.

As a general rule the expectant treatment should be followed. Operative intervention should be made when other visceral lesions are suspected, where the hæmorrhage is serious and progressive, or where the foreign body retained is a very large one. The incision best suited for the management of liver wounds is a right subcostal one, though a median or paramedian approach may give perfectly adequate exposure. When the abdomen is entered, if a small wound is found without active hæmorrhage, leave it alone. A larger wound from which the bleeding has ceased should be packed or sutured, preferably the latter, for secondary hæmorrhage from such a wound is not unlikely. In placing sutures use a large round needle, blunt end first, the suture being of a mattress type. This form of suture should not be drawn tightly in order to prevent its cutting through the liver substance. A properly placed suture will effectively control a very active hepatic hæmorrhage. The retained foreign body, if of considerable size, should be removed in order to avoid the subsequent complication of liver abscess. The shock present should be treated with heat, administration of fluids, and adequate doses of morphine. Where the loss of blood has been considerable and the hæmorrhage is no longer active, transfusion should be performed. The removal of retained missiles from the liver by the method of Pétit de la Villéon, under X-ray illumination and without adequate exposure, is not advised, as it is considered too hazardous.

A considerable number of uncomplicated wounds of the liver treated expectantly get well. The cases of this type operated upon give a mortality of about 30 per cent, while double this mortality rate is to be expected if other complicating lesions are encountered. Certain of the cases with retained foreign body in the liver develop a hepatic abscess and may succumb to sepsis.

Wounds of the gall-bladder and bile ducts are so comparatively infrequent that any special consideration of them will be omitted.

Wounds of the pancreas. The cases reaching the hospital comprise about 0.5 per cent of all abdominal injuries. The proximity of

the organ to the great vessels may give a rapidly fatal result upon the field of battle so that a certain proportion of these cases never reach the hospital.

The accompanying lesions usually found are those of the stomach; other organs are much less frequently involved. The one important element to success is adequate drainage.

At least half of the cases prove fatal from an undiscovered or poorly drained injury. The author had one case showing an anteroposterior wound in the epigastrium. Operation revealed a small shell fragment lodged in the head of the pancreas with an associated contusion but no penetration of the adjacent duodenal wall. The foreign body was readily removed, the wound in the pancreas drained, and the patient when last seen, seven days after operation, was convalescing satisfactorily.

Wounds of the spleen. Wounds of the spleen are much less frequent than those of the liver, the surgeon encountering one splenic wound to every three of the liver. Depage states that two-thirds of the splenic wounds show complicating lesions, but in Wallace's series but one-third of the cases showed associated injuries of other organs.

The injuries may be of all types, from a small perforation or moderate laceration to a complete separation of a considerable portion of the organ, or an avulsion from its pedicle. The visceral injury most frequently complicating a splenic wound is a lesion of the kidney; organs less often involved are the colon and stomach.

As with wounds of the liver, hæmorrhage is the chief symptom along with the shock resulting from it. The intra-abdominal signs of hæmorrhage described under wounds of the liver apply equally to splenic wounds. The fluid, however, is more apt to accumulate in the left flank. The diagnosis is made from the position of the wound and the accompanying signs of hæmorrhage and shock.

The best incision of approach is the left subcostal, but a left rectus incision may give adequate access. In some cases a liberal median or paramedian incision may give abundance of room. The incision for abdominothoracic injuries will be dealt with in a subsequent paragraph. Where the hæmorrhage is inactive and has not been of large amount abstention is the best rule to follow in an uncomplicated case. A small wound encountered at operation and showing no active hæmorrhage should be left alone. Suture in the splenic tissue is less effective in controlling hæmorrhage than in liver tissue, and a continuation of the bleeding is always a possibility. Packing in cases of this sort is desirable. In the vast majority of cases, as Depage well emphasizes, splenectomy should be the rule, as it gives definitely better results. The treatment of hæmorrhage and shock is the same as with liver injuries.

The mortality rate is almost twice as high as that for liver injuries, varying between 50 and 60 per cent. Hæmorrhage is the cause of death in practically all the uncomplicated cases.

Wounds of the kidney. Wounds of this viscus constitute 7 or 8 per cent of all abdominal injuries; one-half of the cases are uncomplicated. Wounds of the right kidney are complicated by liver injuries in about one-third of all cases, and wounds of the left kidney are attended with splenic lesions almost as frequently. The hollow viscera most often wounded are the small gut or colon, while stomach lesions are less frequently encountered.

Wounds of the hilum include injuries to the renal vessels or to the pelvis itself. Wounds of the renal vessels are usually serious and often fatal because of the severe hæmorrhage. It is well to bear in mind that an injury to any of the renal branches results in necrosis of that portion of the kidney tissue which the vessel supplies, as the anastomotic circulation of the kidney is very poorly developed. Injuries of the pelvis itself are comparatively rare and require no further discussion.

Wounds of the parenchyma may be of any type from a simple perforating or tangential wound to a very extensive laceration or destruction of the organ. Fullerton calls attention to the various factors contributing to damage of the kidney tissue: direct injury to the organ or to its blood supply, and pressure effects from hæmorrhage and sepsis.

The X-ray gives important aid in arriving at a correct diagnosis in this group of cases. Hæmorrhage as well is an important symptom; the bleeding may occur from the external wound, it may appear in the urine, or may form a retroperitoneal hæmatoma. Bleeding into the peritoneal cavity may take place if the rupture has been intraperitoneal. Under such conditions one may expect a tender and rigid abdominal wall with dullness in the flank. Under any circumstance, if loss of blood has been considerable the patient may exhibit symptoms of shock.

Leakage of urine is present when the pelvis of the kidney has been opened or the ureter has been torn, but seldom with wounding of the parenchyma itself.

Retention of urine is seen in a certain proportion of cases. Sepsis is a later complication, which may develop where inadequate drainage has been established, or where hollow visceral complications have resulted in a fæcal fistula into the wound. Cases with sepsis exhibit all the symptoms common to this condition. Vomiting is frequently seen. Out of 42 cases reported by Fullerton, arriving at a base hospital with kidney lesions, 9 suffered a secondary hæmorrhage: 1 on the third day, 1 on the seventh day, 5 between the tenth and fifteenth days, and 2 after four weeks.

Conservatism should be the key-note in the treatment of lesions of the kidney. With a penetrating rifle wound and where there is no evidence of intestinal involvement, rest and a liberal administration of opium are indicated. Alarming hæmorrhage, urinary leakage, advancing symptoms of sepsis, or a large retained foreign body are the principal indications for operative intervention. A complicating hollow visceral injury requires immediate operation. The incision of choice is a transverse or oblique one, which may be extended as far forward as is necessary to give adequate exposure of the kidney or to treat other complicating visceral injuries. If a small lacerated wound with a retained foreign body is encountered, the removal of the missile and drainage may be all that is necessary for a satisfactory recovery. Charles advises under these circumstances a *débridement* of the damaged kidney tissues, followed by suture and drainage. A rubber covered clamp upon the renal vessels during this procedure gives satisfactory control of hæmorrhage. If such dissection can be done with little sacrifice of kidney tissue, I believe it to be a legitimate procedure. Nephrectomy should be avoided wherever possible, for in the push of advanced war surgery, definite information as to the function of the other kidney must of necessity be lacking. Nephrectomy, however, must be performed where the vessels themselves are seriously damaged or where the injury to the kidney itself is extensive.

The mortality in uncomplicated cases varies from 25 to 30 per cent. The fatal cases far forward succumb to hæmorrhage. In the rear areas sepsis and secondary hæmorrhage are the chief factors leading to death.

Wounds of the ureter. Wounds of the ureter are infrequent. A gross injury calls for nephrectomy. Where a small wound is encountered suture may be attempted but, in general, ureteral wounds will heal spontaneously if left alone.

Wounds of the bladder. Injuries of this organ comprise approximately 5 per cent of all abdominal lesions and one-half of the cases are uncomplicated.

In Fullerton's series 70 per cent of the cases were complicated by intestinal or bone injuries or both. A wound of the rectum may be expected in from 10 to 15 per cent of the cases. Injury of the prostate is comparatively rare.

Cathelin, in a series of 29 bladder wounds, found that the entrance was placed posteriorly 18 times, anteriorly 7 times, and laterally in the remaining cases. A wound of exit was present in but 5 of the patients.

Bladder perforations may be caused by either the projectile or by bone spicules from the fractured pelvis. The lesion of the bladder may be extraperitoneal or intraperitoneal and may vary considerably in size.

Legueu has reported 10 cases of fracture of the pelvis associated with bladder injury in which a vesical calculus was demonstrable. Other observers have not so uniformily encountered such conditions.

Hæmorrhage in connection with bladder wounds is usually not serious but its occurrence into the bladder suggests an extraperitoneal lesion. With this type of injury a considerable hæmatoma is not infrequently found in the vicinity of the wound in the viscus. Urinary discharge through the entrance wound is fairly uncommon. An empty bladder should make one strongly suspicious of an intraperitoneal perforation. Leakage of urine into the peritoneal cavity causes a considerable degree of peritoneal irritation with definite local signs.

Most of the extraperitoneal lesions result in pelvic cellulitis. In the long standing cases associated bone necrosis and calculus formation may be expected, and in most instances a cystitis still continues.

Extraperitoneal lesions are best treated by wide incision down to the bladder wound, which should be sutured if possible. Ample drainage of soft tissues must then be provided. Suprapubic cystotomy furnishes the best type of bladder drainage and should generally be employed.

The patients suffering from intraperitoneal wounds, and especially those with associated visceral lesions, show such decided symptoms that little doubt exists as to the wisdom of laparotomy. Such lesions require operation with suture of the bladder wound and rubber dam drainage down to the stitch line. A retention catheter or perineal drainage, preferably the former, meets the indications; suprapubic cystotomy should be avoided if possible.

Retained missiles are fairly frequent in the bladder. The projectile must always be sought for within the bladder, and if present removed.

In the latter stages of bladder wounds one must consider the treatment of persistent urinary fistulæ, calculi, and sepsis. Cathelin's method of dealing with persistent fistulæ is an efficient one. He dissects a cuff of skin and infolds it by suture down to the bladder wall, later bringing muscle and aponeurosis over it. Calculi had best be removed by the urethra, with or without crushing, but a suprapubic cystotomy may be necessary. The treatment of sepsis is supportive but the cases usually result disastrously.

The presence of complicating injuries may require considerable modification in operative technique. If a rectal or colic injury is so extensive as to make a colostomy imperative a suprapubic cystotomy should be dispensed with.

Very variable statistics will be found in the literature concerned with the mortality rate following uncomplicated bladder wounds, but the average is about 50 per cent. Where the bladder injury is associated

with a lesion of the small intestine a much higher figure is reached, running to 75 or 80 per cent. The causes of death are sepsis, general peritonitis, or, much more rarely, a secondary hæmorrhage from the pelvic vessels.

An important prophylactic precaution in the avoidance of bladder wounds consists in an invariable order that soldiers should empty their bladders before going into action.

Abdominothoracic injuries. This complicated type of wound has been the subject of much discussion, particularly with reference to the proper mode of treatment. Space will not permit anything more than a summary of the question.

These wounds comprise about 12 per cent of all the abdominal injuries coming to an advanced hospital for treatment and a similar percentage for all thoracic lesions. Lilienthal and his associates, in 67 thoracic cases, found complicating abdominal wounds in 11 per cent.

The lesions encountered are thoracic, diaphragmatic, and abdominal. Duval gives the general rule that with a wound of entry in the chest the thoracic lesions are more apt to be the serious ones, while with entry through the abdomen the abdominal injuries are more often the graver ones. There are frequently several wounds of the lungs and more than one lobe is occasionally involved. The types of lesion are the same as one encounters in simple thoracic wounds. A certain amount of hæmothorax is always present but the amount is variable. In approximately one-third of the cases a hollow abdominal organ is penetrated. An uncomplicated liver injury is more common than one of the spleen. The organs most often injured simultaneously with the liver are the right kidney, the stomach, and the colon; those wounded with the spleen are the left kidney, the stomach, and the pancreas.

The wound in the diaphragm may be made either by the projectile or by a fractured rib. The diaphragmatic wound may vary from a small puncture to an irregular opening of large size; the shape is often slit-like, in which instance it is usually not more than an inch long. In about 10 per cent of the cases herniated abdominal organs will be found in the chest cavity. The omentum is the structure most often seen, and if viscera are extruded into the thorax the omentum usually accompanies them. Next in order of frequency are the spleen, stomach, and transverse colon. Practically all herniations occur through a wound in the left side of the diaphragm.

Through-and-through wounds involving both sides of the diaphragm are seldom encountered in the hospital for most of them die far forward before evacuation can be carried out.

The pathogenic symptoms of abdominothoracic wounds are dyspnœa,

the breathing being rapid and labored; sudden pain in the abdomen at the time of the receipt of the wound; hæmothorax; abdominal rigidity over the corresponding half of the abdomen, especially in its upper part; and shock, which is partially dependent upon the degree of hæmorrhage and partially upon the respiratory distress. Other abdominal symptoms such as definite local tenderness and vomiting may also be evident. Depage has called attention to the displacement of the heart to the right with herniation through the diaphragm.

The course of treatment to be adopted depends upon the types of injury. If there are separate wounds of entrance for the abdomen and chest and the latter one is not a blowing wound, the abdomen should be opened immediately if a hollow visceral lesion is suspected, and the chest should be left undisturbed. With a wound of entrance on the right side of the chest authors vary as to the procedure to be adopted. I believe that if the missile is a small one and X-ray examination localizes it in the liver the wisest course is non-intervention. If the chest wound is a blowing one it should be closed by suture in which the muscular layer is included. No blowing chest wound should ever be allowed to get past the regimental dressing station without a closure of the muscular layers of the wound by suture. This rule should be adhered to even if asepsis cannot be maintained. Many advised operation in this group of patients, the steps being *débridement* of the chest wall, and exploration of the diaphragm and liver through an intercostal or vertical wound after the chest lesions have been cared for. The foreign body is removed from the liver when possible, the diaphragm sutured, and finally the chest itself closed without drainage.

With a wound on the left side above the level of the eighth rib, and an associated abdominal injury which is high up, a different problem is presented. Excellent constructive surgery has been developed by Duval in cases of this type. He uses a vertical incision upon the chest wall beginning near the thoracic wound. The ribs are sectioned in order to allow access to the thorax, and the prolongation of the wound downward opens the abdomen; at times this lower extension may be continued obliquely forward. Other surgeons employ a transpleural approach to the upper abdomen with an incision which is roughly transverse. A rib may be resected, or access may be had through an intercostal space with the aid of Lilienthal's rib spreader. The chest wound is carefully dissected out and any soiled rib or loose bone fragments are removed. With fresh instruments the pleural cavity is explored and any lesions encountered are taken care of. The wound in the diaphragm is then sought for, and enlarged up to 5 or 6 inches: this exposure gives a satisfactory approach to the abdomen. Any abdominal injury found is cared for and

the diaphragm closed. It is generally wise to obliterate the pleural space low down by suturing the diaphragm to either the lung or the lateral pleural wall. The chest should be closed without drainage.

With a wound on the left side and the point of entrance below the eighth rib the lesion within the abdomen is apt to be more serious. In this group of cases the abdomen should first be dealt with through a separate incision. At times it is possible to deal properly with the opening in the diaphragm from below. If the pulmonary injury warrants intervention it may be explored through an intercostal space. The closing off of the pleural cavity is accomplished as described in the preceding paragraph.

Duval to the contrary, the mortality rate is principally due to the lesion in the abdomen, and is distinctly higher when a hollow viscus has been penetrated. The figure for abdominothoracic injuries is from 55 to 60 per cent, while the mortality rate for abdominal wounds in general is but 50 per cent.

The contributions of the present war to civil abdominal surgery may be summarized as follows:

1. It has shown us the types of tangential wounds which are not infrequently without visceral lesions.

2. It has taught us the unwisdom in most cases of relying upon the so-called expectant treatment of abdominal wounds, and the soundness of early radical operation.

3. It has demonstrated the wisdom of waiting an hour or so before operation is attempted in cases with severe shock. This rule applies, of course, only to those instances where shock is not due to active hæmorrhage.

4. It has taught us the best methods of handling abdominothoracic injuries.

5. It has given us an unusual opportunity to review the whole subject of abdominal drainage, strengthening our convictions that the general peritoneal cavity cannot be drained, but that it is possible to drain a single focus within the peritoneal cavity.

6. It has emphasized again and again that speed, dexterity, simplicity of technique, and the minimum of traumatism are essential to success.

BIBLIOGRAPHY

1. Abadie, J. B. Les blessures de l'abdomen. Paris, 1917.
2. Archibald, E. Canad. M. Ass. J., 1917, vii, 298.
3. Barnes, J. K., and Otis, G. Medical and Surgical History of the War of the Rebellion. Washington, 1876.

4. BICHAT. Bull. et mém. de Soc. de chir. de Par., 1916, xlii, 2116.
5. BOWLBY, A., and WALLACE, C. Brit. M. J., 1917, i, 704.
6. BOWLBY, A. Brit. M. J., 1917, ii, 913.
7. CHAVASSU, M. Bull. et mém. de Soc. de chir. de Par., 1918, xliv, 81.
8. DEPAGE, A. Bull. et mém. de Soc. de chir. de Par., 1916, xlii, 1293.
IBID. Bull. et mém. de Soc. de chir. de Par., 1917, xliii, 691.
9. DUVAL, P. Arch. de méd. et pharm. mil., 1918, lxix, 8.
IBID. Arch. de méd. et pharm. mil., 1918, lxix, 355.
10. EASTMAN, J. R. J. Indiana M. Ass., 1917, x, 417.
11. FIOLLE, J. Paris méd., 1917, vii, 170.
12. FRASER, J., and DRUMMOND, H. Brit. M. J., 1917, i, 321.
13. GIBBON, J. H. J. Am. M. Ass., 1919, lxxiii, 187.
14. LERICHE, R. Presse méd., 1915, xxiii, 221.
15. LILIENTHAL, H. J. Am. M. Ass., 1919, lxxiii, 839.
16. LOCKWOOD, A. L., and KENNEDY, C. M. Brit. M. J., 1917, i, 317.
17. MATHIEU. Bull. et mém. de Soc. de chir. de Par., 1915, xli, 2229.
18. ROUVILLOIS and others. Bull. et mém. de Soc. de chir. de Par., 1917, xliii, 705.
19. TUFFIER, T. Arch. de méd. et pharm. mil., 1918, lxix, 4.
20. WALLACE, C. Lancet, Lond., 1916, i, 502.
IBID. War Surgery of the Abdomen. Philadelphia, 1918.
21. WALTERS, C. F., and others. Lancet, Lond., 1917, i, 207.

SECTION XIX

THE EARLY TREATMENT OF GUNSHOT WOUNDS

BY

EUGENE H. POOL, A.B., M.D., F.A.C.S.

Clinical Professor of Surgery, College of Physicians and Surgeons, Columbia University; Attending Surgeon, New York Hospital; Consulting Surgeon, French and New York Orthopædic Hospitals

CHAPTER I

THE EARLY TREATMENT OF GUNSHOT WOUNDS

THE surgical treatment of the wounded begins on the field of battle; operative treatment is limited as far as possible to well equipped units in the rear. The results are dependent to a marked degree upon the observation of certain precautions by those handling the wounded in the advanced area. These are:

1. Early application of sterile dressings, and non-interference with the wound thereafter except for the control of hæmorrhage.
2. Early and correct application of splints in cases of fractures of the long bones.
3. Immediate control of hæmorrhage.
4. Expedition in the transmission of the wounded.
5. Early administration of antitetanic serum.
6. Prevention of shock.

Although these conditions must be fulfilled as closely as possible yet variations of terrain, the distribution of troops, the intensity of battle activity, transportation facilities, and the position of hospitals modify the details to a considerable extent.

As soon as possible after the wounded man is found, a first aid dressing is applied to the wound. Active hæmorrhage is controlled by a light pressure bandage over the dressing. If this does not suffice, a tourniquet may be applied as short a distance as possible from the wound. The tourniquet is a dangerous but at times a necessary accessory, and should be employed with great caution. The time of application should always be noted on the patient's field medical card. In severe cases of fracture, especially in cases of fracture of the femur, it is of vital importance that the part be immobilized before the patient is moved. To accomplish this, trained stretcher bearers are equipped with Thomas splints for immediate application on the battlefield. The bearers carry the wounded on stretchers to the battalion aid post, which is a relatively sheltered and accessible place where medical officers and enlisted men are stationed. Dressings and splints are examined and readjusted if necessary. Antitetanic serum is administered and the time of administration noted on the field card.

The patients are carried on litters to the ambulances, which are brought as close as possible to the battalion aid post. The ambulances

carry them to the *triage,* or sorting station of the field hospitals of the division. During this trip the ambulances pass the ambulance dressing station, where cases which demand immediate attention are removed. Severely shocked cases are held and treated until their condition has improved enough to allow transfer to the *triage.*

If sufficient ambulances are not available, trucks may be used for the slightly wounded.

CARE OF THE WOUNDED IN THE FIELD HOSPITAL

The four field hospitals of the division, if possible, should be grouped together in an advanced position. In active periods one field hospital may be used for wounded, one for sick, one for gassed cases, and one held in reserve. This group constitutes the *triage* or sorting station. All cases go to a main receiving tent from which they are transferred to the appropriate unit.

An experienced surgeon should direct the distribution of cases and indicate the treatment. Dressings should be inspected and readjusted if necessary, but change of dressings or any other disturbance of the patient, except such as is absolutely indicated, should be avoided on account of the resulting suffering, exposure of the wound, and loss of time. Antitetanic serum should be administered if it has not been given. All fracture cases and cases having joint injuries should be examined by the division orthopædist and, if necessary, splints should be readjusted or applied. Tourniquets should be removed and hæmorrhage controlled. Cases with active bleeding should be dressed and appropriate measures taken to arrest the hæmorrhage. Cases in shock should be sent at once to the shock ward. The nontransportable wounded are sent to the operating room. The transportable wounded are divided into two groups, "lying" and "sitting." They should be transferred as quickly as possible, by truck or ambulance, to the appropriate mobile or evacuation hospital. Severely wounded should always be placed in ambulances; wounded and gassed should not be put in the same vehicle.

Experience has demonstrated that the number of nontransportable cases should be reduced to a minimum; in other words, that as little operative surgery as possible should be done in field hospitals. At best, conditions are poor for major surgery in a field hospital; inadequate material, untrained personnel, lack of nurses, imperfect postoperative care, and early postoperative evacuation are elements unfavorable to success. The important functions of the surgical field hospital are *triage,* treatment of shock and rapid evacuation. As Grissinger[1] says, the tendency is to accumulate too much material and to attempt

entirely too much surgery close to the front. The field hospitals should always be cleared as rapidly as possible in order that they may be mobile at all times.

Equipment should be so limited as to be readily transportable. The personnel should include two operating teams and sufficient medical officers and enlisted men to care for the wounded before and after operation. It is vitally important that *triage* and shock treatment should not be neglected by diverting too much of the personnel of the field hospitals into the operative section. Corps or army operative units, such as mobile hospitals, should be placed sufficiently close to relieve the division of this responsibility, and the division should throw the burden of operating as far as possible upon these corps or army units.

Decision in each case as to the advisability of transportation or immediate operation must depend upon local conditions, such as transportation facilities, condition of the roads, and especially the time necessary for transportation to an adjacent hospital. In general the cases which should be regarded as nontransportable are those with:

1. Sucking thoracic wounds, which must be sutured, unless satisfactorily controlled by strapping. Elaborate operative procedures should not be undertaken. At times suture of these wounds has been done as far forward as the battalion aid post.
2. Abdominal wounds, especially if bleeding.
3. Cases which have reacted from a marked degree of shock and are not in fit condition for transportation. These are chiefly cases with multiple wounds and fractures of the femur.
4. Cases with active hæmorrhage.

Other cases can usually be transported to the rear, where better facilities for operation and after-care will more than compensate for the delay.

MOBILE AND EVACUATION HOSPITALS

Mobile and evacuation hospitals drain the divisional *triages*. They are fully provided with surgical facilities and are advantageously placed for the evacuation of patients. The surgical staffs of such units consist of trained teams, each team having an operator, assistant, anæsthetist, nurse and two enlisted men. In addition to the trained nurses attached to the teams, there are also sufficient nurses to look after the operating room and care for the patients before and after operation.

The mobile hospitals must be mobile and expansible in operating capacity. They are placed as far forward as conditions warrant, and should receive the seriously wounded who are not actually nontrans-

portable. The evacuation hospitals, being more permanent and less mobile, are farther to the rear.

Grouping of evacuation hospitals is a distinct advantage in economy and efficiency. Grissinger states that each group should have a medical and surgical section, and a section for gassed cases; that the surgical section should have separate services for slightly wounded and severely wounded. As he emphasizes, close attention should be paid to the slightly wounded, because early and expert attention to this group assures quick return to duty with consequent conservation of man power.

In general, cases should be evacuated from mobile and evacuation hospitals as soon as possible. As a rule, early evacuation after operation is preferable to evacuation on the third and fourth day when infection may be a contra-indication.

SHOCK[1]

Shock is a condition of depression resulting from injury. It is represented clinically by pallor, cold moist skin, weakness, diminished sensibility, rapid weak pulse, lowered blood pressure, and rapid shallow respirations. The most characteristic and important feature is the lowered blood pressure. As Crile (2) states, shock occurs in battle activities more than with casual accidents in quiet trench warfare. Thirst, insufficient food, loss of sleep, anxiety, excitement, cold, exposure, and pain predispose to its development. Injuries associated with considerable hæmorrhage are accompanied by a more profound degree of shock than bloodless injuries of the same extent and character. Shock of severe degree is frequently associated with fractures of the femur. Its occurrence, however, can be minimized to a considerable degree by early splinting. Cannon (3) and others have made observations which suggest that the sudden removal of a tourniquet may accentuate or produce shock by flooding the system with toxic material.

In the treatment of shock rest, warmth, and fluids are the first essentials. Cannon(3) has pointed out the importance of the loss of heat that occurs in the shocked patients from excessive perspiration; and the added stagnation in the superficial blood vessels with further lowering of the blood pressure resulting from the lowered temperature. Frequently the application of external heat alone will promptly raise the blood pressure in a shocked patient. During transportation, therefore, the patient should be kept warm by proper blanketing and the application of external heat. In the absence of hot water bottles, canteens may be used for this purpose.

[1] This subject is discussed more fully in Volume II, Section VI, Chapter VII.

Morphine diminishes the activities of the tissues and the demands for oxygen and relieves pain. It should be given in moderate doses unless the patient is cyanosed. Crile believes that cyanosis is an indication of acidosis and that morphine aggravates the condition.

Fluids should be administered freely by mouth, rectum, or by hypodermoclysis, depending on the severity of the case. If the blood pressure is below the critical level (80 mm. of mercury) and does not rise after a short period of treatment by rest, warmth, and fluids, blood transfusion should be performed. (The technique of blood transfusion is described in Volume I, Section IV, Chapter IV.)

Substitutes for blood are not nearly so efficient, but in the absence of suitable donors they should be employed. Intravenous salt solution is often used. It should be given slowly at a temperature of 116° or 118° F., and in sufficient quantity to produce distinct improvement in the pulse and heart action. Adrenalin, which raises the blood pressure, is often administered with it; 1 c.cm. of a 1 : 1000 solution may be added to 500 c.cm. of salt solution. Unfortunately salt solution in a large proportion of cases has only a temporary effect upon blood pressure. To glucose solution there is the same objection (Cannon). Sodium bicarbonate in 5 per cent solution has been employed with the view of combating the associated acidosis, but has proved disappointing. Gum solution (6 per cent gum acacia in 0.9 per cent sodium chloride solution) has been advocated by Bayliss (4) and Cannon. Its value is believed to lie in the fact that a colloidal solution does not escape from the blood vessels and causes a permanent rise of pressure. It has proved satisfactory in many cases, but in a certain number it has been attended by disappointing results. It cannot be said to have passed the experimental stage and must be further tested before its general adoption can be recommended. Stimulants which act upon the central nervous system are for the most part useless and may be harmful.

The depressing influence of an anæsthetic must always be taken into account. Loss of body heat, as a result of exposure of the patient in a cold operating room, and rough handling of the tissues, especially the abdominal viscera, further favor shock. In a series of cases Cannon observed that the systolic pressure fell during operation from 88 to 62 mm., and the diastolic from 62 to 31 mm. There was also a marked drop in the alkali reserve and the sodium bicarbonate content of the blood as indicated by a lessened carbon dioxide content of the plasma. Under certain conditions, however, operative procedures are unavoidable. Hæmorrhage must be controlled promptly, and penetrating wounds of the abdomen must be explored. If general anæsthesia is necessary nitrous oxide and oxygen should be employed, preceded by a hypodermic

injection of morphine and atropine. If an operation must be undertaken upon a man in a condition of shock, transfusion of blood, or, if this is impracticable, an intravenous saline infusion should be administered during the operation. The anæsthesia should be smooth and even. The operation should be rapid, the manipulations gentle, the dissection clean

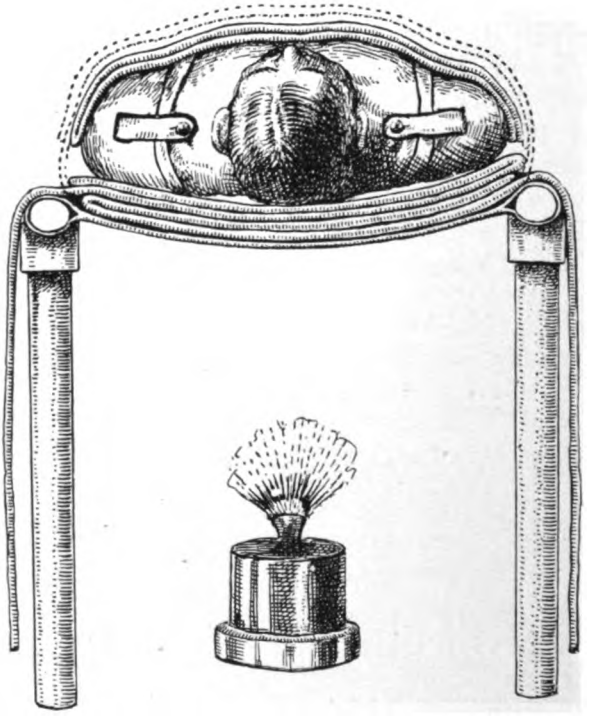

FIG. 361. DEVICE FOR WARMING PATIENT IN SHOCK. (*After Allison.*)

cut, hæmostasis thorough, and the exposure of viscera reduced to a minimum.

At the ambulance dressing stations, field hospitals, mobile and evacuation hospitals, special shock rooms, or wards, are arranged for the treatment of shocked patients. Special men, designated as the shock team, direct the treatment and are provided with blood pressure apparatus, transfusion equipment, etc. In the advanced areas frames are arranged upon which stretchers can be supported; blankets are draped from the stretcher to the ground and heat is provided by means of a small stove placed on the ground in the space thus formed (Fig.

361). Candles or tins of alcohol can be used if stoves are not available. In the hospitals shock beds are arranged by placing a frame over the patient and covering this with blankets. The patient is heated by means of a pipe leading from a small stove into the space under the frame.

THE EARLY TREATMENT OF FRACTURES

The advantages of standardized methods of treatment of fractures at the front based on the use of a small number of effective splints was amply demonstrated in the work of the American army in France(5).

Of the various splints adopted the most important was the Thomas splint, consisting of two iron rods continuous at one end for the application of traction, and united at the other by a ring of padded wire



FIG. 362. THOMAS TRACTION LEG SPLINT.

which permits the upper end of the splint to be pressed against a fixed point. The Thomas arm splint, the Jones arm splint, and the hinged modifications are variations of the same principle.

The Thomas leg splint (Fig. 362) and the hinged, half-ring modification (Blake-Keller, Fig. 363) are applicable for nearly all injuries of the lower extremity below the hip joint, especially for fractures of the femur, injuries about the knee-joint, and fractures of both bones of the leg. The modified splint is more easily packed and carried in bulk and is more easily applied than the Thomas splint. To adjust one of these splints the thigh is flexed while traction is exerted in the long axis of the limb by gripping the ankle. The splint having been slightly bent at the knee, the ring is firmly pressed against the tuberosity of the ischium. The canvas anklet (Fig. 364) is put on, or some form of hitch is made about the ankle without removing the shoe. In the method described by Collins (*Annals of Surgery*, 1916, xlix, 65) a strong bandage 3 inches wide and 2 yards long is used as a hitch (Fig. 365). After the hitch has been made or the garter applied, the bands lying on each side of the ankle are carried around the respective sidebar and tied over the notch at the end of the splint while traction is being exerted upon

them. The Spanish windlass (Fig. 366) may then be employed. The slings for support of the limb may be of wire gauze or of muslin. A bandage is applied around the limb and splint to secure perfect immobilization. The end of the splint is suspended from a litter bar attached to the stretcher (Fig. 367).

The hinged modification of the Thomas arm splint (Fig. 368) is useful for injuries of the upper arm, elbow, and forearm where fixation

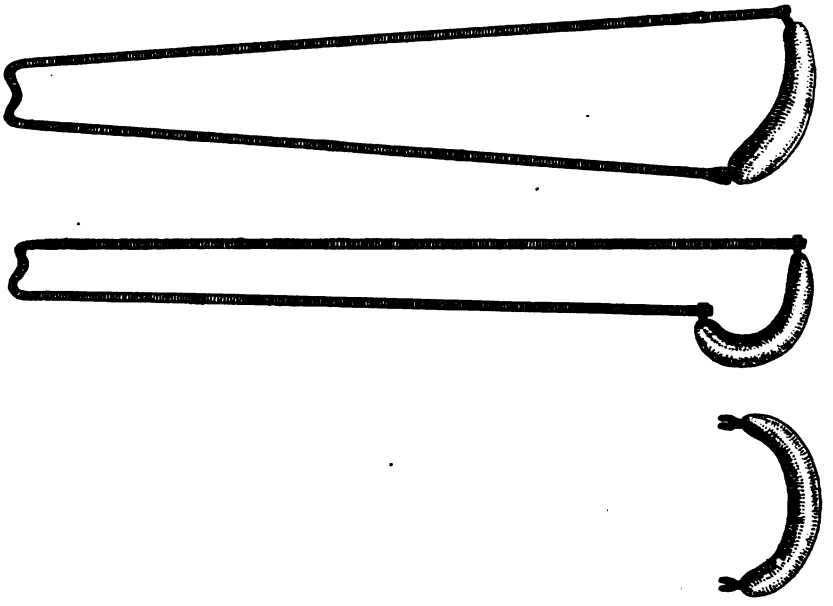

FIG. 363. HINGED MODIFICATION OF THOMAS LEG SPLINT.

and traction are desirable, and where ideal position may be temporarily sacrificed to ease of transportation. The modification consists of a joint between the rods and the ring which permits close apposition of the ring to the shoulder and thorax and still allows the injured limb to be brought to the side of the body. The classical Thomas arm splint may be used in the same way by bending it close to the ring through an angle of 90 degrees.

During the application of these splints the patient is recumbent. The hand should be placed midway between pronation and supination, except in fractures of the forearm when the hand should be more supinated. Strips of adhesive plaster are applied to the forearm for traction; the arm is supported at appropriate points by means of slings tied or pinned

around the rods of the splints; cotton is placed around the limb, and the whole is encircled with a bandage.

The long Liston splint (Fig. 369) is useful for transportation of cases with injuries of the pelvis or hip joint. Since it offers no support posteriorly it should be used with caution. The Cabot posterior wire leg splint (Fig. 370) is useful for wounds of the soft parts and slight injuries of the knee joint without marked effusion, for fractures of the fibula, and for injuries of the ankle and tarsus. It provides immobilization only.

The splint consists of a quadrilateral wire frame covered with a bandage. The upper transverse bar is concave to conform to the convex



FIG. 364. CANVAS ANKLET AND TRACTION BANDS.

surface of the thigh. The splint narrows at the heel and is bent, 12 inches from the end, to form a right-angled foot piece. It should be spread at the heel before it is covered with the bandage. It is retained in position on the limb by three adhesive plaster straps applied near the upper limit of the splint, above the ankle joint, and about the foot proximal to the great toe. Additional supports of light wood or wire ladder splint material may be applied posteriorly and on either side of the limb with webbing straps and buckles (Fig. 371), to prevent rotation.

Ladder splint (Fig. 372) material is made of rods of galvanized iron wire ⅛-inch in diameter, joined by smaller $\frac{1}{16}$-inch wires, ¾ of an inch apart. This material is furnished in 30-inch lengths. It is desirable for coaptation splints or for the fixation of the hand, foot, forearm, elbow, or knee.

With the aid of these various types of splints it is possible to secure immobilization of an injured extremity in practically any desired position. Later, when permanent immobilization is possible, as in a stationary hospital, it may be desirable to substitute more elaborate apparatus in order to maintain immobilization in some position that would manifestly not admit of transportation of the patient.

WOUNDS OF THE SOFT PARTS[1]

The wounded are usually received at the evacuation hospital from four hours to twenty-four hours after the receipt of injury, but during periods of activity the time may be much longer. They present various

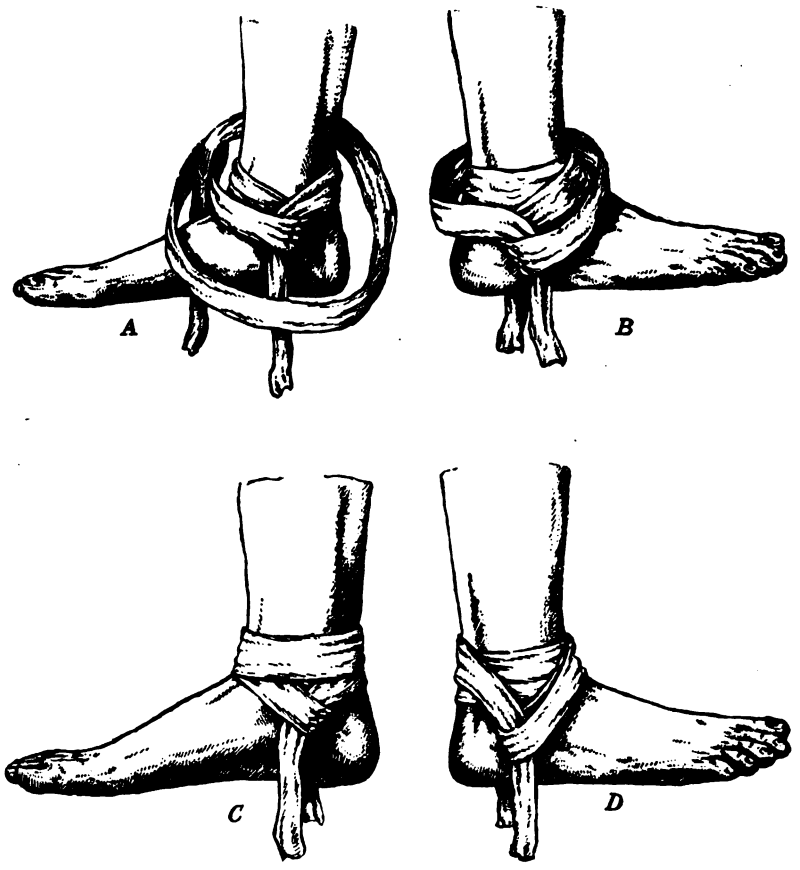

FIG. 365. COLLINS' HITCH.

degrees of shock, hæmorrhage, laceration of the soft parts, and associated lesions. Frequently the wounds are multiple.[2] They con-

[1] Parts of this article have been taken from Pool, Lee and Dineen, *Surg., Gynec. & Obst.*, 1918, xxvii, 289.

[2] In Lemaître's series 2,283 wounded presented 4,227 wounds.

tain pathogenic micro-organisms and in most cases foreign bodies. A few of the wounds already show evidence of gas bacillus infection.

Operative treatment is indicated for the majority of the wounded as soon as possible after the receipt of the injury. Each hour increases materially the danger from infection. Cases that could be saved within four hours are often lost after fourteen; wounds that could be closed successfully within eight hours often become the site of infection and gas gangrene and result in amputation or death if left untreated for eighteen hours.

After the arrival of the patient at the hospital, expedition in the surgical treatment must be effected by the help of a well organized routine. The first essential is the careful sorting of cases at the admission tent. Patients presenting a considerable degree of shock should

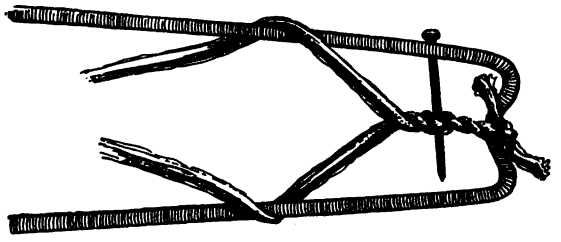

FIG. 366. NAIL TWISTER OR SPANISH WINDLASS.

be left undisturbed on their stretchers and sent to the shock ward. They must first be treated for the shock and operation deferred until reaction is evidenced by a rise of blood pressure. The chief exceptions to this rule are cases with cranial wounds, abdominal wounds, and sucking thoracic wounds. Walking cases and slightly wounded cases are referred to the dressing ward or to the service for slightly wounded. Of the remainder the majority demand X-ray examination and early operation. The dressings are removed and the wounds carefully examined. Those whose condition does not contra-indicate it are bathed. Cases with active bleeding, with sucking thoracic wounds, with penetrating abdominal wounds, with fractures of the femur, with penetrating wounds of the knee, and with multiple wounds receive the first attention. Cases which have reacted from shock may be taken at any time. Cases with uncomplicated wounds of the soft parts are, in general, cared for after the more urgent cases.

The success of operation depends largely upon the thoroughness of the roentgenologist's examination and the accuracy of his findings.

His report should be made on the patient's card according to a definite system. It should include the anatomical site, the size of each foreign body in millimeters, the depth in millimeters, and the position of the part at the time of observation. For example:

"1. Right thigh: F.B. 10x15 mm.; 80 mm. under point marked on skin; limb in extreme outward rotation.

"2. Left leg: no F.B.; fracture both bones, middle third; much comminution."

The operator thus visualizes the condition more accurately than if the report were made in fractions of an inch, or if some relative term were employed. "Millimeter" is always employed to avoid error and confusion.

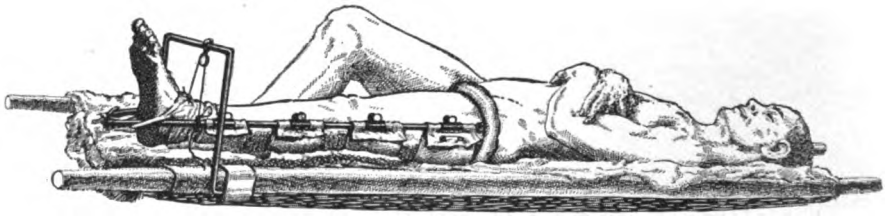

FIG. 367. STRETCHER CRADLE FOR TRANSPORT.

In times of great activity some cases must be operated upon without X-ray examination. These should be carefully selected and should comprise those which apparently do not contain a foreign body or those in which the foreign body is superficial.

The patient should always be examined by the surgeon before anæsthesia is begun. In wounds of the extremities the surgeon should determine whether there is a nerve lesion and an arterial pulse. Apparently innocent wounds of the trunk may in reality be very serious. I have seen a case with a small stab-wound of the soft tissues of the back in which careful examination revealed evidence of a complete transverse myelitis. The possibility of intrathoracic or intra-abdominal involvement should always be borne in mind. Cases in which the genito-urinary tract may have been injured demand examination of the urine.

The preparation of the patient is usually done in the operating room on an extra table while the preceding operation is being completed. The wound is protected with gauze, the part shaved thoroughly, and scrubbed with soap and water over a wide area. Application of chemicals may follow. A common procedure is to cleanse with ether and then apply tincture of iodine. It is important to prepare

a wide field and to encircle the limb in wounds of the extremities. The part is draped with towels and sheets, but attention must be called to the importance of economy in this respect.

A general anæsthetic should be employed except in exceptional cases. Nitrous oxide-oxygen, administered by an expert anæsthetist, is the least harmful. It should be the anæsthetic of choice for patients in a condition of shock, gassed cases, and thoracic cases. Ether, however, is employed in routine cases. Minor operations may often be performed under primary anæsthesia. Local anæsthesia is rarely used.

For convenience of discussion wounds of the soft parts may be subdivided as follows:

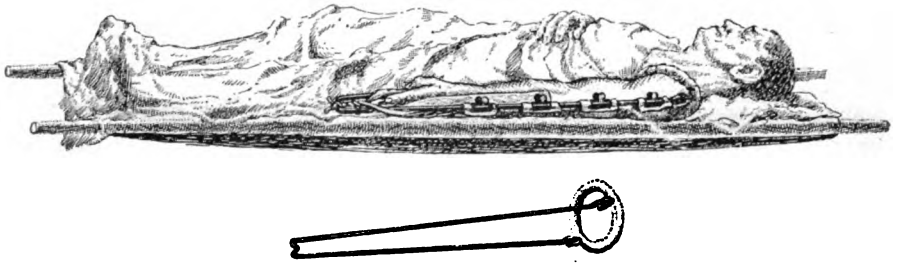

FIG. 368. HINGED TRACTION ARM SPLINT.

1. Wounds by *éclats* or fragments of shells, grenades, or bombs.
   a. Fragment retained; penetrating wounds.
   b. Fragment not retained; perforating, *plai en seton,* through-and-through wounds, or gutter wounds.
2. Wounds by bullets—rifle, pistol, or machine-gun.
   a. Bullet retained; penetrating wounds.
   b. Bullet not retained; perforating, *plai en seton,* through-and-through wounds, or gutter wounds.

A fragment of shell or grenade is of high velocity, irregular in shape, and with sharp edges. In contrast to a bullet it carries with it pieces of clothing and skin into the tissues. Because of its irregular shape it exerts a destructive effect upon the tissues which thus form an excellent medium for the development of the micro-organisms carried in from the clothing and skin. After a latent interval of six hours or more both aerobes and anaerobes proliferate rapidly and penetrate more deeply into the tissues. The local changes and the later systemic effects depend upon the character of the micro-organisms and the tissue resistance.

A bullet at close range exerts a marked explosive force or effect; during the height of its flight, approximately from 300 to 1,500 yards, it penetrates the soft parts with little destruction of the tissues; at long range it loses its steady spinning movement and causes mutilation and laceration. In the majority of cases of perforating bullet wounds the missile passes like a stiletto through the clothing and tissues. Infection does not result because the projectile carries no clothing into the wound, and penetrates with little laceration and traumatization of the tissues. Such cases usually do not require operation since the few organisms

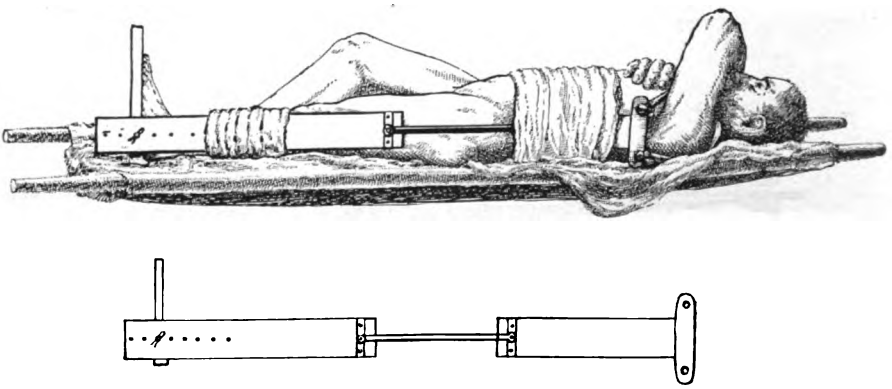

FIG. 369. LONG LISTON SPLINT FOR STRETCHER TRANSPORT.

which are present have not the proper environment for growth. Under certain conditions, however, when the appearance and feeling of the part suggest considerable hæmorrhage or destruction of tissue, perforating wounds by bullets must be treated in the same manner as those made by fragments of shell. The rule is not to operate upon perforating bullet wounds with punctate wounds of entrance and exit, and with little or no ecchymosis, swelling, or tension of the soft parts.

Because of the lower velocity of the shrapnel ball and the fact that some shrapnel balls are embedded in a pitch-like substance which can readily carry foreign material into the wound, shrapnel wounds should in general be treated as if made by a fragment of shell.

The general plan or aim of surgical treatment is the prevention or limitation of infection, the early closure of the wound, and the preservation or re-establishment of function. The first indication is to obtain a clean wound. This is accomplished, primarily, by *débridement*[1] of

[1] This term is used to signify both the incision and the excision of tissues as practised in war surgery.

tissues, that is, by free incision and excision of injured and contaminated tissues and the removal of the foreign material carried by the missile into the wound.

The principle of this procedure may be visualized by considering a typical case of a wound of the soft parts with a track from the skin to the interior of the muscles, containing a fragment of shell and pieces of clothing along its course, and having for its walls lacerated muscle. Pathogenic organisms are present throughout this track. The devitalized pulpified walls of the track furnish an ideal medium for the growth of bacteria. One can readily imagine that immediate wide excision of

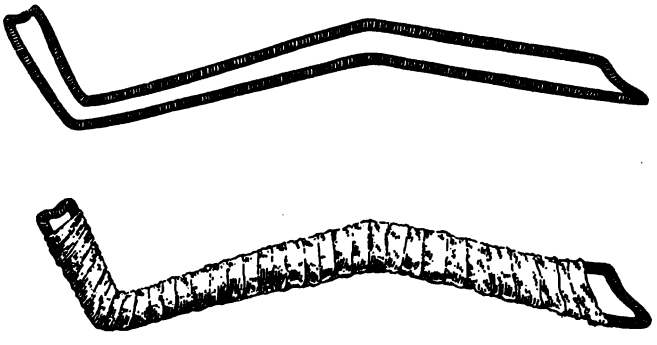

FIG. 370. CABOT POSTERIOR WIRE LEG SPLINT.

such a track as a whole, removal of the devitalized skin, subcutaneous tissues, aponeurosis and muscle, together with the shell fragment, clothing, and micro-organisms contained within the track, will leave a healthy aseptic wound, provided the skin adjacent to the wound has been properly prepared, and the operator has employed a technique comparable to that used in clean operations. To obtain a clean aseptic wound is the ideal aimed at, though it is doubtful if this is actually achieved in any case. But however skeptical one may be as to the total eradication of micro-organisms under the conditions which prevail in these wounds, many wounds after operation undergo repair as if aseptic, and cultures and smears made from them are often sterile.

The closure of the wound may be carried out by immediate or primary suture, delayed primary suture, or secondary suture.

If early and thorough excision is possible and the case can be watched for some days, primary suture may be made. If the operator is in doubt, the wound should be left open and sutured subsequently, either after an interval of from two to six days (delayed primary

suture) or after a longer interval (secondary suture).[1] The determination as to the time depends upon the bacteriologic findings and clinical observation. Obviously the decision as to primary suture in a given case must be attended with much uncertainty; a mistake may readily be costly to the patient. In active periods with a large number of wounded, primary suture should not be considered. It should be employed only in quiet periods and in hospitals where the patients may be watched. In general the wounded are destined to remain in the evacuation hospital for a short time only, that is, from a few hours to a few days, and only rarely for several weeks; consequently, the operative treatment must be so planned that the patient may be evacuated

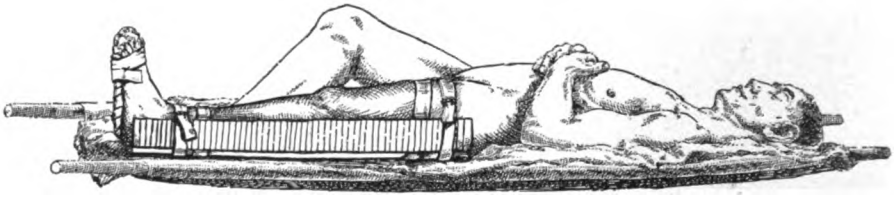

FIG. 371. CABOT LEG SPLINT WITH POSTERIOR AND LATERAL SPLINTS OF LADDER SPLINTING MATERIAL.

safely within a short time. This is not possible if primary suture has been done.

It must be emphasized that even in a rush *débridement* should be properly carried out, and the best possible technique observed. The temptation to relax in these respects during periods of stress should be resisted. The time saved by careless work is not sufficient to warrant the additional risk incurred. Only rarely is it justifiable to substitute incision and drainage for *débridement* in recent wounds.

Technique of débridement. The skin incision should, when possible, be made parallel to the long axis of the limb. This permits wide exposure of the underlying tissues and renders subsequent suture less difficult. A transverse incision should rarely be employed. In the case of a deep transverse perforating wound it is better to make two longitudinal incisions (Fig. 373) and work inward from each rather

[1] The distinction between delayed primary suture and secondary suture is one of wound repair rather than of time. Delayed primary suture is one in which the edges can be approximated and will unite without excision of tissue. Secondary suture is one in which the epidermis has grown inward and must be excised for proper union. In late secondary suture dense granulation tissue must also be excised.

than make a transverse incision with division or excision of considerable muscle tissue. In the former case suture is usually readily done at an early date, whereas in the latter primary suture is often impossible because of the difficulty of uniting the severed muscle. Even when this is accomplished the sutures frequently tear out and allow retraction of the muscle with resulting dead space and breaking down of the wound. When the transverse wound has not been closed primarily, or has reopened, secondary suture is delayed and is more difficult. The functional result is also less favorable on account of the transverse section of the muscle.

Transverse incisions should be employed in the extremities only in superficial wounds involving the subcutaneous tissues or with very superficial involvement of muscle. In the glutæal region and on the trunk

FIG. 372. LADDER SPLINT MATERIAL.

the incisions should in general be in the direction of the fibers of the underlying muscle. Occasionally, as in deep, transverse, through-and-through wounds of the calf, a long median incision may be employed advantageously; the track is exposed in the middle of its course and *débridement* is carried out from this region in both directions. The skin wounds of entrance and exit are excised by small elliptical excisions and the wound edges approximated.

The operation itself consists in the free excision of all tissues with which the foreign body has come into contact and all devitalized tissue, except structures such as nerves, large vessels, and bones whose removal would interfere with the function of the part and cause permanent disability. Free excision, however, does not mean ruthless blind butchery of the parts, but rather, careful, intelligent dissection, with liberal removal of such parts as should be removed, and with equally scrupulous preservation of such parts as may be left with safety.

The wound itself with all contused skin is excised by removing an elongated ellipse of skin. No healthy skin should be sacrificed on the sides of the ellipse as it is important to conserve as much skin as possible in the transverse plane of the limb to facilitate suture. This is especially important in the forearm. There is no advantage in attempting a *débridement* through a short incision. A deep *débridement* demands a long incision. The skin incision must always be vertical to

the skin surface; the tendency to bevel the incision should be avoided as this interferes materially with satisfactory suture.

Attention should be called to the fact that Lemaître prefers to begin with a short incision, say of 5 or 6 cm., and to increase it as the need arises. He does not hesitate to extend the ends inward or outward or to transform the incision into a flap.

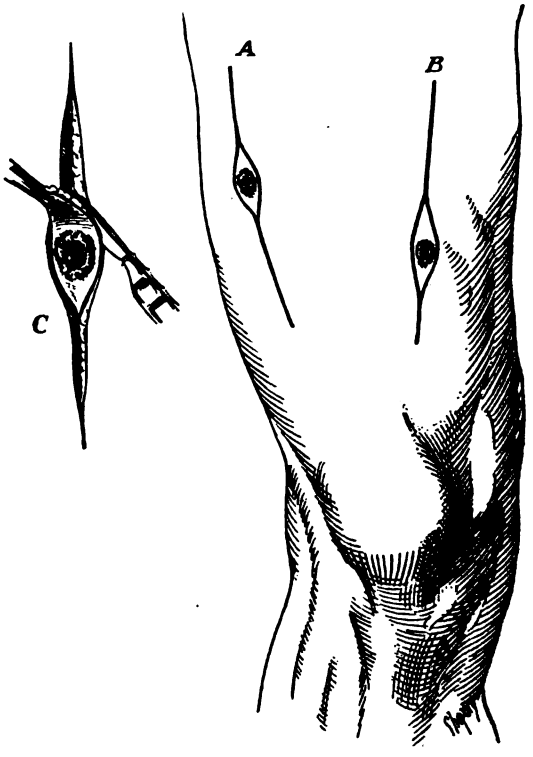

FIG. 373. DÉBRIDEMENT. Excision of the external wound.

When there are two wounds, one or two incisions may be employed as already described. Similarly when the foreign body has taken a transverse or oblique course, penetrated a considerable distance, and lodged in the tissues, two incisions may at times be used to advantage, one over the foreign body and one to excise the wound of entrance, both being used for excision of the track.

After excision of the skin wound, the instruments should be discarded or washed in alcohol. The skin edges are widely retracted and

the subcutaneous tissues removed as far as there is evidence of laceration or contamination. It is not necessary, however, to remove all blood infiltrated subcutaneous tissue. In general, the fingers are kept out of the wound and the dissection made with instruments. Good exposure of every plane by retraction is essential, the edges being rolled outward with toothed retractors of some form of clamp, such as the Allis forceps.

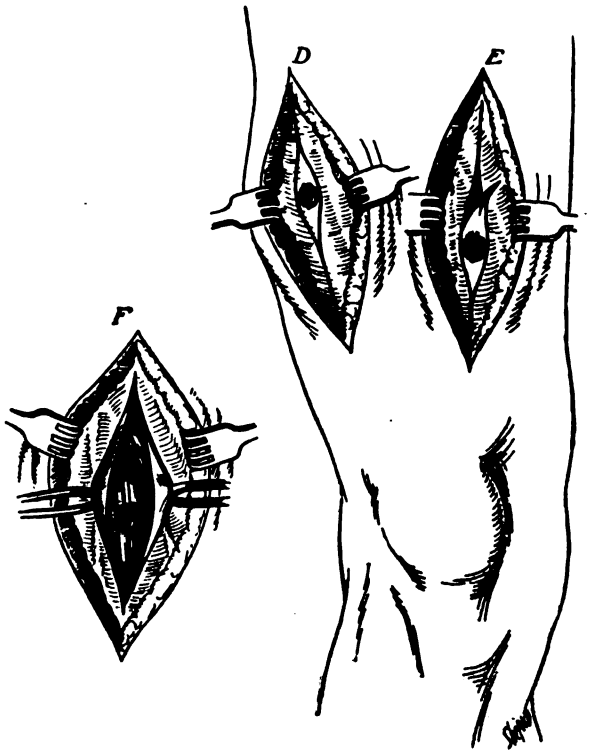

FIG. 374. DÉBRIDEMENT. Excision of the aponeurotic layer.

The aponeurosis is treated in the same manner as the skin, that is, by a long straight incision with removal of the wound by a relatively narrow ellipse (Fig. 374). The aponeurosis is of great value in secondary sutures in the lower extremity and shoulder, and, therefore, should not be ruthlessly sacrificed. It must be emphasized that liberal excision of aponeurosis or skin is not necessary because it is not in these tissues that infection ordinarily originates or develops. The aponeurosis should be widely retracted and muscle planes exposed. It is this tissue that

favors infection. All traumatized and devitalized muscle must be removed. This demands excision for a distance of 0.5-1 cm. on all sides of the track. The dissection is made parallel to the fibers of the muscle (Fig. 375); a long, relatively narrow ellipse is removed so that the sides tend to fall together after the excision. The dissection should be

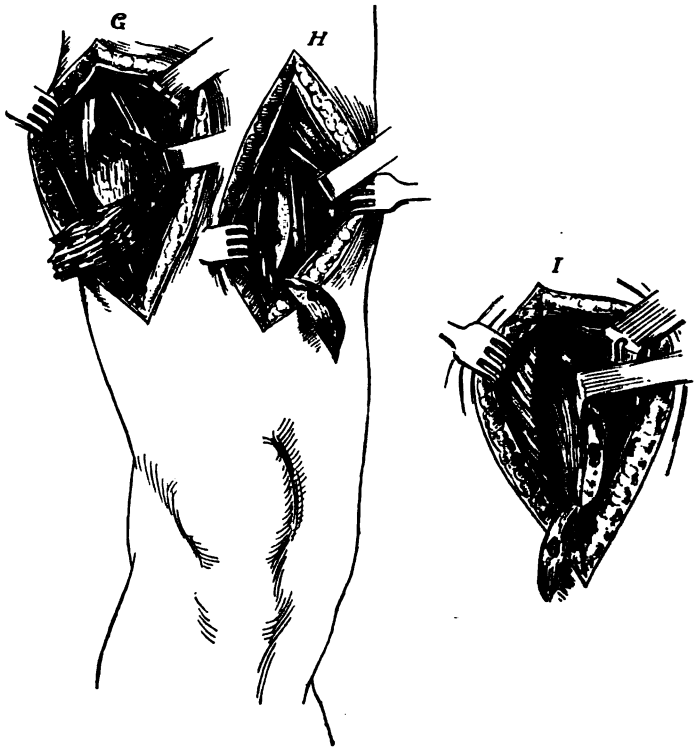

FIG. 375. DÉBRIDEMENT. Excision of injured muscle.

made by planes, muscles should be identified, and the situation of nerves and large vessels should always be borne in mind. The track should be followed by sight, not by probing; for this purpose a reflecting headlight is indispensable. If the track is lost between muscle planes, often slight flexion or extension of the limb will bring it into view. Careful hæmostasis is necessary at all stages. Sponging of blood should be done by pressure and not by rubbing, because the latter method may carry organisms from an infected to a clean part of the wound and may cause a small track to be lost to view (Lemaître). The foreign

body should not be extracted until reached in the dissection, otherwise the parts fall together and the tissues immediately beyond the body, which often contain clothing, may not be adequately excised. When the excision is complete all exposed muscle must look healthy, contract when pinched with forceps and ooze when snipped with scissors; otherwise its vitality has been diminished to such a degree as to favor gas bacillus infection. At times the finger must be introduced to search for the foreign body, but, as a rule, in cases where the track is lost or where

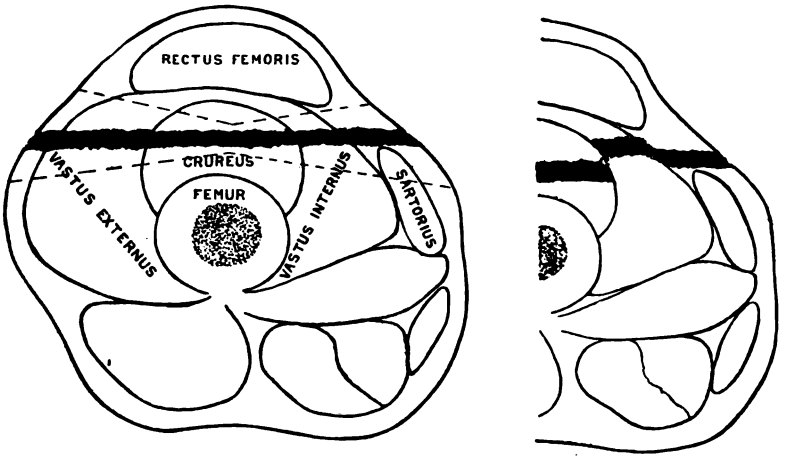

FIG. 376. CHANGE OF POSITION OF WOUND TRACK RESULTING FROM CHANGED POSITION OF LIMB.

for other reasons difficulty arises in locating the foreign body, fluoroscopy should be employed.[1] If this fails, the tissues should not be blindly torn up, but after a careful search one should desist, leaving the wound open and removing the foreign body subsequently, after more careful X-ray localization or under the screen. When the deep tissues are so markedly infiltrated with blood as to suggest the possibility of constriction of the muscles under the overlying fascia, this fascia must be incised so as to free the muscles from internal pressure.

When the fragment or track is in proximity to a large vessel, as for instance, the brachial vein, the vessel should be inspected and, if traumatized, should be treated by ligation and excision of the contused portion, otherwise secondary hæmorrhage is likely to occur. If there is danger of gangrene resulting from ligation a primary suture should

[1] The Bergonie *vibreur* was used to advantage at La Panne and elsewhere.

be performed and the case watched with particular care. In the case of a small lateral wound Lemaitre advises repair of the vessel wall by suture if the neighboring tissues are healthy. Ordinarily, however, it is best to ligate the vessel about 1 cm. above and below the vascular wound and to excise the intervening portion. Though sudden and unexpected hæmorrhage will occasionally confront the surgeon, the absence of an arterial pulse below the lesion and the widespread infiltration of the soft tissues about the wound usually warn the operator in advance of the presence of a vascular lesion. The importance of having a tourniquet at hand at all times is obvious.

Care should be taken to avoid injury to nerves by careless dissection. A severed nerve should be united, and if possible the nerve should be buried within muscle tissue. When preliminary examination shows that a nerve has been injured, it should be exposed above or below the tract early in the operation to avoid traumatization during *débridement.*

When the excision has been completed all hæmorrhage should be controlled. As little catgut as possible should be buried. The wound should be irrigated with saline or Dakin's solution. Ether has been extensively employed for irrigation of wounds after *débridement,* but it probably has not sufficient merit to warrant its use. Lemaitre employs 5 per cent tincture of iodine, after drying the wound, to fix the superficial micro-organisms. One of its disadvantages is the slight secretion of turbid serum due to its action upon the superficial cells of the wound. We have not been able to note any advantages from its use.

If the wound is left open vaseline gauze is placed over the exposed skin edges and subcutaneous tissues in order to prevent the dressing from adhering and to lessen oozing and pain when the dressing is removed. Gauze soaked in Dakin's solution is placed loosely in the wound in such a way as not to cause retention of secretions. Dry gauze is applied over this and the dressing kept in place with a bandage. This is the routine treatment for cases which are to be evacuated early. Cases which are to be retained may be dressed similarly or Carrel-Dakin treatment, if indicated, may be begun at once.

The indications for Carrel-Dakin treatment may be summarized as follows:

If the operator is satisfied that *débridement* is satisfactory and that the wound is likely to be susceptible of suture in a few days chemical disinfection is unnecessary, and Carrel-Dakin treatment is not used. If for any reason, such as incomplete excision of tissues or the large size of the wound, it seems probable that the wound must be left open for a week or more, Carrel-Dakin treatment is advisable. Even clean wounds that are left open for a considerable time almost always become

infected, but the use of Carrel-Dakin treatment will prevent or limit the infection. When infection has occurred the use of Dakin's solution will do much to control and terminate it. Under these conditions the treatment is essential.

Primary suture. The advantages of primary suture are obvious; the disadvantages consist chiefly in the danger of inclosing micro-organisms in the wound, particularly anaerobes of the types which produce gas gangrene, and pyogenic organisms. A gas bacillus infection or pyogenic infection in a few cases will counterbalance many successful closures. The only means of rendering primary suture safe is by operative care and thoroughness, good judgment in the selection of cases for suture, and scrupulous watchfulness for some days after the operation. Primary suture should never be done when the exigencies of a service demand haste in the primary operation, or when a case must be evacuated soon after the operation.

The interval of time between the receipt of the wound and operation, the character of the tissue involved, and the situation of the wound, are important factors in determining the possibility of successful primary suture. Wounds involving the muscles of the calf, thigh, or gluteal regions should not be closed as a rule after a longer interval than eight hours. In these muscular parts gas bacillus infection is prone to occur and to result disastrously. In other muscular parts the time may often be extended to twelve hours. In wounds not involving muscles the time may be further extended. Wounds of the hands, as a rule, should be left open, treated with Dakin's solution and closed subsequently. Wounds of the face and scalp should always be sutured.

Extensive laceration of the soft parts, the presence of a large foreign body, or considerable clothing in the tissues shorten the time in which primary suture may be made safely.

Conditions which demand haste in the operation and therefore militate against thorough and painstaking *débridement,* such as shock or the presence of multiple wounds, preclude primary suture. Diminution of the vitality of the parts with marked infiltration of the tissues with blood as a result of vascular lesions, such as occur in wounds of the calf with division of the posterior tibial artery, contra-indicates primary suture following excision.

Scrupulous aseptic technique must be observed throughout the operation and clean instruments must be employed after the contaminated tissues have been removed. The muscles and aponeurosis are approximated with interrupted catgut. As little and as fine catgut should be introduced as will approximate the tissues and obliterate the dead spaces. The skin and subcutaneous tissues are closed with interrupted silkworm

gut. A drain is rarely needed but should be employed if there is a dead space or probability of oozing. It should be removed as soon as possible, in general within twenty-four hours. Silkworm strands, rubber tissue, or split tube should be employed according to the indications. In some cases, especially in deep wounds of muscular parts, a few strands of silkworm are advantageous as a means of obtaining a culture from the interior of the wound. After the dressings have been applied the part should be immobilized.

Partial primary suture of wounds of the soft parts has nothing to recommend it and should not be employed.

A wound which has been closed by primary suture must always be examined within twenty-four hours, and in the meantime the general condition of the patient must be carefully watched. It is the failure to recognize the development of gas bacillus infection or pyogenic infection as early as one should, and the unwillingness to admit the failure of primary suture that cause the fatalities. Lemaître does not ordinarily dress his wounds for twelve days unless there is a drain, in which case he removes it in three or four days. The signs to which he attaches importance as pointing to infection and indicating inspection of the wound are rise of temperature and pulse, and tenderness or spontaneous pain after twelve hours. If infection or a hæmatoma is found the wound must be reopened.

Bacteriologic examination of wounds with reference to suture. The co-operation of a bacteriologist is indispensable in making a decision as to the possibility of delayed primary and secondary sutures. For this purpose reliance must be placed chiefly upon cultures, the important feature being the determination of the presence of hæmolytic streptococci.

Although bacterial counts are far from exact, they give an indication as to the degree of bacterial contamination of a wound and of the progress from day to day. They are of especial value in confirming the clinical indications and contra-indications for suture.

Twenty-four hours after the primary operation of *débridement* or excision of tissues, the wound is dressed and a bacteriologic examination made. If no organisms are found suture is indicated. If hæmolytic cocci are present, suture is not considered. In the absence of hæmolytic cocci, if the wound clinically admits of closure, the presence of a few anaerobes or other organisms does not contra-indicate suture. A large number of organisms of any kind indicates caution. Suture, in that event, should be delayed and bacteriologic examination should be repeated at the following dressing. If the character of the wound or culture has not changed the wound may then be sutured.

Delayed primary suture is usually made in from two to six days after the primary operation. The disadvantages are the possibility of postoperative contamination of the open wound, and the subjection of the patient to a second operation with the attending discomfort, danger of pneumonia, etc. These disadvantages, however, do not equalize the risk incurred by primary suture in doubtful cases.

All dressings of wounds after the primary operation should be made according to the Carrel-Dakin technique. At each dressing necrotic areas are sought and snipped off. The pre-operative preparation of the wound for delayed primary suture consists in painting the skin with tincture of iodine after thorough cleansing.

Secondary suture. After forty-eight hours a culture and a smear are made from the wound and thereafter a smear is made every two days. Care must be taken not to touch the skin surface in making the smears, since this vitiates the value of the report. When the organisms in two successive counts are few, that is, approximately one per two fields, the wound is considered susceptible of secondary suture, unless it has contained hæmolytic streptococci at any time. In that case careful cultures are made from the granulation tissue and discharge from all parts of the wound, and absence of hæmolytic streptococci established by two successive negative cultures before suture is made. It has been observed that streptococci are prone to lie dormant in small numbers, but to flare up and cause virulent infection after closure of the wound.

Lemaître distinguishes two kinds of secondary suture, that of the superficial tissues and that involving the deeper structures. In secondary suture of the skin the incision surrounds the new epidermis along the wound edges; a healthy normal skin edge must be present for successful suture. The skin is freed by undermining in all directions as far as is necessary in order to approximate the edges with the minimum tension. This separation is made in the plane immediately superficial to the deep fascia; only dense scar tissue or projections of granulation tissue are removed from the wound. The deep fascia is then approximated with interrupted catgut when possible. Usually this may be done in the thigh and shoulder; but rarely in the leg, arm, and forearm. The skin and subcutaneous tissues are closed with silkworm gut. Considerable tension may be allowed, far more than we are in the habit of permitting in civil practice. If little skin was removed at the original operation the skin stretches in a short time, tension is relieved and good union results. The result of suture is directly proportionate to the degree of tension. If there is extreme tension, infection may be expected. It is surprising, however, how well most of these wounds

do, even after some infection. After the suture, a dry dressing is applied with considerable pressure and left undisturbed, if conditions warrant, for about eight days when the sutures are removed. In secondary suture involving the deeper parts the scar tissue is removed as a whole and all the layers are reconstructed.

When two longitudinal wounds are on the same transverse plane with considerable loss of tissue in each, one wound can usually be closed completely and the other closed in part. A dry dressing is applied and the wounds are left for about eight days when the sutures are removed. The unclosed portion then presents a flat, clean, granulating surface.

Wounds of the face. Wounds of the face must be considered independently. However severe, extensive, and dirty the wound, virulent pyogenic infection and gas gangrene are not prone to develop. This feature makes it possible by timely operative intervention to avoid in most cases the gruesome mutilations which were so often allowed to occur in the early days of the war. The rule which may be safely followed is to repair wounds of the face as soon as possible after the receipt of the injury without general excision of tissues. The wound is cleaned thoroughly and only such tissue is removed as is definitely devitalized. The mucous membrane is then closed and the wound sutured. Such wounds unite quite regularly. Secondary plastic operations are made in order to improve unsightly scars, to reconstruct the angle of the mouth, etc. The frequently associated fractures of the maxillæ should be treated by a surgeon-dentist. In his absence the original operator should conserve as far as possible all fragments of bone.

Wounds of the hand. In general the soft parts should be studiously conserved; when conditions warrant it primary suture should be made and early active motion enforced. Wounds by shell fragments with retained foreign bodies should be operated upon. Wounds caused by very small fragments may be left unopened, especially if bone, tendons, or joints are uninvolved.

In extensive wounds of the hand slow, painstaking cleansing by conservative *débridement* is necessary. Tendons are cleaned carefully: unopened tendon sheaths should not be entered. If practicable, divided tendons are sutured. If suture is not possible, severed tendons should be united with others so as to obtain the best functional result. Even extensive wounds of the hand should be closed if they have been carefully and thoroughly treated. If a dead space is present, a drain should be introduced. Plastic operations with sacrifice of a finger and excision of a metacarpal are advisable if the danger of infection can thus be diminished.

Wounds of the foot. Ample longitudinal incisions are necessary except for perforating wounds near the margin of the foot, in which case a transverse incision is employed, laying open the whole track. In the anterior part of the foot, it is best to expose the whole track by incision through the web between the toes. Conservation of the digits is not necessary to the same extent as in the hand. Usually primary suture may be made in slight wounds. Extensive wounds of the foot should be left open and treated with Dakin's solution.

THE BACTERIOLOGY OF WAR WOUNDS

All wounds are more or less contaminated by pathologic microorganisms derived from the patient's skin, from his clothing, and from the infected fertilized soil with which he comes into such intimate contact. The degree of infection depends upon a number of factors: the nature of the infecting organism, the amount of infectious material carried into the wound, the extent of tissue damage, the individual resistance of the patient, and the extent of time elapsing between the onset of injury and effective surgical treatment.

Bacterial growth does not occur immediately after the receipt of the wound. There is a latent period of six hours or more during which the contaminating organisms multiply and penetrate the tissues, local resistance develops, and the contaminated wound becomes an infected wound.

Three types of organisms demand particular mention: the streptococci, the anaerobes, and the bacillus of tetanus. The recognition of the character of infection from the clinical symptoms is of importance because the treatment in each case is essentially different.

In streptococcus infections, or in infections in which the streptococcus is the predominating organism, the temperature rises rapidly, and may reach 103°-104° within thirty-six or forty-eight hours. The face is flushed, the patient is restless and complains of pain, but the cold, clammy perspiration and the intense, shock-like symptoms associated with gas gangrene are usually lacking. Locally the tissues are red, tense, and extremely tender. An area of infiltration extends for a considerable distance from the wound, and may involve an entire limb. The injured tissues are swollen and slightly discolored. The wound discharge is usually thin, yellowish or grayish yellow, and not offensive. Lines of lymphatic involvement may extend centralward from the wound. In this type of infection operative procedures must be carried out with caution, and should be confined to incisions adequate for drainage, the excision of obviously necrotic tissue, and the removal of foreign

material with the least possible manipulation of the surrounding tissues. This is followed by instillation of Dakin's fluid at two hourly intervals.

In severe pyogenic infections, such as streptococcus or staphylococcus septicæmia, it has been shown that intravenous injection of a foreign protein exerts some favorable action. For this purpose Wolf, of Liége, has recommended the injection of 10 c.cm. of a 10 per cent solution of commercial peptone every two days until blood culture is negative. We have seen it employed at LaPanne, Belgium, with considerable success in cases of staphylococcus and streptococcus septicæmia.

In gas bacillus infection the pathologic process at first tends to remain localized, since the anaerobes multiply rapidly in the devitalized tissue but with greater difficulty in normal tissue. Taylor believes that the type of wound is of great importance, for gas gangrene is essentially a disease of traumatized muscle. Wounds of the thigh, calf, shoulder, and gluteal region are most commonly involved. Deep wounds made by shell fragments are particularly liable to infection. Even apparently clean entry and exit wounds caused by machine-gun bullets may develop gas gangrene. Wounds involving main blood vessels, such as the popliteal artery, are frequently followed by gas gangrene in the distal segment of the limb. In these cases the organisms find an excellent medium for growth in the muscles whose vitality has been diminished by the destruction of their blood supply.

At the primary operation infection is usually readily recognized by the odor and appearance of the wound and the condition of the muscles. When it develops later, its onset is suggested by changes in the general condition of the patient, which commonly develop in from 18 to 24 hours. These changes are an increasing rapidity of the pulse, a peculiar grayish appearance of the face, and a moderate rise of temperature. The condition rapidly becomes worse, and six hours later the systemic symptoms are often greatly accentuated. The patient becomes profoundly toxic, with high temperature, delirium, and dyspnœa. Locally the part is painful, swollen, tender, and often bronzed in patches; the surface, however, may look and feel normal. Crepitation is frequently present, but tympany and positive X-ray findings are so often lacking that little significance should be attached to their absence. Lemaître has urged nail percussion which he says frequently gives a tympanitic sound at a considerable distance from the wound, and produces exquisite pain at the point of greatest tympany. The association of these two signs, in his opinion, always corresponds to infection by anaerobic organisms.

On opening the wound, or perhaps not until the aponeurosis has been opened, bubbles of gas and brownish fluid exude, and the typical rotten

meat smell is noted. The involved muscle shows the characteristic appearance and lack of vitality; notably, an unhealthy salmon color, friability on pinching, and failure to contract and absence of oozing when cut.

The treatment of gas gangrene, whether present at the primary operation or of later development, consists in free incisions, followed by complete excision of the involved muscle. At the conclusion of the operation all exposed muscle must look normal, contract when pinched, and bleed when cut. In testing for bleeding the operator must assure himself that the blood supply is not interfered with as a result of the position of the limb. Excision is followed by Carrel-Dakin treatment of the wound and free administration of fluids, especially alkalies. The sera developed by Bull and by Weinberg appear to exert some beneficial influence.

Amputation must be resorted to when the process is too extensive for excision of involved muscle tissue, when deficient circulation of the limb indicates gangrene of the part, or when profound toxæmia threatens the patient's life.

Tetanus bacillus infection may develop even in trivial wounds such as abrasions occurring in connection with trench foot and frost-bite. Tetanus antitoxin neutralizes the toxic products elaborated by the tetanus bacillus, but does not influence the spores. Since it is only effective for about 14 days, at least two injections, at intervals of one week, were carried out in some of the allied armies.

It has been noted frequently that tetanus may develop after operative procedures undertaken some time after the original injection. Because of this fact cases subjected to secondary operative procedures more than seven days after the administration of antitoxin should be given a protective dose of antitetanic serum.

In the American army one injection of 1500 units was the rule, given as soon as possible after the receipt of the wound. If operation was performed or compound fractures were manipulated more than seven days after the initial injection the dose was repeated. This method proved satisfactory in spite of the theoretical advantages of repeated dosage.

TRENCH FOOT

Trench foot is a vasomotor disturbance affecting the feet of soldiers exposed to the unsanitary conditions of trench life. It may vary from a simple swelling to extensive necrosis, and is invariably accompanied by acute and persistent pain. Nothing differentiates trench foot from conditions of the same kind which occur away from the trenches ([6]).

It occurs for the most part in units stationed in flooded trenches where the men stand for variable periods in water and mud. It is more common under conditions of great humidity than in very cold weather. Interference with the circulation of the legs from tight leggings, tight puttees, badly fitting shoes, and dirty feet favor its incidence. Raymond and Parisot (6) attribute the condition to invasion of the feet by moulds derived from the soil, but this explanation has not been confirmed.

During the first stage pain is intense. There is often a peculiar sensation as if one were walking on cotton. Squeezing the foot transversely or pressing on the sole over the metatarsals causes intense pain.

In the second stage there is œdema in addition to pain. The skin may be pale but it is usually red; the redness and swelling may extend upward to the thigh. In the third stage there are discoloration, painful anæsthesia, and blebs. In the fourth stage gangrene is added to the picture. The gelatinous floor of the blebs becomes dry and discolored. A grumous material appears which tends to invade the adjacent tissues. If this substance is removed it tends to reform. Gangrene may develop without the preliminary bleb formation.

Septicæmia complicating trench foot is rare but is usually fatal when it occurs. If amputation is done, gangrene tends to recur in the stump. Tetanus is likely to follow trench foot, therefore antitetanic serum should be administered in every case. Gas gangrene has developed in a number of cases of trench foot.

Prophylactic measures can prevent or limit the condition. In the allied armies, inspection of the feet, dry footwear, frequent changes of socks, cleanliness, massage of the feet after exposure, care in selection of shoes, and drainage of trenches greatly diminished the occurrence of trench foot.

When trench foot has developed the feet should be bathed at medium temperature as soon as possible after leaving the trenches. After being dried they should be enveloped in gauze saturated with a solution containing one part of pulverized camphor and fifteen parts of borate of soda in one thousand parts of boiled water (Raymond and Parisot).

Small blisters not exceeding 1 cm. in diameter should not be opened: larger ones should be excised and the gelatinous layer removed. A wet dressing of 3 per cent solution of camphor in ether may then be applied. It is best not to employ surgical procedures to liberate sloughs, because by such operations extension of the process is favored. Dressings saturated in camphorated ether may be used to soften the sloughs, which can then be gradually removed with forceps.

In the severe forms with discoloration of the toes and feet and multiple blisters, parallel incisions should be made in the long axis of

the foot down to the underlying œdematous layer. Purulent foci should be adequately opened and drained.

The frankly necrotic form is frequently complicated by septicæmia and especially by gas gangrene. Here the aim is not so much to treat the local lesion as to prevent death. Some surgeons advise primary high amputation, but Raymond and Parisot([6]) state that they have never seen an undisputed indication for amputation.

REFERENCES

1. GRISSINGER, J. W. Lectures of Army Sanitary School, A. E. F., No. 153.
2. CRILE, G. W. Lectures of Army Sanitary School, A. E. F., No. 109.
3. CANNON, W. B. A Consideration of the Nature of Wound Shock. J. Am. M. Ass., 1918, lxx, 611-617.
4. BAYLISS, WM. Intravenous Injection in Wound Shock. Brit. M. J., 1918, i, 553-556.
5. Manual of Splints and Appliances for the Medical Department of the U. S. Army, 1917.
6. RAYMOND AND PARISOT. Lectures of Army Sanitary School, A. E. F., No. 4.

INDEX

Abdomen, gunshot wounds of, 709-742
bibliography, 741
incidence of, 712
military importance of, 712
nonpenetrating, involving abdominal wall, 713
gutter wounds, 713
penetrating and perforating, 717
complications, 725
fistulæ, fæcal and urinary, 726
hæmorrhage, 726
infections, 725
nephritis, 726
postoperative, 725
pulmonary complications, 726
operative treatment, indications for, 720
against, 721
technique of, 722
postoperative treatment, 724
visceral injury, symptoms of, 719
retroperitoneal visceral injuries, 714
shock in patients suffering from, 717
subcutaneous rupture of viscera, 715
diagnosis of, 716
treatment of, 716
visceral injuries, treatment of, 727
abdominothoracic injuries, 739
bladder, wounds of, 737
colon, wounds of, 731
kidney, wounds of, 736
liver, wounds of 733
pancreas, wounds of, 734
rectum, wounds of, 732
spleen, wounds of, 735
stomach, wounds of, 727
symptoms of, 719
abdominal distension, 720
abdominal pain, 720
treatment of, 727
ureter, wounds of, 737
Abdominal gynæcological operations, 101-330
after-treatment, 11
risks and sequellæ of, 13
Abdominal hysterectomy, 106
hysterotomy, 328, *see* Hysterotomy, abdominal
myomectomy, 131, *see* Myomectomy, abdominal
operations, *see* Gynæcological operations, abdominal, 101-330
Abdominothoracic injuries, 739
incidence of, 739
lesions in, 739
mortality from, 741
symptoms of, 739
treatment for, 740
Abortion, tubal, operations for, 264, *see* Tubal abortion
Acidosis and postoperative vomiting, 39
Acrohystero-Salpingectomy, 249; cut showing Bell's operation for, 250
indications for, 249
technique of, 251
Actinomycosis of uterine tubes and ovaries, 231
Adenomyoma of uterus, 140
clinical signs of, 141
microscopical composition of, 141
resembling fibroids, 141
subserous fibroid, illustration of uterus in sagittal section, 142
subtotal hysterectomy for, 143
Adhesions, complicating classical Cæsarean section, 354
peritoneal, formation of, after peritoneal injury, 177
prevention of, 182
chemical method of, 202
resulting from chemical trauma, 179
infection, 179
mechanical trauma, 179
Alexander-Adams operation for retrodisplacement of uterus, 313

Alignment of fractures, by bone plating, 566
general observations on, 568
Amputation of cervix uteri, 46, 285
Anærobic infection of wounds, 772
Anæsthesia, general, for operations on skull, 585
local, for operations on skull, 586
use of nitrous oxide-oxygen in operations on thorax, 679
for Schauta's operation, 167
" Wertheim's operation, 151, 164
Angioma, photographs of patient with cutaneous and subcutaneous, 436
treatment of, by radium rays, 435
Ankle, wounds of, 501
Ankle joint, treatment of fractures about, by irrigation and extension splint, (Penhallow's), cut showing, 565
Anterior colpohysterotomy, 324, *see* Colpohysterotomy
Appendix, removal of, peritonization following, 188; cut showing, 192
Arm, wounds of, perforating, due to bullet, cut showing, 537
Axial rotation of fibroids, 113
of ovarian cysts, 213

Bacteriology of war wounds, 771
anærobes, 772
bacillus of tetanus, 773
streptococci, 771
Baldwin's operation for reconstruction of artificial vagina, 74
Bedsores, complicating operations, 13
Bladder, carcinoma of, radium treatment for, 423
displacement of, during labour, cut showing, 271-272
hernia of, partial reduction of, cut showing, 275
injuries to, following abdominal operations, 32
in Wertheim's operation, 165
operations upon, 60
preparation of, for abdominal operation, 5
separation of, from anterior vaginal wall, 276; cut showing, 274
from cervix, 277; cut showing, 276
Bladder: (*Cont.*)
in anterior colpohysterotomy, cut showing, 325
treatment of, after pelvic operations, 288
in Schauta's operation, 170
in Wertheim's operation, 153
wounds of, 737
complications of, 738
extra peritoneal lesions, 738
intraperitoneal lesions, 738
mortality from, 738
Bladder peritoneum, advancement of upon fundus, in operative treatment of retrodisplacement of uterus, 316; cut showing, 319, 320, 321
Blake's method of treating fractures of humerus by extension and suspension, cut of, 529
Blood substitutes employed in cases of shock, 749
Blood transfusion, following gynæcological operations, 40
for wounds of thorax, 690
Bone flap method of treating gunshot wound of brain, cut showing, 591
Bone grafting, 576
Bone grafts, indirect, for repair of defect of symphysis of jaw and chin, cut showing, 632
for wounds of face and jaw, 628
implanting of, 630
indications for, 630
obtaining of, 630
Bone injuries, treatment of, in wounds of face and jaw, 618
Bone plating, 566
cases illustrating, 570, 571, 573
for shell wound of tibia, cuts showing, 574, 575
history of case, 573
methods of treatment, 567-569
technique of, 574
Bones, long, wounds of, 509, *see* Long bones, wounds of
Brain, abscess of, complicating gunshot wounds in skull, surgical treatment of, 609; cut showing, 609
gunshot wounds of, surgery of, 581
relation of various parts of, diagram showing, 586

Breast, cancer of, radium treatment of, 422
and fibroids, 126
Broad ligament, cysts of, 220
method of opening from vagina, cut showing, 392
Broad ligament abscess, abdominal approach to, cut showing, 394
Broad ligament pregnancies, secondary rupture of, at third to fourth months, 260
Buccal cavity, cancer of, radium treatment of, 421
Burrow Stewart's operation, for reconstruction of upper lip, cut showing, 656
for repair of extensive defect of lower lip and chin, cut showing, 655

Cabot posterior wire splint, cuts of, 564
leg splint, 753; cuts of, 759, 760
Cæsarean section, cervical, 373, *see* Cæsarean section, suprasymphyseal cervical, 366
classic, 350
after treatment of, 357
anæsthetic for, 352
complications of, 354
contra-indications to, 356
hæmorrhage in, 356
infection in, 356
objections to, 375
postoperative complications, 357
preparation of patient for, 351
suture of uterus after, 354; cut showing, 355
technique of, 352
treatment of placenta in, 355
uterine drainage in, 356
uterus steadied by volsella, cut showing, 353
closure of cervical stump, cut showing, 365
of serous surface of uterus, after, cut showing, 191
comparison of methods, 376
corporeal, 350, *see* Cæsarean section, classic
indications for, 373, 381
Porro, 358
advantages of, 361
Cæsarean section: (*Cont.*)
anterior peritoneal cul-de-sac being opened, cut showing, 362
clamps applied to level of uterine artery, cut showing, 360
clamps on broad ligament, cut showing, 359
indications for, 358
peritoneal closure after ligaments and tubes have been securely united to the cervical stump, cut showing, 366
sterilization with, 362
indications for, 362
methods of, 365
stump held by volsellum while broad ligament is ligated, cut showing, 364
technique of, 358
uterine artery clamped, cut showing, 361
suprasymphyseal cervical, 366
advantages of, 376
indications for, 373
technique of, 370
vaginal, 333
anæsthesia for, 344
cervix incised to the internal os, cut showing, 337
conditions for, 333
dangers of, 342
freeing bladder from cervix, cut showing, 335
indications for, 333
incision of the posterior wall, cut showing, 339
of lower uterine segment, cut showing, 338
line of incision, cut showing, 334
splitting the cervix, cut showing, 336
suture in, 341
of anterior incision, cut showing, 341
technique of, 335
use of Voorhees bag to pull down cervix for incision, cut showing, 340
Cancer of breast, and fibroids, in relation to hysterectomy, 126
Cancer of buccal cavity, radium treatment of, 420

Cancer of cervix, causes of death from, in Schauta's operation, 172
by infiltration, 149
mortality from, in Wertheim's operation, 163
operations for, Wertheim's radical extirpation by the abdominal route, 150
by permeation, 149
radical extirpation by vaginal route, *see* Schauta's operation
radium treatment for, 430
technique of, 431
and secondary growths, percentage of, 150
after subtotal hysterectomy, 136
groups of cases, 137
Cancer of cicatrix, following operation, 39
Cancer of colon, complicating fibroids and hysterectomy, 125
Cancer of ovary, 219
secondary, cut of, 219
in section, cut of, 220
Cancer of tongue, radium treatment of, 420
Cancer of uterus, after bilateral ovariotomy, 140
and fibroids, relative value of total and subtotal hysterectomy, 138
operations for, 173
Carcinoma, treatment of by radium therapy, 417
of bladder, 423
of the breast, 422
of œsophagus, 424
of prostate, 423
of rectum, 425
of stomach and intestines, 425
Cardiac lesions, complicating fibroids, in relation to hysterectomy, 122
Carotid artery, ligation of, following wounds of face and jaws, 616
Carrel-Gentile syringe, use of, in gunshot wounds of skull, 599; cut showing, 604
Caruncle, urethral, removal of, 61
Cataract, radium treatment of, 441
Catheter, use of, in operations on skull, for cleaning wound track, 598; cut showing, 603
Cauterization, as a method of peritonization, 194
Cerebral abscess, complicating gunshot wounds in skull, surgical treatment of, 609
Cerebral hernia, following shell wounds, 610
dressings for, 610; cut showing, 611
six weeks after operation, cut showing, 613
three weeks after operation, cut showing, 612
Cervicovaginal fistula, operations for, 90
Cervix, atresia or stenosis of, 54
dilation of, 43
fibroids, hysterectomy for, 115
malignant disease of the, operations for, 149
stenosis or atresia of, 54
Cervix uteri, amputation of, 46
high, 49; cuts showing, 52, 53
low, 46; cuts showing, 47, 48, 50, 51
as operative measure for cystocele, 285; cut showing, 285
suture, of raw surfaces after, cut showing, 287
carcinoma of, operations for, 149-172
radical extirpation by abdominal route, 150
by vaginal route, 167
Chest wall, closure of, 696
imperfect closure, 696
after thoracotomy, fat and muscle closed over defect caused by rib resection, 701; cut showing, 700
insertion of single and mattress sutures, 698; cut showing, 697
insertion of wire rib stay, 699; cut showing, 698
pectoralis major and latissimus dorsi, margins of, united with mattress sutures, 701; cut showing, 701
rib stay drawn taut, 700; cut showing, 699
superficial fascia, deep layer of, closed with buried stitches, 701; cut showing, 702

Chest wall: (*Cont.*)
inner aspect of, after fatal case of purulent pleurisy, cut showing, 696
Chest wounds, *see* Thorax, wounds of
Chorio-epithelioma, of uterine tube and ovary, 235
of uterus, 173
Cicatrix and buried sutures, 38
cancer of, following operation, 39
keloid scars, 39
Clitoridectomy, 67
Clitoris, removal of, *see* Clitoridectomy, cut showing resection of, 67
Cœliotomy, giving away of wounds after, 14
pneumonia complicating, 17
Collins' hitch, 571; cut showing, 754
Colon, cancer of, complicating fibroids, and hysterectomy, 125
wounds of, 731
incidence, table showing, 731
mortality from, 732
operation for, 732
Colpocœliotomy, 55; cut showing incision for, 56
posterior, 59
Colpohysterotomy, advantages over abdominal hysterotomy, 330
anterior, 324; cut showing, 324, 325, 326, 327, 328, 329.
closure of anterior uterine wall, cut showing, 328
excision of thickened edges of the uterine wall, cut showing, 328
exposure of the constriction ring and uterine tubes, cut showing, 326
incision of anterior uterine wall, cut showing, 326
incision of vaginal wall in, cut showing, 324
position of fingers for reinversion, cut showing, 327
separation of bladder from cervix, cut showing, 325
Colpotomy, posterior, 58; cut showing incision for, 58
Comminuted fracture of shaft of humerus, cuts of, 520
due to bullets, cuts of, 516, 517, 518
of humerus, upper part, by bullet, cut of, 531
of phalanges, with complete destruction of interphalangeal joints due to bullet, cut of 544
of radius and ulna, due to bullet, cut of, 536
of shaft of humerus, with indirect fracture, cut of, 515
of tibia, and fissured fracture, associated with perforating bullet wound, 554
Corporeal Cæsarean section, 350, *see* Cæsarean section, classic
Cranial burr, use of, cut showing, 593
Cranial injuries, 581, *see* Skull, wounds of
Cranial perforator, use of, cut showing, 592
Currettage of uterine cavity, 45
Cushing's operation for fracture of skull, 590, 596
Cystocele, 271
operations for, advancement, 283
amputation of cervix uteri for, 285
excision of part of body of uterus for, 286
transposition, 273; cuts showing, 274, 275, 276, 277, 278, 279, 280
Cystotomy, vaginal, 60
Cysts, of broad ligament, 220
ovarian, associated with fibroids, 124
axial rotation of, 213
cyst-adenoma, 214
free intracystic bleeding of, 214
multilocular glandular, 214
papillomatous (papilliferous), 217
spurious capsules of, 221
suppurating, 212
typhoid infection of, 213
parovarian removal of, 207, *see* Ovariotomy
of vulva, benign, removal of, 69

Débridement, 758
Carrel-Dakin treatment after, indications for, 766
excision of aponeurotic layer in, cut showing, 763
excision of the external wounds in, cut showing, 762

Débridement: (*Cont.*)
excision of injured muscle, cut showing, 764
technique of, 760
Defundation, technique of, cut of, 186, 189, 190
DeMartel's operation for fractures of skull, 590, 595; cut showing, 591
Dermatology, radium treatment in, 432
Diabetes, complicating fibroids, in relation to hysterectomy, 123
Diaphragm, operations upon, 695
wounds of, 672
closure of, 673
Discussion of the hymen, 68
Drainage, in hysterectomy, 111
after operations on wounds of thorax, 702
materials for, cut showing, 704
in treatment of infected wounds, 504
Dura, penetration of, in fractures of skull, 592
slightly punctured, 592
through and through wounds, 606
widely torn, 592
Dyspnœa, following fracture of jaw, 616

Ear, diseases of, radium treatment for, 442
Ectopic gestation, early rupture of gravid tube, 257
exploratory laparotomy for, 260
interstitial pregnancy, 262
in later months of pregnancy, 263
operations for, before rupture, 260
early rupture of gravid tube, 257
in which grave symptoms ensue between third and fourth months, 260
in pelvic hæmatocele, 266
in interstitial pregnancy, 262
in later months of pregnancy, 263
in rudimentary cornual pregnancy, 261
in secondary rupture of broad ligament pregnancies at third to fourth month, 260
in tubal abortion, 264
Ectopic gestation: (*Cont.*)
prolonged to fourth month, cut of, 259
rudimentary cornual pregnancy, 261
with sac situated on insertion of tube into uterine cornu, 259
with secondary rupture of broad-ligament pregnancies at third to fourth months, 260
terminating in tubal abortion, 264
varieties of, 257
Elbow, wounds of
skiagram showing extent of bone injury, 506
Elbow joint, wounds of, 497
Elephantiasis of vulva, cuts showing, 63, 64, 65, 66
Embolism of pulmonary artery, after hysterectomy, 22
statistics on, 22
symptoms of, 22
Trendelenburg operation for, 25
Empyema, complicating wounds of thorax, 704
treatment of, 705
Encephalitis, complicating gunshot wounds in skull, 608
surgical treatment of, 608
Endometritis chronic, radium treatment for, 430
Enterovaginal fistula, operation for, 97
Enterovesical fistula, operation for, 98
Enucleation, abdominal, for fibroids, definition of, 130
indications for, 133
Epithelial infection, 215
inlays, 648
Epithelioma, radium rays in treatment of, 418
Eradicative operations upon uterine tubes, 247
Erosions of tibia, due to shell fragment, cut of, 558
Exophthalmic goiter, radium treatment for, 444
Extension and irrigation splint for fractures about ankle joint, cut of, 565
and suspension, apparatus for, 527
Blake's method of treating fractures of humerus by, cut of, 529
methods of, 527
on modified Hodgen's splint

Extension and irrigation splint: (*Cont.*)
for compound fracture of humerus, cut of, 527
for treatment of fractures of humerus, cut of, 530
splint, Page aluminum, cut of, 549
for reduction and proper alignment of fracture of metacarpus, cut of, 542
Extirpation of uterus by abdominal route, 150
by vaginal route, 167
Extraperitoneal operations, 313
Extremity, wounds of upper,
wrist, 497
elbow joint, 497
shoulder joint, 496

Face, gunshot wounds of, 770
bone grafts for, 628, *see* Bone grafts for wounds of face and jaw
bone injuries, treatment of, 618
bony defects and malpositions, reconstruction of, 628
burn, repair of injury of, cut showing, 644
cheek and lower lip, repair of defect of, cut showing, 643
death following, causes of, 615
foreign bodies in, removal of, 617
infections resulting, treatment of, 623
plastic operations for, 649
defects within mouth, 657
defects of orbit and eyelids, 660
defects of palate, 659
on lip, 650
resection of a depressed scar, 649
repair of soft tissues, 635
drainage in, 646
flaps for, 635
general plan, determining of, 641
location, suitable, for obtaining flap for, 642
post-operative treatment, 646
size and shape of defect, determination of, 640
sutures for, 645
removal of, 646

Face: (*Cont.*)
reconstruction of bony defects and malpositions, 628
resection of, scars due to, 649
sepsis resulting from treatment of, 623
skin grafts for, 633; cuts showing, 633, 634, 635
soft tissues, pedicled flap from cheek for repair of, cut showing, 634
from neck, for repair of, cut showing, 633
plastic operations for, 635
repair of, 621
treatment of, early, 616
anæsthesia, 622
bone injuries, 618
evacuation of cases of, in, 622
foreign bodies, removal of, in, 617
soft tissues of, in 621
vital forces, care of, in, 616
treatment of, late, 623
fistulæ, traumatic, 626
fractures, delayed union of, 624
sepsis, 623
suture, delayed, 625
trismus, 626
Fallopian tube and ovary, suspension of, cut of, 245
Femur, wounds of, 543
complications of, 545
diagnosis of, 545
due to shell, cut of, 543
fracture, comminuted, due to bullet, cut of, 546
oblique, with displacement, cut of, 548; description of case, 549
oblique and fissured, from deflected bullet, fragments still seen in bony tissue, cut of, 547
prognosis of, 546
treatment of, 546
Fibroids, bicornate, cuts of, 118, 119
of broad ligament, illustration, 117
operation for removal of, 117
cancer of cervix resulting from removal of, 136
and cancer of uterus, 138
cervix, operative treatment of, 115
complications of, in relation to

Fibroids: complications, (*Cont.*)
hysterectomy, cancer of breast, 126
cancer of colon, 125
cardiac lesions, 122
cysts of ovary, 124
diabetes, 123
gall-stones, 124
pelvic, 124
pregnancy, 125
table of cases of, 129
sarcoma of tibia and fibula, 127
thickening of vermiform process, 124
thyroid lesions, 123
double, 119
flora of, 121
globular intramural, illustration of sagittal section, 113
hysterectomy for, *see* Hysterectomy
impaction of, 111
mortality from, in different operations for, 134
in hysterectomy, 128
operations on, enucliation, abdominal, 131
hysterotomy, 131
myomectomy, abdominal, 131
and pregnancy, 133, 134
recurrence of, dependent on form of operation, 133
sarcoma of uterus, associated with, 139
sessile, subserous, illustration of, 114
subserous, adenomyoma of uterus resembling, cut of, 142
illustration of uterus in section, 133
twin, 112
cut showing uterus with, in sagittal section, 112
with twisted pedicle, 113
Fibro-myoma of uterus, radium treatment of, 429
Fibula, wounds of, 555
complications of, 557
diagnosis of, 557
fracture, comminuted, of tibia and due to shell fragments, cut of, 556
contact, due to shell fragment, cut of, 559
Fibula: (*Cont.*)
perforation and splintering, due to bullet, cut of, 555
prognosis of, 558
treatment of, 558
Field hospital, care of wounded in, 746
function of, 746
Fistula, cervicovaginal, 90
enterovaginal, 97
enterovesical, 98
fæcal, postoperative complication of perforating and penetrating wounds of the abdomen, 726
genital, cut showing different types of, 81
operative treatment of, 79-98
operations for cervicovaginal, 90
enterovaginal, 97
enterovesical, 98
rectovaginal, 92, 311; cuts showing, 90, 91, 92, 93, 94, 96, 309, 310
congenital, 96
ureterovaginal, 90
vesicovaginal, 79; cuts showing, 82, 83, 84, 85, 86, 87, 88, 89
rectovaginal, causes of, 92
congenital, 96
traumatic, following wounds of face and jaw, 626
treatment of, 627
types of, 626
ureteric treatment of, 34
ureterovaginal, 90
Fixation of fractures, 566-568
of uterine tubes, indications for, 244
technique of, 246
Flap, combined neck and cheek for defects above oral fissure, Esser's plan of obtaining, cut showing, 639
with pedicle of subcutaneous tissue containing temporal artery and vein, from forehead, cut showing, 637
pedicled, for repair of soft tissues, from cheek, cut showing, 634
from forehead, cut showing, 635
from neck, cut showing, 633
for replacing defect of orbit

Flap: (*Cont.*)
and lower lid, from forehead, cut showing, 636
tubular, for repairing defect of orbit and lower lid, cut showing, 638
Flaps for wounds of face and jaw, 649, *see* Plastic operations for repair of soft tissues
Flora of uterus, in relation to hysterectomy, 120
Foot, wounds of, 771
furrow, caused by deflected bullet, cut of, 567
description of, 563
Forceps, bone biting, for chest surgery, cut of, 685
left in abdomen, 26
lung, Tuffier's, cut of, 688
Montenovesi, use of, cut showing, 594
Forearm, wounds of, *see* Radius, wounds of, 535, also ulna, wounds of
Foreign bodies in abdomen, left after operation, 25
complicating wounds of thorax, 705
removal of, 706
Foreign bodies, localization and extraction of, under X-Ray control, 451-488
apparatus required, 453
extraction of, under X-Ray guidance, 477
bonnet method, 484; cuts showing, 482, 483, 484, 485, 486, 487
open screen method in darkened room, 480; cut showing, 478, 479
centering tube, 454
information to be gained by, 452
marking skin for, 455
technique of, 457; cuts showing, 459, 461, 462, 463
double shift fixed angle method, 471; cuts showing, 472, 473
Harpoon method, 475
Hirtz compass method, cut showing, 476
multiple diameters method, 467
nearest joint method, 462
Foreign bodies: (*Cont.*)
orthodiagraphic method, 466; cut showing, 466
parallax method, 463; cut showing, 465
right-angled planes method, 467; cut showing, 466, 468
single shift triangulation method, 470; cut showing, 470
removal of, from wounds of face and jaws, 617
in skull, nail and magnet used in removal of, cut showing, 606
Fracture, of "butterfly" type, simulation of, by perforation of proximal phalanx by bullet, cut of, 544
comminuted, of femur, due to bullet, cut of, 546
of shaft of humerus, due to bullet, cuts of, 516, 517, 518
of tibia, due to bullet, cut of, 556
of tibia and fibula, cut of, 556
of ulna, due to shrapnel bullet, cut of, 535
complete, of tibia, with moderate comminution, due to grenade, cut of, 561
compound, of humerus, treated by extension and suspension on modified Hodgen's splint with Carrel-Dakin method, cut of, 527
contact of fibula, due to shell fragment, cut of, 559
of metacarpal bones by shell fragment, cut of, 541
with radiating fissures caused by lead core of deformed bullet, cut of, 557
in tarsal region, by shell fragment, cut of, 560
delayed or non-union, or loss of continuity, bone grafting for, 576
early treatment of, 751
splints for, 751
Cabot posterior wire leg splint, 753; cut showing, 759, 760
Liston, 753; cut showing, 758
Thomas arm splint,

Fracture: (*Cont.*)
hinged modification of, 752; cut showing, 757
Thomas leg splint, 751; cut showing, 751
modification of, 751; cut showing, 752
Stretcher cradle for transport, cut showing, 756
of femur, 543, *see* Femur, wounds of
of fibula, 555, *see* Fibula, wounds of
fissured, of radius, due to shrapnel bullet, cut of, 532
of shaft of humerus, cut of, 514
of tibia, with some comminution associated with perforating bullet wound, cut of, 554
of ulna, due to shrapnel bullet, cut of, 533
and grooved, of radius, due to shell fragment, cut of, 534
grooving, of humerus, cut of, 513
of phalanx, with radiating fissures, due to bullet, cut of, 543
of tibia, due to bullet, cut of, 555
and comminuted of tibia due to bullet treated by bone grafting, cuts of, 578; history of case, 577
by indirect violence with comminution of shaft of humerus, cut of, 515
of jaw, treatment of, 618
delayed union of, causes, 624
treatment, 625
of metatarsals, 561, *see* Metatarsals, wounds of
oblique, of femur, with displacement, cut of, 548; description of, 549
and fissured from deflected bullet, fragments still seen in bony tissue, cut of, 547
open, reduction and fixation of, by means of bone plating, 566
Page aluminum splint applied for, cut of, 525, 549
permanent fixation of, 522
Fracture: (*Cont.*)
right-angled splint for, cut of, 526
shell, of shaft of humerus, cut of, 519
of skull, with penetration of dura, operative treatment of, 595
without penetration of dura, operative treatment of, 590
bone flap method, 590
Cushing's method, 590
DeMartel's method, 590
of thigh, suspension frame for, cut of, 550
Thomas splint, modified for, cut of, 524
of tibia, 555, *see* Tibia, wounds of
treated by Blake's method of extension and suspension, cut of, 529
extension splint for reduction and proper alignment of, cut of, 542
by extension and suspension, cut of, 530
by Thomas Arm Extension splint, cut of, 521
permanent fixation of, 522
treatment of, by bone grafting, 576
bone plating, 566
Function, restoration of, by active mobilization after joint injury, cut showing, 507
Fundus, advancement of bladder peritoneum upon in operative treatment of retrodisplacements, 316; cuts showing, 319, 320, 321
amputation of, in Porro Cæsarean operation, cut showing, 363
for retrodisplacements of uterus, 316

Gall bladder, removal of, in course of hysterectomy for fibroids, 124

Gas bacillus infection, diagnosis of, 772; treatment of, 773
Gas gangrene, diagnosis of, 772
treatment of, 773
Gauze stuffing, disadvantages of, 27
Genital fistulæ, operative treatment of, 79
cervicovaginal, 90
enterovaginal, 97
enterovesical, 97

Genital fistulæ: (*Cont.*)
rectovaginal, 92
ureterovaginal, 90
vesicovaginal, 79
Gilliam's operation, 323
Gravid tube, early rupture of, 257
Grenades, wounds due to, of forearm, with extensive destruction on ulna side, cut of, 539
of tibia, complete fracture with moderate comminution, cut showing, 561
Gunshot wounds, bacteriology of, 771
bibliography of, 775
early treatment of, 745
of the face, 770
in non-transportable cases, 747; in field hospitals, 746
of foot, 771
fractures, 751
of the abdomen, 709
of hands, 770
of the joints, 491
of skull and brain, surgery of, 581
in mobile and evacuation hospitals, 747
precautions of, observed in advanced area, 745
shock, 748
of soft parts, 754, *see* Soft parts, wounds of
Gynæcological operations, abdominal, 101-330
after-treatment in, 11
complications of, 13
acidosis and postoperative vomiting, 39
bed-sores, 13
cancer of cicatrix, 39
cicatrix, 38
embolism of pulmonary artery, 22
fate of ligatures, 36
foreign bodies left in abdomen, 25
giving way of wound, 14
hæmorrhage, 15
intrapelvic, 16
injuries to bladder, 32
to intestines, 29
to ureter, 32
intestinal obstruction, 31
kraurosis, 38
metrostaxis, 13
parotitis, 17
Gynæcological operations: (*Cont.*)
perforating ulcer of stomach and small intestine, 32
pneumonia, 17
post-anæsthetic paralysis, 13
stick-abscesses, 39
tetanus, 28
thrombosis, postoperative, 19
preparation for, 5
preparation of patients for, 3-8
for abdominal, 5
for special, 7
for vaginal, 6
Gynæcology, radium therapy in, 429

Hæmatocele, differential diagnosis, 265
para-tubal, 265
pelvic, 265
physical signs of, 266
peritubal, 265
Hæmatomata, complicating pubiotomy, 349
Hæmorrhage, after abdominal operations, 15
following classic Cæsarean section, 356
complicating pubiotomy, 349
postoperative complication of penetrating and perforating wounds of the abdomen, 726
in tubal abortion, 264
in Wertheim's operation, 164
following wounds of abdomen, 717, 719
following wounds of face and jaws, 616
Hæmothorax in chest wounds, 676
physical signs of, 678
treatment of, 677
Hands, wounds of, 770
Harpoon method of localizing foreign bodies, 475
Hausner's glue, for holding extension straps, 527
Heart, operations upon, 695
Hebosteotomy, 343, *see* Pubiotomy
Hernia, cerebral, following shell wounds, 610
dressings for, 610; cut showing, 611
six weeks after operation, cut showing, 613
three weeks after operation, cut showing, 612

Hip-joint, wounds of, 499
Hodgkin's disease, radium treatment for, 444
Hospitals, field, treatment of gunshot wounds in, 746
mobile and evacuation, 747
Humerus, wounds of, 523
comminution and splintering, due to bullet, cut of, 572; history of case, 571
comminution of upper part, by bullet, cut of, 531
complications of, 524
diagnosis of, 525
fracture, Page aluminum splint applied for, cut of, 525
Thomas splint, modified for, cut of, 524
prognosis of, 534
treatment of, conservative, 526
case illustrating importance of, 530
by extension and suspension, cut of, 530
Blake's method of, cut of, 529
on modified Hodgen's splint for compound fracture, with Carrel-Dakin method, cut of, 527
radical, 527
Hydrocele of labia majora, removal of, 72
Hymen, discission of, 68; cut showing, 68
Hysterectomy, abdominal, 106; on bicornate uterus, 119
after bilateral oöphorectomy and ovariotomy, 231
after bilateral ovariotomy, 222
for cervix fibroids, 115
embolism of pulmonary artery due to, 22
Trendelenburg operation for, 25
for fibroids and complications,
cancer of breast, 126
cancer of colon, 125
pregnancy, 125
table of cases of, 129
sarcoma of tibia and fibula, 127
mortality from, 128
on patients of seventy and upwards, 130
Hysterectomy: (*Cont.*)
risks of, 127
with twisted pedicle, 113
flora of uterus in relation to, 120
indications for, 101
injuries to bladder due to, 32
injuries to ureter following, 32
intestinal obstruction following, 31
perforating ulcer of stomach or small intestine due to, 32
for puerperal sepsis, 393
relative value of total and subtotal, 136-146
cancer of body of uterus and fibroids, 138
subtotal, 101, 106
for adenomyoma of uterus, 143
cancer arising from, 136
fate and value of belated ovaries, 144
indications for removal of ovaries and tubes, 107
stump after, cut of, 108
supra-vaginal, peritonization following, 187
thrombosis due to, 20
total, 109
drainage, 111
and impacted fibroids, 111
with preliminary ligature of hypogastric arteries, 110
vaginal, 102, 287, *see* Vaginal hysterectomy
Wertheim's, 150
and visceral complications associated with fibroids, 122
cardiac lesions, 122
diabetes, 123
thyroid lesions, 123
Hystero-salpingectomy, indications for, 251
technique, 251
Hysteropexy, complications of, 19
Hysterotomy, abdominal, for inversion of uterus, 328
definition of, 131
vaginal, *see* Cæsarean section, vaginal

Ileum, used as flap, for peritonization, 201
Ileus, resulting from classic Cæsarean section, operation for, 357

Incision for ovariotomy, 208
suture of, 212
Infection in joint wounds, 504
postoperative, complication of perforating and penetrating wounds of the abdomen, 725
Intestinal mucosa, repair of injury to, cut of, 184
Intestinal obstruction after pelvic operations, causes of, 31
frequency of, 31
treatment of, 32
Intestine, small, wounds of, 729
incidence of, 729
mortality from, 730
operation for, 730
Intestines, carcinoma of, radium treatment of, 425
injury to, in gynæcological operations, 29
Intrapelvic hæmorrhage after abdominal operations, 16
Inversion of uterus, operations for, 323-330
types of, 323
abdominal hysterotomy, 328
anterior colpohysterotomy, 324
Irrigation and extension splint for fractures about ankle joint, cut of, 565
splint, cut of, 566

Jaw, fracture of, delayed union of, 624
causes of, 624
treatment, 625
dyspnœa following, treatment of, 616
treatment of, 618
lower, loss of bone in, prosthesis for replacing, cut showing, 619
ramus of, maintaining position of, following injuries to, 619
upper, displacements of, due to injury, treatment of, 620
Joints, gunshot wounds of the, 491
Joints, wounds of, after treatment, 505
complications of, 502
joint infection, 503
non-penetrating injuries, 492
penetrating, 494
percentage mortality from, during World War, 491
Joints: (*Cont.*)
perforating injuries, 496
types of, 491
see also under ankle, elbow, hip, knee, shoulder, and wrist joints.

Keloid, treatment of, by radium, 434
Kidney, wounds of, 736
mortality from, 737
operative treatment for, 737
symptoms of, 736
Knee joint, wounds of, 499
penetrating, treated by débridement, cut showing, 501
uccessfully operated upon, cut showing, 500
perforating, treated by débridement, cut showing, 502
Kraurosis, post-operative, 38
Krönig's operation, cuts showing, 368, 369, 370, 371, 372, 373, 374, 375

Labia majora, removal of hydrocele of, 72
Labour, displacement of bladder and urethra during, cuts showing, 271, 272
Lacerations of the perineum, 271
operative treatment of, 292
Laryngology, radium in, 442
Lateral ventricle, position of, diagram showing, 585
Latzko's operation, 372; cuts showing, 377, 378, 379, 380, 381
Leg, wounds of, Cabot posterior wire splint for, cuts of, 564
fracture, contact, in tarsal region, due to shell fragment, cut of, 560
infected gunshot, bridged plaster for, cut of, 562
treatment of, case illustrating, 563
Page aluminum extension splint, cut of, 549
Parker suspension apparatus, and method of appliance, cut of, 563
see also, Tibia, wounds of, and Fibula, wounds of
Leukæmia, splenic and lymphatic, radium treatment in, 443

Leukoplakia, radium treatment of, 420
Ligaments, uterosacral, shortening of, cut showing, 314, 315
Ligature carrier for use in pubiotomy, cut showing, 346
Ligature materials for operations on uterine tubes, 241
Ligatures, applying of, in Wertheim' operation, 159
fate of, in pelvic operations, 36
Lips, plastics upon, 650; cuts showing, 651, 653, 654, 655, 656, 657, 658
Burrow Stewart's operation for reconstruction of upper lip, cut showing, 656
Burrow Stewart's operation for repair of extensive defect of lower lip and chin, cut showing, 655
Ectropion of lower, due to burn, repair of, cut showing, 657
Rose's operation, 656
upper, restoration of by cheek flaps, cut showing, 658
Liver, wounds of, 733
diagnosis of, 734
mortality from, 734
operation for, 734
symptoms of, 733
Localization of foreign bodies in wounds, *see* Foreign bodies, localization and extraction of under X-Ray control, 451-488
Long bones, wounds of, 509-577
comminuted fracture of shaft of humerus due to bullet, cuts of, 516, 517, 518
comminution of shaft of humerus by bullet, with indirect fracture, cut of, 515
comminution and displacement in tibia due to shell, with treatment by bone plating and splint, cuts of, 574, 575; history of case, 573, 574
comminution of phalanges with complete destruction of inter-phalangeal joint, due to bullet, cut of, 544
comminution of radius and ulna, due to rifle bullet, cut of, 536
comminution and splintering of humerus due to bullet, cut of, 572; history of case, 571
comminution of upper part of humerus due to bullet, cut of, 531
complications, associated with, 507
in femur, 545
in forearm, 536
in humerus, 524
in metacarpal bones, 540
in metatarsals, 562
in phalanges, 543
in tibia and fibula, 557
diagnosis of, 508
in femur, 545
in forearm, 537
in humerus, 525
in metacarpal bones, 541
in metatarsals, 562
in phalanges, 543
in tibia and fibula, 557
femur, 543, *see* Femur, wounds of
fibula, 555, *see* Fibula, wounds of
in forearm with extensive destruction on ulna side, due to grenade, cut of, 539
fracture, comminuted, of femur, due to bullet, cut of, 546
comminuted, of tibia, cut of, 556
of tibia and fibula, 556
complete with moderate comminution of tibia, due to grenade, cut of, 561
complications of, 512
compound of humerus, treated by extension and suspension on modified Hodgen's splint, with Carrel-Dakin method of treatment for wound, cut of, 527
contact, of fibula, due to shell fragment, cut of, 559
of metacarpal bones by shell fragment, cut of, 541
with radiating fissures caused by lead core of deformed bullet, cut of, 557
in tarsal region, by shell fragment, cut of, 560
of fibula and tibia, of radius, due to shrapnel bullet, cut of, 532

Long bones: (*Cont.*)
of shaft of humerus, due to bullet, cut of, 514
of tibia with some slight comminution, associated with perforating bullet wound, cut of, 554
grooving of humerus, due to bullet, cut of, 513
of phalanx, with radiating fissures, due to bullet, cut of, 543
of tibia, due to bullet, cut of, 555
indirect, and comminution of shaft of humerus, cut of, 515
of lower leg and thigh, Page aluminum extension splint for, cut of, 549
of metacarpus, extension splint for reduction and proper alignment of, cut of, 542
oblique, of femur, with displacement, cut of, 548; description of, 549
oblique and fissured, from deflected bullet, fragments still seen in bony tissue, cut of, 547
due to perforating bullet wound of humerus, cut of, 514
of radius, fissured and grooved, due to shell fragment, cut of, 534
of shaft of humerus caused by shell fragment, cut of, 520
shell, of shaft of humerus, cut of, 519
of thigh, suspension frame for, cut of, 550
treated by Blake's method of extension and suspension, cut of, 529
treated by extension and suspension, cut of, 530
treated by right-angled splint, cut of, 526
treated by Page aluminum splint, applied for, cut of, 525
treated by Thomas' arm extension splint, cut of, 521
Long bones: (*Cont.*)
treated by Thomas' splint, modified, for, cut of, 524
of ulna, comminuted, due to shrapnel bullet, cut of, 535
of ulna, fissured, due to shrapnel bullet, cut of, 533
of ulna, fissured and perforated, from deformed and disintegrated bullet, cut of, 534
furrow, of foot, caused by deflected bullet which passed through left leg, striking right foot, cut of, 567; description of, 564
of humerus, *see* Humerus, wounds of, 523
infection due to, percentage of, 509
treatment for, 517
lesions caused by, 510
contact fractures, 510
contusions, 510
fissures, 510
fractures by indirect violence, 511
grooves and gutters, 511
perforations of diaphysis, 510
metacarpal, *see* Metacarpal bones, wounds of
metatarsal, *see* Metatarsals, wounds of
perforating, of arm, due to bullet, 537
of tibia, cuts of, 554
associated with fissured fracture and some comminution, cut of, 554
due to bullet, cut of, 553
perforation of proximal phalanx simulating butterfly fracture, cut of, 544
perforation and splintering of fibula, due to bullet, cut of, 555
phalanges, *see* Phalanges, wounds of, 542
prognosis of, in femur, 546
in forearm, 538
in metacarpal bones, 541
in metatarsals, 562
in phalanges, 543
in tibia and fibula, 558
of radius, *see* Radius, wounds of, 535

Long bones: (*Cont.*)
shell wound of femur, cut of, 545
splintering of radius, from shell fragment, cut of, 538
splintering of tibia due to shell fragment, cut of, 559
statistics on, 509
tibia, 555, *see* Tibia, wounds of
treatment of, at the base, 515
bone grafting, 576
bone plating, 566
Cabot posterior wire splint, cuts of, 564
conservative, 515
dressing, 521
extension splint, Page aluminum, cut of, 549
in femur, 546
in forearm, 538
at the front, 511
in humerus, 526
immobilization of injured bone, 522
for infection, 517
irrigation and extension splint for fractures about ankle joint, Penhallow's, cut of, 565
irrigation splint, Penhallow's, cut of, 566
in metacarpal bones, 542
in metatarsals, 562
Parker's suspension apparatus and method of application, cut of, 563
permanent fixation of fractures, 522
in phalanges, 543
radical, 522
Thomas arm extension splint, cut of, 521
in tibia and fibula, 558
of ulna, *see* Ulna, wounds of
Lung, effect of ligation of pulmonary artery on, 667
dog's, experimental splenization in, cut showing, 674 (facing)
injury to, 673
lacerated wound of lower lobe, cut showing, 692 (facing)
operations upon, 691
excision, 691
sutures, method of reducing number used in repair after resection, cut showing, 694
suturing after, 694
Lung: (*Cont.*)
thoracotomy of election, 692; cut showing, 693
thoracotomy of necessity, 692
sheep's, five weeks after ligation of artery supplying left upper lobe, cut showing, 666
five months after ligation of artery supplying inferior margin of left lower lobe, cut showing, 668
Lymphatic glands, tuberculosis of, radium treatment for, 428
Lymphosarcoma of neck, photographs of patient with, before and after radium treatment, 427

Malignant growths, treatment of, by radium rays, 417

Mattress suture, diagram of, 107
Mayo operation for excision of uterus, 104, cuts showing, 288-291
Mediastinum, operations upon, 695
Meningitis, complicating gunshot wounds in skull, surgical treatment of, 608
Metacarpal bones, wounds of, 540
complications of, 540
diagnosis of, 541
fracture contact by shell fragment, cut of, 541
prognosis of, 541
treatment of, 542
extension splint for reduction, and proper alignment of fracture, cut of, 542
Metatarsals, wounds of, 561
complications, 562
diagnosis of, 562
prognosis of, 562
treatment of, 562
case illustrating, 563
Metrostaxis, after gynæcological operations, 13
Mobile and evacuation hospitals, early treatment of gunshot wounds in, 747
Montenovesi forceps, use of, cut showing, 594
Morphine, in treatment of wounds of thorax, 678
use of, with novocaine, for operations on skull, 587

Musculospiral nerve, injury to, complicating fracture of humerus, 524
Myomectomy, abdominal, 131-135
definition of, 131
indication for, 133
peritonization following, 188

Nævus pigmentosus, radium treatment for, 437
Nerve, phrenic, blocking of, in operations on thorax, 688
exposure of, cut showing, 690
incision for, cut showing, 689
Novocaine, use of for operations on skull, 587

Obstetrical operations, 333-383
classic Cæsarean section, 350
Porro Cæsarean section, 358
pubiotomy, 342
section of pelvic girdle, 342
symphysiotomy, 343
vaginal Cæsarean section, 333
Œsophagus, carcinoma of, radium therapy for, 424
Omental grafts as a method of peritonization, 196
microscopic appearance of, cut showing, 197
technique of, 198
Oöphorectomy, 226-235
bilateral, consequences of, 231
hysterectomy after, 231
conditions indicating, 226, 229
and results of operation on, 232
Operation, Abbott's, A. W., for atresia of the vagina, 76
Alexander-Adams', extraperitoneal, for retrodisplacements of uterus, 313
Baldwin's, for atresia of vagina, 74
Bell's, acrohystero-salpingectomy, 250
Crossen's, anterior colpohysterotomy, cuts showing, 325, 326, 328
Cullen's, pelvic abscess, 390, cuts showing, 390, 391, 392, 394
Cushing's, Harvey, cranio-cerebral, 590
David's, Vernon, recto-vaginal fistula, 311, cuts showing, 309, 310
Operation: (*Cont.*)
De Martel's, for fracture of skull, 590
Duval's abdomino-thoracic, 740
Frank's, suprasymphyseal Cæsarean section, 367
Gellhorn's, modification of Krönig's, 372
Gilliam, for retrodisplacements of uterus, 322
Haultain's, abdominal hysterotomy, 328
Kelly's, H. A., perineorrhaphy, 298
Krönig's, cervical (transperitoneal) Cæsarean section, 372, cuts showing, 368-375
Latzko's extraperitoneal Cæsarean section, 372, cuts showing, 377-381
Mayo's, C. H. vaginal hysterectomy, 104, cuts showing, 288-291
Porro's, Cæsarean section, 358
Robinson's, for atresia of the vagina, 74
Rose's, hare lip, 656
Schauta's, radical extirpation of uterus by vaginal route, 167
Spinelli's, anterior colpohysterotomy, 324
Stewart's, Burrow, for upper lip reconstruction, cut showing, 656
Trendelenburg's, for embolism of pulmonary artery after hysterectomy, 25
Van Langenbeck's, palate, 659
Webster's, peritonization following suspension of the uterus, 193
Webster-Baldy, for amputation of fundus retrodisplacements of uterus, 316
Wertheim's, radical extirpation of uterus by abdominal route, 150
Young's, shortening of the utero-sacral ligaments, cuts showing, 314, 315
Operations, abdominal gynæcological, 101-330, *see* Gynæcological operations, abdominal
abdominal myomectomy, 131
acrohystero-salpingectomy, 249
Alexander-Adams, for retrodisplacement of uterus, 313

Operations: (*Cont.*)
Baldwin's, for cystocele, 271, reconstruction of artificial vagina, 74
for carcinoma of the cervix uteri, 149
for ectopic gestation, operations for, 257
for fibroids, *see* Fibroids, operations on
for genital fistulæ, 79, *see* Fistula, operations for
on heart, 695
for hysterectomy, 101
for hystero-salpingectomy, 251
for Ileus resulting from classic Cæsarean operation, 357, *see* Ileus
for inversion of uterus, *see* Inversion of uterus, operations for, 323
on lung, *see* Lung, operations upon, 691
for malignant disease of uterus and cervix, 149
on mediastinum, *see* Mediastinum, operations upon, 695
for non-malignant affections of uterus, 101
obstetrical, *see* Obstetrical operations, 333
on ovaries, *see* Ovariotomy, 207
on ovaries and tubes, see Oöphorectomy, 227
peritonization, 177
plastic, *see* Plastic operations
salpingectomy, 247
salpingostomy, 242
for urethrocele, 272
for uterine prolapse, 271
on uterine tubes, 239, *see* Uterine tubes, operations on
on uterus, see Uterus, operations on, 101
vaginal, *see* Vagina, operations on, 72
vaginal Cæsarean section, 333
on vulva, *see* Vulva, operations on, 62
Wertheim's operation for cancer of cervix, also for radical extirpation of uterus, 150
Orthodiagraphic method for localizing foreign bodies, 466; cut showing, 466
Osteoperiosteal grafts for wounds of face and jaws, 631
Otology, radium in, 442
Ovarian cysts, associated with fibroids, 124
axial rotation of, 213
cyst-adenoma, 214
free intracystic bleeding of, 214
papillomatous (papilliferous), 217
spurious capsules of, 221
suppurating, 212
typhoid infection of, 213
Ovarian dermoids, 215
spurious capsules of, 221
Ovarian fibroids, 216
Ovarian tumours, dermoids, 215
Ovaries, belated, fate and value of, 144
carcinoma of, 219
Chorion-epithelioma of, 235
cysts of, associated with fibroids, 124
parovarian, 207
suppurating, 212
diseases of, operations for, 207-235
epithelial infection of, 215
fibroids of, 216
operations on, oöphorectomy, 226
ovariotomy, 207
parovarian cysts, removal of, *see* Ovariotomy
removal of, indications for, 107
sarcoma of, 216
suspension of, and of Fallopian tube, cut of, 245
tumours of, carcinoma, 219
pedicle of, 210
removal, *see* Ovariotomy
Ovariotomy, 207-225
adhesions encountered in, 209
anomalous, 221
bilateral, cancer of uterus after, 140
hysterectomy after, 222, 231
pregnancy after, 222
for carcinoma, 219
for cyst-adenoma, 214
definition of, 207
for dermoids, 215
at the extremes of life, 222
for fibroids, 216
history of, 207
incision for, 208
incomplete, 221
in infants, table of, 223
instruments for, 207

Ovariotomy: (*Cont.*)
intestinal obstruction following, 31
mortality from, 224
in old age, 223
table of, 224
for papillomatous cyst, 217
pedicles, varieties and treatment of, 210
perforating ulcer of stomach or small intestine, due to, 32
position for, 208
preparation of patient for, 208
repeated, 222
for sarcoma of ovary, 216
suture of abdominal incision in, 212
Ovary, operations for diseases of the, 144, 207
Ovary and tube, tuberculous, cut of, 228

Page aluminum extension splint, cut of, 549
Page aluminum splint for fracture of humerus, cut of, 525
Palate, defects of, closure of by approximating mucoperiosteal flaps, cut showing, 659
repair of by pedicled flap of skin and platysma from neck, cut showing, 660
Von Langenbeck operation for, 659
Pancreas, wounds of, 734
Panhysterectomy, *see* Hysterectomy, total
Papillomatous cyst of ovaries, 217
Parallax method for localizing foreign bodies, 463
Paralysis, post-anæsthetic, complicating operations, 13
Parker suspension apparatus and method of application, cut of, 563
Parotitis, after abdominal operations, 17
Pedicles, of ovarian tumours, varieties and treatment of, 210
Pelvic abscess, cut showing, 391
complications, associated with fibroids in relation to hysterectomy, 124
Pelvic floor, relaxed, perineorrhaphy for, 292
girdle, section of in obstetrical operations, 342
Pelvic glands, removal of, in Wertheim's operation, 160
hæmatocele, 266
peritoneum following removal of uterus and adherent pus tubes, cut showing, 199
Pelvis, generalized suppurative inflammation of, cut showing, 390
normal, sagittal section of, cut showing, 281
sagittal section of, following transposition operation and perineorrhaphy, cut showing, 282
used as flap for peritonization, 198
Penhallow's irrigation and extension splint for fractures about ankle joint, 565, 566
Perforating ulcer of the stomach and small intestines, following abdominal operation, 32
Perineorrhaphy, 292, cuts showing, 293, 294, 295
after care, 297
for complete laceration of perineum, 298
flap method, 298
results of, 306
for high rectocele, 308; cut showing, 302, 303, 304, 305, 306, 307
for relaxed pelvic floor, 292
for rectovaginal fistula, 311
Perineum, complete laceration of, perineorrhaphy for, cuts showing, 296, 297, 298, 299, 300, 301
lacerations of the, operative treatment of, 292
ruptured, repair of, 301; preparation for, 7
Periosteal elevator, cut showing, 688
Peritoneal adhesions, chemical treatment of, 202
cavity, closure of, peritonization following, 194; cut showing, 195
opening of in colpocœliotomy, 57
in Schauta's operation, 172
suture of, in Wertheim's operation, 162
Peritonitis, acute pelvic, oöphorectomy for, 229
gonococcal, treatment of, 229

Peritonitis: (*Cont.*)
nature's method of walling off, cuts showing, 178, 180
resulting from classic Cæsarean operation, 357
due to Wertheim's operation, 166
Peritonization, 177-204
definition of, 177
methods of, 185
by chemical methods, 202
by cauterization, 194
infolding raw surfaces by sutures, 185
by omental grafts, 196
by using other abdominal structures as flaps, 198
after panhysterectomy, cuts of, 185, 200, 201, 202, 203
following removal of appendix, 188; cut showing, 192
following suspension of the uterus, combined with removal of tube and ovary, cut showing, 194
technique for burying knots in, cut showing, 183
Peroneal nerve, external involvement complicating fracture of tibia and fibula, 557
Phalanges, wounds of, 542
comminution, with complete destruction of inter-phalangeal joint, due to bullet, cut of, 544
complications of, 543
diagnosis of, 543
fracture, grooving, with radiating fissures caused by bullet, cut of, 543
perforation, simulating butterfly fracture, cut of, 544
prognosis of, 543
treatment of, 543
Pharyngeal mucous membrane, cancer of, radium treatment of, 421
Plastic operations, for repair of soft tissues, 635
burn, repair of injury due to, cut showing, 644
drainage in, 646
flaps for, 635
cutting of, 637
obtaining of, 635, 642
suitability of, 636
turning of, with narrow pedicle, 637
Plastic operations: (*Cont.*)
types of, 638
vitality of, testing for, 636
general plan, determining of, 640
location, suitable for obtaining flap, 642
arm, 644
cheek, 643
chest, 643
forehead, 642
neck, 643
rib, 644
toe, 644
post-operative treatment, 646
size and shape of defect, determination of, 641
sutures for, 645, removal of, 646
for wounds of face and jaw, 649
forehead and eyelid, repair of defect of, by pedicled flap, cut showing, 661
lip injuries, 650
circular defects, repair of, cut showing, 654
ectropian of lower, due to burn, repair of, cut showing, 657
extensive defect of lower, and chin, by Burrow Stewart's operation, cut showing, 655
reconstruction of upper lip by Burrow Stewart's method, cut showing, 656
repair of defect involving full thickness of both, cut showing, 651
restoration of angle of mouth, 651, cut showing, 652, 653
restoration of upper by cheek flaps, cut showing, 658
Rose's operation for hare lip, 656
mouth injuries, 657
orbit and eyelids, injuries of, 660
palate injuries, 659
Van Langenbeck operation, 659; cut showing, 659
repair of wounds of the face, 615
resection of a depressed scar, 649
Pleural cavity, cleaning of, 686
introduction of aspirating nozzle

Pleural cavity: (*Cont.*)
after rib resection, cut showing, 687
Pleurisy, chest wall, inner aspect of, after fatal case of, cut showing, 696
Pneumonia, after abdominal operation, 17
embolic, 17
complicating wounds of thorax, 705
inhalation, causes of, 17
Porro Cæsarean section, 358, *see* Cæsarean section, Porro
Post-anæsthetic paralysis, 13
Pregnancy, after bilateral ovariotomy, 222
complicating fibroids and hysterectomy, 125
table of cases of, 129
interstitial, 262; cut of, 263
operations performed during, preparation for, 6
rudimentary cornual, cut of, 262
special anatomy during, 369
symptoms and operative treatment of, 261
Prolapse of urethra, 61
Prolapse of uterus, 271
operations for, amputation of cervix uteri, 285
preparation of patient in, 8
vaginal hysterectomy for, 287
Prostate, carcinoma of, radium treatment of, 423
Prosthesis for replacing loss of bone in lower jaw, cut showing, 619
Pubic bone, sawing through in pubiotomy, cut showing, 348
Pubiotomy, 342
anatomy of, cut showing line of incision, 343
cut showing position of veins likely to be injured, 344
after-treatment in, 350
complications, 349
conditions for, 344
lacerations in, 349
ligature carrier for use in, cut showing, 346
passing needle around the bone, cut showing, 347
sawing through pubic bone, cut showing, 348
technique of, 345
Puerperal infections, pyæmia, 395
surgical treatment of, 387-398
efficacy of, 387
indications for, 388
Puerperal pyæmia, *see* Pyæmia, puerperal
Puerperal sepsis, causes for, 388
operations for, curettage, 389
hysterectomy, 393
vaginal drainage, 393
Puerperal thrombophlebitis, clinical picture of, 396
frequency of, 395
Pulmonary embolism, after abdominal operations, 22
Pyæmia, puerperal, clinical picture of, 395
operations for, contraindication to, 397
mortality of, 397
technique of, 398
Pyosalpinx, difficulties in removal of, 229
Pyothorax, complicating wounds of thorax, 707

Radical extirpation of uterus, by vaginal route, 167

Radio-activity, 402
table showing, 403
Radiogram of skull, showing retained metallic foreign body, cut of, 583
Radium, active deposit of, apparatus for using, 409
alpha rays, 403
apparatus for applying, 404
beta rays, 404
in dermatology, 432
for angiomata, 435
for benign tumours, 434
for chronic infections, 438
for diseases of ductless glands, 443
exophthalmic goiter, 440
for disorders of appendages of the skin, 440
for hypertrophic diseases of skin, 440
for inflammatory and granulomatous infiltrations of uncertain nature, 439
for malignant tumours, 434
for nævus pigmentosus, 437
for neuroses, 440

Radium: (*Cont.*)
Hodgkin's disease, 444
leukæmia, 443
gamma rays, 404
in general surgery, 417
for cancer of lingual, buccal and pharyngeal mucuous membrane, 420
for carcinoma of bladder, 423
for carcinoma of breast, 422
for carcinoma of œsophagus, 424
for carcinoma of prostate, 423
for carcinoma of rectum, 425
for carcinoma of stomach and intestines, 425
for epithelioma of skin, 418
for leukoplakia, 420
for malignant tumours, 417
for sarcomata, 426
for tuberculous lymphadenitis, 428
in gynæcology, 429
for carcinoma of the cervix uteri, 430
for fibromyoma of the uterus, 429
injuries due to, 446
internal administration of, 444
in internal medicine, 444
in ophthalmology, 441
in otology and laryngology, 442
for skin diseases, *see* Radium, in dermatology
Radium emanation, advantages in use of, 406
apparatus containing, 407; cut showing, 407
inhalation or swallowing of, 445
objections to use of, 407
and radio-active deposit, 401
Radium needles, description of, 405
Radium rays, a, b, c, d, e, f, and g, 401
absorption and filtration of, 409
distance filtration of, 411
dosage, 415
length of exposure, 413
methods of application, 412
pad for holding radium in position, cut showing, 413
reaction from, 414
screens for, 410
secondary, 410
Radium salt, apparatus containing, 405
Radium salts, administration of, 445
apparatus containing, 405
needles, 405
Radium therapy, 401-448
for angioma, 435
for exopthalmic goiter, 444
in gynæcology, 429
for carcinoma of cervix uteri, 430
for fibromyoma of uterus, 429
for keloid, 434
for malignant growths, 417
cancer of buccal and pharyngeal mucous membranes, 420
cancer of tongue, 420
carcinoma of bladder, 423
carcinoma of œsophagus, 424
carcinoma of prostate, 423
carcinoma of rectum, 425
carcinoma of stomach and intestines, 425
epithelioma, 418
leukoplakia, 420
sarcomata, 426
by rays, dosage, 415
for superfluous hair, 441
tuberculosis of lymphatic glands, 428
Radius, wounds of, 535
comminution, due to rifle bullet, cut of, 536
complications of, 536
diagnosis of, 537
fracture, fissured, due to shrapnel bullet, cut of, 532
fissured and grooved, due to shell fragment, cut of, 534
prognosis of, 538
splintering, due to shell fragment, cut of, 538
treatment of, 538
Rectocele, high, definition of, 308
perineorrhaphy for, 308
Rectovaginal fistula, 92
congenital, operation for, 96
operation for, 94, 311; cuts showing, 90, 91, 92, 93, 94, 96, 97, 309, 310
Retrodisplacements of uterus, operative treatment of, 312-322
advancement of bladder peritoneum upon the fundus, 316
Alexander-Adams operation for, 313
amputation of the fundus, 316

Retrodisplacements: (*Cont.*)
extra peritoneal, 313
Gilliam's operation, 322
indications for, 312
intra-abdominal, 315
postoperative care, 322
vaginal suspension by round ligaments, 313
Webster-Baldy operation, 316; cuts showing, 317, 318
modification of, 316
Rectum, carcinoma of, 425
separation of in Wertheim's operation, 156
wounds of, 732
mortality from, 733
operations for, 733
Rectum and rectal fistula, injury to in Wertheim's operation, 156
Rib resection, 683
exposure of rib for, cut showing method of, 684
Rib stripper, cow horn, cut showing, 688
Rose's operation for hare-lip, 656
Round ligaments, suspension of uterus by, 313
vaginal fixation of, 283; cut showing, 284

Salpingectomy, with conservation of ovary, cut of, 249
by excision, indications for, 248
technique of, 248
by simple ligature, indications for, 247
technique of, 247
Salpingitis, acute, oöphorectomy for, 229
Salpingo-oöphorectomy, cut of, 248
Salpingostomy, cut of, 243
definition of, 242
indications for, 242
technique of, 244
Sarcoma, of ovary, 216
of tibia and fibula, complicating hysterectomy for fibroids, 127
of uterus, associated with fibroids, 139
Sarcomata, radium treatment of, 426
Scalp, wounds of, operative treatment for, 589
Schauta's operation for radical extirpation of the uterus and vagina, 167
Septic infection, in Wertheim's operation, 166
Shears, rib, simple type of, cut showing, 685
Sherman's bone plate, in treatment of fractures, technique, 570, 573, 574
Shock, 748
anæsthetic, administration of, 749
death due to, in Wertheim's operation, 164
symptoms of, 748
treatment of, 748
blood substitution in, 749
warming patient in, 750; device for, cut showing, 750
Shoulder joint, wounds of, 496
Shrapnel, wounds caused by, fracture, comminuted, of ulna, cut of, 535
fracture, fissured of radius, cut of, 532
of ulna, cut of, 533
Sigmoid, used as flap for peritonization, 199; cuts showing, 200, 201, 202, 203
indications for, 200
Sinclair, Major, formula of, for holding extension straps to skin, 528
Skin, marking of, in localizing foreign bodies, 455
Skin diseases, radium treatment for, *see* Radium in dermatology
Skin grafting, 647
epithelial inlays, 648
full-thickness grafts, 647
Thiersch grafts, 647
Skull, radiogram of, showing retained metallic body, cut showing, 583
wounds of, 581
abscess track, healing, photograph of, 609
anatomical considerations, 584
and brain, gunshot wounds of, surgery of, 581
cerebral ventricle entered by missile, treatment of, 605
classification of, 589
closure of, 600
complications, surgical treatment of, 608

Skull: (*Cont.*)
cerebral abscess, 609
encephalitis, 608
meningitis, 608
ventriculitis, 608
dressings, with special reference to hernia cerebri, 610
foreign bodies in, 602
dangers of removal of, 603
nail and magnet, use of for removal of, cut showing, 606
gutter, cerebral damage in, cut showing, 597
partial closure of, after operation, cut showing, 596
fractures with penetration of dura, 592
operative treatment of, 595
types of, 594
without penetration of dura, treatment of, 580
left open at operation, cut showing, 605
operations for
anæsthesia in, 585
bone, block of, removed, cut showing, 601, 602
dead tissue removal, 599
general considerations, 588
procedure in, 588
tripod incision, cut showing, 600
use of catheter in, 598
optimum time for operation, 581
small penetrating, cut showing, 598
penetration by metallic foreign body, damage due to, cut showing, 599
postoperative treatment, 610
preliminary preparation of, 582
neurological examination, 583
prognosis of, 612
removal of area of injury, cut showing, 595
scalp wounds, 589
sinus, control of, 604
through and through wounds, 606; cut showing, 607
mortality of, 607
Sodium citrate solution, as a method of peritonization, 204
Soft parts, wounds of, 754
by bullets, 758
by shell or grenade fragments, 757
by shrapnel, 758
treatment, by débridement, 758
technique of, 760
suture, bacteriologic examination of wounds with reference to, 768
suture delayed, primary, 767
secondary, 767
Spleen, wounds of, 735
operations for, 735
symptoms of, 735
Splints, Cabot posterior, cut of, 564
canvas anklet and traction band, cut showing, 753
especially constructed to hold leg in position after removal of plaster on account of œdema in shell wound of tibia; cut of, 575; history of case, 573, 574
extension, Page aluminum, cut of, 549
for reduction and proper alignment of fracture of metacarpus, cut of, 542
Hodgen's modified, for compound fracture of humerus treated by extension and suspension, cut of, 527
intraoral, nasal or facial, apparatus for immobilizing, cut showing, 618
ladder, material for, 753; cut showing, 761
Liston, 753; cut showing, 758
method of application of, and strapping to hold arm, in proper position, cut of, 523
nail twister or Spanish windlass, 752; cut showing, 755
Page aluminum, applied for fractures of humerus, cut of, 525
Penhallow's irrigation and extension, for fractures about ankle joint, cut of, 565
right-angled, for fractures of elbow or forearm, 526
Thomas' arm, hinged modification of, 752; cut showing, 757
Thomas', modified, for fractures of humerus, cut of, 524
Thomas' traction leg, cut showing, 751
hinged modification of, 751; cut showing, 752

Sterilization performed with Cæsarean section, 362
indications for, 362
methods of, 365
Stitch abscess, due to buried sutures, 39
Stomach, carcinoma of, radium treatment for, 425
dilation of, following abdominal operations, 40
after classic Cæsarean section, 357
wounds of, 727
mortality from, 729
operations for, 728
symptoms of, 728
Streptococcal infection, diagnosis of, 771
treatment of, 772
Stretcher cradle for transport of patients with fractures, cut showing, 756
Suppurating ovarian cysts, 212
Suprasymphyseal cervical Cæsarean section, 366, *see* Cæsarean section, suprasymphyseal cervical
Suspension apparatus, Parker, and method of application, cut of, 563
Suspension frame for fracture of thigh, cut of, 550
Suspension of uterus by Webster's method, peritonization following, 192
Suture, of abdominal incision in ovariotomy, 212
Suture, buried, removal of, 39
use of, 38
delayed for wounds of face and jaw, indications for, 625
technique of, 626
infolding raw surfaces by, 185
indications for, 186
technique of, 187
mattress, diagram of, 107
of peritoneal floor in Wertheim's operation, 162
placed through fundus of uterus in transposition operation, cut showing, 278
postoperative thrombosis, due to, 21
Suture materials for operation on uterine tubes, 241
Symphysiotomy, 343

Tent, insertion of, in gynæcological operations, 8
Tetanus, after operations, 28
of wounds, 773
Thiersch grafts, 647
Thigh, wounds of, 549
treatment of, Page aluminum extension splint, cut of, 549
suspension frame for fracture, cut of, 550
without union after prolonged convalescence, case illustrating, 552
Thomas' arm extension splint, fracture treated by, cut of, 521
Thomas' arm splint, hinged modification of, 752; cut showing, 757
Thomas' splint, modified, for fractures of humerus, cut of, 524
Thomas' traction leg splint, 751
hinged modification of, 751
cut showing, 752
Thoracic parietes, injury to, 671
Thoracotomy, 682
blocking of phrenic nerve, 688
cleaning of pleural cavity after, 686
introduction of aspirating nozzle into pleural cavity, after rib resection, cut showing, 687
closure of chest wall after, fat and muscle closed over defect caused by rib resection, 701; cut showing, 700
insertion of single and mattress suture, 698; cut showing, 697
insertion of wire rib stay, 699; cut showing, 698
pectoralis major and latissimus dorsi, margins of united with mattress sutures, 701; cut showing, 701
rib stay drawn taut, 700; cut showing, 699
superficial fascia, deep layer of, closed with buried sutures, 701; cut showing, 702
of election, 683
aspirating nozzle introduced into pleural cavity after rib resection, cut showing, 687

Thoracotomy: (*Cont.*)
position of patient, cut showing, 683
lung, margin of being guided toward wounds by Tuffier's forceps, cut of, 693
rib exposed for resection, method of exposing, cut showing, 684
indications for, 682
instruments for, cut showing, 685, 686, 687, 688
limited, 682
of necessity, 683
rib resection, 683
Thorax, wounds of, 665-708
bibliography, 708
blood transfusion in, 690
complications, empyema, 704
foreign body, retained in, 705
removal of, 706
hæmothorax, 676
pleurisy, 705
pneumonia, 705
pyothorax, 707
drainage after operative treatment, 702
materials for, cut showing, 704
excision of parietal wounds, 681
intrathoracic resistance to infection, 665, 669
principles of treatment, 670
postoperative treatment, 703
surgical methods for, 678
thoracotomy for, *see* Thoracotomy, 682
treatment, pre-operative, 678
types of, 671
involving parietes and viscera, 672
injuries to thoracic parietes, 671
involving viscera alone, 674
Throat, diseases of, radium treatment for, 442
Thrombophlebitis, puerperal, clinical picture of, 396
Thrombosis, postoperative, complicating abdominal operations, 19
prophylactic measures against, 21
Thumb, comminution of terminal phalanx, illustration, 544
Thyroid gland, lesions of, complicating fibroids, in relation to hysterectomy, 123
Tibia, wounds of, 555
comminution and displacement due to shell, with treatment by bone plating and splint, cuts of, 574, 575; history of case, 573, 574
complications of, 557
diagnosis of, 557
erosion, just below tubercle, due to small shell fragment, cut of, 558
fracture, comminuted, due to bullet, cut of, 556
of fibula and due to shell fragments, cut of, 556
complete with moderate comminution, due to grenade, cut of, 561
grooving, due to bullet, cut of, 555
perforating, associated with fissured fracture and some comminution, cut of, 554
due to bullet, cut of, 553
by rifle bullet, cut of, 554
prognosis of, 558
splintering, due to shell fragment, cut of, 559
treatment of, 558
Tibia and fibula, sarcoma of, after hysterectomy, 127
Tibial arteries, hæmorrhage, complicating fracture of tibia and fibula, 557
Tongue, cancer of, radium treatment of, 420
Total hysterectomy, peritonization after, cut of, 185
Trachoma, radium treatment for, 441
Traumatic fistulæ, following wounds of face and jaw, 626
treatment of, 627
types of, 626
Trench foot, 773
complications of, 774
treatment of, 774
Trendelenburg operation for embolism of pulmonary artery after hysterectomy, 25
Tripod incision, for gunshot wounds of skull, cut showing, 600
Trismus, 626

Tubal abortion, differential diagnosis, 265
hæmorrhage of, 264
occurrence of, 264
operations for, by abdominal route, 267
indications for, 266
technique of, 267
by vaginal route, 267
para-tubal hæmorrhage, 265
pelvic hæmatocele, 265
physical signs of, 266
peri-tubal hæmatocele, 265
Tuberculous lymphadenitis, radium treatment for, 428
Tuberculosis of the skin, radium treatment for, 438
Tuffier's rib spread, cut showing, 686
Tumours, malignant, *see* Carcinoma
of ovary, carcinoma, 219
dermoids, 215
fibroids, 216
pedicle of, 210
removal of, *see* Ovariotomy
sarcoma, 216
of vagina, benign, removal of, 76
of vulva, benign, removal, of, 69

Ulna, wounds of, 535
comminution, due to rifle bullet, cut of, 536
complications of, 536
destruction, due to grenade, cut of, 539
diagnosis of, 537
fracture, comminuted, due to shrapnel bullet, cut of, 535
fissured, due to shrapnel bullet, cut of, 533
fissured and perforated, from deformed and disintegrated bullet, cut of, 534
prognosis of, 538
treatment of, 538
Ureter, injuries to, following hysterectomy, 32
ascertaining which ureter, 34
avoidance of treatment of, 33
in Wertheim's operation, 151
sclerotic obliteration of, 34
treatment of in Schauta's operation, 171
Ureter: (*Cont.*)
in Wertheim's operation, 154, 156
wounds of, 737
Ureteric fistula, removal of kidney for, 34
spontaneously healed, results following, 35
Urethra, displacement of during labour, cuts showing, 271, 272
operations upon, 60
prolapse of, 61
Urethral caruncle, removal of, 61; cut showing, 62
Urethrocele, definition of, 272
operations for, advancement, 283
amputation of cervix uteri for, 285
excision of part of body of uterus for, 286
transposition, 273; cuts showing, 274, 275, 276, 277, 278, 279, 280
vaginal fixation of the round ligaments, 283
vaginal hysterectomy, 287
postoperative treatment, 288
Uterine abscess following classic Cæsarean section, 357
Uterine artery, ligature of, in Wertheim's operation, 155, 156
Uterine displacements, operative treatment of, 271-330
for cystocele and uterine prolapse, 271
for inversion of uterus, 323
for perineorrhaphy, 292
for retrodisplacements, 312
Uterine drainage after classic Cæsarean section, 356
Uterine fibroids, bicornate, illustration, 118, 119
complications of, in relation to hysterectomy, *see* Fibroids, complications of, on double uterus, 119
globular intramural, illustration of sagittal section, 113
impaction of, in pelvis, 111
sessile subserous, illustration of, in section, 114
subserous, illustration of, in section, 133

Uterine fibroids: (*Cont.*)
twin, illustration of sagittal section, 112
with twisted pedicle, 113
Uterine polyps, extirpation of, 45
Uterine prolapse, operative treatment of, 271
Uterine tubes, bacteriology of, in relation to operations, 230
cancer of, primary, cut of, 234
operation for, 232
chorion-epithelioma of, 235
dilatation of, 242
fixation of, 244
infected, cut of, 227
operations on, acrohystero-salpingectomy, 249
conservative, 242-246
dangers and difficulties of, 252
dilatation of, 242
eradicative, 247-253
fixation, 244
general indications for, 238
hystero-salpingectomy, 251
method of access, 239
preliminary details, 239
salpingectomy by excision, 248
by simple ligature, 247
salpingostomy, 242
suture and ligature materials, 241
removal of, 365; cut showing method of, 367
indications for, 247
tuberculosis of, 230
Uterine tube and ovary, actinomycosis of, 231
tuberculous, cut of, 228
Utero-sacro ligaments, division of in Wertheim's operation, 157
shortening of, cuts showing, 314, 315
Uterovaginal fistula, operation for, 90
Uterus, adenomyoma of, 140
adenomyomatous and tuberculous, cut of, 141
amputation of in obstetrical cases, *see* Cæsarean section, Porro
bicornate, hysterectomy on, 119
blood supply of, diagram showing, 105
cancer of, 138, *see* Cancer of uterus
chorio-epithelioma in, 173
curettage of, for puerperal infections, 390
Uterus: (*Cont.*)
effect on, of bilateral oöphorectomy and ovariotomy, 231
exploration of, 43
fibromyoma of, radium treatment of, 429
flora of, in relation to hysterectomy, 120
fundal resection of, peritonization following, 188
fundus of, suture placed through in transposition operation, cut showing, 278
impacted in pelvis, 111
intravaginal operations on, 43
inversion of, 323, *see* Inversion of uterus
malignant disease of the, operations for, 150, 173
operations on, abdominal myomectomy, 131-135
hysterectomy, 101-130
subtotal, 101, 106
total, 101, 109, 174
vaginal, 102
for malignant disease of, 149-174
for non-malignant affections of, 101-146
palliative, for cancer of, 173
radical extirpation by abdominal route, 150; cuts showing, 154, 155, 157, 158, 159, 160, 161
causes of death and complications of, 164
ultimate results of, 163
radical extirpation by vaginal route, 167; cuts showing, 168, 169, 170, 171
Webster's, 192
prolapse of, 271, *see* Prolapse of uterus
retrodisplacements of, 312, *see* Retrodisplacements of uterus
suspension of, by Webster's method, peritonization following, 192; cut showing, 193
suture of in classic Cæsarean section, 354; cut showing, 355
vaginal suspension by round ligament, 313

Vagina, artificial, making of, 73
Baldwin's method, 74; cut showing, 75

Vagina: (*Cont.*)
Robinson's method, 74
closure of, in Schauta's operation, 168
disinfection of previous to transposition operation, 275
division of, in Wertheim's operation, 159
operations on, 72
for atresia or stenosis, 72
for benign tumours, removal of, 76
hysterectomy, *see* Vaginal hysterectomy, 102
preparation of, for Wertheim's operation, 152
treatment of, in Schauta's operation, 168
Vaginal Cæsarean section, *see* Cæsarean section, vaginal, 333
Vaginal cystotomy, 60
Vaginal fixation of round ligaments, 283; cut showing, 284
Vaginal hysterectomy, 102, 287; cuts showing, 103, 288, 289, 290, 291
for cystocele and uterine prolapse, 287; cuts showing, 288, 289, 290, 291
Mayo's method, 104; cuts showing, 288, 291
Vaginal introitus, operation for enlargement of, 69; cut showing, 70
Vaginal operation, for cancer of cervix, Schauta's, 167
Vaginal wall, incision of, in anterior colpohysterotomy, cut showing, 324
Varnish, adhesive, for holding extension straps, 527
Ventricle, lateral, position of, diagram showing, 585
Ventriculitis, complicating gunshot wounds in skull, surgical treatment of, 608
Vermiform process, thickening of, associated with fibroids, 124
Vesico-vaginal fistula, operation for, 60, 79; cuts showing, 82, 83, 84, 85, 86, 87, 88, 89
Mackenrodt's, cut of, 83
preparation of patient for, 7
preparatory treatment of, 80
Sim's, cut showing, 82
Visceral complications with fibroids in hysterectomy, 122
Visceral injuries,
symptoms of, 719
treatment of, 727
Vomiting, postoperative, 39
Vulva, circumcision of, 67
elephantiasis of, cuts showing, 63, 64, 65, 66
excision of, 62
operations on, 62
circumcision, 67
clitoridectomy, 67
enlargement of vaginal introitus, 69
excision of, 62
extirpation of varicose veins, 72
hydrocele of labia majora, removal of, 72
hymen, discission of, 68
tumours and cysts, removal of, 69
vulvovaginal gland, removal of, 71

Webster-Baldy operation, 316; cuts showing, 317, 318
Webster's method of suspension of uterus, peritonization following, 192
Wertheim's operation for cancer of cervix, 150
Wertheim's operation for radical extirpation of uterus, by the abdominal route, 150
Wounds, of abdomen, 709, *see* Abdomen, gunshot wounds of
of ankle and foot, *see* Ankle and foot, wounds of, 501
of arm, *see* Arm, wounds of, 537
of bladder, 737
of colon, 731
complications associated with, in femur, 545
of diaphragm, 672, *see* Diaphragm, wounds of
of face, 770, *see* Face, wounds of
of femur, *see* Femur, wounds of, 543
of fibula, *see* Fibula, wounds of, 555
of foot, *see* Foot, wounds of, 501, 563, 567, 771

Wounds: (*Cont.*)
of forearm, *see* Radius, wounds of, 535, *also,* Ulna, wounds of, 535
giving way of, after operations, 14
of hands, 770, *see* Hands, wounds of
of humerus, 523, *see* Humerus, wounds of
of intestine, small, 729
of joints, 491, *see* Joints, wounds of
of kidney, 736
of leg, 543, *see* Leg, wounds of
of liver, 733
of long bones, *see* Long Bones, wounds of, 509
of metacarpal bones, 540, *see* Metacarpal bones, wounds of
of metatarsals, 561, *see* Metatarsals, wounds of
of pancreas, 734
perforating, of arm, due to bullet, cut of, 537
of tibia, cuts of, 553, 554
associated with fissured fracture and some comminution, cut of, 554
due to bullet, cut of, 553
Wounds: (*Cont.*)
of phalanges, *see* Phalanges, wounds of, 542
of radius, *see* Radius, wounds of, 535
of rectum, 732
of scalp, 589, *see* Scalp, wounds of
of skull, 581, *see* Skull, wounds of
of soft parts, 754, *see* Soft parts, wounds of
of spleen, 735
of stomach, 727
of thigh, 549, *see* Thigh, wounds of
of thorax, 665, *see* Thorax, wounds of
of tibia, 555, *see* Tibia, wounds of
of ulna, 535, *see* Ulna, wounds of
of ureter, 737
Wrist joint, perforating wound treated by primary excision, cut showing, 498

X-ray, extraction of foreign bodies under guidance of, 477
bonnet method, 484
open screen method, 480
X-ray tube, centering of for localization work, 454; cut showing, 455